

# Review Article **Compte rendu**

## Surgical approaches for cesarean section in cattle

Loren G. Schultz, Jeff W. Tyler, H. David Moll, Gheorghe M. Constantinescu

**Abstract** – Bovine practitioners are often presented with dystocias that require a cesarean section. Many practitioners perform this surgery using the same approach each time due to their comfort with one specific approach or lack of familiarity of other available options. The goal of this article is to explain the advantages, disadvantages, and indications for each of the different approaches to aid the practitioner in achieving better surgical success rate.

**Résumé** – **Les approches chirurgicales pour la césarienne chez les bovins.** Les praticiens bovins sont souvent confrontés à des dystocias nécessitant une césarienne. Plusieurs praticiens réalisent cette chirurgie en utilisant régulièrement une même approche bien maîtrisée plutôt qu'une autre approche moins familière. Le but de cet article est d'expliquer les avantages, les désavantages et les indications de chacune des différentes approches afin d'aider le praticien à obtenir un meilleur taux de succès chirurgical.

(Traduit par Docteur André Blouin)

Can Vet J 2008;49:565–568

### Introduction

**C**esarean section is potentially indicated in cases of dystocia when a calf cannot be delivered by fetal rotation and extraction. There are 8 available surgical approaches for the bovine cesarean section: the standing left paralumbar celiotomy, standing right paralumbar celiotomy, recumbent left paralumbar celiotomy, recumbent right paralumbar celiotomy, recumbent ventral midline celiotomy, recumbent ventral paramedian celiotomy, ventrolateral celiotomy, and the standing left oblique celiotomy. Each has its own advantages and disadvantages. Selection of an approach should be based on the type of dystocia, the cow's condition, the environmental conditions, the availability of assistance, and the surgeon's preference. The goal of this review article is to familiarize practitioners with each of the approaches to assist them in choosing an optimal approach.

### Source material

Medline, accessed via PubMed, was used to collect the majority of the references that were used in describing experimental work (keywords included: cesarean, uterus, xylazine, bovine, sutures, and ruminant). The textbook, *Techniques in Large Animal*

*Surgery* by Turner and McIlwraith, was used for the historical review. Older review articles also served as resources.

### General considerations

Cesarean section is potentially indicated in cases of dystocia when a calf cannot be delivered by fetal rotation and extraction. The decision on whether to perform a fetotomy or a cesarean section is dictated by whether the calf is alive, the availability of operating space in the cow's pelvis, whether the cervix is open, access to restraint facilities, perceived value of the cow, perceived value of the calf, and the importance of future cow fertility (1). Perhaps the most important factor in choosing between these 2 procedures is the specific preference and expertise of the practitioner.

### Guiding principles

Although a number of procedures are available for cesarean section and these procedures vary greatly, there are common principles that guide the veterinarian in the selection of the surgical approach and conduct of the procedure. A paramount goal of cesarean section should be to limit the contamination of the peritoneal cavity with uterine contents. Peritoneal cavity contamination, particularly in cattle with dead, emphysematous fetuses, greatly increases the risk of peritonitis, limits the cow's chances of survival, and limits the surviving cow's productivity.

It is important to exteriorize the uterus. This aids in limiting peritoneal cavity contamination, thereby aiding in the prevention of peritonitis. The choice of surgical procedure has a direct bearing on whether the practitioner is able to exteriorize the uterus. Large fetuses, large cows, and small stature all limit the ability of the veterinarian to exteriorize the uterus. For example,

---

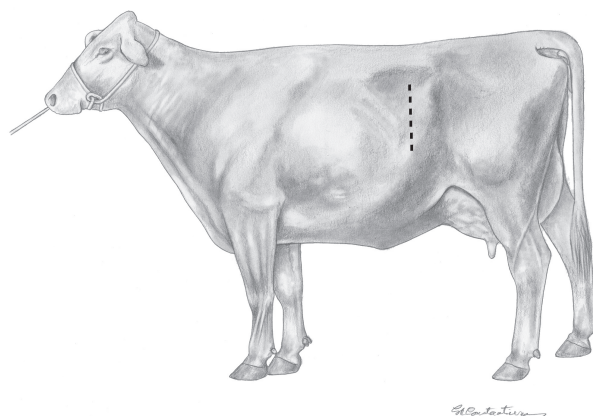
Departments of Veterinary Medicine and Surgery (Schultz, Tyler); Biomedical Sciences (Constantinescu) University of Missouri Columbia, Missouri 65211, USA; and Department of Veterinary Clinical Sciences, Center of Veterinary Health Sciences, Oklahoma State University, Stillwater, Oklahoma 74078, USA (Moll).

Address all correspondence and reprint requests to Dr. Schultz; e-mail: schultzlo@missouri.edu

when delivering a fetus in anterior presentation, a common method to exteriorize the gravid uterus is for the surgeon to enter the peritoneal cavity with his/her hand and identify the gravid horn of the uterus. Then, rather than attempting to lift the entire uterus, the surgeon identifies and grasps a rear limb in the middle of the shaft of the metatarsus. The surgeon's other hand is then placed over the point of the tarsus. The limb is rocked toward the incision, lifted through the incision, and the hock is wedged in the cranioventral aspect of the incision. When delivering a calf in posterior position, the surgeon grasps the metacarpus and the carpus is wedged in the incision. After positioning the limb in the incision, the uterus is incised avoiding cotyledons, the limb is grasped directly and traction is placed on the calf. Uterine incisions should be positioned on the greater curvature of the uterus and the incision should be placed distant from either the cervix or apex of the horn. As a general rule, an incision from either the metatarsus or metacarpus to the foot is sufficiently long to permit extraction of the calf without causing uterine tears. As the calf is being extracted, the contralateral limb is identified and exteriorized, and the uterus is brought out with the calf as it is exteriorized. Attempts to lift the entire uterus out through the abdominal incision prior to incising the uterus usually fail, due to the combined weight of the fetus and uterus. Attempts to manipulate or grasp the uterus rather than the fetus will often cause uterine tears and abdominal contamination.

The uterus should be closed with an absorbable monofilament suture on a tapered needle in a continuous inverting pattern. Sutures should be placed only partial thickness, incorporating the serosa and muscular layer of the uterus. Studies have examined uterine healing when a number of different suture materials have been used. Surprisingly, large sized, plain catgut is probably the suture material of choice. Synthetic absorbable sutures persist longer in tissues and have been associated with more dramatic scarring of the uterus (2–5). Additionally, catgut appears less prone to cause uterine tears when tension is placed on the suture line. Braided suture materials seem particularly prone to cause tearing of the uterus as they are tightened. In terms of suture patterns, the use of the Utrecht pattern with all portions of suture, including starting and finishing knots buried, appears to be the best (1). Exposed suture is a nidus for adhesions following intra-abdominal surgery (7,8). In cases of an emphysematous fetus or if the uterus is friable, the surgeon may decide to oversew the uterus with a 2nd layer.

Sedating the cow with xylazine prior to uterine closure is not recommended. Xylazine has a direct myotonic effect, causing uterine contractions, which make the uterus friable (7,9–11). These contractions may make exteriorization of the uterus and suture placement more difficult and problematic, increasing the likelihood of uterine tears during closure. During standing approaches, the need for sedation is obviated by good restraint facilities and local anesthesia. For recumbent procedures, casting, restraint, and local anesthetics should permit the surgical approach, fetal extraction, and uterine closure. In cows that struggle or remain fractitious the surgeon may choose to administer xylazine after uterine closure is completed.



**Figure 1.** Standing left paralumbar celiotomy. The placement of the incision is indicated by the dashed line.

### Standing left paralumbar celiotomy

The standing left paralumbar celiotomy is the most commonly used approach for an uncomplicated cesarean section (1,12). In general, paralumbar approaches are often favored by practitioners because most food animal practitioners are familiar with this approach. The approach is sufficiently similar to that used for rumenotomy and either the right or left approaches to correct abomasal displacement, so that most practitioners have a high degree of comfort with this approach. The incision is made vertically in the middle of the paralumbar fossa, starting approximately 10 cm ventral to the transverse processes of the lumbar vertebrae and continuing ventrally, far enough to allow removal of the calf (Figure 1). Closure of the abdominal wall is straightforward and relatively easy. Absorbable suture is used to close the abdominal musculature. The rumen aids in retaining the abdominal viscera within the peritoneal cavity. Absolute requirements for this procedure include an appropriate restraint facility and a cow capable of standing through the entire procedure. Contraindications for this procedure include an inability of the patient to stand through the procedure and large fetuses that preclude exteriorization of the uterus. Lifting a uterus and calf to the paralumbar incision is usually difficult and occasionally impossible for some practitioners.

### Standing right paralumbar celiotomy

This approach has all the indications and contraindications of the left paralumbar approach (1,12). The additional and perhaps most important difference between the left and right paralumbar approach is the difficulty in keeping viscera in the peritoneal cavity with the right paralumbar approach. Most practitioners studiously avoid this approach; however, some practitioners feel right horn pregnancies are more manageable with the right paralumbar approach. This approach is helpful when a large calf can be palpated in the right horn with its limbs directed towards the right side of the cow or heifer and on cows with hydrotic condition of the uterus. In the case of an animal with such a condition, the location of the rumen and the increased size of the uterus seem to force the uterus into the right paralumbar fossa, permitting easier removal of the fetus, limiting abdominal

contamination, and permitting the surgeon to leave substantial volumes of fluid within the lumen of the uterus. This is not to suggest that cesarean section is the treatment of choice for hydrotic conditions of the uterus; however, the practitioner is occasionally presented with cows whose hydrops condition is sufficiently advanced that it seems unlikely that the cow will survive an induced parturition.

### Recumbent left paralumbar celiotomy

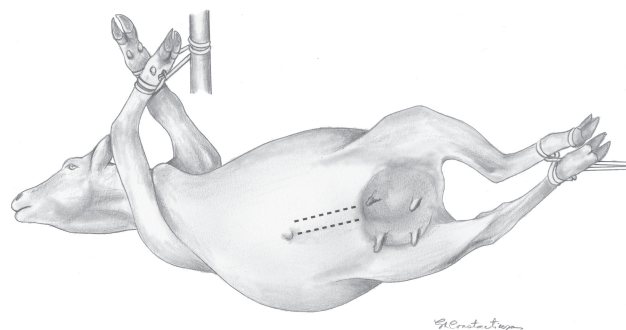
This approach differs little from the standing left paralumbar approach (1). Additional assistance is nearly always needed to cast the cow, if not recumbent already, and to place the cow in right lateral recumbency. The incision is made slightly more ventral than in the standing left paralumbar celiotomy. Exteriorization of the uterus is often difficult because the gravid uterus falls away from the incision. Closure is more difficult than when the standing left paralumbar approach is used, due to increased tension on the muscle layers, but it is rarely problematic.

### Recumbent right paralumbar celiotomy

This approach is very seldom used, as it is very similar to that of recumbent left paralumbar celiotomy and has the additional complication of not having the rumen to retain the abdominal viscera (1).

### Recumbent ventral midline celiotomy

This approach is straightforward and is most commonly used on a recumbent animal (1). If the incision is appropriately placed, the only body wall layers incised are the skin, subcutis, and the linea alba. Additional assistance is required to cast and position the cow for this approach. The cow is typically positioned in dorsal recumbency, leaning toward the surgeon at a 45 degree angle (Figure 2). Both front and hind feet are tied to a gate or wall. This positioning is critical. If the cow is positioned either in exact dorsal recumbency or leaning away from the surgeon, exteriorization of the uterus becomes problematic, if not impossible. Once the peritoneal cavity has been opened, it may be necessary to pull the greater omentum cranially to expose the uterus. Exteriorizing the uterus is facilitated by untying the hind feet only and temporarily laying the hind limbs flat on the ground. After removal of the fetus and closure of the uterus, the cow is repositioned in dorsal recumbency and the linea alba is closed. Closure of the abdominal wall is often difficult. The authors typically close the linea with polyglactin 910 (#3 Vicryl, Ethicon; Johnson & Johnson, New Brunswick, New Jersey, USA) in an everting interrupted horizontal mattress pattern. Eversion of the linea permits the surgeon to oversee the linea with relative ease and safety. Other appositional suture patterns, including simple continuous, may be used. Some practitioners may choose to close the linea alba with a braided nonabsorbable suture; however, this choice will cause carcass contamination with foreign material. A surgeon's knot, 2 overhand knots on the 1st throw, facilitates appositional closure of the linea alba. In cases where closure of the abdomen wall is difficult, loosening the back legs and using Bachaus towel clamps to appose the 2 sides of the incision will help to relieve the tension prior to



**Figure 2.** Recumbent ventral midline celiotomy and recumbent ventral paramedian celiotomy. The placement of the incision is indicated by the dashed line.

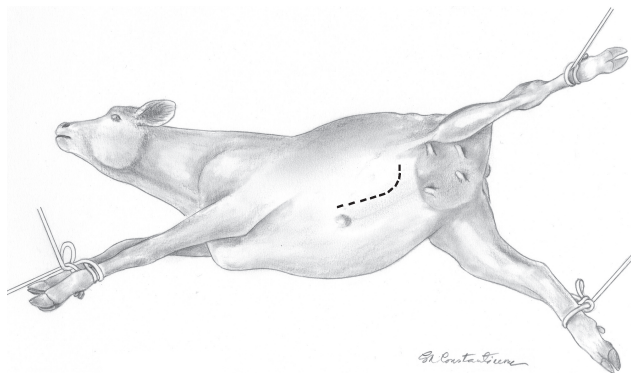
tying the knots. Integrity of abdominal wall closure is critical. Less than optimal closure may result in either abdominal wall herniation or, in severe cases, evisceration of the cow. The ease with which the uterus is exteriorized with this approach makes it optimal for exteriorizing the uterus, a critical issue when the surgeon is attempting to remove an emphysematous fetus. This approach is also ideally suited to 1st calf heifers of the beef breeds, because the incision is somewhat hidden and does not involve retail cuts, suggesting that this approach would be preferable, if the producer is likely to sell the animal for slaughter soon after the procedure. This approach should be used when the large udder of older beef and dairy cows precludes extending the incision sufficiently caudad to permit ready exteriorization of the uterus, and when udder edema and the increased ventral vasculature make this approach more complicated.

### Recumbent ventral paramedian celiotomy

This approach is similar in most respects, including the advantages and contraindications, to the ventral midline approach (1,12). The abdominal wall incision is placed parallel and approximately 5 cm lateral to the linea alba (Figure 2). Some authors have postulated that the abdominal wall closure of the paramedian approach is more secure than that of the ventral midline approach. This makes little sense. Neither the internal sheath of the rectus abdominis muscle, nor the rectus abdominis muscle has substantial holding properties and it would seem that a 1-layer abdominal closure is easier and, hence, preferable to a 3-layer closure.

### Ventrolateral celiotomy

This approach is similar to the other ventral approaches, but it may be better suited for the older dairy or beef cow (1,12). The cow is positioned in right lateral recumbency. The hindlimbs should be extended caudally and the upper limb abducted for the best exposure to the incision site (Figure 3). This approach uses a curvilinear incision that is roughly parallel to the last rib; it starts approximately 5 cm lateral to the umbilicus and courses caudodorsally toward the inguinal area (Figure 3). This approach readily permits exteriorization of the uterus, making it suitable for removal of a large emphysematous fetus. In cattle with a large udder, the incision is more readily extended caudally than when the ventral midline or ventral paramedian approach



**Figure 3.** The proper positioning of the cow and incision site for the ventrolateral celiotomy. The placement of the incision is indicated by the dashed line.

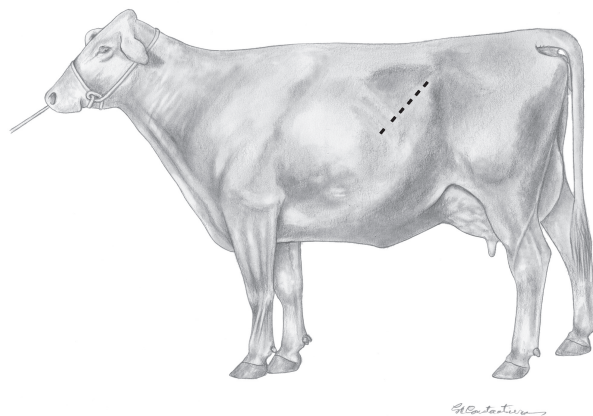
is used. Consequently, this approach may have utility in dairy cows and older beef cows. In addition, this incision is not readily visible in a standing cow, which may be an advantage if the cow is going to be sold soon after the operation. Closure of the incision is often more difficult than with the other approaches, as more tension is placed on the muscle layers. The integrity of the abdominal wall closure is less secure than that of either the ventral midline or ventral paramedian approaches and therefore, more prone to herniation and evisceration of the cow.

### Standing left oblique celiotomy

This described variation of the left paralumbar celiotomy approach has distinct advantages (4,13). In this approach, the incision starts 4 to 6 cm ventral and cranial to the tuber coxae, extends cranioventrad at a 45 degree angle to the ground, and terminates at the last rib (Figure 4). This incision extends further cranially and more ventrally than the traditional left paralumbar incision; it can also be used in the recumbent left approach. The external abdominal oblique muscle is incised in the same direction as the skin. The internal abdominal oblique and transversus abdominus muscles can then be gridded parallel to the incision using a combination of sharp and blunt dissection. Herniation is less problematic than with the ventral approaches; however, the apex of the gravid uterus is far more readily exteriorized in this procedure compared with the other standing procedures. This approach holds distinct advantages for surgeons with either smaller stature or less physical strength. The patient must be adequately restrained and must be able to remain standing, but as with the other standing procedures, minimal assistance is needed.

### Summary

Most surgeons use a standing left paramedian celiotomy to perform cesarean section in the cow. The left oblique approach is preferable under most circumstances, because the uterus is readily exteriorized, limiting peritoneal cavity contamination. Alternative approaches are available that will further limit the



**Figure 4.** Standing left oblique celiotomy. The placement of the incision is indicated by the dashed line.

potential for contamination. Practitioners are encouraged to consider alternate approaches for certain conditions.

### Author contributions

Drs. Schultz, Tyler, and Moll collaborated in the writing of the manuscript and Dr. Constantinescu provided editing and the illustrations.

CVJ

### References

1. Campbell ME, SL Fubini. Indications and surgical approaches for cesarean section in cattle. *Compend Contin Educ Pract Vet* 1990;12: 285–292.
2. Driscoll GL, Baird PJ, Merkelbach PJ, Smith DH. Synthetic absorbable and nonabsorbable microsutures: a histological comparison. *Clin Reprod Fertil* 1982;1:151–156.
3. Holtz G. Adhesion induction by suture of varying tissue reactivity and caliber. *Int J Fertil* 1982;27:134–135.
4. Newman KD, Anderson DE. Cesarean section in cows. In: Smith RA, Desroches A, eds. *Update in Soft Tissue Surgery*. *Vet Clin North Am Food Anim Pract.* 2005;21:73–100.
5. Quesada G, Diago V, Redondo L, Rodriguez-Toves L, Vaquero C. Histologic effects of different suture materials in microsurgical anastomosis of the rat uterine horn. *J Reprod Med* 1995;40:579–584.
6. Riddick DH, DeGrazia CT, Maenza RM. Comparison of polyglactic and polyglycolic acid sutures in reproductive tissue. *Fertil Steril* 1977;28:1220–1225.
7. Jansen CA, Lowe KC, Nathanielsz PW. The effects of xylazine on uterine activity, fetal and maternal oxygenation, cardiovascular function, and fetal breathing. *Am J Obstet Gynecol* 1984;148:386–390.
8. Moll HD, Wolfe DF, Schumacher J, Wright JC. Evaluation of sodium carboxymethylcellulose for prevention of adhesions following uterine trauma in ewes. *Am J Vet Res* 1992;53:1454–1456.
9. Hoeben D, Mijten P, de Kruif A. Factors influencing complications during cesarean section on the standing cow. *Vet Q* 1997;19:88–92.
10. Perez R, Garcia M, Arias P, Gallarado M, Valenzuela S, Rudolph MI. Inhibition of xylazine induced uterine contractility by clenbuterol and nifediprine. *Res Vet Sci* 1997;63:73–76.
11. Sakamoto H, Misumi K, Nakama M, Aoki Y. The effects of xylazine on intrauterine pressure, uterine blood flow, maternal and fetal cardiovascular and pulmonary function in pregnant goats. *J Vet Med Sci* 1996;58: 211–217.
12. Turner AS, McIlwraith CW. *Techniques in Large Animal Surgery*. Philadelphia: Lea & Febiger, 1982:277–283.
13. Parish SM, JW Tyler, JV Ginsky. A left oblique celiotomy approach for cesarean section in the standing cow. *J Am Vet Med Assoc* 1995;207: 751–752.