


SURGICAL OPERATIONS

FOR 6th YEAR

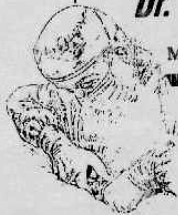

By
Wael Metwaly Sayed

| CONTENTS | |
|--------------------------------------|-------------|
| Chapter | Page |
| * Introduction | 1 |
| * General Surgery | |
| 1. Thyroidectomy..... | 3 |
| 2. Radical Mastectomy..... | 7 |
| 3. Hernial Operations..... | 10 |
| 4. Sympathectomy..... | 18 |
| 5. Amputation..... | 20 |
| 6. Operations for Varicose Vein..... | 22 |
| 7. Venous Cut down..... | 24 |
| 8. Ingrowing Toe nail..... | 25 |
| 9. Sebaceous Cyst..... | 25 |
| 10. Management of Abscesses..... | 26 |
| * G.I.T Surgery | |
| .Abdominal Incisions..... | 29 |
| 1. Gastrostomy..... | 31 |
| 2. Gastrectomy..... | 32 |
| 3. Splenectomy..... | 36 |
| 4. Cholecystectomy..... | 38 |
| 5. Exploration of CBO..... | 40 |
| 6. Appendicectomy..... | 42 |
| 7. Colostomy..... | 44 |
| 8. Haemorrhoidectomy..... | 46 |
| 9. Operations for Anal Fissure..... | 47 |

| Chapter | Page |
|-------------------------------------|------|
| * Urinary Tract Surgery | |
| . Renal Incisions..... | 49 |
| 1. Nephrostomy..... | 50 |
| 2. Nephrectomy..... | 51 |
| 3. Removal of Renal Stones..... | 53 |
| 4. Uretero -lithotomy..... | 54 |
| 5. Cystolithotomy..... | 55 |
| 6. Prostatectomy..... | 56 |
| 7. Circumcision..... | 57 |
| * Inguino-Scrotal Operations | |
| 1. Undescended Testis..... | 59 |
| 2. Varicoele..... | 60 |
| 3. Hydrocele..... | 62 |
| * Miscellaneous Operations | |
| 1. Tracheostomy..... | 65 |
| 2. Rib Resection..... | 67 |

With my Best Wishes
Dr. Wael Metwaly
 Tel : 7228206
 Mob : 012 2466443



Introduction

الذي يرحون بالدموع يصبون بالابتهاج
 انظروا إلى الأجيال القديمة وتأملوا. هل توكل أحد على الرب فتدري؟
 الذي بدأ معك اول الطريق له يدرك في منتصفه
 هو شافى هو حارف مش ينسى ☺

OPERATIVE SURGERY

Introduction








A Sutures

- | | |
|--|--|
| <p>Absorbable</p> <p>(I) Natural : As chromic Cat gut</p> <p>(II) Synthetic : As Vicryl & Dexon</p> | <p>Non Absorbable</p> <p>(I) Natural : As Silk</p> <p>(II) Synthetic : As Proline & Nylon</p> |
|--|--|

Indications

- | | |
|--|-----------------------------------|
| ① Ligate <u>Vessels</u> . | ① Tendon & Nerve repairs |
| ② Close <u>Fascia & Peritoneum</u> . | ② Hernial repairs . |
| ③ Approximate <u>Muscles</u> . | ③ Closure of <u>Skin</u> (Silk) |

B Stitches

- ① **Simple Interrupted sutures**
e.g. Skin closure 
- ② **Continuous sutures**
e.g. Peritoneum 
- ③ **Interrupted Mattress sutures**
e.g. Myo's repairs of Hernia 
- ④ **Tension sutures**
e.g. First Abdomen 
- ⑤ **Trans-fixation sutures**
e.g. during Hernial repairs 
- ⑥ **Lembert's sutures**
used to invert a continuous sutures 
- ⑦ **Triple string sutures**


C Operative Talk

Items to be discussed

- ★ **Indications** .
- ★ **Contra-indications** .
- ★ **Pre-operative preparation** :
As Thyrotoxicosis or Colon surgery
- ★ **Operative details** :
 - **Anesthesia** : For ☞
 - (a) Operations below umbilicus : **General or spinal Anaesthesia**
 - (b) Operations above umbilicus : **General Anaesthesia**
 - (c) Operations for localized area : **Local Anaesthesia**

N.B. : We use general anesthesia usually with children

- **Position** .
- **Incision** .
- **Steps** : As the following ☞
 - (a) Exposure of the operative field .
 - (b) Dissection & Ligation of Blood vessels .
 - (c) Haemostasis, closure + drain .

N.B. : Drains are removed when discharge from it stops.
It may be removed ☞
- After 2 days in neck operations .
- After 4 days in Abdomen & Breast

- ★ **Post-operative Care**
As pulse, ABP, Temp ... etc .

★ complications :

A Operative complications

- **Shock**, Infection or pulmonary complications .
- **lry Hge** from bleeding vessels .
- **Injuries of important structures** .

B Post-operative complications

- Wound Infection .
- Recurrencey .

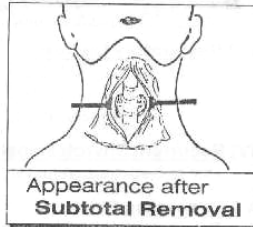
[Thyroidectomy]

5

Leaving only the postero-medial part with baring of the Trachea i.e Isthmus should be excised.

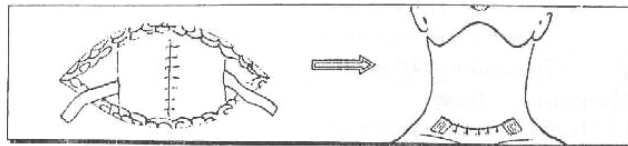
Why ?

- To ① Preserve Para-thyroid gland
- ② Preserve Thyroid function.
- ③ Avoid Injury of R.L.N.



[VI] Closure " In layers "

- ① Infra-hyoid muscles are approximated in the middle line & sutured transversely
- ② A drain is inserted on either side .
- ③ skin & platysma are closed as separated layers .



★ Post operative Care

- [I] Vital signs observation for 1st 24 hours .
- [II] Drains are removed at 2nd day
- [III] Stitches are removed at 4th day .

Complications

A Operative complications

- Shock, Infection & pulmonary complications .
- Iry Hge : from bleeding vessels .
- Injury of Important structures as RLN , Trachea etc....

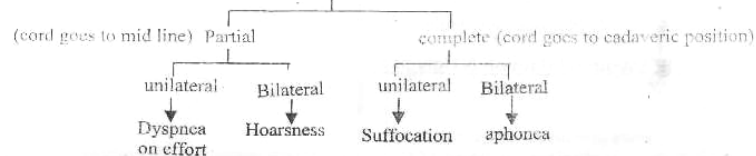
B Post-operative complications

1- Early Complications

- [I] Sore Throat .
- [II] Tracheitis & Laryngitis.
- [III] Difficulty in swallowing & pain in back of neck.

2- Late Complications

[I] Recurrent Laryngeal Nerve Injury :



[Thyroidectomy]

6

[II] External Laryngeal Nerve Injury :

Loss of High pitched voice

[III] Respiratory Distress :

- Due to ① Bilateral R.L.N injuries
- ② Reactionary Hge & Laryngeal oedema .
- ③ Tracheomalacia .

[IV] Recurrent Thyrotoxicosis :

Due to Inadequate removal .

[V] Myxoedma :

Due to excess gland is removed.

[VI] Hypoparathyroidism :

- Causes : ① Removal of all parathyroid gland .
- ② Interrupt their Blood supply .
- ③ Fibrosis around the gland .

▪ Manifestation : [Tetany]

- ★ Manifest → Carpo-pedal spasm .
- ★ Latent → Chervestie's sign & Trousseau's sign

▪ Treatment : Slow I.V Ca Gluconate 10 cc 10%

[VII] Reactionary Haemorrhage : within 24 hour .

- Cause : Slipped ligature as Bad Haemostasis .
- Manifestation : Suffocation
- Treatment : [Urgent Treatment]

Through opening the wound even in bed then transfere the patient to operative theater. The wound will explored & the bleeding points are secured .

[VIII] Post-operative Thyroid crisis (storm)

- Cause : Acute Hyper-thyroidism because of bad pre-operative preparation for toxicity .

▪ Manifestations :

- ★ symptoms → muscular Excitability up to convulsion & Dyspnea .
- ★ signs → Temp : ↑ up to 41°C
- pulse : ↑ up to 160/min & Irregular .
- A.B.P : ↑ (Systole & Diastole) → heart failure

▪ Treatment : [Urgent Treatment]

- ① Ice Packs to limb, head & Abdomen → ↓ pyrexia
- ② O₂ Inhalation & A.B for chest Infection
- ③ Morphia for sedation & Inderal for Toxicity

[IX] Wound Infection & Ugly scar .

Operation 2

7

RADICAL MASTECTOMY (HALSTED)

★ Indications

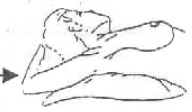Operable cases of cancer breast (stage I & II)
 * Stage I : Mobile Breast Mass + No Metastasis .
 * Stage II : Mobile Breast Mass + Mobile L.Ns + No Metastasis.

★ Anesthesia

"General" (Endotracheal) Anaesthesia .

★ Position

"Supine" with head Tilted to the opposite side & the arm on the same side is abducted 90°



★ Incision

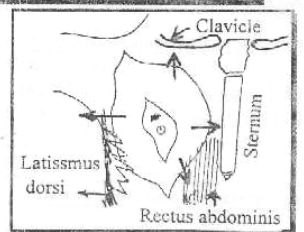
Elleptical Incision including the Nipple & Areola

| | |
|--|---|
| <p>(A) Halsted Incision</p> | <p>(B) Transverse Incision</p> |
| <p>* Used only with Any mass below or above the Nipple</p> | <p>* Used only for central located mass</p> |

★ Steps

[I] Mobilization of skin Flaps :

They are dissected as following
 [A] Superiorly : To the clavicle .
 [B] Inferiorly : To the Rectus sheath .
 [C] Medially : To the sternum .
 [D] Laterally : To the Anterior border of Latissimus dorsi .



[II] Exposure of Axilla :

The Axilla is opened by dividing the pectoralis major at it's insertion Then the clavi-pectoral fascia is dissected & pectoralis minor is divided at it's insertion. Finally Both muscles are retracted with breast mass.

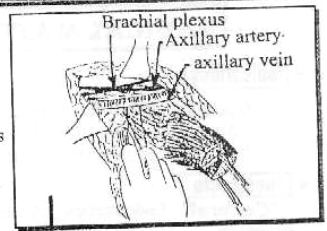
| | |
|--------------------------------------|--|
| <p>Dividing the pectoralis major</p> | <p>Dividing the pectoralis minor (The pectoralis major is retracted)</p> |
|--------------------------------------|--|

8

[Radical Mastectomy]

[III] Structures to be removed : 4

- ① Whole breast tissue .
- ② Ellipse including nipple & Areola .
- ③ Pectoralis major & minor which including interpectoral group of L.Ns i.e L.Ns of Roter.
- ④ All Fat , Fascia & L.Ns in the Axilla .

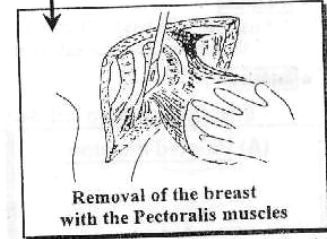


[IV] Structures to be preserved : 4

- ① Axillary vessels & Nerves .
- ② Cephalic vein .
- ③ Nerve to latissimus dorsi
- ④ Nerve to Serratus Anterior

[V] Structures to be sacrificed : 3

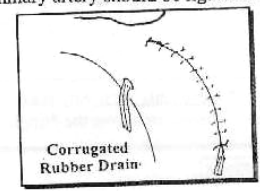
- ① Medial pectoral nerve .
- ② Lateral pectoral nerve .
- ③ Inter-costobrachial nerve .



N.B : During Dissection
 The 2nd, 3rd & 4th perforators of internal mammary artery should be ligated and divided.

[VI] Ensure Haemostasis & Closure.

Close with 2 drains one in the Axilla the other in the lower part of the wound .



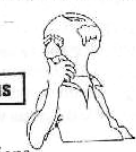★ Post-operative Care

[I] Post-operative Irradiation :

To Supra-clavicular L.Ns & Internal mammary L.Ns if stage II only .

[II] Drains are removed at 4th day.

[III] Stitches are removed at 7th day.



Complications

A) Operative complications

- Shock , Infection & pulmonary complications .
- Irv Hge : from bleeding vessels .
- Injury of important structures as Axillary vessels, cephalic vein, Brachial plexus, Nerve to latissimus dorsi or nerve to serratus anterior → winging of scapula

B) Post-operative complications

- [I] Haematoma or wound infection .
- [II] Oedema of upper limb .
 - Early pitting due to infection .
 - Late brawny due to removal of excess lymphatics.
- [III] Bridle scar : if the incision crosses the axilla → limitation of abduction of upper limb .

[Radical Mastectomy]

9

N.B. ①

1 (QUART) or (TART) operation :

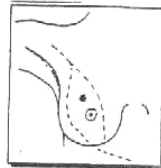
- [A] (QUART) Quadrentectomy + Axillary L.Ns. removal + Radiotherapy.
- [B] (TART) Tumorectomy + Axillary L.Ns. removal + Radiotherapy

N.B. Irradiation to Mediastinum & Supraclavicular regions

- It is suitable for :
- ① Small masses < 4 cm
 - ② Big Breast
 - ③ Well Differentiated tumour
 - ④ Young Female

2 Radical Mastectomy of (Halsted) :

- Removal of
 - ① Elliptical part of skin with nipple & Areola
 - ② Whole Breast Tumor
 - ③ 2 Pectoralis muscles.
 - ④ All Axillary L.Ns & fat Medial to Axillary vein
- Preservation of
 - ① Axillary vessels
 - ② N. to Serratus Anterior
 - ③ Cephalic vein
 - ④ N. to Latissimus Dorsi.



3 Modified Radical Mastectomy of (Patey) (Most Widely Accepted)

- Same as Halsted but preservation of both pectoralis muscles, By (Cutting only at their insertions for better Cosmosis)

4 Extended Radical Mastectomy (Not done Nowadays).

- Radical Mastectomy + Removal of Internal Mammary L.Ns., through sternotomy.

N.B. ②

Simple Mastectomy

☆ Indications :

- ① Stage III & IV cancer breast.
- ② Mastitis carcinomatosa.
- ③ Cysto-sarcoma phylloids.

☆ Technique :

- An Elliptical incision is used
- Removal of Breast, Nipple, Areola
- Removal of mass

N.B. : Preserving the pectoral muscles & Fascia.



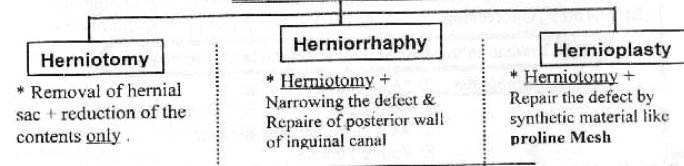
Operation 3

10

HERNIAL OPERATIONS

I Operations for Inguinal Hernias

1. Indirect (oblique) Inguinal Hernia



2. Direct Inguinal Hernia

- The Above mentioned 3 Types of Hernial operations are suitable for " Indirect Inguinal Hernia " only.
- But Direct Inguinal Hernia : Herniorrhaphy or Hernioplasty is done i.e no Herniotomy is done alone

A Herniotomy

★ Indications

Indicated with infants & children below 12 years. Why ? Because the Deep ring is + good musculature for. Inguinal canal.

★ Anesthesia " General or Spinal"

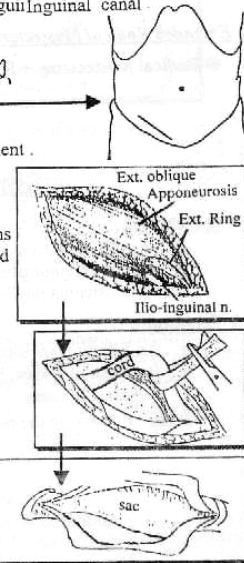
★ Position " Supine"

★ Incision

Inguinal incision : 1 finger above & parallel to medial 2/3 of Inguinal ligament .

★ Steps

- [I] The External oblique Apponeurosis is incised in line of it's fibers , So That it opens the external ring so the inguinal canal is opened
- [II] The Ilio-inguinal nerve is protected Why ? To avoid paralysis of conjoint Tendon so prevent Direct Hernia .
- [III] The spermatic cord in which the hernial sac lies is hooked by ring forceps .
- [IV] The spermatic cord coverings are incised longitudinally and the hernial sac is Identified by being
 - ① Pearly in shape
 - ② white in colour .
 - ③ Antro-lateral to their cord structures .

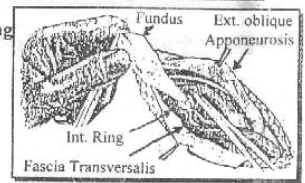


[Hernial operation]

11

Then - The neck of the sac is identified by being

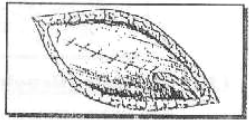
- ① The narrowest part of the sac .
- ② surrounded by Extra-peritoneal Fat .
- ③ Lateral to inferior Epigastric vessels .



[V] The sac is opened and the contents are reduced

[VI] The Neck of Hernial sac : Transfixed & ligated as high as possible then Excised .

[VII] The Cord coverings : Resutured again **then** the wound is closed in layers .



N.B: No drains are used

B) Herniorrhaphy

* **Indications**

Indicated with large Hernial defect in adult or Elderly with good musculature

* **Anesthesia** + **position** + **Incision** → same as Herniotomy

* **Steps**

(A) Herniotomy : As Above

(B) 2 steps 1- Narrowing of stretched Internal ring to the size of tip of little finger .
By plication of the Fascia Transversalis (*Lytle's Repaire*)
2- Reinforcement of posterior wall of Inguinal canal
By One of the followings

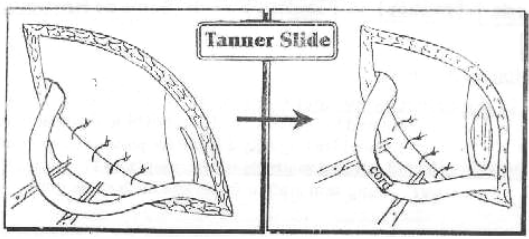
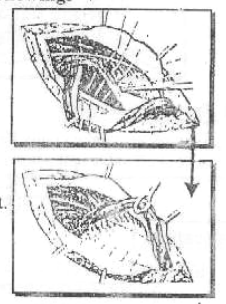
[I] **Bassini Repair** :

- Suture the conjoint Tendon down to the inguinal ligament behind the cord .

Q: **Why Bassini repair is unphysiological ?**

Because ① Interferes with shutter mechanism of inguinal canal during ↑ I.A.P
② Healing is very weak between fleshy muscle & Tendinous ligament.

Q: **What is meant by " Tanner slide "**?
If there is tension in the repair , we do " Tanner slide " = Relaxing incision in the Rectus Sheath to prevent this Tension .

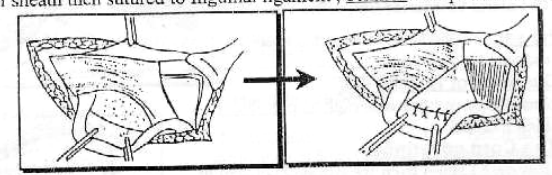


[Hernial operation]

12


[II] **Blood-good Repair** (Uses of Rectus sheath)

A triangle of Anterior Rectus sheath is turned laterally & hinged on lateral border of sheath then sutured to Inguinal ligament , behind the spermatic cord.



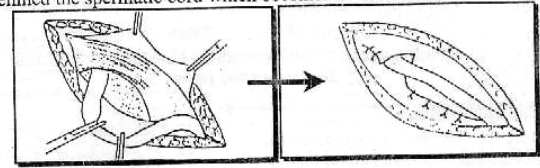
[III] **Shouldice Repair**

The Fascia Transversalis is divided longitudinally along the posterior border of the canal. Then **Double Breasting** is done i.e the lower flap is sutured to the under surface of upper flap.



[IV] **Halsted Repair** (Anterior Transposition of the cord)

suturing the External oblique Aponeurosis to the inguinal ligament behind the spermatic cord which becomes subcutaneous .



[V] **Mc vey's Repair**

Brings the Transversalis Fascia further posteriorly & inferiorly to pectineal ligament. It is effective in the repair of inguinal hernia associated with femoral Hernia.

C) Hernioplasty

* **Indications**

Indicated with old patient (weak musculature + wide defect) or with recurrent Hernias

* **Anesthesia** + **Position** + **Incision** → Same as Herniotomy

* **Steps**

(A) **Herniotomy** : As Above

(B) **Repair of the defect by synthetic material** As proline meshes which is sutured to conjoint Tendon (above) & Inguinal ligament (below) leaving only a space for passage of spermatic cord.

Q: **What are the old natural methods for hernioplasty ?**

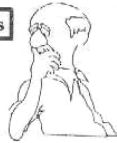Answer : using skin graft or fascia lata i.e. Natural graft.

[Hernial operation]

13

Complications

- [I] **Haemorrhage** : from bleeding vessels .
- [II] **Infected wound** .
- [III] **Injury of important structures** as :-



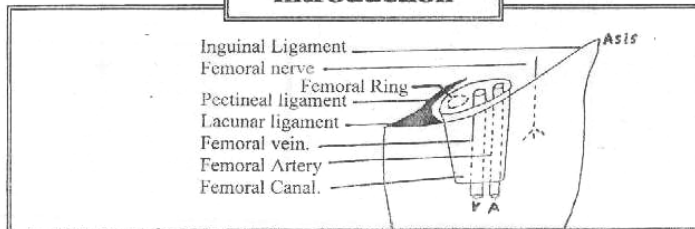
- ① Vasc Deferens → Impaired fertility .
- ② Tercular artery → Ischemic orchitis .
- ③ Ilio-inguinal nerve → Anesthesia over Inguinal region & Paralysis of conjoint tendon i.e direct hernia .
- ④ 2ry Hydrocele → From Tight Ext. or Int. Rings
- ⑤ 2ry Varicocele → From Tight Ext. or Int. Rings

[IV] **Recurrency:**

- **Preoperative Causes:** Obesity, D.M, Anaemia & poor health .
- **Operative Causes:**
 - ① Tight stitches → devitalized tissue .
 - ② uses of absorbable sutures .
 - ③ Insertion of a drain through the wound .
- **Post-operative Causes:**
 - ① Persistent pre-operative causes .
 - ② Infected wound .
 - ③ Lifting heavy object before 3 months of operation .

II Operations for Femoral Hernia

Introduction



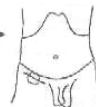A Low Approach (Lockwood)

★ **Anesthesia** "General or Spinal"

★ **Position** "Supine"

★ **Incision**

In upper part of the Thigh 1 Finger below & parallel to the Inguinal ligament .

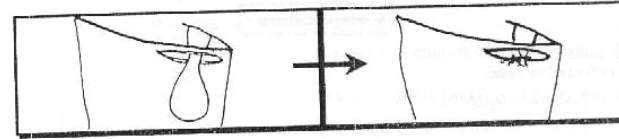


★ **Steps**

- ① **The sac is Identified** & dissected till it's neck .
- ② **The sac is opened** . The contents are reduced & Transfixed as higher as possible and excised .
- ③ **Repair** : Femoral ring is closed by suturing the Inguinal ligament to the pectineal ligament.

[Hernial operation]

14



★ **Disadvantages** : So Not used Nowadays .

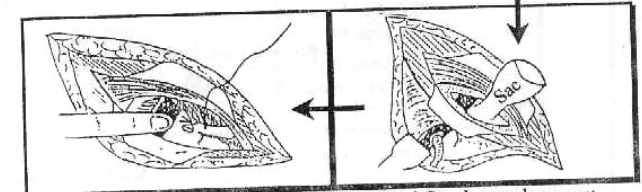
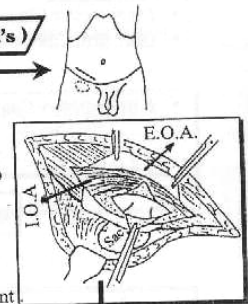
- ① Neck of sac Can not be reached properly .
- ② High rate of recurrency .
- ③ If strangulated with gangrenous Intestine , resection can not be done from this narrow field in upper thigh .

B Inguinal approach (Lotheissen's)

★ **Incision** Same as for Inguinal operations .

★ **Steps**

- ① **The Inguinal Canal is opened** then the lower skin flap is dissected down to expose the fundus of the sac which is pushed up from below to help the delivery of sac above inguinal ligament .
- ② **The sac is opened** . The contents are reduced Then the sac is transfixed & excised .
- ③ **Repair** : Suturing the conjoint tendon to the inguinal ligament then to the pectineal ligament

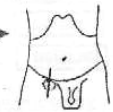


★ **Disadvantages** : Distribute shutter mechanism of Inguinal Canal & weakens post. wall of the Canal.

C High approach (Mc EVEDY)

★ **Incision**

Verticle incision above the Hernia and continued above Inguinal ligament .



★ **Steps**

- ① **The Anterior rectus sheath** is opened, the muscle is retracted medially then the posterior rectus sheath is opened & Exposing the peritoneum .
- ② **The Hernial sac is Identified and opened** . Then the contents are reduced & Transfixed as higher as possible and excised .
- ③ **Repair** : see **Mc Vay's** Repair .

III Operations for Para-umbilical Hernia (P. U. H.)

A Mayo's Repair

★ **Indication** Small defect

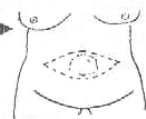
★ **Anesthesia** "General"

★ **Position** "Supine"

★ **Incision**



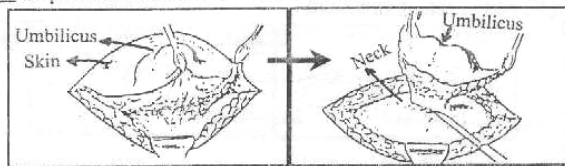
Transverse Elliptical incision is done over the Hernia & Enclosing The umbilicus



★ **Steps**

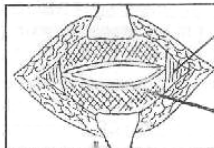
[I] **The incision** is deepened till the anterior rectus sheath is reached all around the sac.

[II] **The sac** is opened at it's neck & the contents are reduced.



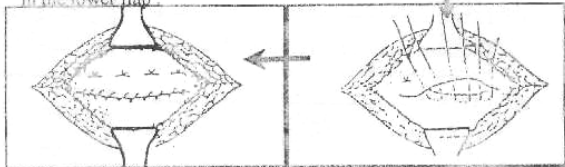
[III] **The sac is excised with overlying skin** and the defect in the linea Alba is widened on both sides till the red fibers of recti muscles appear.

[IV] **Finally** the upper flap of linea alba is sutured over the lower flap by interrupted transverse mattress sutures



Rectus
Linea alba

[V] **The free edge** of upper flap is sutured in the lower flap.



[VI] **The wound is closed** over a subcutaneous drain.

B Hernioplasty

Indicated with Large defect & Recurrent Hernias.

IV Operations for Epigastric Hernia

Fatty Hernia of linea Alba

★ **Small Hernia** : Excision of the fat lobule then repair the defect.

★ **Large Hernia** : Mayo's operation as for P.U.H. operations.

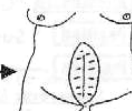
V Operations for Incisional Hernia

★ **pre-operative preparation** As weight reduction & treatment of any causes leading to ↑ I.A.P.

★ **Anesthesia** "General"

★ **Position** "Supine"

★ **Incision** Elliptical incision including the scar.



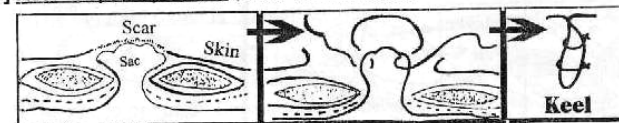★ **Steps**

Dissection is done till the edge of defect at the abdominal wall
Then ONE OF THE FOLLOWING WILL BE DONE :-

[I] **Anatomical Repair** (If the defect is small).

The sac is excised & the Abdominal layers are defined & closed separately

[II] **Keel repair operation** (If the defect is wide).



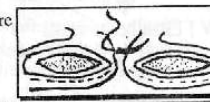
The sac is identified & dissected down to the neck, without opening the sac, it is invaginated in the Abdomen by a series of investing sutures. The edges of the defect are closed. So as, the repair if viewed in cross section. Look like the keel of the Boat.

[III] **Catell's Repair (5 layers)**

The sac is dissected & opened. The contents are returned to Abdomen. Then Closed by the followings.

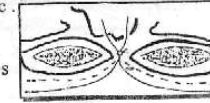
① **1ST LAYER** :

The neck of the sac is closed from inside the sac



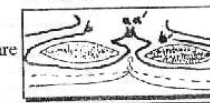
② **2ND LAYER** :

The sac is excised 2 cm distal to 1st layer & it's edges are sutured as 2 layer.



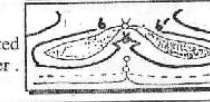
③ **3RD LAYER** :

The 2 medial flaps of posterior rectus sheath are Sutured as 3rd layer.



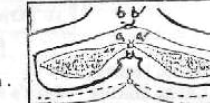④ **4TH LAYER** :

The Recti muscles on either sides are approximated & sutured in the middle line as 4th layer.



⑤ **5TH LAYER** :

The 2 lateral flaps of anterior rectus sheath are sutured in front of muscles in middle line as 5th layer. Finally : skin is closed over a drain.



[IV] **Hernioplasty** :

The Best Repair by using proline mesh.

Strangulation

* **Treatment** : [Emergency operation after Resuscitation]

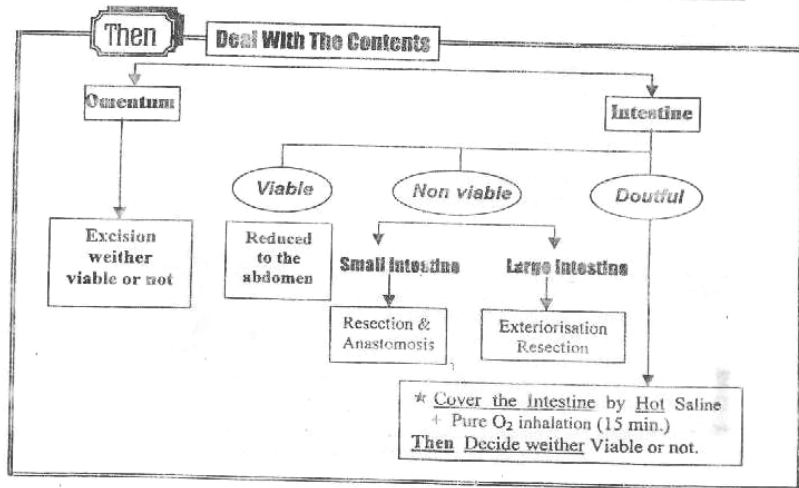
(A) Immediate Resuscitation

- ① Hospitalization.
- ② **Ryle's Tube** for suction.
- ③ **Urinary Catheter** is applied.
- ④ I.V **Fluids** To correct electrolyte imbalance
- ⑤ I.V **Blood & Ringer's Lactate** to correct Hypovolaemia.
- ⑥ I.V. **Broad spectrum A.B.** to guard against Septic Shock.

(B) Immediate Operation

- ① **Incision** should be planned to **Expose** the fundus of sac and Open it to **Evacuate Toxic fluid** 1st.
- ② **The constricting agents** should be divided over the fingers to **avoid injury** of intestine.
- ③ **The contents** are pulled out & Examined, viable or not

| | Viable Intestine | Non-viable Intestine |
|-----------------------|--------------------|------------------------|
| • Intestinal Color | • Pink or Dark red | • Brown or Black. |
| • Peritoneal Lustres | • Present. | • Absent. |
| • Mesenteric Arteries | • Pulsating | • Non-pulsating |
| • By Pinching | • Contracts | • No Response |
| • Consistency | • Firm | • Floppy |
| • If Injured | • Bleeding occur | • No Bleeding |



Operation 4

SYMPATHECTOMY

* **Indications**

[A] To improve circulation in an ischemic limb .

- ① **Arteritis** e.g Burger's Disease .
- ② **Vasospastic disorders** e.g Raynaud's disease .
- ③ with **Amputation** to improve wound healing .

[B] Treatment of **Hyperhidrosis** of hand or foot .

[C] To relieve pain as in Causalgia, Sudek's atrophy or Visceral pain

* **Contraindications**

[A] **Intermittent claudication** (i.e worsen the muscle Ischaemia) .

[B] **Massive gangrene** (i.e Ineffective & needs amputation)

[C] **Diabetic patient** (i.e Auto-sympathectomy) .

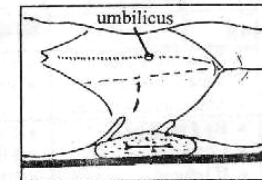
I LUMBAR SYMPATHECTOMY

* **Anesthesia** "General"

* **Position** "Supine" with the side of operation raised by 30° by sandbag

* **Incision**

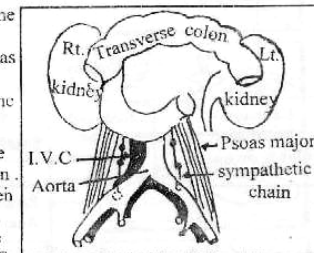
Transverse incision from the tip of last rib to the lateral border of rectus in direction of the umbilicus .



* **Steps**

① **The muscles are divided** in the line of the incision & the peritoneum is stripped inwards to expose the medial border of psoas major muscle i.e Extra-peritoneal.

② **The sympathetic chain** lies in the groove between the vertebral bodies & medial border of psoas major muscle, overlapped by Aorta on Lt. Side & I.V.C on the Rt. Side .



1st **Lumbar ganglion** lies beneath the Crus of the diaphragm so not seen .

2nd **Lumbar ganglion** the highest seen below the lower pole of kidney .

3rd **Lumbar ganglion** lies Just above the lower end of the Aorta or I.V.C.

4th **Lumbar ganglion** lies beneath the common iliac vessels .

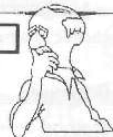③ **Finally** the sympathetic chain is divided below 3rd ganglion & above 2nd ganglion. So we remove the 2nd and 3rd ganglion.

- N.B**
- ① **Don't Mistake** Lymphatics, Genito-femoral nerve or the Tendinous strips of psoas minor from the sympathetics chain.
 - ② **For Complete denervation of L.L** : The 1st ganglion can be excised. **But In** bilateral operation, one side must be preserved to avoid Failure of ejaculation .
 - ③ **Any sympathectomy** to be effective it should be pre-ganglionic as post - ganglionic sympathectomy Causes denervation Hypersensitivity. i.e Hypersensitivity of the vascular media to chemical mediator such as **Noradrenaline** after cutting their direct nerves → **Episodic vasospasm** .

Complications

A Operative complications

- Shock, Infection & pulmonary Complications .
- **Irry Hge** From bleeding vessels .
- Injury of important structures as Lumber veins etc .



B Post-operative complications

- Incomplete sympathectomy .
- Failure of ejaculation [If bilateral removal of L₁]
- Denervation Hypersensitivity .

II CERVICAL SYMPATHECTOMY

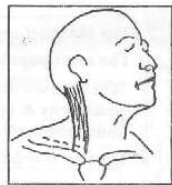* **Anesthesia** "General"

* **Position** Head is extended & Tilted to opposite side .

* **Incision** Supra-clavicular over it's medial 2/3 .

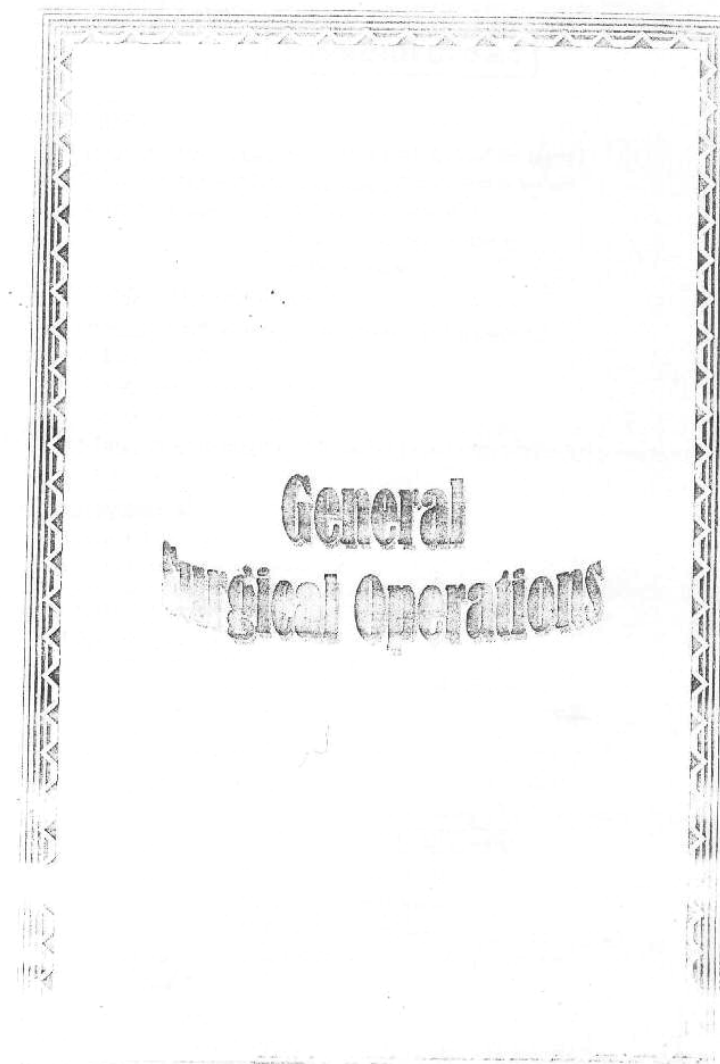
* **Steps**

- ① **Dividing** the clavicular head of sternomastoid, Inferior. belly of omohyoid & scalenus anterior .
- ② **The subclavian artery** is exposed, The Thyrocervical Trunk is divided & the artery is depressed down .
- ③ **The supra-pleural Fascia (Sibson's Fascia)** is divided & The dome of pleura is depressed down .
- ④ **The stellate ganglion** (Fused Inferior Cervical & 1st. thoracic ganglion) is Found at neck of 1st. rib .
- ⑤ **The Chain is divided** below the 3rd Thoracic ganglion and all rami of the 2nd & 3rd ganglia are divided .
- ⑥ **The nerve of Kuntz** is also divided



N.B: The Complications of Cervical sympathectomy ↻

- ① Incomplete sympathectomy.
- ② Horner's syndrome .
- ③ Injury of pleura or thoracic duct



Operation 1

THYROIDECTOMY

★ **Indications**

[I] **Subtotal Thyroidectomy** : " Removal of 7/8 of the gland "

- ① Main treatment of **2ry Toxic goitre** after control of toxicity .
- ② **1ry Toxic goitre** with
 - a. Failure of medical ttt .
 - b. Recurrent after medical ttt .
 - c. Huge in size .
- ③ **SNG** i.e Multi-nodular goitre

[II] **Hemi-thyroidectomy** : " Lobectomy + Isthmusectomy "

- ① **Toxic Nodule**
- ② **Adenoma** of thyroid gland .
- ③ **SNG** i.e Single nodular goitre

[III] **Total Thyroidectomy** : " **Bilateral Total Lobectomy + Isthmusectomy** "

Malignant goiter

★ **Contraindications**

[A] **General causes** :

Bad general condition like ↻
Chest infection , Heart Failure , Recent myocardial Inflection . Recent cerebral stroke , uncontrolled D.M ... etc .

[B] **Specific causes** :

- ① During 1st. Trimester of pregnancy
- ② Children & Adolescents < 25 years to avoid recurrency .
- ③ Progressive Exophthalmos .

★ **Pre-operative preparation of thyrotoxic patients.**

[A] **Long Term preparation** :

Neomercazole till reach the euthyroid state (for 2-3 months)

(Then) Lugol's Iodine (5% Iodine + 10% KI in water) ↻

- **Action** : ① ↓ Protease enz. which release I₂ & T₄
- ② ↓ Organic Iodine formation .
- ③ ↓ Effect of TSH on gland .

• **Dose** : 5-15 drops T.D.S for 14 days before operation .

[E] **Short Term preparation** :

Indral 40 mg (4 Times / day)

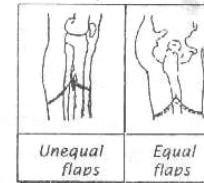
for 10 days preoperative & continued for 1 week after the operation to prevent Thyrotoxic crisis

[Amputation]

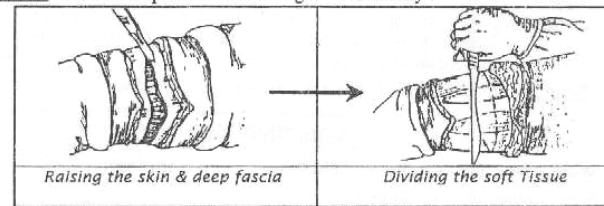
② **Fashioning of flaps** : 2 Types ↻

a. **Unequal flaps** : long post flap (Better vascular) as in B.K.A.

b. **Equal flaps** : Equal (Ant. & post. flaps) as in A.K.A as following ↻



- **Length** : Equal 1/2 diameter .
- **Shape** : Semi-circular to avoid dog ears .
- **Thickness** : Skin & deep fascia to ensure good vascularity .



③ **Muscles** : Cut midway between skin incision & The Level of bone section .

④ **Vessels** : Light at their Anatomical position .

⑤ **Nerves** : Cut with sharp scalpel to avoid neuroma formation .

⑥ **Periosteum** : Raised for 1/2 inch above the level of bone section to avoid spur formation .

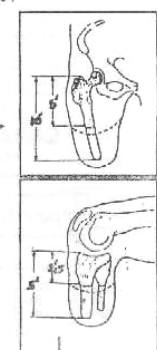
⑦ **Bone** : Sectioned at site of election .

▪ **A.K.A** : Minimum length = 5 inches below the tip of greater Trochanter .
Maximum length = 10 inches below the tip of greater Trochanter .

▪ **B.K.A** : Minimum length = 2.5 inches below the Joint Line .
Maximum length = 5 inches below the Joint Line .

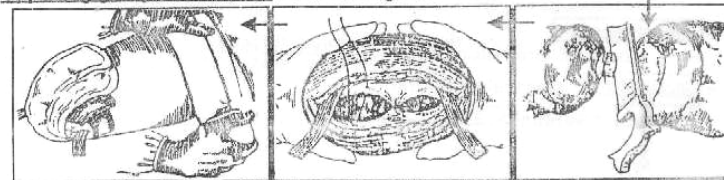
N.B : ① The muscles should be protected with a Wet gauze from bone dust just to avoid Myositis ossificans .

N.B : ② In B.K.A: The Fibula should be divided 1st at a higher level than Tibia to obtain a conical stump .



⑧ **Haemostasis** is ensured after release of Tourniquet .

⑨ **Opposing groups of muscles** are sutured together .



Pressure Bandage

Closure of deep fascia

Bone section

[Amputation & surgery for varicose vein]

- ⑥ **Closure** : Close the deep fascia & skin over a drain .
- ⑦ **Bandage** : To compress the stump & to obtain conical shaped stump .
- ⑧ **Physiotherapy** : to Keep muscle's tone .
- * **Artificial Limb** : After 3-6 months when the final shape of the stump is obtained .

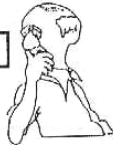★ **Criteria of Ideal Amputated stump**

- ① **Length** : The length of a stump is an advantage because the short stump is liable to slip out of the prosthesis .
- ② **Shape** : Stump should be smooth, Rounded & conical .
- ③ **Coverings** : Bone end should be covered with deep fascia & skin only So the muscles are better not sutured over the bone end to avoid an adherent painful scar .
- ④ **Scar** Not adherent & Healed by 1ry intention .



Complications

- ① **Wound Infection** → Adherent painful scar .
- ② **Skin** : Sloughing, Callosities or Ulceration .
- ③ **Muscle** : Atrophy or Myositis ossificans .
- ④ **Bone** : Spurs formation & osteomyelitis .
- ⑤ **Nerves** : Neuroma formation .
- ⑥ **Vessels** : Heamatoma → 2ry infection → delayed healing .
- ⑦ **Phantom Limb** : Patient feels that the amputated Limb is still present .
- ⑧ **Causalgia** : sever burning pain in the distal end of the stump ± treated by sympathectomy



Operation 6

SURGERY FOR VARICOSE VEINS

★ **Indications**

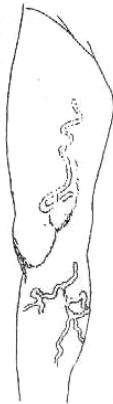- (1ry V.V or 2ry V.V. provided that deep system is patent).
- If ① Associated Saphena varix with 1ry V.V.
- ② Presence of Incomptent perforators i.e Blow out .
- ③ Complications as Hige or Ulcer .
- ④ Large Varicosities
- ⑤ Cosmetic disfigurement .

★ **Contraindication**

If occluded deep system , pregnancy or Thrombophlebitis

★ **Anesthesia** " General or Spinal"

★ **Position** " Supine"



[Surgery for varicose vein]

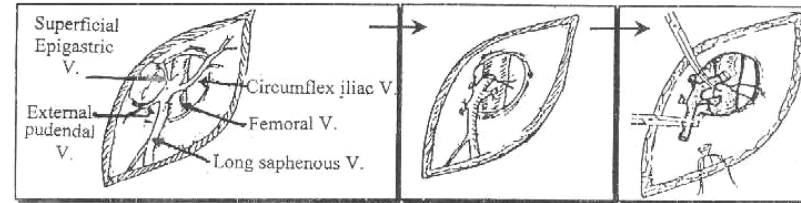
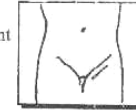★ **Types of Operations**

[A] **Trendelenberg's Operation** (Sapheno-femoral ligation) :

▪ **Indicated** with sapheno-femoral incompetence i.e Saphena varix .

▪ **Steps** :

- ① **Transverse incision** below & parallel to the inguinal ligament
- ② **The upper end of long saphenous** is exposed Then the 3 Tributaries are ligated & divided .
- ③ **The long saphenous vein** is ligated & divided from femoral vein .

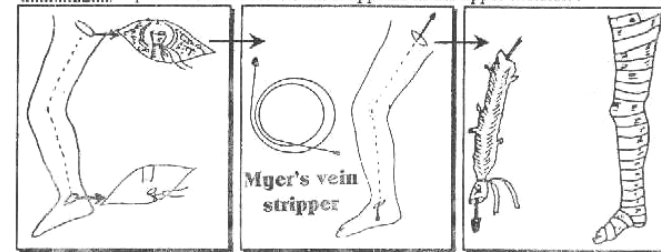


[B] **Subcutaneous stripping of long saphenous :**

▪ **Indicated** if the whole system is severely affected .

▪ **Steps** :

- ① **Trendelenberg's operation** is done as before .
- ② **The lower end of long saphenous vein** is exposed by a small transverse incision in front of medial malleolus. The vein is divided & it's distal end is ligated .
- ③ **A Stripper** is pushed from below until it appears in the upper incision .



- ④ **The lower end of the vein** is ligated around the stripper **then** the stripper is pulled from it's upper end stripping the long saphenous .
- ⑤ **To avoid bleeding** from avulsed tributaries during stripping the Leg should be raised up & pressure bandage is applied .

★ **Post-operative Care**

Elastic stoking is used for 2 week with early amputation to avoid D.V.T.

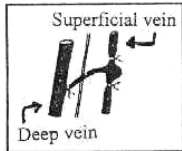
[Surgery for varicose vein & venous cut down operation]

Complicated by :

- ① Bleeding or S.C Haematoma .
- ② Injuries of saphenous nerve
- ③ Residual Varicosities after operation .

[C] Sub-fascial Ligation of incompetent perforators [Cockett & Dodd]

- indicated with : Incompetent perforators if 2 or 3 in numbers usually performed on Ankle perforators .
- Method : By passing from muscles to penetrate deep fascia through postro-medial incision behind the tibia .
- Complicated by ugly scar & high rate of recurrency .



Operation 7

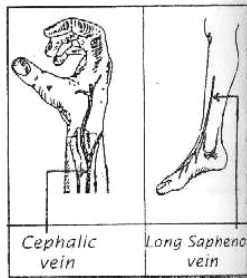
VENOUS CUT DOWN OPERATION

Indications

- ① Shocked patient as the veins are collapsed & Burn
- ② Patients on long term parenteral nutrition .

Selection of Vein

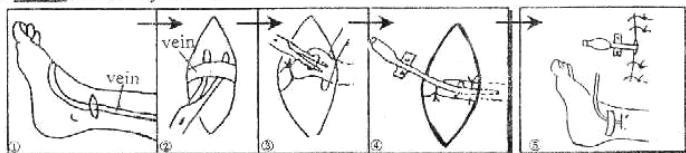
- ① The cephalic vein : 1.5 inches above the Radial styloid process or at the lateral aspect of the elbow . It is better to use it than the long saphenous vein as the latter is liable to Thrombophlebitis .
- ② The long saphenous vein : 1.5 inches above the ant. border of medial malleolus .



Anesthesia "Local"

Steps

- ① Transverse incision over the vein .
- ② The entire circumference of the vein is exposed 1 cm length
- ③ 2 Ligatures are passed proximal and distal (The distal one is ligated only) .
- ④ A small incision s made in the proximal end of the vein end a Catheter is pushed inside it & the proximal ligature is tightened over it .
- ⑤ Close the skin by stitches .



Complications

- ① Thrombophlebitis with long saphenous
- ② Pain due to including the saphenous nerve in ligature around the vein .
- ③ Wound infection or obstruction of canula .



Operation 8

INGROWING TOE NAIL

Introduction

- Definition : Nail side curls inward causing injury and infection of nail fold .
- Causes : It may result from tight shoes or cutting nail short convexily .
- Clinical Picture :
 - Mainly affect the big Toe .
 - Patient represents by painful red Swollen nail fold which may show infected granulation Tissues .

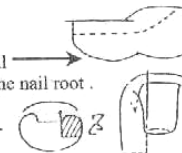


Anesthesia

"Spinal or Local" but without Adrenaline

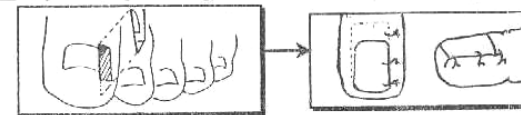
Incision

- ① Longitudinal one via the affect side of the nail deep to the bone & extended proximally to the nail root .
- ② Another one is made through the skin by the side of lesion down to the phalanx .



Steps

- ① Excise a wedge of Tissue between the 2 incisions .
- ② The gap may be left open to be granulated or closed by 2-3 interrupted sutures .



Operation 9

MANAGEMENT OF SEBACEOUS CYST

Indications

- It should be removed because
 - ① It cause boldness of overlying skin .
 - ② Infection → Abscess Formation .
 - ③ Ulceration → Cock's peculiar Tumor [Scalp]

Anesthesia

Local(Xylocain 2%) with Adrenaline .

Steps

- [A] If infected : Incision & drainage .
- [B] If not infected : Excision as following
 - ① Shaving of hair 1 or 2 inches around & washing by Betadine .
 - ② Elliptical incision over the cyst including punctum .
 - ③ The cyst & The skin are removed .

Complications

Wound infection or Recurrency

Operation 10

MANAGEMENT OF ABSCESS

General Rules

★ **Position of patient**

According to dependency of Abscess .

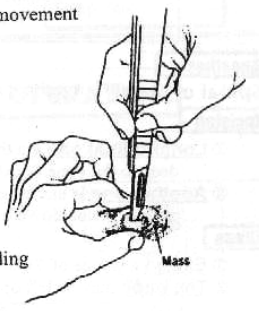
★ **Anesthesia**

General especially with Breast abscess , parotid abscess , palm abscess & peri-anal abscess .

To avoid destruction of vital structures with sudden movement of patient under local anesthesia .

★ **Incision** must be ↗

- ① Most dependent site .
- ② Adequate length .
- ③ Parellel to major Vessels & Nerves .
- ④ Along skin creases if possible .
- ⑤ Completely exposed .
- ⑥ **Packed by Gauze pack** for 24 hour to control bleeding



Don't forget special sites for incision

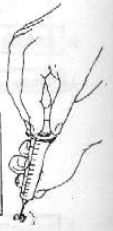- ① **Forehead & Face** : Along skin crease .
- ② **The Neck** : Transverse or Parellel to skin crease .
- ③ **Breast** : Radial or Along the Mammary Fold .
- ④ **Axilla** : Vertical So it gaps when the arm is adducted .
- ⑤ **Cubital or Popliteal Fossa** : Transverse incision within the skin crease .
- ⑥ **Gluteal Region** : Downwards, Forwards & Laterally i.e Along the Fibers of glutius Maximus muscle .

★ **Drainage**

Don't wait for Fluctuation

- Especially with
- ① **Breast** Abscess : To avoid lactiferous duct destruction .
 - ② **Parotid** Abscess : To avoid Facial nerve destruction .
 - ③ **Palm** Abscess : To avoid fine nerves destruction .
 - ④ **Peri-anal** Abscess : To avoid Ano-rectal fistula .

N.B: Any Abscess must be drained
 Except **A** = Amoebic Liver Abscess
B = Brain Abscess → Must be Aspirated
C = Cold Abscess of T.B



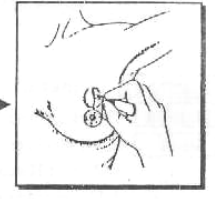
[Management of Abscesses]

[1] BREAST ABSCESS

★ **Position** "Supine"

★ **Anesthesia** "General"

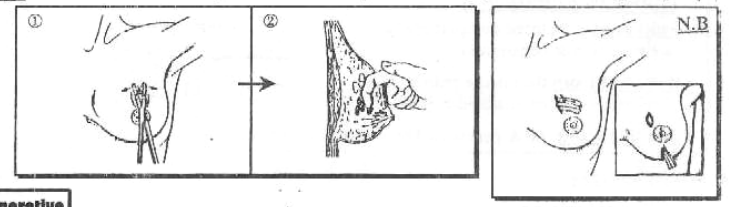
★ **Incision** Radial incision over the most fluctuation part



★ **Steps**

- ① **Introduce artery forceps** to wider the opening to allow the pus to escape .
- ② **Introduce a finger** into the cavity to break down all loculi converting the lesion into a single & large Cavity .

N.B: counter- incision may be needed for dependant draining (If Abscess at upper part)



★ **Post-operative**

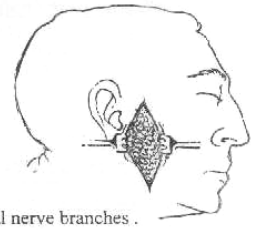
Analgesics, Antibiotics & Dressing every day .

[2] PAROTID ABSCESS

★ **Position** "Supine"

★ **Anesthesia** "General"

★ **Incision** Hilton's Method ↗



★ **Steps**

- ① A **vertical skin incision** in front of ear is done .
- ② **The deep fascia** is incised transversely to avoid injury of facial nerve branches .
- ③ A **sinus Forceps** is then introduced closed and then opened to drain the pus .

★ **Post-operative**

Analgesics, Antibiotics & Dressing every day .

★ **Complications**

- ① Facial paralysis .
- ② Parotid Fistula .
- ③ **Fray's syndrome** : Hyperaesthesia, flushing & sweating in the pre-auricular area during meal. It is due to partial injury of the auriculo-temporal nerve .

[3] MANAGEMENT OF HAND INFECTION

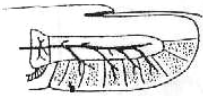
General Rules

- ★ **Anesthesia** "General"
- ★ **Incision** Never Crosses the skin crease .
- ★ **Steps**
 - ① All pus is evacuated & the cavity is curatted .
 - ② Perfect Haemostasis .
 - ③ Under cover of strong Antibiotics .

A PULP SPACE INFECTION


SURGICAL ANATOMY

- **Pulp space** is closed compact space between skin & periosteum .
- **It is shut from** the middle pulp by a Transverse septum attached to bone .
- **It is filled with** fat & partitioned by incomplete fibrous septa .



★ Drained either by ↷

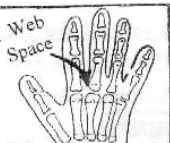- ① **Direct incision** over the inflamed point .
- ② **Hockey-stick incision** if **One side** of pulp is inflamed
- ③ **Trans- fixation incision** passing in front of the phalynx with division of all septa if the **whole** pulp is full of pus .



B WEB SPACE INFECTION

SURGICAL ANATOMY

- **Web spaces** is S.C spaces between the 4 digital slips of palmar aponeurosis .
- **It is bounded by.**
 - Proximal phalanges on each side
 - Palmar skin in front
 - Dorsal skin behind



★ Drained by ↷

Transverse incision on palmar surface of web, near its free border . Counter incision may be done posteriorly if the abscess communicates with a dorsal pocket .

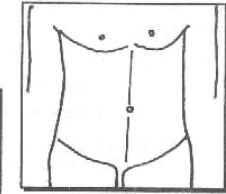
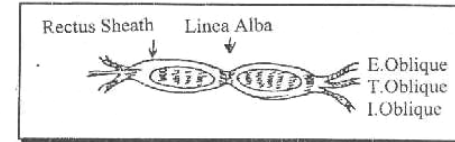


ABDOMINAL INCISION

III Vertical Incision :

① Midline Incision :

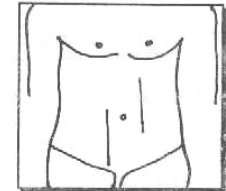
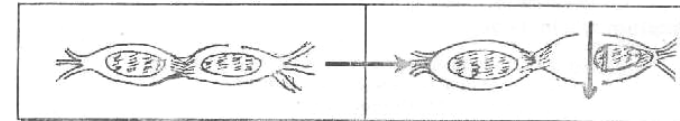
- **Method** : From Xiphi-sternum to symphysis pubis passes Through Linea Alba .
- **Layers** : Skin, S.C Tissues, Linea Alba & peritoneum .



- **Advantages** :
 - ① Quickly incision & can be enlarged freely .
 - ② Expose midline abdominal organs .
- So used for emergency as peritonitis
- **Disadvantage** : bad healing power .

② Rt. or Lt. paramedian incision :

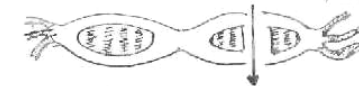- **Method** : Longitudinal incision 1 inch from the midline above or below the level of umbilicus or complet long. incision
- **Layers** : Skin, S.C Tissues, Ant. rectus sheath **Then** displace rectus muscles laterally to avoid injury of it's nerve supply . **Then** post. rectus sheath & peritoneum .



- **Advantages** :
 - ① Being safe & healing power is strong .
 - ② Expose Any Abdominal Organs .
- **Disadvantag** : Time consuming so not recommended in emergencies .

③ Trans-rectal Incision :

similar to the classic para - median incision but the rectus muscle is split .



III Transverse Incision :

① **Transverse epigastric (Bucket Handle) incision :**

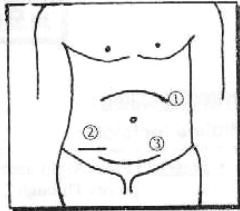
It is used for upper abdominal Exploration.

② **LANZ's incision :**

It is a modified Mc Burney's incision.

③ **Transverse supra-pubic (Pfannenstiel) incision :**

- **Method:** Lower Transverse supra- pubic incision.
- **Layers:** Skin, S . C Tissues & Ant. Rectus sheath.
 Then The 2 recti are separated.
 Then post. rectus sheath & peritoneum.
- **Advantage :**
 The scar is cosmetic as the wound lies in Langer's line.
- **Disadvantage :**
 It is Time consuming.

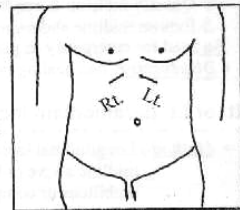


IIII Oblique Incision :

① **Subcostal Incision Rt. or Lt. :**

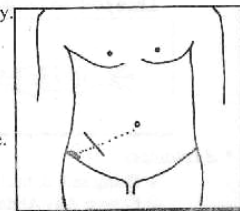
Rt. Sub-costal Incision = **Kocker's incision.**

- **Method :** 1 cm below & parallel to the costal Margin. It starts at midline and stops at lateral border of rectus muscle (but can be extended more)
- **Layers:**
 Skin, S . C tissues, Ant. Rectus sheath, the rectus muscle, post. Rectus sheath & peritoneum.
- **Used for** ↗
 Cholecystectomy, Exploration of C B D & Splenectomy.



② **McBurney's Incision :**

- **Method:** 2 inches incision is made perpendicular To line joining **A.S.I.S** & the umbilicus centered over **Mc Burney's point** which is junction of outer 1/3 & Inner 2/3 of this line.
- **Layers:**
 Skin, S . C tissues, Ext. oblique aponeurosis is opened along it's Fibers.
 Then split Int. oblique & Transversus fibers & Peritoneum.
- **Used for** ↗
 Appendicectomy.



Gastrostomy

* **Indications**

[A] **Temporary :**

- **Congenital :** Congenital oesophageal atresia.
- **Traumatic :** Rupture oesophagus due to Instrumentation.
- **Post-operative** stricture of oesophagus.
- **Neoplastic :** Removable Tumor of (Mouth, Pharynx or Oesophagus)

[B] **Permanent :**

Irremovable Tumor of (Mouth, Pharynx or Oesophagus)

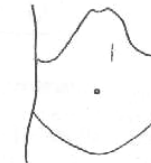* **Anaesthesia** "General"

* **Position** "Supine"



* **Incision**

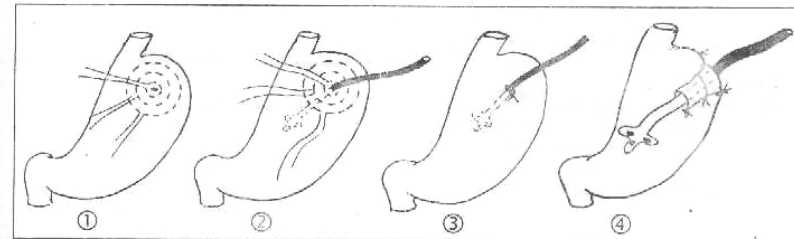
Lt. upper Trans-rectal Incision.



* **Steps** (2 Types).

[A] **Temporary; Serous lined gasterstomy :**

- ① **Peritoneum is opened** & the ant. wall of stomach is identified then at a selected site near the lesser curve, 3 seromuscular burse-string sutures are made.
- ② **An opening is made in their center** through which self retaining catheter is introduced.
- ③ **The burse-string sutures** are tied around the catheter inverting a tube of the wall of stomach lined on it's inside by serosa.
- ④ **A catheter** is brought outside the abdomen through a separate stab away from the incision.

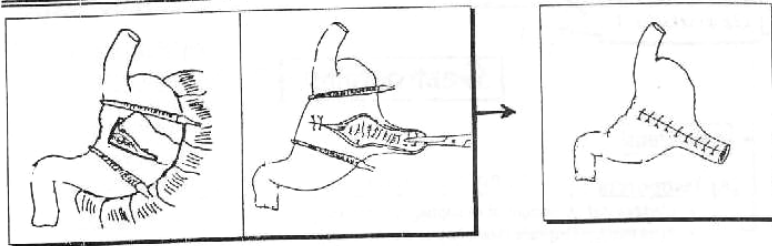


[B] **Permanent; Mucous lined gasterstomy :**

- ① A Flap from the Anterior wall of stomach is Fashioned in form of tube which is **mucous lined.**
- ② The Resulting defect of stomach is closed in 2 layers.
- ③ The Tube is brought to the surface & Fixed to the skin.

[Gastrostomy & Gastrectomy]

32



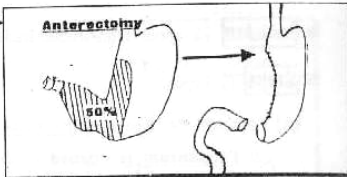
* **Complications** Wound Infection & If Leakage occur → peritonitis.

Operation 2

Gastrectomy

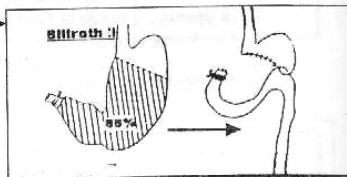
[1] **Hemi-gastrectomy : Antrectomy**

- It is Designed to remove the pyloric antrum which is the site of production of Gastrin Hormone used with DU.
- About 50% of distal part of the stomach is removed. i.e. (Hemi-gastrectomy).
- Followed by gastro-duodenal anastomosis.



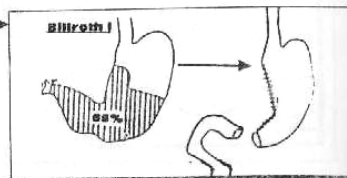
[2] **Subtotal gastrectomy : Billroth II**

- It is Designed to reduce the parietal cell Mass used with DU or cancer pylorus
- About 85% of distal part of the stomach is removed. i.e. (Subtotal Gastrectomy).
- Followed by gastro-jejunal anastomosis Then closure of duodenal stump



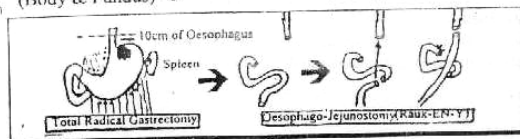
[3] **Partial gastrectomy : Billroth I**

- Indicated only with the gastric ulcer.
- About 65% of distal part of stomach is removed i.e. (Partial Gastrectomy).
- Followed by gastro-duodenal anastomosis.



[4] **Total gastrectomy :**

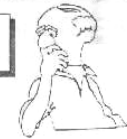Indicated with cancer stomach (Body & Fundus) ☺



[Gastrostomy & Gastrectomy]

33

Post-gastrectomy Complications



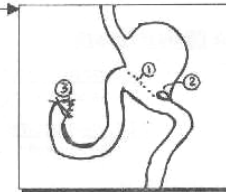
[1] Early Complications

[A] Operative complications

- Shock, infection and pulmonary complications
- Iry Hge from bleeding vessels.
- Injuries of important structures at stomach bed.

[B] Post-operative complications

- Haematemesis : Due to bleeding from suture line of anastomosis.
- Stomal obstruction : i.e. obstruction at line of anastomosis, by oedema at stoma
- Duodenal blow out : Follow Billroth II anastomosis after gastro-jejunosomy the blind duodenal stump may be distended with pancreatic and biliary juice → ↑ pressure → Disruption of suture line → Biliary peritonitis.



[2] Late Complications

[A] Recurrent ulceration

☆ Aetiology :

A) Inadequate surgery :

- e.g. ① Missing a vagal nerve (usually the posterior)
- ② Missing a vagal branch running over the lower oesophagus which is called "Criminal nerve".
- ③ Leaving part of gastric antrum (G-cells)

B) Other causes as Zollinger-Ellison syndrome i.e. Gastrinoma

C) Uses of ulcerogenic Drugs : Corticosteroids, Aspirin, NSAIDs ... etc.

☆ Site :

- Stomal (on the anastomotic line). i.e. Flase e.g. gastro-jejunal ulcer or gastro-duodenal ulcer.
- Site of original ulcer : i.e. True.

☆ Clinical picture :

Recurrancy of ulcer symptoms.

☆ Investigations :

Same as peptic ulcer especially Endoscopy and Estimation of circulating gastrin in blood by radio-immuno-essay for Z/E syndrome.

☆ Treatment :

[A] Medical ttt :

- H₂ receptor blocker as Cimitidine.
- Proton pump blocker as Omeprazole.

[B] Surgical ttt :

- Following vagotomy : Antrectomy is performed.
- Following Gastrectomy : Vagotomy is performed.

[Gastrostomy & Gastrectomy]

[B] **Dumping** [Post-cibal syndrome]

- It is a syndrome with Vasomotor & G.I.T symptoms after meal.
- It may be :



(I) Early Dumping

☆ **Aetiology :**

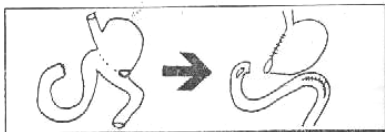
Rapid gastric emptying with the delivery of a hypersomolar solution to the proximal small gut with the result of shift of fluid from the circulatory plasma to the proximal small gut leading to ↑ Intestinal activity and ↓ blood volume.

☆ **Clinical Picture :**

- Vasomotor symptoms :**
As sense of weakness, Flushing and palpitation.
- G.I.T. symptoms :**
As Epigastric Fullness and pain with nausea ending by explosive diarrhea.

☆ **Treatment :**

- Frequent small meals.
- Beladonna** may reduce Intestinal motility.
- If symptoms persist convert gastro-jejunosomy to gastro - duodenostomy if possible



(II) Late Dumping

☆ **Aetiology :**

Overshot of **Insulin** which is caused by rapid delivery of large amounts of carbohydrates to the small intestine.

☆ **Clinical picture :**

Picture of **Hypoglycaemia**, sweating, palpitation and confusion which relieved by carbohydrate ingestion.

☆ **Treatment :**

- Avoid high carbohydrate in diet.
- Olive oil** with diet may delay emptying of stomach.

[C] **Biliary Gastritis**

Alkaline reflux gastritis.

[D] **Increase Incidence of Cancer**

In gastric remnant properly related to Biliary gastritis

[Gastrostomy & Gastrectomy]

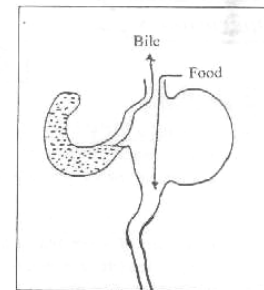
[E] **Afferent Loop syndrome**

☆ **Definition :**

It is a periodic vomiting of large quantities of bile and pancreatic secretions free of food with sudden relief of epigastric pain.

☆ **Aetiology :**

It is a mechanical obstruction of the long afferent jejunal loop because of its kinking at the anastomosis so that the bile and pancreatic juice accumulate in this loop until the obstruction is suddenly relieved.

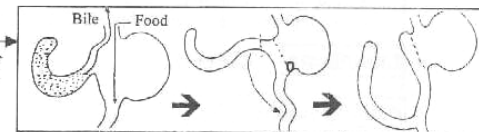


☆ **Clinical picture :**

Fullness and Epigastric pain following meals & followed by projectile bilious vomiting.

☆ **Treatment :**

Operative
Consists of conversion of Anastomoses to a Raux-en-Y loop.



[F] **Gastro-jejuno-colic Fistula**

It is a complication of gastro-jejunal ulcer, occurring in 4-8% of cases the ulcer penetrates & erodes the Transverse colon.

[G] **Intestinal obstruction**

It is due to internal herniation of Intestinal loops through a gap in the mesocolon.

[H] **Gall stone formation**

Commonly after Trunkal vagotomy due to associated denervation of the gall bladder → Impairment of its contractility → stasis → gall stone Formation.

[I] **Post-vagotomy Diarrhea**

[J] **Post-gastrectomy nutritional disturbances**

- ① **Weight loss.**
- ② **Steatorrhea & diarrhea :**
Due to lack of mixing of food with pancreatic & biliary secretions
- ③ **Vit. D Deficiency :**
Treated by Vit. D supplement.
- ④ **Ca Deficiency :**
Treated by Ca supplement.
- ⑤ **Fe Deficiency Anaemia :**
Treated by I.M Vit. B₁₂.

Operation 3

Splenectomy

*** Indications**

[A] Absolute Indications:

- **Traumatic** Rupture of spleen.
- Certain **Blood disease** as
 - ① Idiopathic Thrombocytopenic purpura.
 - ② **Congenital** Haemolytic Anaemia.
 - ③ Thalassaemia.
- **As part of other operations**, e.g. Radical gastrectomy.
- Splenic **cyst or Abscess**.
- **Tumors** of spleen e.g. Hodgkin's disease.
- Splenic Artery **Aneurysm**.

[B] Relative Indications :

- Bilharzial splenomegally ± Hypersplenism
- **Acquired** Haemolytic Anaemia.
- Staging laparotomy for Hodgkin's disease.

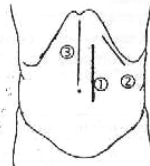
*** Anaesthesia "General"**

*** Position** Supine



*** Incision**

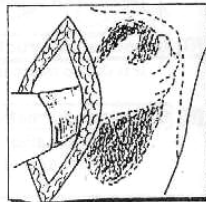
- ① Lt. upper paramedian (common).
- ② Lt. Sub-costal (Less common).
- ③ Midline (Thoraco-abdominal) if urgent cases.



*** Steps**

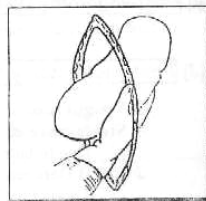
① **The Rt. Hand is passed**

Over the lateral surface of the spleen between it & the diaphragm.



② **The lateral edge of the wound**

Is strongly retracted & the spleen is drawn medially Exposing the **posterior** layer of **Lieno-renal** ligament. Then This layer is divided.



③ **The spleen is delivered outside the wound:**

The lower pole is delivered 1st, then the upper pole.

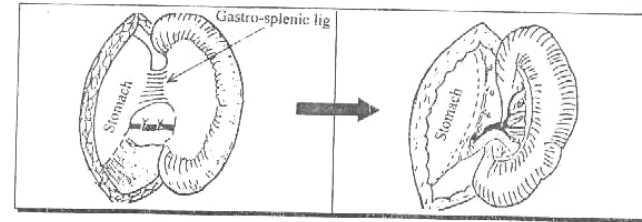
- Hot packs** are inserted in the splenic bed to
- ① Support the diaphragm to avoid sudden descent
 - ② Control of minor bleeding at splenic bed.
 - ③ Steady the spleen.

Don't Forget

④ **Ligation & division of gastro-splenic ligament :**

Which contains the short gastric vessels.

[Splenectomy]

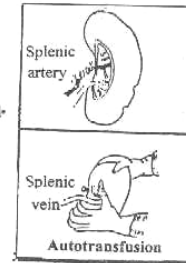


⑤ **Ligation & Division of Anterior layer of lieno-renal ligament :**
To expose the splenic vessels & Tail of pancreas.

Then ☆ **Ligation of splenic artery** by 3 ligatures of silk & the artery is divided between the distal 2 ligatures.

Then ☆ **We squeeze the spleen** to get benefit of stored blood Inside it i.e. **Auto-Transfusion**.

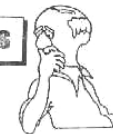Then ☆ **Ligation of splenic vein** by 3 ligatures of silk & the vein is divided between the distal 2 ligatures.



⑥ **Finally :**

- ① **The spleen is removed** & it's bed is inspected for any bleeding which must be secured.
- ② **Peritonisation** of splenic bed by suturing the anterior & posterior layers of lieno-renal ligaments.
- ③ **The Abdomen is closed** in layers without drainage.

Complications



A] Operative complications

- **Shock**, Infection & pulmonary complications.
- **Irr Hge.** from bleeding vessels.
- **Injury of important structures** as Stomach, Pancreas ... etc.

B] Post-operative complications

① **General Complications**

- ① Post-splenectomy fever : unsettled cause.
- ② Vomiting & Hiccough.
- ③ Acute gastric dilatation & Paralytic Ileus.

② **Local Complications**

- ① **Reactionary Haemorrhage** : due to slipped ligature or bad Haemostasis.
- ② **Haematemesis** : due to splenectomy with active oesophageal varices.
- ③ **Sub-diaphragmatic** collection of blood.
- ④ **Splenosis peritonei** : in case of ruptured spleen.
- ⑤ **Portal vein thrombosis** : due to ↑ platelets count.
- ⑥ **Burst Abdomen** : due to post-operative distension & also if the pancreas is injured → liberation of proteolytic Enzyme → Burst Abdomen

Operation 4

Cholecystectomy

38

Indications

- **Congenital** : Septated gall bladder.
- **Traumatic** : Rupture G.B..
- **Inflammatory** :
 - ① Acute cholecystitis (Calcular & Non calcular).
 - ② Chronic calcular cholecystitis.
 - ③ Chronic non calcular cholecystitis in Typhoid carrier.
 - ④ Mucocele & Empema of G.B.
- **Neoplastic** : Operable carcinoma of gall bladder.

Contraindications

1. Biliary Dyskinesia.
2. Asymptomatic gall stones in unfit patient.
3. Liver cirrhosis.

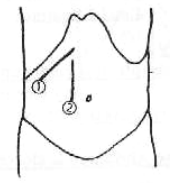
Anaesthesia "General"

Position "Supine"



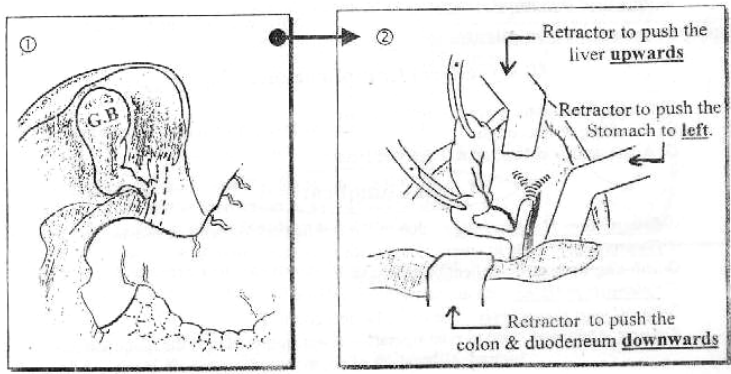
Incision

- ① Rt. Sub-costal (Kocher's) incision.
- Or ② Upper Rt. para-median incision.



Steps

- ① **Exposure of operative field by :**
 - Stomach is retracted to the **left**.
 - Colon & duodenum are retracted **down**.
 - Liver is retracted **upwards** to expose the G.B.
- ② **A forceps is applied to the fundus of G.B.** which is pulled on to visualize the [Y] junction of the 3 bile ducts. The peritoneum over this junction is incised & the cystic duct is dissected up to it's junction with the CBD.



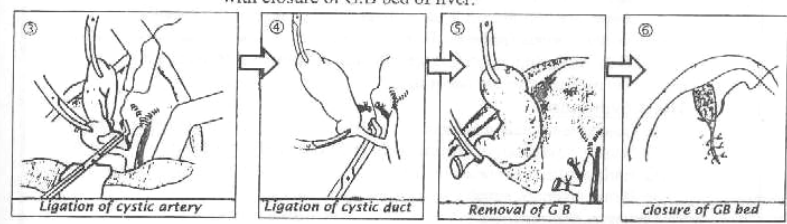
[cholecystectomy]

39

- ③ **The cystic artery** is Ligated & divided. It is usually present at a higher level & more posteriorly than the cystic duct..

N.B. : **An operative cholangiogram** can be performed at this step the value is to demonstrate any stone in the C.B.D.

- ④ **The cystic duct** is ligated about 5 mm lateral to the CBD and is then divided.
- ⑤ **Now The G.B.** is freed from it's bed in the liver by blunt dissection then removed with closure of G.B bed of liver.



- ⑥ **The Abdomen** is closed with a drain in the hepato-renal pouch.

N.B. : **Retrograde cholecystectomy** (Fundus 1st cholecystectomy)
Some surgeons prefer removal of G.B from above downwards starting at the fundus then cystic duct & cystic artery.
This is done if the duct can't be identified because of adhesions

Complications

A Operative Complications

- **Shock**, Infection & pulmonary complications.
- **Irr Hge** from bleeding vessels.
- **Injuries of Important structures :**
 - as ① Injury to **CBD or CHD** by a clamp or a ligature may lead to post-operative obstructive jaundice.
 - ② Injury of **liver substance**.
 - ③ **Liver failure** from ligation of hepatic artery Instead of cystic artery as a mistake.
 - ④ Injuries of **duodenum** or hepatic flexure of colon.

B Post-operative complications

- **Incisional Herraia**.
- **Post-cholecystectomy syndrome** [persist or recurrency of symptoms]
 - IF ① Missed stone in CBD.
 - ② Stricture of CBD.
 - ③ Spasm of sphincter of oddi.
- **Wrong Diagnosis** : As

Wilkie's Triade which is
Chronic peptic Ulcer + Chronic Appendicitis & Chronic Calcular Cholecystitis

Saint's Triade which is
Hiatus Hernia + diverticulosis Coli + Chronic Calcular Cholecystitis

Recently

Laparoscopic cholecystectomy (LC) :

The Idea

- To induce a pneumoperitoneum using CO₂ gas
- Then Through 4 small ports, a special camera and fiberoptic scope are introduced and a magnified picture of the internal organs is visualized on a Television screen.
- Then By using special graspers and instruments, the surgeon can perform cholecystectomy

The Advantages

- ① Less post-operative pain
- ② Short post-operative hospital stay (1-2) days only.
- ③ Early return to work.
- ④ Better cosmetic result.

The contra-indications :

- ① Pregnancy as no space for pneumoperitoneum.
- ② Marked obesity as it is difficult to induce to induce the ports.
- ③ Bleeding Tendency.
- ④ Liver Cirrhosis.
- ⑤ Empyema of gall bladder.
- ⑥ Carcinoma of gall bladder.
- ⑦ Compromize of Cardio-vascular or Respiratory function.
- ⑧ previous upper abdominal surgery is relative contraindicated.

Operation 5

Exploration of the CBD

*** Indications**

[A] Pre-operative indication:

- ① Calcular obstructive Jaundice
- ② Past history of Jaundice.
- ③ History of recurrent cholangitis (Charcot's Fever).
- ④ Evidence of dilated C.B.D (> 1cm) by sonar

[B] Intra-operative (if during cholecystectomy)

- ① Gall stones if founded smaller than the size of cystic duct. i.e. may be passed to CBD
- ② Palpable stones inside CBD.
- ③ Intra-operative cholangiography reveal a stone in CBD
- ④ Dilated C.B.D (> 1cm)

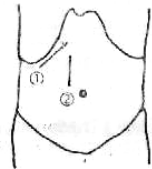
*** Anaesthesia "General"**

*** Position** Supine

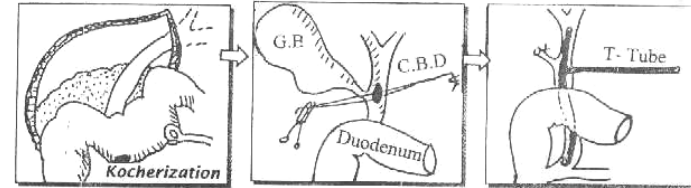


*** Incision** Like Cholecystectomy.


- ① Rt. subcostal (Kocher's) incision.
- ② Upper Rt. para -median incision.



*** Steps Conventional Cholecystectomy & Choledocholithotomy**



- ① The 1st step is to mobilise the duodenum from posterior abdominal wall (Kocherisation of duodenum) to expose the retro-duodenal portion of C.B.D.
- ② 2 stay sutures are taken in the wall of the supra- duodenal portion of C.B.D.
- ③ A vertical incision (2cm long) is made in between the 2 stay sutures.
- ④ Stone forceps is introduced into the C.B.D to remove the stone, then patency of C.B.D is confirmed by passing a metal dilator (Bake's dilator)
- ⑤ Some surgeons insert a Choledochoscope to check that there are no retained stones
- ⑥ T-Tube is inserted in (CBD) which is closed around the tube, the long limb of the tube is brought outside the patient.
- ⑦ T-Tube Cholangiogram can be performed after closure of CBD to check absence of filling defect. i.e. Completion T-tube cholangiography.
- ⑧ Cholecystectomy is then performed



In some cases: An additional procedure has to be performed in addition to Choledocholithotomy.

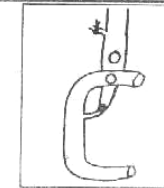
I] Choledocho-duodenostomy:

• Indications:

- ① Stricture of lower end of CBD.
- ② A stone impacted at lower end of CBD.

• Technique :

An anastomosis between CBD & the 1st part of the duodenum.



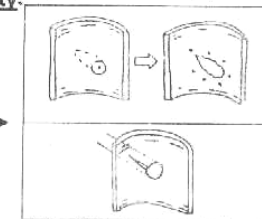
II] Sphincterotomy or Sphincteroplasty:

• Indications:

- ① stricture or papilla of sphincter of oddi
- ② A stone impacted at sphincter of oddi

• Technique:

A longitudinal cut is made in the papilla and Part or all of the sphincter of oddi is divided at The 10 O'clock position to avoid injury of the pancreatic duct.



*** Post-operative**

10 days post- operative another cholangiography to ensure that no residual stones before removal of The T-tube

Operation 6

Appendicectomy

42

*** Indications**

- ① Acute Appendicitis.
- ② Recurrent Attacks of Subacute Appendicitis.
- ③ Mucocele of Appendix.
- ④ Carcinoid Tumors of the Appendix.

*** Contraindication**

- ① Appendicular Mass
- ② Crohn's disease affecting the caecum to avoid fistula.

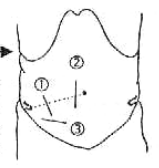
*** Anaesthesia "General or Spinal"**

*** Position "Supine"**



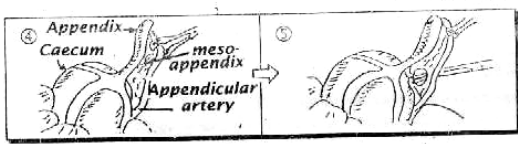
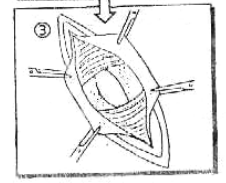
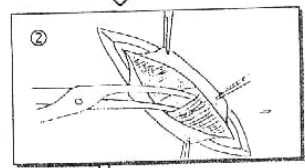

*** Incisions**

- ① **Mc Burney's** : 2 inches incision is made perpendicular to the line joining A.S.I.S. & the umbilicus. Centered over Mc Burney's point (Junction of Outer 1/3 & Inner 2/3 of this line)
- ② **Rt. Lower paramedian**
- ③ **Lanz's Incision** (Modified Mc Burney's) Transverse Lower abdominal skin crease incision.



*** Steps**

- ① **The External Oblique Aponeurosis** is split in the line of its fibers i.e. same line of incision. Then its edges are retracted to expose the internal oblique muscle
- ② **The Internal oblique Muscle** is split together with the underlying Transversus Abdominis muscle in one line
- ③ **The peritoneum & Fascia Transversalis** are then picked up as one layer & divided in the line of incision
- ④ **After the opening of peritoneum**, the caecum is pulled to Outside the abdomen then Taenia coli are followed to the base of appendix.

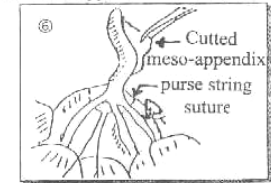


[Appendicectomy]

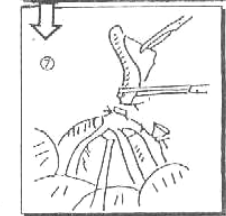
43

⑤ **Devascularization of Appendix** by ligation of meso-appendix including the Appendicular artery.

⑥ **A sero-muscular burse-string suture** is applied in the wall of Caecum around and 1 cm from the base of Appendix

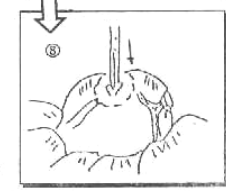


⑦ **The Base of the Appendix** is then crushed 3 Times by a **Kocher's** Forceps 1 cm apart in between each Crush Then the appendix is excised at the Level of 2nd crush & the stump is sterilized by **Betadine**.



N.B : If the Appendix is severely inflamed, Crushing of it's base is better avoided.

⑧ **The stump of the Appendix** is invaginated into the Caecum and the purse-string sutures are tightened



N.B: If the inflammation has reached the wall of caecum, **Invagination** is better Avoided & covered by greater Omentum.

⑨ **Completed Haemostasis** : then the abdomen closed without drain

N.B: When the case is complicated by Appendicular abscess, A drain must be used.

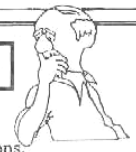Complications

A Operative Complications

- **Shock**, Infection & pulmonary complications.
- **Irr Hge**, from bleeding vessels.
- **Injury of important structures** as Ileum, Caecum ... etc.

B Post-operative complications

- (I) **Hernia**
 - **Incisional**: From wound infection.
 - **Direct Inguinal**: if Ilio-inguinal nerve injury occur.
- (II) **Faecal Fistula**
 - It occurs with injured wall of caecum.
- (III) **Post-operative** Intestinal obstruction
 - Because of adhesions



Operation 7

44

Colostomy

It is an opening of the colon to the skin = An Artificial Anus

Indications

[A] Temporary :

- **Congenital:** High Ano-rectal malformations or Hirschsprung's disease.
- **Traumatic:** Perineal tears or Colo-rectal tears
- **Neoplastic:** Colo-rectal Tumors.
- **Others :** To protect a distal doubtful Colo-rectal Anastomoses.

[B] Permanent :

- **Operable Carcinoma:** After Abdomino-perineal resection
- **Inoperable Carcinoma:** As a palliative Treatment.

Types (مهم)

[A] According to Indications :

- ① Temporary Colostomy.
- ② Permanent Colostomy.

[B] According to The site :

- ① Transverse (Sub-hepatic) colostomy.
- ② Sigmoid (Iliac) Colostomy.
- ③ End (Terminal) Colostomy.

[C] According to the Shape :

- ① Simple loop Colostomy
- ② Double-barrel Colostomy [Obsolete]
- ③ Terminal (End) Colostomy.

Now We will discuss ↻

Temporary, Transverse & Simple loop Colostomy

Pre-operative preparation

- **Colonic Anastomosis** is liable to disruption, Leakage & peritonitis because ↻
 - ① The highly infective content by both aerobic & anaerobic organism.
 - ② Constant gaseous distention.

SO

[1] **Improve** nutritional status of the patient.

[2] Bowel preparation :

a. **Mechanically :** Enema & laxatives 4 days before operation.

b. **Chemically :**

- ① Intestinal Antiseptics (Neomycin & Metronidazole) orally 3 days before operation
- ② I.V Cephalosporines & Metronidazole At Time of anaesthesia.

[colostomy]

45

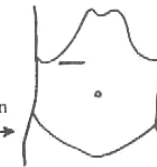Anaesthesia "General"

Position Supine



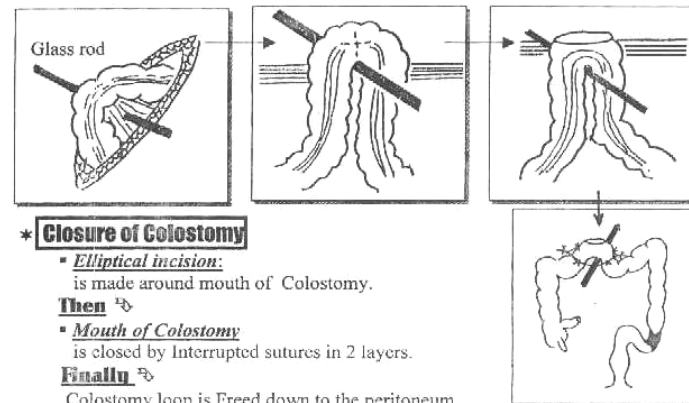
Incision

Transverse muscle cutting incision below the Rt. costal margin



Steps

- ① **Colon** is grasped & delivered outside the abdomen.
- ② **The site of colostomy** is selected as close as possible to hepatic flexure.
- ③ **A window** is opened in the transverse mesocolon With a **glass rod**
- ④ **The peritoneum** is then sutured to the serosa of the colon all around to make colostomy extra-peritoneal.
- ⑤ **The colon is opened** along it's Axis through the Tenia Coli.
- ⑥ **The mucosa of the colon** is then sutured to the skin all around



Closure of Colostomy

- **Elliptical incision:** is made around mouth of Colostomy.
- Then** ↻
- **Mouth of Colostomy** is closed by Interrupted sutures in 2 layers.
- Finally** ↻

Colostomy loop is Freed down to the peritoneum without opening the peritoneum

N.B :Pre-operative preparation Must be done before closure of the colostomy.

Complications

- ① **Skin Excoriation.**
- ② **Prolapse :** due to redundancy of the proximal limb of colostomy.
- ③ **Retraction:** If colostomy is made under tension.
- ④ **Stenosis** of the orifice.
- ⑤ **Necrosis** of distal end
- ⑥ **Gangrene:** due to inadequate blood supply of colostomy.
- ⑦ **Para-colostomy Hernia :** if the peritoneum was not closed properly all around the colostomy.



Operation 8

Haemorrhoidectomy

46

*** Indication**

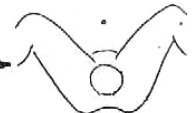
- ① Late 2nd, 3rd & 4th degree piles.
- ② Failure of instrumental treatment.
- ③ Associated Pathology requires Surgery e.g. Chronic Anal fissure.

*** Pre-operative preparation**

- One day before operation : repeated enema to washout rectum.

*** Anaesthesia** "General or Spinal"

*** Position** Lithotomy Position



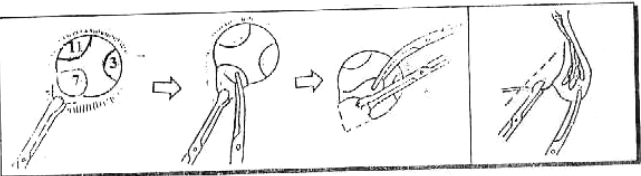
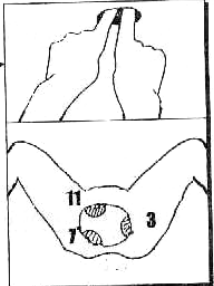
*** Steps**

① **Dilatation of Anal sphincter**

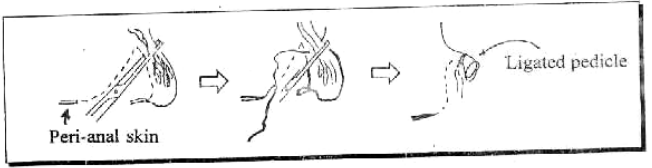
By a lubricated fingers up to 4 finger, till the 3 mother piles are visualised at 3, 7 & 11 o'clock position.

② **A bladder forceps** are applied to catch the mucocutaneous junction & then an **artery forceps** are applied to catch the fundus of piles.

③ **A v-shaped cut is made** in the skin opposite each pile & the pile is dissected up from it's fundus till it's pedicle.



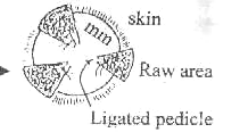
④ **The pedicle is crushed** with **Kocher forceps** & Transfixed by a silk suture then divided distal to the ligature.



[Haemorrhoidectomy & operations For Anal Canal]

47

③ **3 pieces of gauze Soaked** with flavin solution are introduced into Anus so as to Cover the raw areas



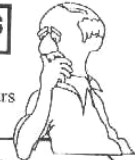*** Post-operative Care**

- ① **Pethidine is given I.M** every 12 hours for 2 days as Analgesic
- ② **The 3 gauzes** are removed after 48 hours.
- ③ **The patient is advised** to sit in warm baths with Antiseptic solution as **Dettol (4 times/d)**

N.B. : P.R Exam : Is started from 7th day till completed healing (About a month) to prevent Anal stenosis

Complications

- ① **Haemorrhage** :
 - 1ry during operative
 - Reactionary within 24 hours
 - 2ry After 7 days.



N.B: Post-operative Haemorrhage :

- Very common with
- ① Haemorrhoidectomy.
 - ② Kidney operations
 - ③ Prostatectomy.
 - ④ Tonsilectomy.

- ② **Pain**: which leads to Reflex urine Retention.
- ③ **Recurrence** : from daughter piles.
- ④ **Anal stenosis** : from removal of excess skin & mm in between piles.
- ⑤ **Anal Fissure** : from incomplete wound healing.
- ⑥ **Injury of Internal sphincter** : Incontinence to flatus or stools.

Operation 9

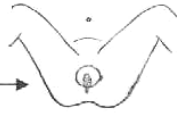
Operations For Anal Fissure

*** Indications**

- ① Acute Anal Fissure not respond to medical Treatment or digital dilation.
- ② Chronic Anal Fissure.

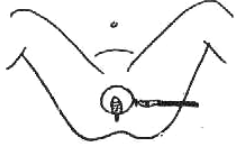
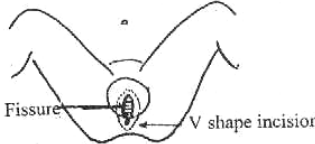
*** Anaesthesia** "General or Spinal"

*** Position** Lithotomy Position



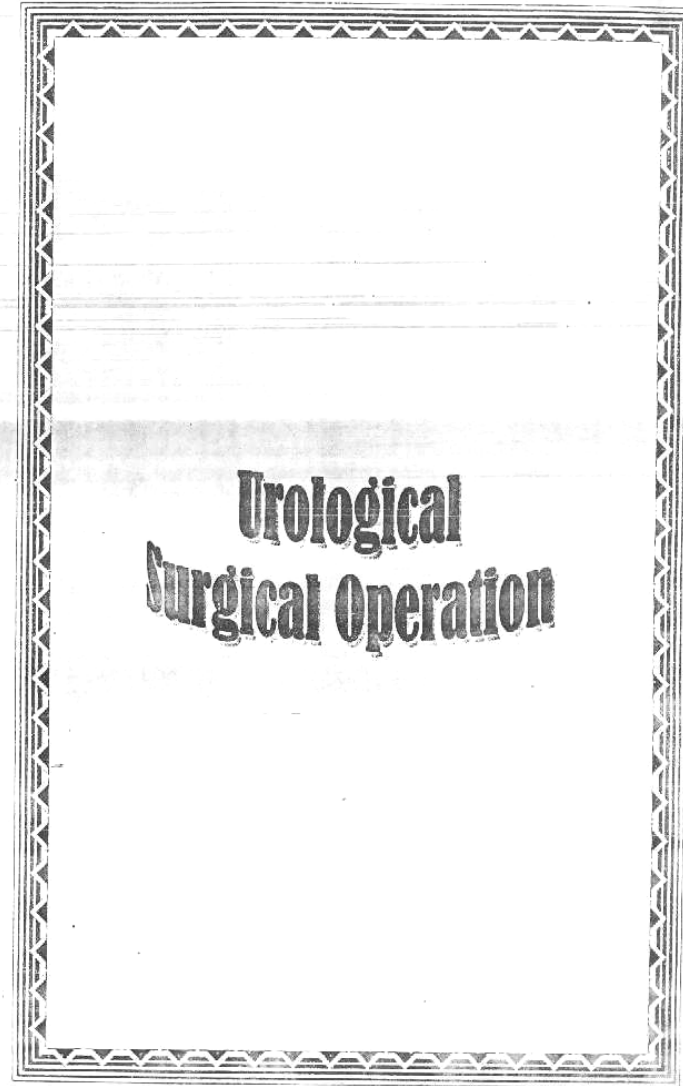
[operations for Anal fissure]

* **Steps** [The Aim is to obtain complete relaxation of Internal sphincter to allow healing].

| [A] Closed lateral Internal Sphincterotomy | [B] Fissurectomy & posterior. Internal Sphincterotomy |
|---|--|
|  |  |
| <p>① Saline-adrenaline (1/200,000) sol. is injected around the internal anal sphincter</p> <p>② The scalpel is introduced at the 3 O'clock position through the skin in between the internal & external sphincter & parallel to them</p> <p>③ The scalpel is then rotated 90° towards the anus to divide the internal sphincter up to the level of Dentate line</p> <p>④ Pressure by the I.t. index inserted into the anus on the site of sphincterotomy helps to rupture any undivided fibers & to induce haemostasis.</p> | <p>① Dilatation of anal sphincter by lubricated fingers up to 4 fingers.</p> <p>② A(V-shaped) incision is made in the skin opposite the fissure including the skin tag</p> <p>③ Dissection is carried out in the S.C. tissue and submucosa below the fibrosed edges of the fissure, till reaching the dentate line, then excise the Fissure, Anal polyp & sentinel pile</p> <p>④ The internal sphincter is cut in the bed of the fissure (posterior Int. sphincterotomy)</p> |

Complications

- ① Injury of Anal sphincters.
- ② **Haematoma** :
Especially with closed lateral Internal sphincterotomy.



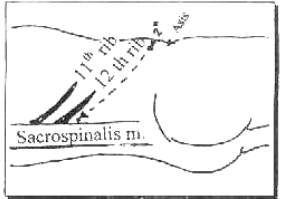
Renal Incisions

[1] Lumbar (Morison's) Incision :

Method :

Incision extends from the renal angle to a point (2 inches) above A.S.I.S at Anterior Axillary line

N.B. : Renal Angle :
Angle between Sacro-spinalis & last Rib.



Layers :

Skin, S.C Tissues and muscle layers.

N.B. : Muscle layers :

- 1st layer : Ext. oblique (laterally) & Latissimus dorsi (medially).
- 2nd layer: Int. oblique (laterally) & Serratus postero-inferior (medially).
- 3rd layer : Transversus abdominis (laterally) & Lumbar fascia (medially).

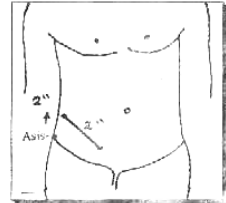
Used for : Exposure of kidney & Upper 1/3 ureter.
For ① Nephrostomy & Nephrectomy.
② Pyelolithotomy or Nephrolithotomy.
③ Removal of stone upper 1/3 ureter.

[2] Abernathy's Incision :

Method :

Incision starts 2 inches above ASIS on the Anterior Axillary line & passes downwards and medially 2 inches above & parallel to the lateral 2/3 of inguinal ligament.

Used for : Exposure of Middle 1/3 ureter.
For Removal of stone Middle 1/3 ureter

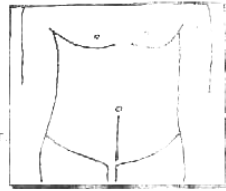


[3] Supra-pubic Incision :

Method :

Incision extending from umbilicus to the symphysis pubis

Used for : Exposure of Lower 1/3 ureter & urinary bladder.
For ① Removal of stone lower 1/3 ureter.
② Cystolithotomy.



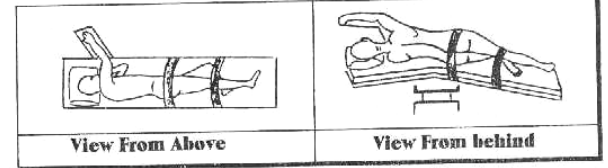
I Exposure of the Kidney

* **Approach** 2 Approaches

- ① Posterior (Extra-peritoneal).
 - ② Anterior (Trans-peritoneal).
- For Trauma & Tumors.

* **Position**

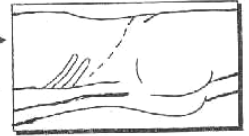
On lateral side, with leg extended, the other one is flexed at Hip and Knee Joints with a sand bag below the opposite side to open the Renal angle.



* **Anaesthesia** General

* **Incision** Lumbar (Morison's) Incision

Incision extends from the renal angle to a point (2 inches) above A.S.I.S at Anterior Axillary line

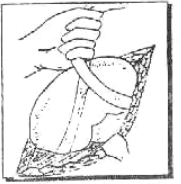


* **Steps**

Posterior (Extra-peritoneal) Approach :

- ① **The perinephric Fascia** of Zuker-kandel is opened.
- ② **The perinephric Fat** is dissected to see the kidney with it's capsule.

N.B.: If there is difficulty in Exposure The last rib can be resected to obtain wide filed.



③ **The kidney is delivered** from the wound and then dealt with as follows

Operation 1

Nephrostomy

* **Indications**

- ① Calculus Anuria.
- ② Hydronephrosis & Pyonephrosis.
- ③ Irremovable distal obstruction :
as ureteric stricture or cancer bladder.

[Nephrostomy & Nephrectomy]

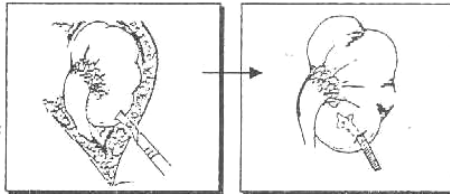
* **Position** + **Anaesthesia** + **Incision** → As above

* **Steps**

• Kidney is Exposed (as usual)

Then IF the kidney is grossly Hydronephrotic :

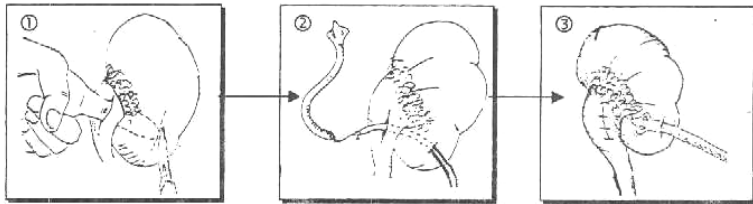
A self-retaining catheter is introduced into the pelvis or lower calyx through a small nephrostomy incision.



But IF the kidney is relatively Healthy:

(Cahot's Method) is done →

- ① **The kidney is mobilized** & An incision is made into the pelvis through which a finger is inserted into the lower calyx.
- ② **A small Incision** is made in the renal cortex over the finger.
- ③ **The Tube** is put in the pelvis and Came out from the kidney substance through the calyx.



Operation 2

Nephrectomy

[A] Partial Nephrectomy

* **Indications**

- ① **Congenital** : Solitary cyst of the kidney.
- ② **Traumatic** : Avulsion lower pole.
- ③ **Inflammatory** : Localized focus of T.B.
- ④ **Stones** : Impacted at lower calyx.

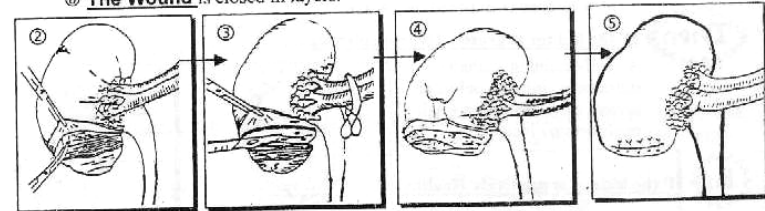
* **Position** + **Anaesthesia** + **Incision** → As before

* **Steps**

- ① **The kidney** is exposed (as usual) with ligation of vessels at hilum.
- ② **The capsule** is incised & stripped upwards.

[Nephrectomy]

- ③ **The kidney Tissue** is cut in a V-shaped manner.
- ④ **The Calyx** is sutured and the kidney tissue is sutured and covered by the redundant capsule.
- ⑤ **The Incision** is closed.
- ⑥ **The Wound** is closed in layers.

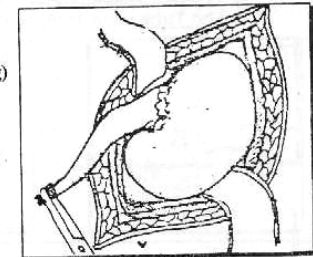


[B] Total Nephrectomy

* **Indications**

(Provided the other kidney is well-functioning)

- ① **Congenital**: Multicystic kidney.
- ② **Traumatic** : Avulsed whole kidney.
- ③ **Inflammatory** : - Renal T.B.
- Pyonephrosis.
- ④ **Stone** : e.g. staghorn stone.
- ⑤ **Obstructive uropathy** : Hydronephrosis.
- ⑥ **Neoplasm** : - Hypernephroma.
- Wilms' tumor,.....
- ⑦ **Others** : as Hydatid cyst.



* **Position**

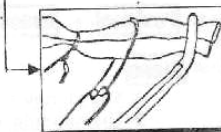
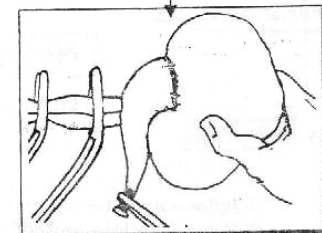
* **Anaesthesia**

→ As before

* **Incision**

* **Steps**

- ① **The kidney** is exposed (as usual)
- ② **The ureter** is identified and divided (at its upper 1/3).
- ③ **The pedicle** is cutted and ligated between 2 clamps.
- ④ **The kidney** is removed.
- ⑤ **The wound** is closed in layers over a drain.



Operation 3

Removal of Renal Stones

53

[1] Pyelolithotomy :

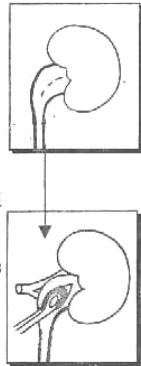
(Removal of stone through Renal Pelvis)

*** Indications**

- ① Solitary stone in an Extra-renal pelvis.
- ② Stone in a calyx which can be delivered in the pelvis.

*** Technique**

- ① **The kidney** is Exposed (as usual).
- ② **The stone is palpated**, steaded in it's position Then the renal pelvis is incised over the stone.
- ③ **The stone is removed** by a stone forceps.
- ④ **The distal ureter** is explored by a metal dilator to ensure it's patency (No distal obstruction).
- ⑤ **The wound** is closed over a drain.



[2] Nephrolithotomy :

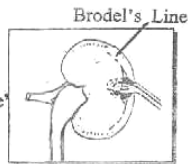
(Removal of stone through Renal Parenchyma)

*** Indications**

- ① When the kidney can not be delivered because of adhesions or short pedicle.
- ② Stone in a cortex which can not be delivered in the pelvis.

*** Technique**

- ① **The kidney** is Exposed (as usual).
- ② **The incision** is made Just behind & parallel to "**Brodie's line**".
- ③ **The stone** is removed then the wound is closed.



[3] Pyelo- Nephro-Lithotomy :

It is a **Combined incision** at renal pelvis and renal parenchyma.

[4] Bench surgery : (In V. difficult cases).

The kidney is removed from the body i.e. Nephrectomy and dealt with outside the body and then re-implanted again.

[5] Total Nephrectomy : If staghorn stone.

54

Complications of Kidney Operations



A Operative Complications

- Shock, Infection & Pulmonary Complications.
- **Iry Hge** From renal pedicle.
- **Injuries of important structures as**
 - ① peritoneum → peritonitis.
 - ② Intercostal vessels → bleeding
 - ③ Intercostal nerves → paralysis of Rectus Abdominis
 - ④ Duodenum & colon → Fistula

B post-operative Complications

- Haemorrhage (2ry or Reactionary)
- Infection → Peri-nephric abscess.
- Recurrent stones.
- **Urinary fistula:** if there is distal ureteric obstruction.

II Exposure of the ureter

Upper 1/3 Ureter: Through lumbar morision incision (as renal operations).

Mid 1/3 Ureter: Through abernathy's (Iliac) incision.

Lower 1/3 Ureter: Through midline supra-pubic from umbilicus to symphysis pubis (as urinary bladder operations)

Operation 4

Ureterolithotomy

(Abernathy's operation)

*** Indications**

Stone middle 1/3 ureter with Failure of medical & Instrumental treatment

*** Position**

Supine with the side of operation is raised 20°.

*** Anaesthesia**

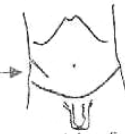
"General"

*** Incision**

Abernathy Incision

*** Steps**

- ① **The ureter is exposed extra- peritoneal** then heled by a rising forceps

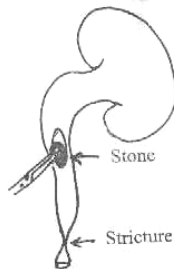


[Ureterolithotomy & Cystolithotomy]

55

N.B: The ureter is a Retro-peritoneal structure and it is identified by:

- Tubular structure surrounded by longitudinal vessels.
- Crosses the common iliac artery bifurcation.
- Shows peristaltic waves.
- Aspiration reveals urine.



- ① **The ureter is incised** longitudinally over the stone and the stone is removed by a forceps.
- ② **A dilator is passed** through the ureter to the bladder to detect any distal stricture.
- ④ **The wound** is closed in layers over a drain

III Exposure of the urinary bladder

Through midline supra- pubic incision For Cystolithotomy.

Operation 5

Cystolithotomy

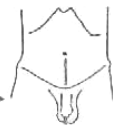* **Indications**

- ① **Stone bladder** with failure of medical & Instrumental Treatment.
- ② **Other Pathology** as SEP, B NO or Diverticulum.

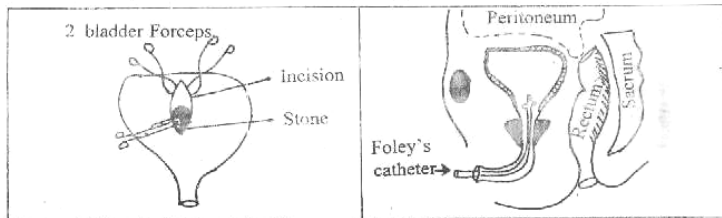
* **Position** "Supine"

* **Anaesthesia** "General"

* **Incision** Midline supra- pubic.



- * **Steps**
- ① **The peritoneum** is not opened & pushed up to expose the bladder.
 - ② **After exposing the bladder**, it is held between 2 bladder forceps. Then it is opened in the midline, and stone is removed by a forceps.
 - ③ **The abdomen** is closed over a drain (i.e. suprapubic tube)
 - ④ **Finally** a Urethral foley's catheter is inserted.



Operation 6

56


Prostatectomy

* **Indications**

- ① **Sever Prostatism** Sever frequency, Severe dribbling of urine or Weak stream.
- ② **Complicated Prostatism:** more than one attack of Acute retention, Haematuria & back pressure on kidney.
- ③ **Residual urine > 200 cc**

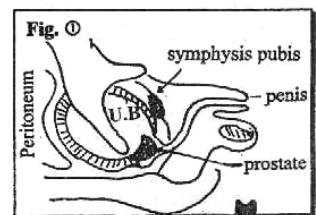
Endoscope Surgery

- Trans-urethral Resection [TUR]**
- using the cysto-resectoscope, the prostate is removed piece by piece using Electric cutting.
 - It is the operation of choice for the majority of patient, the only limitation is large adenoma because of hazardous result.

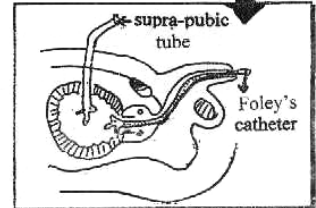


Open Surgery

- ① **Trans-vesical Prostatectomy:** Fig ①
Through a midline supra-pubic incision. The urinary bladder is opened, the index finger is inserted into the bladder neck, and so the adenoma is enucleated then the Haemostasis occur.
Finally: Closure of the bladder over a Foley's catheter and supra-pubic Tube

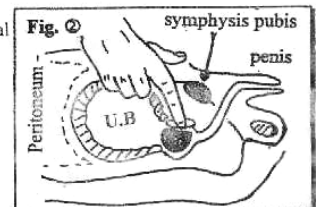


- ② **Retro-pubic (Millin's) Prostatectomy:** Fig ②
Through a midline supra-pubic incision. the retro- pubic space is exposed (by cutting) the pubo-prostatic Ligaments. **But** bladder is not opened, the Adenoma is enucleated and Haemostasis is secured undervision



* **Complications of Surgery**

- ① **Bleeding** ± clot retention.
- ② **Incontinence** in 1:10,000 because of damaged internal sphincter.
- ③ **Retrograde Ejaculation** in bladder because of damaged internal sphincter.
- ④ **Infection** → Urethritis & Cystitis.
- ⑤ **Urethral Stricture**
- ⑥ **Impotence** (2-5%): due to injury of pudendal nerve fibers in the region of posterior urethra.



Operation 7

Circumcision

Indications

- ① Religious reasons.
- ② Phimosis & para-phimosis
- ③ Recurrent **balanitis** (Infection of glans penis)
- ④ Recurrent **balanoposthitis** (Infection of prepuce)

Contraindications

- ① Congenital Anomalies as **Hypospadias**.
- ② Bleeding Tendency as **Hemophilia**

I Neonates & Infants (< 2 years)

Bone Cutting Method

Anaesthesia

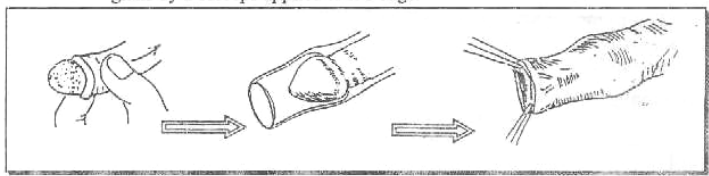
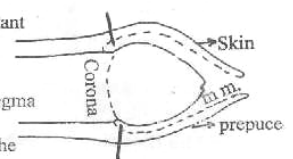
No Anaesthesia below 1 year
but General Anaesthesia above 1 year

Position On Back

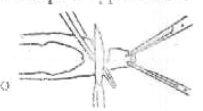
The knees are held flexed & abducted by an assistant

Steps

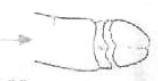- ① **The Prepuce is retracted** till the Corona is seen then the glans is cleaned well from smegma
- ② **The Prepuce now is returned** in place over the glans by 2 forceps applied to it's edge.



- ③ **The Prepuce is pulled forwards** and bone cutting forceps is applied on it [Take care to injure the glans]
Then maintain it for 1 min. to crush the vessels & to obtain good Haemostasis
Finally the prepuce is excised by a scalpel distal to bone cutting forceps.



Now ④ **The glans is protruded** through the cut edges
Apieces of gauze is applied circumferentially to the site of circumcision after being moisted by **Tinc. Benzoic co.**



[Circumcision]

II Children (> 2 years) & Adult

Dissecting Method

N.B: pre-operative preparation:

By **Bromide** as sedative to prevent post-operative erection with Adult


Anaesthesia

General Anaesthesia for older children (2-12) years.
Spinal Anaesthesia: For Adult > 12 years

Why Local Anaesthesia is Contraindicated?

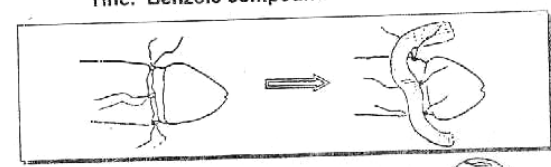
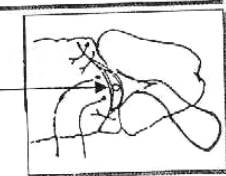
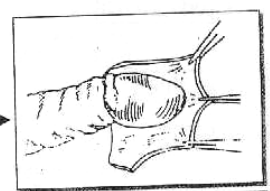
Because it is formed of **(2% Xylocain)** + Adrenaline which is Vasoconstricting of all penile vessels → gangrene of the glans.

Position "Supine"



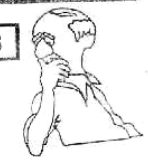Steps

- ① & ② **Same** as Bone Cutting Method.
- ③ **The dorsum of the prepuce is Slit** by A scissor till the corona of the penis is seen, the prepuce is incised Circumferentially at the level of corona
- ④ **The Bleeding vessels are Ligated.** Undervision especially the fraenular artery
- ⑤ **The mucosal stump of excised prepuce is** approximated to the skin of penile shaft by few Interrupted sutures.
- ⑥ **Finally:** A Ribbon of gauze Soaked with **Tinc. Benzoic compound**



Complications

- ① **Injury** of glans penis
- ② **Abrasion** of External meatus Leading to ulceration.
- ③ **Haemorrhage:** mainly from Fraenular artery.



Operation (1)

Operations for Undescended Testis

Orchidopexy

* **Indications**

Surgical treatment is the only treatment of most cases.


* **Timing**

It is now regarded as acceptable to operate in the child's 2nd - 3rd year.

* **Anaesthesia**

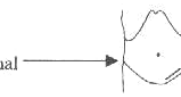
General

* **Position**

"Supine" 

* **Incision**

Inguinal incision to open the inguinal canal



* **Steps**

2 Steps : ↴

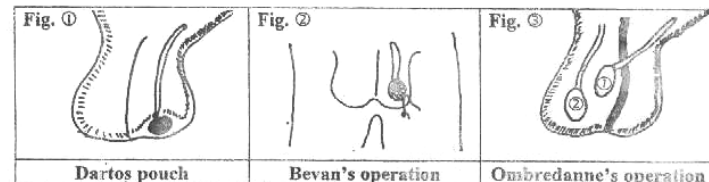
(A) Mobilization of the Vas deferens & Testicular vessels :

- Any Associated hernia is dealt with.
- Cord elongation by dissecting it high up and cutting any anchoring band.
- Inferior epigastric artery may be divided to abolish angulation of the vas around it.

The aim of the above mentioned steps is to gain length of spermatic cord & help testicular descent.

(B) Fixation & Retaining the mobilized testis in the scrotum :

- ① **Dartos pouch** : by putting the testis between the skin of scrotum & Dartos muscle see (fig. ①).
- ② **Bevan's operation** : A sitch is passed from the tunica albuginea to the skin of scrotum See (Fig. ②).
- ③ **Ombredanne's operation** : The mobilized testis is brought through an opening in the scrotal septum See (Fig. ③).



N.B. : Bilateral Arrested Testis :

Bilateral Orchidopexy is not recommended. So one side is done at a time & the other one after 6 months.

**Inguino-scrotal
Surgical Operations**

[Operations for Undescended Testis & Varicocele]

* **Management of Difficult Cases :**

The difficulty usually arises from short testicular artery. This can be dealt with by one of the following methods

① **Staged Orchidopexy :**

The Testis is brought down in more than one stage.

② **Fowler steven's operation :**

High division of testicular vessels provided that the testis is supplied also by the artery of vas.

③ **Micro-vascular Technique :**

Division of testicular vessels then anastomose them to inferior epigastric vessels using micro-surgery.

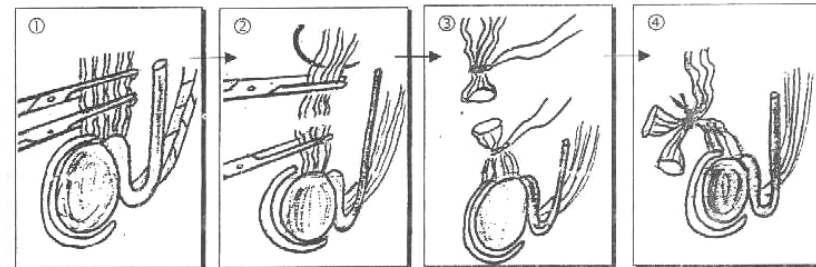
④ **Orchidoceliopexy :**

The testis is placed within the Abdomen, this is done if the other testis was removed and the mobilized testis can't be brought down to the scrotum.

[Operations for Varicocele]

(B) **Trans-fixation Ligation :**

- ① **The Pampiniform plexus** is exposed then the anterior group of veins are caught by **Kocker's** Forceps.
- ② **Trans-fixation** by (strong catgut) is done for both cut end.
- ③ **The venous plexuses** are **ligated** in between them.
- ④ **The 2 ligated ends** are tied together to elevate the Testicle.



⑤ **The Tunica vaginalis** is then everted why? To avoid post-operative (2ry) hydrocele.

Operation (2)

Operations for Varicocele

* **Indications**

- ① Large sized **painful** varicocele.
- ② Serious depression of spermatocoele (**oligospermia**).
- ③ **Failure** of medical treatment.

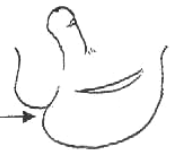* **Anaesthesia** "General or Spinal"

* **Position** Supine

* **Incision** 3 Approaches can be used :

[I] **Scrotal Approach :**

i.e. Through scrotal incision



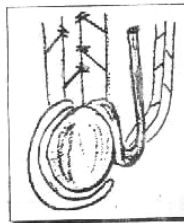
Steps (A) or (B)

(A) **Multiple ligation** (Delta operation)

- ① **The pampiniform plexus** is exposed, then the anterior group of veins are ligated at their junctions (**Delta points**)

N.B. : No veins are excised

- ② **The Tunica vaginalis** is then everted. Why? To avoid post-operative (2ry) Hydrocele.

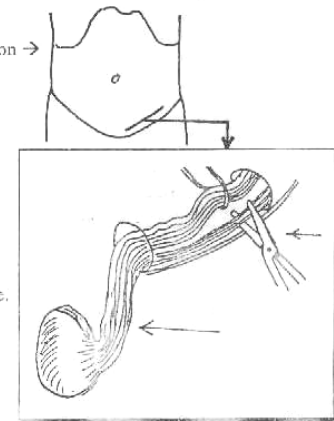


[II] **Inguinal Approach :**

i.e. Through inguinal incision

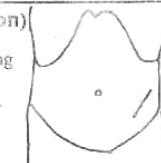
Steps

- ① **The Canal** is opened & **spermatic cord** is delivered.
- ② **The Vas & it's artery** with 1 or 2 veins are carefully separated from the main mass of dilated veins which are divided at internal inguinal ring.
- ③ **The Tunica vaginalis** is then everted. why? To avoid post-operative (2ry) hydrocele.



[III] **Pelvic Approach (Paloma's operation)**

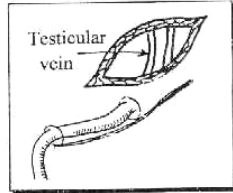
- i.e. Incision is made 3 cm above the level of deep ring
- * The E.O. Aponeurosis & the muscular fibers are separated



[Operations for Varicocele & Hydrocele]

Steps

- ① **The Peritoneum** is swept upwards.
- ② **The Testicular veins**, which at this level one or two in number are exposed & ligated.



SO **The Advantage of Paloma's Operation :**

No Fear of endangering the blood supply of the testis (even if the testicular artery is divided, there is still adequate blood supply to the testis through cremasteric artery & artery of vas, which can not be injured at this level.

Complications

- ① **Ischaemia of the Testis :**
If accidental ligation of both artery of vas & testicular artery.
- ② **Recurrence of Varicocele :**
Due to improper technique.



Operation (3)


Operations for Hydrocele

*** Indications**

The Ideal Treatment of 1ry vaginal hydrocele.

*** Anaesthesia** "General or Spinal"

*** Position** Supine 

*** Incision** **Transverse Scrotal incision** between skin vessels → 

*** Techniques**

- ① Eversion of the Tunica.
- ② Excision of the Tunica.
- ③ Plication of the Tunica (Lord's operation).

[I] Eversion of the Tunica :

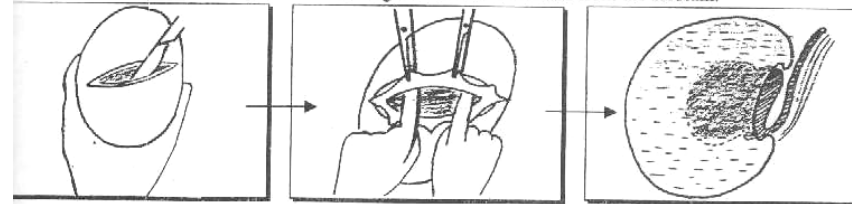
*** Indications**

- ① *Small* Hydrocele.
- ② *Thin* walled.
- ③ *Non* recurrent.

[Operations for Hydrocele]

*** Steps**

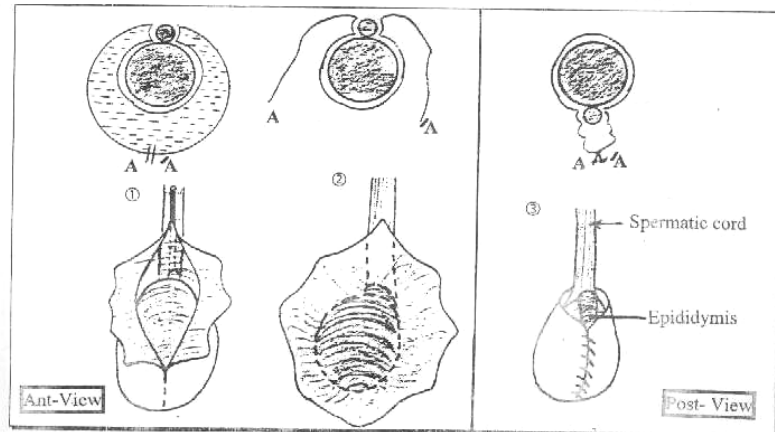
- ① **The Incision is Carefully deepened** until the Hydrocele sac is reached
- ② **A line of cleavage** immediately external to the hydrocele is found then followed in all directions & continued around the sac.
- ③ **Now**, The Hydrocele including the testis is enucleated from the scrotum.



- ④ **The sac** is incised & everted then sutured continuously behind the epididymis.
- ⑤ **The wound** is closed over a drain.

SO **The Aim of this operation :**

To bring the visceral layer of tunica immediately under the scrotum. Thus any fluid formed will be drained by lymphatics of the scrotum.



*** Post-operative**

- ① Removal of **drain** after 24 hours.
- ② Removal of **stitches** after 5 days.

[Operations for Hydrocele]

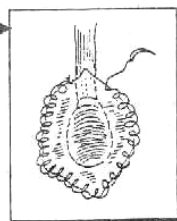
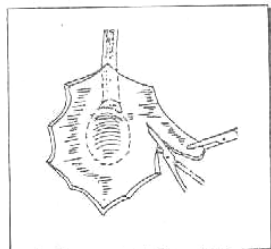
[II] Excision of the Tunica :

☆ **Indications**

- ① Large Hydrocele.
- ② Thickened, Fibrosed or Calcified sac.
- ③ Recurrent Hydrocele.

☆ **Steps**

- ①, ② & ③ As Eversion of Tunica.
- ④ The Tunica is excised closed to its reflection onto the epididymis and the bleeding points are secured then running continuous locking suture of fine catgut is then inserted all around the cut margin to reduce subsequent bleeding.
- ⑤ The wound is closed over a drain.



* **Post-operative**

- ① Removal of drain after 24 hours.
- ② Removal of stitches after 5 days.

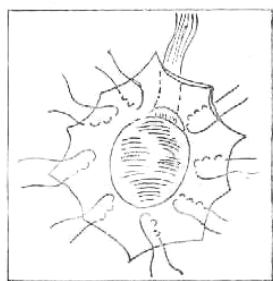
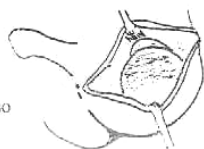[III] Plication of the Tunica (Lord's operation)

☆ **Indications**

NOW, the operation of choice when the tunica is not thickened.

☆ **Steps**

- ① A small incision is made through all layers, including the tunica.
- ② The Testis is allowed to prolapse through the wound so that the tunica is totally everted.
- ③ A series of 10 - 12 cat gut sutures are taken radially from the cut edge of the tunica to the reflection of the tunica from the testis and epididymis.
- ④ The Testis is pushed in.
- ⑤ The wound is closed without drain.



Advantages :

- No Tissue dissection.
- No Bleeding.
- No Reactionary oedema.
- No Recurrency.

Miscellaneous
Surgical Operations

Operation 1

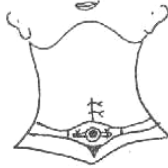
Tracheostomy

65

*** Indications**

[1] Upper Respiratory Tract obstruction:-

- **Congenital**: Congenital Laryngeal web.
- **Traumatic**: Injury to the larynx.
- F.B in the larynx.
- **Inflammatory**: chronic stenosis following T.B.
- **Neoplastic**: carcinoma of the larynx
- **Others**: Oedema of glottis 2ry to diphtheria



[2] Lower Respiratory Tract obstruction: i.e. Secretory obstruction

For repeated aspiration of secretions from Tracheo-bronchial Tree, if the patient can not get rid of it

- e.g ① Prolonged Coma.
- ② Paralysis of Respiratory muscles with
 - (a) Poliomyelitis.
 - (b) Diphtheria
 - (c) Myasthenia gravis.
 - ③ Severe Chest injuries e.g Flail Chest.

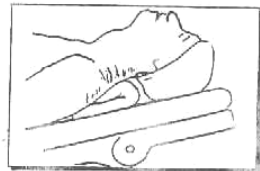
[3] Prophylactic i.e. No obstruction

As 1st step in extensive surgery of Mouth, Pharynx & larynx to prevent inhalation of blood during operation

*** Anaesthesia "General or Local" (1% Novocain with Adrenaline).**

*** Position** Same as for Thyroidectomy

*** Incision** Vertical midline in the Neck from cricoid cartilage to Supra. sternal notch, cutting. (a) Skin
(b) Platysma
(c) Deep fascia

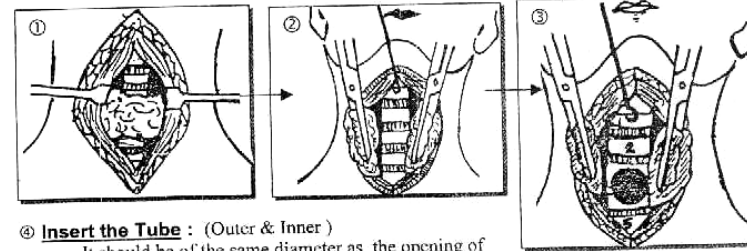


*** Steps**

- ① **The Pre-tracheal muscles are retracted** to the sides of incision exposing the isthmus of the Thyroid gland.
- ② **Divided the Isthmus** between 2 (Kocker's forceps) this will expose the Trachea.
- ③ **Open the Trachea** (between 3rd & 4th rings) After hooking the cricoid cartilage upwards to fix the Trachea

[Tracheostomy]

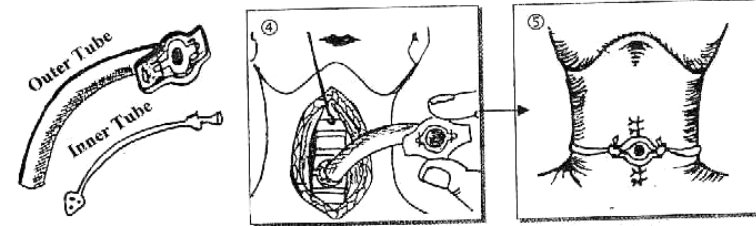
66



④ Insert the Tube : (Outer & Inner)

It should be of the same diameter as the opening of the Trachea to avoid air leak & surgical emphysema.

⑤ Close the wound: In layer around the Tracheostomy tube.



*** Post-operative Care**

- ① **Semi-sitting** position to avoid cough & choking.
- ② **Frequent suction** of secretions.
- ③ **Humidification** of inspired air avoid Tracheal irritation, simply by applying a layer of wet gauze at the opening of the tube
- ④ **The Inner Tube.** Should be washed by sodium bicarbonate/ 6h to avoid accumulation of secretions around it

Complications

- ① **Bleeding:** from divided Isthmus of the thyroid gland.
- ② **Wound Infection.**
- ③ **Surgical Emphysema** of Neck from air leak around the tube.
- ④ **Tracheal Fistula:** may persist after removal of the Tube.



Operation 2

Rib Resection

*** Indications**

- [1] **Disease of the rib:** Osteomyelitis, T.B or Tumors.
- [2] **To obtain a graft:** For mandibular reconstruction
- [3] **As a part of other operations**
 - e.g (a) Drainage of Empyema or lung abscess
 - (b) Exposure of kidney.
 - (c) Cervical Rib syndrome.

*** Anaesthesia** "General or Local"

*** Position** Supine 

*** Incision** In the same direction of the rib

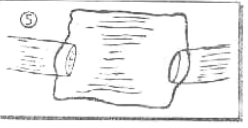
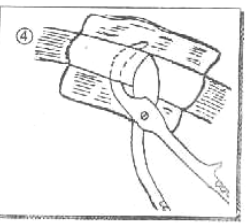
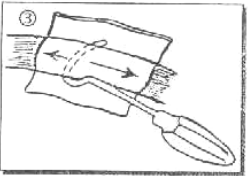
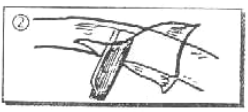
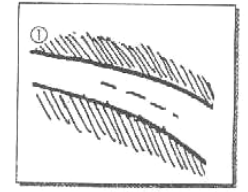
*** Steps**

- ① **The outer periosteum** is incised in the same direction.
- ② **The periosteum is stripped** by periosteal Elevator.
- ③ **A Doyan Raspatory** Is passed around the rib from below upwards. (to avoid injury of Intercostal Neurobundles) so the posterior periosteum is stripped also.
- ④ **The Rib which is non devoid** of it's periosteum is cut using **Rib Shear**.
- ⑤ **The Anterior periosteum** is then sutured & the wound is closed

N.B: **In cervical Rib** : Remove the rib with it's Periosteum to prevent it's regrowth

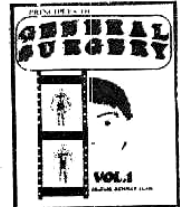Complications

- ① Injury to inter-costal nerves & vessels.
- ② Injury to pleura



Other Operative TALK

"See Surgical Notes"



(1) **GENERAL SURGERY VOL. 1**

*** Wounds :**

- Management of Lacerated wound in the forearm.
- Management of Lacerated wound in the calf
- Management of cut wrist.
- Management of stab wound in femoral Δ.

*** Plastic Surgery :**

- How to cover a skin defect

*** Breast :**

- Treatment of Mastitis & Acute Breast Abscess

*** Thyroid :**

- Treatment of 1ry & 2ry Toxic goitre
- Treatment of Malignant Thyroid

*** Ischaemia :**

- Management of Acute limb Ischaemia
- Management of Aneurysm

*** Lymphatics :**



- Management of Cold Abscess in the neck

*** Hernia :**

- Treatment of strangulated femoral Hernia

*** Head & Neck :**

- Principles of Treatment of Cancer Lip
- Principles of Treatment of Cancer Tongue



(2) **G.I.T SURGERY VOL. 2**

*** Stomach :**

- Management of CHPS
- Management of Duodenal ulcer
- Management of perforated P.U
- Management of Bleeding P.U

- Management of pyloric stenosis in Adult
- Treatment of cancer stomach
- * **Portal Hypertension :**
 - Management of bleeding oesophageal varices
- * **Spleen :**
 - Management of stab wound in Lt. Hypochondrium
- * **Liver :**
 - Management of stab wound in Rt. Hypochondrium
- * **Jaundice:**
 - Management of obstructive Jaundice
- * **Appendix :**
 - Management of Acute Appendicitis
- * **Large Intestine :**
 - Management of Colo-rectal Tumors
- * **Intestinal obstruction :**
 - Management of Ileo- Caecal Intussusception
- * **Small Intestine :**
 - Management of Imperforated Anus



(3) SPECIAL SURGERY VOL.3

- [I] **Urology :**
 - Management of Retention of Urine
 - Treatment of Urinary Stones
 - Management of Cancer bladder
- [II] **Orthopaedics:**
 - Management of # Clavicle, # Humerus & Colle's #.
 - Management of # Pelvis, # Femur & Pott's #.
- [III] **Chest Injuries:**
 - Management of (Sucking Chest Wound) open pneumothorax
 - Hemothorax
- [IV] **Neuro-Surgery:**
 - Treatment of Compound depressed fracture of parietal region.
- [V] **Peripheral Nerves:**
 - Management of peripheral nerve injuries

**With my Best Wishes
Dr. Wael Metwaly**