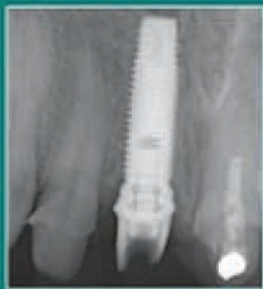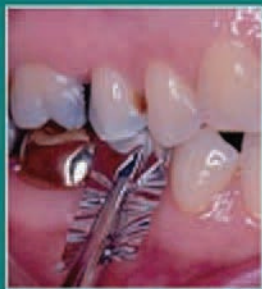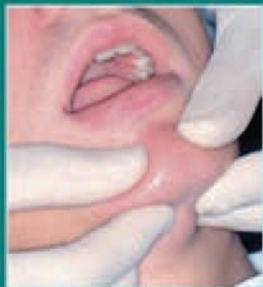


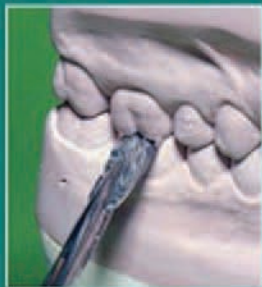SECOND EDITION

# Restorative Dentistry

An integrated approach

<http://dentalbooks-drbassam.blogspot.com>



Blackwell  
Munksgaard

**Peter Jacobsen**

# Restorative Dentistry

To Charlotte, Matthew and Christopher – may their dreams come true.

# Restorative Dentistry

An Integrated Approach

*Second Edition*

**Peter Jacobsen, MDS (Lond), FDSRCS (Eng), FHEA**

Reader in Restorative Dentistry, Division of Adult Dental Health,  
Wales College of Medicine, Cardiff University, Cardiff, UK;  
Honorary Consultant in Restorative Dentistry,  
Cardiff and Vale NHS Trust, Cardiff, UK

<http://dentalbooks-drbassam.blogspot.com>



© 2008 by Blackwell Publishing Ltd

Blackwell Munksgaard, formerly an imprint of Blackwell Publishing, which was acquired by John Wiley & Sons in February 2007. Blackwell's publishing programme has been merged with Wiley's global Scientific, Technical, and Medical business to form Wiley-Blackwell.

Editorial offices:

Blackwell Publishing Ltd, 9600 Garsington Road, Oxford OX4 2DQ, UK

Tel: +44 (0)1865 776868

Blackwell Publishing Professional, 2121 State Avenue, Ames, Iowa 50014-8300, USA

Tel: +1 515 292 0140

Blackwell Publishing Asia Pty Ltd, 550 Swanston Street, Carlton, Victoria 3053, Australia

Tel: +61 (0)3 8359 1011

The right of the Author to be identified as the Author of this Work has been asserted in accordance with the Copyright, Designs and Patents Act 1988.

All rights reserved. No part of this publication may be reproduced, stored in a retrieval system, or transmitted, in any form or by any means, electronic, mechanical, photocopying, recording or otherwise, except as permitted by the UK Copyright, Designs and Patents Act 1988, without the prior permission of the publisher.

Designations used by companies to distinguish their products are often claimed as trademarks. All brand names and product names used in this book are trade names, service marks, trademarks or registered trademarks of their respective owners. The Publisher is not associated with any product or vendor mentioned in this book.

This publication is designed to provide accurate and authoritative information in regard to the subject matter covered. It is sold on the understanding that the Publisher is not engaged in rendering professional services. If professional advice or other expert assistance is required, the services of a competent professional should be sought.

First published 2008 by Blackwell Munksgaard

ISBN: 9781405167994

*Library of Congress Cataloging-in-Publication Data*

Restorative dentistry : an integrated approach / Peter Jacobsen. – 2nd ed.

p. ; cm.

Includes bibliographical references and index.

ISBN: 978-1-4051-6799-4 (pbk. : alk. paper)

1. Dentistry, Operative.

[DNLM: 1. Dental Restoration, Permanent. WU 300 AR435 2008] I. Jacobsen, P. H. (Peter H.)

RK501.R473 2008

617.6–dc22

2007032687

A catalogue record for this title is available from the British Library

Set in 9/11.25pt Sabon by Aptara Inc., New Delhi, India

Printed and bound in Singapore by Markono Print Media Pte Ltd

The publisher's policy is to use permanent paper from mills that operate a sustainable forestry policy, and which has been manufactured from pulp processed using acid-free and elementary chlorine-free practices. Furthermore, the publisher ensures that the text paper and cover board used have met acceptable environmental accreditation standards.

For further information on Blackwell Munksgaard, visit our website:  
[www.dentistry.blackwellmunksgaard.com](http://www.dentistry.blackwellmunksgaard.com)

# Contents

<i>Contributors</i>	<i>vii</i>	14 Principles of Occlusal Management	143
<i>Preface</i>	<i>ix</i>	15 Fixed Prosthodontics – Crowns	157
<i>Acknowledgements</i>	<i>xi</i>	16 Colour and Aesthetics	175
<b>Section I The Patient</b>		17 Impression Materials and Techniques	187
1 The Patient – His Limitations and Expectations	3	<b>Section IV Fixed and Removable Prosthodontics</b>	
2 History and Examination	5	18 Diagnosis and Treatment Planning for Fixed and Removable Prosthodontics	199
3 Diagnosis and Stabilisation	15	19 Fixed Prosthodontics: Resin-Retained Bridgework	210
4 General Principles of Treatment Planning	25	20 Fixed Prosthodontics: Conventional Bridgework – Design and Planning	217
<b>Section II The Restoration and Its Environment</b>		21 Fixed Prosthodontics: Conventional Bridgework – Clinical Procedures	226
5 Applied Biology of the Teeth	35	22 Fixed Prosthodontics: Basic Principles of Implants	240
6 The Pathology of Caries and Pulpal Disorders	46	23 Fixed Prosthodontics: Clinical Aspects of Implants	249
7 The Periodontium in Health and Disease	56	24 Removable Prosthodontics: Partial Dentures – Design	263
8 Functional Anatomy of the Occlusion	62	25 Removable Prosthodontics: Partial Dentures – Clinical Procedures	273
9 Properties of Restorative Materials	74	26 Removable Prosthodontics: Complete Dentures	278
<b>Section III Clinical Management and Techniques</b>		<b>Section V Problems</b>	
10 Intracoronal Restorations	91	27 Tooth Surface Loss	295
11 Management of the Deep Cavity	107		
12 Root Canal Treatment	115		
13 Management of the Periodontally Involved Dentition	135		

28	Temporomandibular Dysfunction	302	30	Management of Failure in the Restored Dentition 2: Dentures	322
29	Management of Failure in the Restored Dentition 1: Fixed Restorations	310		<i>Bibliography</i>	329
				<i>Index</i>	333

# Contributors

**Robert Adams, MSc (Lond), MSurgDent, BDS (Wales), FDSRCS (Eng)**  
Specialist Dental Practitioner,  
Wilmslow, Cheshire  
Honorary Lecturer in Dental  
Implantology, Wales College of  
Medicine, Cardiff University,  
Cardiff, U.K.  
*Implantology*

**Martin Addy, PhD, MSc, BDS (Wales), FDSRCS (Eng)**  
Professor of Periodontology,  
University of Bristol Dental  
School, Bristol  
Honorary Consultant in  
Restorative Dentistry, United  
Bristol HealthCare NHS Trust,  
Bristol, U.K.

**John Moran, PhD, MScD, BDS (Wales), FDSRCS (Eng)**  
Senior Lecturer in Periodontology,  
University of Bristol Dental  
School, Bristol  
Honorary Consultant in  
Restorative Dentistry, United  
Bristol HealthCare NHS Trust,  
Bristol, U.K.  
*Periodontology*

**Alan Harrison, TD, QHDS, PhD, BDS (Wales), FDSRCS (Eng)**  
Emeritus Professor of Dental Care  
for the Elderly, University of  
Bristol Dental School, Bristol  
Formerly Honorary Consultant in  
Restorative Dentistry, United  
Bristol HealthCare NHS Trust,  
Bristol, U.K.  
*Removable Prosthodontics*

**Gavin J Pearson, PhD, BDS (Lond), LDSRCS (Eng)**  
Professor of Biomaterials in  
relation to Dentistry, Queen  
Mary Westfield College,  
London, U.K.  
*Dental Biomaterials*

**David K Whittaker, PhD (Wales), BDS (Manc), FDSRCS (Eng)**  
Emeritus Professor of Oral  
Biology, Wales College of  
Medicine, Cardiff University,  
Cardiff  
Formerly Honorary Consultant  
Dental Surgeon, Cardiff and  
Vale NHS Trust, Cardiff,  
U.K.  
*Oral Biology and Pathology*





# Preface

This book began life in the mid-1980s when three friends mused about the state of the world as they walked around a churchyard in Northleach, Gloucestershire, after a very good lunch in a restaurant long since gone. The product was ‘Conservative Dentistry – an Integrated Approach’ published by Churchill Livingstone in 1990. The intention of that book was to distil the essentials of the subject and merge them with the appropriate aspects of the supporting sciences to try to avoid the compartmentalisation of dental education and show the relationships that extend from oral biology, oral pathology and dental biomaterials into clinical practice.

The original book was expanded in the mid-1990s and was published as ‘Restorative Dentistry – an Integrated Approach’ by Butterworth–Heinemann in 1998. This book sold well but is now clearly past its sell by date – hence this new edition.

The new book embraces the new and, I hope, retains the old where this has been seen to be clinically successful and relevant to modern practice. The practice of dentistry has gone through many transitions in its history and the present time is no different. There is the saying ‘What goes around, comes around’ and this applies to dentistry too.

So, Dear Reader, please indulge this old man in the autumn of his career with a little time for reflection on the 20 years since his first book was published and the 40 years since he qualified.

A trip down memory lane into the textbooks and writings of the late Victorian era and early part of the twentieth century provides a fascinating historical perspective on what our professional forefathers thought and did. It may come as a shock to read that many of the principles we expound now were expounded then. Bridgework was taught as needing high standards of construction with an appreciation of the role of the occlusion and the need for sound abutments. Today’s strategy for the management of periodontal disease is the same as that practised in 1900 though the role of the occlusion in causing the disease, prevalent in the 1960s, has gone.

The overriding impression is that our forefathers were just as clever as us, sometimes cleverer, but they were restricted by their materials and equipment. Look at the Bing Bridge of 1868. It is instantly recog-

nisable as a resin-retained bridge with wings and a pontic but instead of being glued on, it was pinned on. There were no air turbines, no polymers; there were arsenic root fillings and poor local analgesics. In the early twentieth century, all the precision retainers we would recognise today had been designed for the then preferred ‘removable bridgework’.

As a student in the 1960s, I learnt the Baldwin technique of glueing in an amalgam restoration with a wet mix of zinc phosphate cement. What are the Young Turks doing now? – glueing them in with polymers.

The cycle of ignorant rediscovery continues. Fifty years ago deep caries was managed by superficial removal and then the placement of a tannic acid dressing to ‘harden’ the dentine. Six months later the tannic acid was removed and the tooth restored. Today we have the ‘new’ ‘stepwise’ excavation of caries.

The quest for aesthetic restorations has led to ‘amalgam-free’ dental practices and the prescription of polymeric composites for all intracoronal restorations. Milled ceramics with CAD/CAM technology have arrived together with durable adhesives. The Young Turks now reject dentine pins and post crowns – see one and glue one! How much longer will the principles of the preparation geometry of near-parallelism be taught for crown retention?

Endosseous implants represent the biggest development of the last 20 years. How long will it be before endodontics disappears? Crown-retained bridgework with its use of dubious abutments is also a candidate for the history books.

The practice of dentistry and indeed the teaching of dentistry is about managing transitions – silicates to composites, copper rings to elastomers, vulcanite to acrylic. But there is a need to beware of false dawns – the self-polymerising filling materials of the 1950s, the sandwich technique of the 1980s, multiple ‘generations’ of dentine adhesives, discarding gold inlays – and dental academics have to be conservative with a small ‘c’. It is no use allowing the Young Turks to take over with their revolutionary ideas only to find that 2 or 3 years of students have qualified not knowing techniques that turn out to be still fundamental; you cannot call them back and start again!

Modern educational theory reveals the difficulty that all learners have in making links between ‘boxes’ of information that are actually connected but are taught in ‘modules’. This problem is compounded by the modular style of education now provided in most schools in the United Kingdom. Dentistry, of course, has a multitude of these boxes and it seems to be taking longer for students to establish the links between the boxes – to ‘integrate’ the information. Students seem to finish one year of study and pass on to the next, consigning the first to the filing cabinet, without realising the importance of the ‘continuum of dental education’.

The ‘Integrated Approach’ attempts to develop the links that make for success in restorative dentistry.

This new edition of the book tries to balance the old tried and tested with the new kids on the block. It tries to hit the moving target of developments in materials without losing the basic techniques that have served our patients well and will continue so to do. The days of molar endodontics and conventional bridgework may be numbered but until many more dentists are trained in the use of implants, messing about up root canals and trying to cut parallel-sided preparations will still be required.

*P.H.J.  
Cardiff 2007.*

# Acknowledgements

Many people, friends and colleagues have helped in the gestation, writing and production of this book and its predecessors.

My sincere thanks are due to all the specialist contributors. To Alan Harrison and David Whittaker for the chapters they wrote for the first edition which have stood the test of time and needed little change. Thanks to John Moran for revising Martin Addy's chapters. I welcomed our implantologist Robert Adams to the team and thank him for suffering the indignities of being 'integrated'. Lastly, to my dear friend Gavin Pearson, who has been a stalwart supporter, adviser and co-conspirator for more years than we both want to remember, my sincere thanks not only for updating the biomaterials text but also for his personal support and advice.

Mr Frank Hartles and the staff of the Audiovisual Aids Unit at Cardiff have contributed greatly through the clinical photographs and the new artwork – in particular Mr Sam Evans and Miss Ruth Bowen deserve a personal mention and thanks. Artwork from

the first edition was done by Mr Peter Cox, freelance Medical Artist, and by Mrs Jo Griffiths and I thank them again for their efforts.

Within the clinical chapters, many of the cases illustrated are from my own clinical practice within the University Dental Hospital, Cardiff, and here I would like to emphasise the need for such cases to be planned and treated by the efforts of an integrated team. Without the skills and support of Mr Jeff Lock, Chief Dental Technologist, who has worked with me for over 20 years and seems to be able to see my crown margins when I cannot, together with a very large number of dental nurses, the quality of care that these patients received would have been considerably reduced.

The staff of Blackwell Publishing, particularly Miss Katrina Chandler and Miss Amy Brown, have assisted in the development and publication of the book.

Finally, all my undergraduates and postgraduates provided the inspiration to put this thing together (again) – I hope they like it.

*P.H.J.*



# Section I

## The Patient



"I'm ready when you are."

<http://dentalbooks-drbassam.blogspot.com>

# Chapter 1

## The Patient – His Limitations and Expectations

The provision of high-quality restorative dentistry depends upon the dentist:

- Making an accurate diagnosis
- Devising a comprehensive and realistic treatment plan
- Executing the treatment plan to a high technical standard
- Providing subsequent continuing care

There is a very strong tendency, particularly in the field of fixed prosthodontics, for the dentist to become over-interested in the technical execution of treatment. There is a vast range of materials and equipment to stimulate this interest and compete for his attention. It is perhaps inevitable that dentists can become obsessive about types of bur or root canal file, the pros and cons of various materials and the precise techniques of restoration.

This is not to decry such interest because a high standard of technical execution is essential for the longevity of restorations. However, technical execution must be seen in the context of the four-point sequence listed above. Without a sound diagnosis and treatment plan, even the best technical execution will be doomed to failure.

A major influence on the formulation of the treatment plan is:

### ■ The Patient (Frontispiece)

It is usually by his own volition that he seeks restorative advice and treatment, and he usually brings with him certain problems and limitations that influence treatment planning and the delivery of care.

Each patient also attends with strong preconceptions based on his previous experience of dentistry. This could be good or bad, with a single traumatic episode being able to reverse many years of cooperation. The patient will have some idea of what dentistry could or might do for him, and what he wants from his dentist. Some of his concepts could well be limited or unambitious, and education has a major role to play here. Conversely, sometimes his concepts could be over-ambitious, complex bridgework for instance,

and here re-education is often necessary to bring him down to the practical and feasible.

It might be that the dentist has the skills and technical facilities to perform advanced procedures, but before he puts bur to tooth, he must stop and ask whether this is really what *this* patient needs and wants. If the answer is no, then to proceed is an act of pure selfishness that might also be regarded as negligent!

Certainly the dentist may have certain treatment goals for all his patients – no pain or caries, healthy periodontium, complete occlusion – but the way in which he prescribes and delivers his care has to be tempered by the patient's aspirations for his own mouth and his readiness to accept care.

A prolonged treatment plan could be very inconvenient to a shift worker or to a mother with young children or those with no personal transport. It might create restorations that will be beyond the maintenance capacity of the lazy or disinterested, or those with inadequate washing facilities.

Perhaps the patient is a reluctant attender, extremely apprehensive of dental care and its possible discomforts, and will require some form of therapeutic help just to get the simple things done. The short, unambitious treatment plan is more likely to succeed here, and if the patient's confidence can be obtained, the more complex treatment could be provided later.

Advanced restorations require skill and facilities, and these have to be paid for, either by the state or by the patient. Both have limited resources and both deserve value for money. Committing resources to an ambitious treatment plan should involve judgement on the likely lifespan of the restorations in that



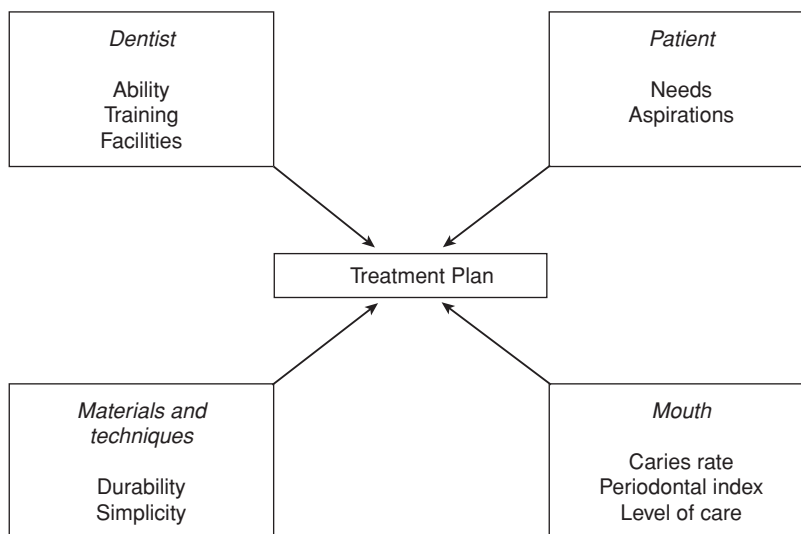


Fig. 1.1 Influences on the formulation of a treatment plan.

particular mouth and its conditions, and whether the expense is justifiable – *cost benefit analysis*.

The intra-oral conditions bring as much influence to bear. The caries rate, the number of missing teeth, the periodontal condition, the presence of dentures and the quality of previous restorative work all act as limitations to the scope of the treatment plan. All of us like to provide our best work for those who will appreciate it and look after it. Disinterest on the dentist's part is created by the appearance of large plaque deposits and evidence of little care.

The other side of the equation is what may be available and this relates to the dentist's skills and training, the materials and techniques at his disposal, and the facilities available for providing care (Fig. 1.1). These, in turn, could well modify or even dictate the patient's aspirations – a clean, well-equipped and efficient practice would indicate a good level of care to the average patient, whilst the reverse could well lower his expectations.

The dentist should offer only what is realistically available and work within his own limitations. It is certainly no disgrace to say that certain options are beyond your capabilities and it is possible to consider referral to an appropriate specialist. It could also be that the options the patient has aspirations towards are those with a lower success rate, and it is sensible to tell him this frankly.

There is considerably more awareness of the cosmetic possibilities of modern dentistry and thus demand for new materials and techniques. Much of this is expensive and has not been fully evaluated over a sufficient period for total confidence in its durability. The patient deserves a proper explanation about the reservations there are about particular lines of treatment.

The provision of restorative treatment is a complex arrangement wherein the patient, the dentist, the technical support and the materials must be in harmony to produce a satisfactory result. The limitations of one element will inevitably change the effects of the others. It is important to remember that the treatment is only as good as its weakest link – don't let that be you!

The key to success throughout is communication – listen and learn from what the patient says, explain what can be done for him, and then decide jointly on what should be done. If you are not sure, do not commit yourself, but delay the decision and take advice from your colleagues or even your local consultant.

This book begins by talking about how to find out what's wrong with the patient and what does he want done about it, coupled with the limitations the patient brings to formulating a treatment plan and then to executing it.

## Chapter 2

# History and Examination

It is very important to listen to what the patient has to say about his problems.

This aspect of care can be neglected in an obsession to 'get inside the mouth'.

The history is the basis for diagnosis and treatment planning – there is potential for harm to the patient if it is neglected.

The history should provide a clear account of the patient's experience of health care prior to the current attendance. It should establish an organised body of knowledge about the patient's dental past and his fitness to receive future treatment – it forms part of the rationale for his management.

The history, though, is very subjective and prone to differences in the perceptions and aspirations of the patient and the dentist. These differences may be reduced or exaggerated by the level of communication between the two, and the dentist must bear this problem in mind.

Clearly, it is the dentist's responsibility to create the right atmosphere for the patient to tell his story. The patient must be sitting comfortably in quiet surroundings and be confident in the dentist's sympathetic attention. He should be sitting upright, not supine and vulnerable, and facing the questioner with his eyes at the same level. This avoids the 'operating' position, with its overtones of discomfort and interrogation. The dentist should sit in front of the patient facing him, and not out of sight behind him.

The most limiting aspect of the history is that to a certain extent it is not strictly factual. It is the patient's perception of events or circumstances. Even items of medical history can be incorrectly remembered and misunderstood, and in difficult cases the patient's medical practitioner must be contacted for information.

The dental aspects are often muddled, particularly in the identification of a troublesome tooth in amongst 30 or so others.

The dentist has to sift this information and organise it, give it the weight it deserves, and then record it and draw conclusions from it. He has to pick up

inconsistencies in the story and use a systematic approach so as not to miss anything. However, he must beware of the too precise patient with an obsessively detailed history, which can be just as misleading or unhelpful as that provided by someone who is vague.

Patient's memories or understanding of previous treatment are often confused or just blank. Some may not remember having root treatment; the dentist just spent a long time fiddling with the tooth!

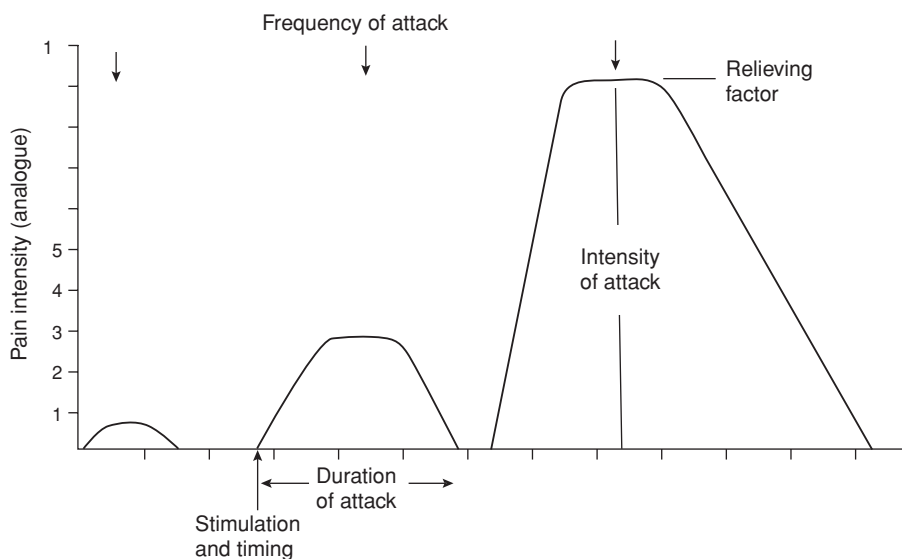
The history should be taken slowly, with pauses for writing in the notes; this helps the patient relax and lets further information come to his mind.

### Evaluation of Dental Pain

Of all the aspects of history taking, this is the one where a systematic approach is essential. The patient in pain can often be rambling and disjointed. The dentist must have a clear plan in mind and must bring the patient back to it by firm questioning.

The following questions are important:

- Where is the pain, e.g. tooth, gum, face, ear?
- Does it change position, i.e. radiate elsewhere?
- Describe the pain, e.g. throbbing, sharp, dull.
- How long has the pain been there?
- How strong is it?
- How long does it last?
- What brings it on?
- What takes it away?
- Does it come at any particular time day or night?
- How often does it occur?
- Is it getting worse or getting better?
- Are there any associated symptoms, e.g. swelling, bad taste?



**Fig. 2.1** Schematic characterisation of pain. The diagram shows the initiation of the pain, the frequency of the pain, its intensity, its duration and the effect of any relieving factors.

It can be useful to have the patient scale the intensity of the pain from 1 to 10 and give some pictorial representation of the intensity, duration and frequency of each attack (Fig. 2.1).

Do not lead the patient; questions should be phrased so that a positive reply, rather than a plain 'yes' or 'no', is required.

The description of the pain will lead to certain provisional diagnoses and also allow the exclusion of others.

### Pulpal disorders

The correlation of symptoms with actual pulp state is very poor. It is possible for several grades of pathology to be present within the same pulp. For instance, a single pulp could have an area of necrosis, an area of chronic pulpitis and an area of acute pulpitis (Chapter 6), but it would almost certainly be the acute pulpitis that provoked the painful symptoms.

So bearing in mind the pitfalls of the precise diagnosis, the following generalisations about symptoms can be made.

#### Physiological response

The pulp will respond to extremes of temperature through a sound crown, but the pain will be transient and stop as soon as the stimulus is removed.

When dentine is exposed by caries, trauma or simply gingival recession, then saliva and acid or alkali ions will reach the odontoblastic processes. The disturbance of the neutral pH will cause symptoms, usually of a transient and mild nature.

Temperature changes may stimulate pain, either when larger areas of cervical dentine are exposed or when caries has spread well into the tooth. However, the pain stops when the stimulus is removed, though in dentine hypersensitivity, the pain can be quite unpleasant.

Once toxins or bacteria reach the pulp, the symptoms become more severe.

#### Acute pulpitis

The symptoms are classically an intense throbbing pain, initiated by heat, sometimes relieved by cold, well localised to one tooth, though sometimes radiating to the ear from the lower molar region. The patient is kept awake at night, and standard analgesics are not very effective. It is usually episodic, with increasing frequency and intensity of each episode, until it becomes continuous. It stops when the pulp dies or is removed.

#### Chronic pulpitis/slow dying (moribund) pulp

This condition often produces no symptoms, but may give rise to vague, dull and diffuse pain along a

quadrant; i.e. it is poorly localised. Examination will often reveal several teeth with deep restorations, any one of which could be the cause.

### Apical infection

Chronic apical infection is usually symptomless – hence the need for continued radiographic review of root-treated teeth. Acute apical periodontitis usually creates an intense throbbing pain, not affected by temperature, fairly continuous, worse at night and initiated or made worse by biting or knocking the tooth. It is usually well localised, and percussing the teeth for diagnostic purposes is unnecessary (and cruel!). Routine analgesics are not very successful and the pain goes immediately the pressure within the bone is relieved, usually when the infection has caused perforation of the cortical plate followed by a soft tissue abscess, or sinus formation. If pressure builds again in the soft tissues, then a throbbing pain is again likely, but not as intense as that produced by the rigidly confined infection.

In the latter case, swelling will be an accompanying complaint.

### Periodontal disease

General acute conditions will give rise to generalised soreness of the mouth with perhaps ‘bleeding gums’, a ‘bad taste’ and ‘painful eating’ as accompanying symptoms.

Local conditions, such as pericoronitis or a lateral periodontal abscess, will cause more localised pain and soreness, particularly on eating.

Chronic periodontal disease is usually painless, but symptoms of bleeding or a bad taste are good indicators. Mild acute exacerbations sometimes occur as a result of occlusal trauma, and these cause vague diffuse pain, similar to the moribund pulp.

### Temporomandibular dysfunction and other facial pain

This is discussed in more detail in Chapter 28, but the clinician must be careful not to place the difficult diagnostic pain problem into this category for want of any better ideas! Remember that the *most common cause of pain* around the jaws arises from pathology of the pulp and the periodontal ligament (*odontogenic pain*) and these must be investigated first.

Derangements and inflammation of the temporomandibular joint can lead to pain that is localised to the joint area, sometimes felt within the external auditory meatus, and often accompanied by clicking or crepitus in the joint.

The more common symptoms arise from the muscles of mastication and give rise to facial pain and headaches. The pain is usually in the area of the affected muscles, though occasionally retro-orbital pain is described. The character of the pain is typical of all acute muscular problems – soreness, tenderness, difficulty with movement, and sometimes a clear starting point is remembered, such as a wide yawn, removal of wisdom teeth, etc.

Pain described outside the muscle areas may not be from temporomandibular dysfunction; for instance, the maxillary antrum sometimes produces overlapping anterior pain.

The most classic pain picture is that of *trigeminal neuralgia*, with its trigger zone and paroxysms of intense pain. However, this character can be modified into *atypical facial pain* that may be trigeminal in origin, psychotic or due to central nervous system lesions. Pain that crosses the midline is often psychotic in origin.

However, in all these cases, the purely dental causes must be eliminated first.

### Diagnosis of pain – summary

Obtain a full description of the pain; this will undoubtedly lead to an incomplete provisional diagnosis. However, an open mind is important until after the clinical examination, so beware of early categorisation of pain.

Caries tends to affect several teeth in the same mouth, and so these teeth could exhibit different stages of the pathology. Symptoms of each could co-exist in the same quadrant, and confuse the pain picture completely. Here, each facet of the symptoms needs to be dissected out, and analysed separately.

### Medical History

Information about the patient’s general health is essential for the planning of his dental care. Some medical conditions will influence the component items of a treatment plan or change its whole direction, whilst others will influence the way in which ‘normally’ planned care is delivered. This is discussed in detail in Chapter 4.

Past and present disease experience should be questioned together with information about current drug therapy. A structured series of questions is the most reliable way of taking a medical history (Table 2.1), but the questioner must be careful not to miss

**Table 2.1** Medical history taking

Have you suffered from:

- any serious disease?
- any heart or chest trouble?
- rheumatic fever, chorea, growing pains?
- pneumonia or bronchitis?
- jaundice, hepatitis?

Do you have:

- bleeding disorders?
- diabetes?
- epilepsy?

Have you ever had a blood transfusion?

Have you ever given blood, or been turned down as a donor?

Are you allergic to any drugs, antibiotics or any other substances?

Have you ever taken penicillin, and were you alright after?

Have you ever been in hospital or had any operations?

Are you taking any tablets or medicines at the moment (beware anticoagulants, steroids, drug abusers)?

Do you smoke or drink alcohol?

Have you been ill recently or consulted your doctor?

anything because the patient misunderstands or mishears the questions. The series of questions will need to be expanded if particular problems are evident from the history. For example, if the patient complains of soreness or ulceration of the mouth then questioning on possible causative or modifying factors must be explored. If there is any doubt about the patient's general health, it will be necessary to contact their general medical practitioner for information, particularly to ascertain whether the patient is suitable for the delivery of dental care without problems.

## Previous Experience of Dentistry

The patient's previous experience will condition him to expect certain things of dentistry in general. These could be good or bad. His attitude in turn is conveyed to the dentist, who may respond by tailoring the treatment plan to his perceptions of the attitude.

The patient may have high aspirations based on his previous experience, or vice versa. The dentist will judge the extent of the previous experience and may be influenced to continue the same basic pattern.

The important aspects to question are:

- Range of treatment experience
- Method of delivery of care, e.g. sedation
- Experience of analgesia/anaesthesia
- Prostheses: age, comfort, function
- General satisfaction with previous care
- Any particular problems

The answers will indicate any special needs, such as non-adrenaline containing local analgesic, use of sedation and so on.

The patient's opinion of his dentures will help the decision about possible replacement or relining (Chapter 24).

A patient dissatisfied with his previous care could continue to be dissatisfied, even if the new dentist provides the best care possible. Unfortunately, dentistry and plastic surgery attract perfection seekers!

## Family and Social History

The general home and work environment may dictate how easy or difficult it might be to carry out oral hygiene procedures or maintain a non-cariogenic diet. The home might also contain entrenched attitudes to dental care.

Work patterns – shiftwork, absences from home – or young children, may reduce the ability to attend for prolonged courses of treatment.

Anxiety and emotional problems can be initiators of stress-related facial pain and muscle disorders (Chapter 28).

## History Taking – Summary

The efficiency of history taking will be related to the confidence of the patient in the listening powers of his dentist and the ability of both to communicate with each other.

History taking should not be a rigid system of checklists, though there must be a consistent basis for the dentist's questions. The programme of questioning must be flexible and adapted towards the individual patient – it is *his* story.

## Clinical Examination

The clinical examination must establish the status of the oral tissues as a basis for diagnosis and treatment. It is important to observe and record health as well as disease, and to be as accurate as possible when doing it. These observations must be part of a continuing exercise that should be performed briefly at every visit, particularly over long courses of treatment – nothing remains static!

Comprehensive, sequential, up-to-date and easily read records are necessary to assess the progress of conditions, particularly when a preventive approach is being used, e.g. application of fluoride to early enamel caries. A brief scan of the records should re-inform the dentist of the patient's background at each visit. Many minutes spent thumbing back over old entries is wasteful, so updated summary sheets are essential.

Reviewing the summary sheets will provide the background for each visit and the decisions to be made as problems occur.

The examination begins as soon as the patient enters the surgery. How mobile is he, is he breathless, flushed? Does he look fit and alert? Does he appear nervous or apprehensive? This series of observations may give clues about the patient's attitude to treatment, motivation or an underlying medical condition.

An immediate *extra-oral examination* may be indicated if there is a facial swelling or if the patient

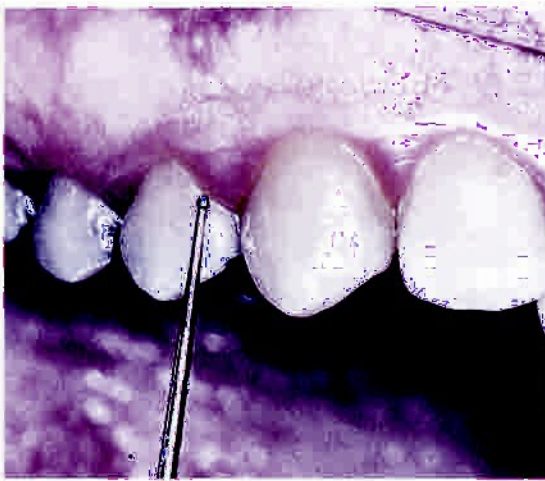has complained about tenderness in muscles or joints. However, in restorative dentistry, in contrast to oral surgery, all the important signs will be in the mouth. For example, routine palpation of lymph nodes is not useful when in many cases these may be enlarged from trivial facial infections.

*Intra-oral examination* should commence with a quick, general assessment of the condition of the mouth which will indicate the context in which the dentist will have to work. Is it clean and well maintained? Or are there large areas of plaque, open carious lesions and failed restorations?

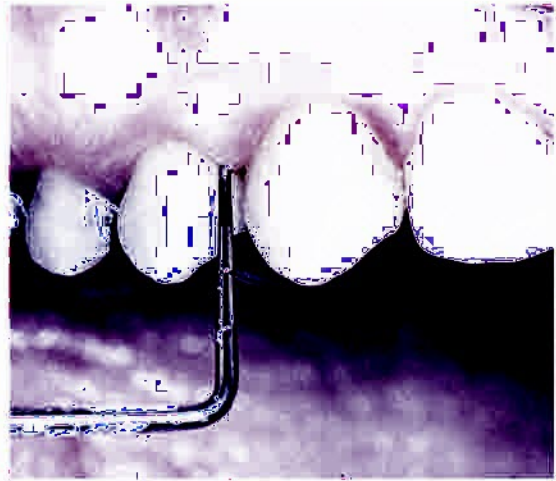
Then turn to the area of the main complaint, if the patient has one. Certainly if there is pain, then some form of stabilisation will be necessary that could be prevented if time is taken for a full examination first (Chapter 3).

*Soft tissues* should be examined, looking at their shape, integrity and colour. Look for swellings, ulceration, inflammation of all areas from the lips back to the fauces and pharynx.

The Basic Periodontal Examination (BPE) is an important and simple screening examination. (It was known as the Community Periodontal Index of Treatment Needs – CPITN.) The periodontium is examined with a World Health Organisation CPITN probe to determine pocket depth, bleeding response and to detect calculus. The probe is light with a ball tip of 0.5 mm diameter that is designed to detect sub-gingival calculus without penetrating the floor of the pocket (Fig. 2.2).



(a)



(b)

Fig. 2.2 The BPE examination: (a) the profile of the probe; (b) the probe inserted into a gingival crevice.

**Table 2.2** The Basic Periodontal Examination

Score	Tissue assessment	Probe appearance
0	Health	
1	Bleeding on probing only	The black band on the probe does not enter the pocket
2	Plaque retentive factor, e.g. calculus/restoration overhang	
3	Pocket 3.5–5.5 mm	The black band enters the pocket and is partly visible
4	Pocket >5.5 mm	The black band disappears in the pocket
–	No teeth present in the sextant	

In addition to these scores, the symbol \* should be added to the sextant score when there are clinical abnormalities such as furcation involvement, mobility, mucogingival problems or recession extending to the black area of the probe (3.5 mm or greater).

The mouth is divided into sextants, the gingival crevice of each tooth is examined in at least four sites and the worst clinical finding in that sextant is recorded as the code for that sextant.

If the probing depth is more than 3 mm and the probing is accompanied by bleeding, this would indicate *periodontitis*. The findings and clinical implications are shown in Table 2.2. Whilst this is a useful and easy system, it is limited in terms of overall treatment planning. It certainly records signs of existing pathology but the treatment plan can only be completed when the diagnosis is qualified by consideration of modifying factors. This is discussed in detail in Chapter 13.

Observations of plaque deposits may be recorded on a chart which is a useful baseline against which to judge success of oral hygiene procedures.

These observations may be summarised as an *oral hygiene index*. There are several oral hygiene or debris indices, but the simplest is that of Greene and Vermillion, which uses six teeth, an upper and lower molar on opposite sides, an upper and lower premo-

lar on opposite sides and an upper and lower incisor on opposite sides. Both lingual and buccal surfaces are scored by:

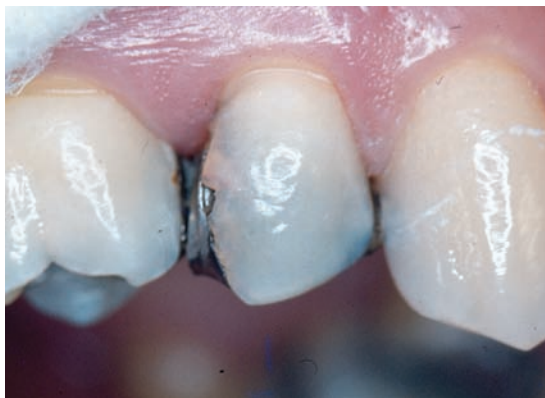- 0 = no plaque present
- 1 = plaque present on cervical third
- 2 = plaque present on both cervical third and middle third
- 3 = plaque present on whole surface

The index is the total scored divided by the number of surfaces examined.

The examination of the teeth for caries and restoration defects should be done after a thorough *prophylaxis* to remove stains and debris which would otherwise obscure observation. A dry field and a good light are traditionally necessary, but a probe should only be used with caution.

The probe should not be used to test a ‘sticky fissure’ since the application of pressure will simply break it down further. Occlusal caries should be diagnosed principally by appearance – darkness underlying the cuspal slopes – aided in the deeper lesions by radiography (see later). Additionally, transillumination is useful for unrestored teeth, and this technique can also reveal cracks in the enamel.

The margins of existing restorations are difficult to examine, particularly approximal, without using a probe, because such areas cannot be seen clearly and may be obscured by the restoration on radiographs. The probe must be used gently, though, to avoid creating a defect that did not exist previously (Fig. 2.3).



**Fig. 2.3** Recurrent caries around the distobuccal margin of the amalgam restoration in 5. This is shown by the fracture of the enamel margin and the white zone around the buccocervical corner.

The recording of caries and restorations is based on the use of the *dental chart*, which can easily become a static record. It is valuable as a record of the teeth and the planned restorations at the beginning of treatment, but as work proceeds, it becomes out of date. Periodic re-charting should be done so that there is not just a chart of the teeth some years ago, when the patient joined the practice, with line upon line of restored holes at each course of treatment, but a single current chart.

Detailed examination of the *periodontium* requires observation of gingival shape, size, texture and colour, and also crevice depth. Several indices have been developed for the assessment of the periodontium including measurement of plaque accumulation, gingival health, pocket depth, bleeding and treatment requirements.

Examination of the *occlusion* is discussed in detail in Chapter 14, but briefly, arch form, missing teeth and their effects, restoration of the occlusion by dentures, crowns and bridges should be assessed. Centric occlusion, centric relation and lateral and protrusive movements should be observed and noted, and where appropriate, a diagnostic articulated mounting should be used.

## Special Investigations

### Pulp sensitivity (vitality) testing

An indication of the condition of the pulp is of great diagnostic value, but the methods available fall very far short of the absolute. Most methods rely on nerve stimulation by electricity, thermal change or mechanical interference, but really the *vitality* of a pulp depends on its blood supply, which cannot be tested easily. Hence the change of term to *pulp sensitivity* which is the response elicited by testing.

Complications also arise because of the varying state of the tissues in a single diseased pulp. Multi-rooted teeth can have one root containing healthy pulp, and the other containing necrotic debris – a *false positive* could be recorded. Pus or inflammatory exudate in the root canal can conduct electricity and this is another reason for a false positive result.

*False negative* results can occur because the pulp is insulated by much secondary dentine, or where the enamel is unable to transmit the stimulus because of its thickness or its proximity to large restorations.

Teeth restored with insulating materials, such as ceramics or polymers, are also difficult to test.

*Electric pulp testing* passes a low current at high potential through the tooth. The current must have a square wave form because it must pass through enamel and dentine, which are relatively poor conductors, and reach the other side at sufficient potential to stimulate the nerves of the pulp.

Unfortunately, numbers are ascribed to the patient's response, and this gives the test more apparent scientific validity than it actually possesses. It really is subjective with a *yes* or a *no* as the response. The patient's expectation of the test influences the result, particularly if the sensation from the first, control tooth is very painful. A pre-emptive response is very likely in the subsequent tests.

Because false positive and false negative results are possible with electric pulp testing it should be complemented with *thermal tests* to increase the information available. Ice sticks, or ice crystals made by evaporating ethyl chloride from a large pledget of cotton wool, can be used but the amount of ice applied must be substantial to create sufficient temperature differential to affect the pulp. Because the tooth crown is a good heat sink, a small pledget of cotton wool with ice crystals may have no effect.

Hot gutta-percha or impression compound should be applied to a lubricated tooth surface to contrast with the cold results. Interestingly, the effect of heat is often less than that of cold since the temperature difference is larger when dropping from 37 to 0°C, compared to the rise from 37 to about 65°C.

The most reliable pulp test is the *test cavity*, and this can be done quite simply by starting a cavity in the tooth under test without local analgesia having explained the purpose of this to the patient; the dentist stops as soon as there is a response.

Non-operative pulp tests must be interpreted with caution, but they produce one more piece of the diagnostic jigsaw to be placed alongside the clinical examination and the radiographic findings.

### Blood tests

The oral tissues may be the first to reflect systemic disease and a full cell count and haemoglobin estimation may be indicated in cases of abnormal gingival inflammation to exclude blood dyscrasias such as leukaemia or anaemia.

Patients on anticoagulant therapy may require an international normalised ratio (INR) estimation prior to dental treatment that carries a risk of bleeding. Procedures such as scaling and polishing, root planing, infiltration analgesia and single extractions may be



done with an INR less than 4. Inferior dental blocks and multiple extractions carry the most risk and the INR level needs to be less than 2.5 for these. Changes to anticoagulant therapy should be done in consultation with the responsible physician. This, of course, requires support from the local hospital, and if this is not forthcoming, the treatment plan would have to be modified accordingly.

## Radiography

Radiographs are essential for proper diagnosis and treatment planning in restorative dentistry.

Three views are important: the orthopantomogram (OPT/OPG), the bitewing and the periapical. The information they provide is as follows.

### OPT

- General but *imprecise* scan of the teeth and jaws
- Buried teeth, roots and cysts
- Apical infection (sometimes)
- Existence of root fillings
- Temporomandibular joint (sometimes)

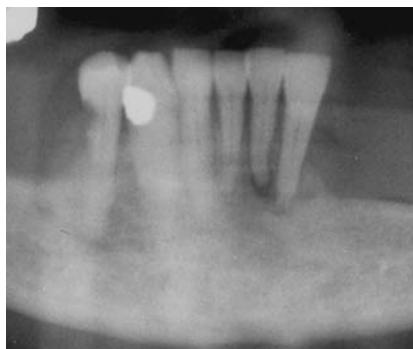
### Bitewing

- Caries: approximal and occlusal
- Depth of restorations
- Restoration integrity
- Interdental bone height
- Pulp chamber morphology

### Periapical

- Apical infection
- Integrity of root fillings and posts
- Interdental bone
- Root fractures and perforations
- Resorption
- Root canal morphology

The OPT has some value as a scan for *new* patients who have had considerable dentistry; patients often cannot say what type of treatment has been performed. However, the value of a repeat OPT at any time must be questioned. As will be discussed below, there are radiographs that give a better definition with lower exposure of the patient to ionising radiation. If the posterior region of the body of the mandible needs to be seen, then a lateral oblique film will provide a better image.



**Fig. 2.4** Part of an OPT showing an apparent apical radiolucency on  $\bar{I}$ . Root canal therapy was started on the basis of this film.

Only structures in the OPT *focal corridor* will be in focus and there may not be sufficient definition for the diagnosis of caries or for the accurate estimation of interdental bone height. In some areas, there may be masking of the root apices by overlapping structures, and occasionally apparent apical radiolucencies may be seen, which are just artefacts. Overlap of the vertebral column in the midline is a particular problem.

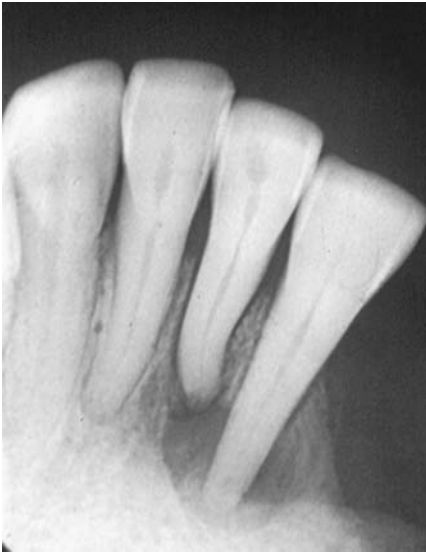In addition, because of variable image densities and the angulation of the beam in certain areas, dramatic misdiagnoses are possible. Figure 2.4 shows part of an OPT that shows a very precise radiolucency, apparently associated with the lower left central incisor.

Based on this film only, and without a vitality test, root canal therapy was started. The tooth was painful! An apical film was then ordered (Fig. 2.5), which suggests that the radiolucency is more associated with the lateral incisor than the central. The lateral incisor was vital to pulp testing.

The radiolucency is not ‘right’ for an apical area – it is round, not merging smoothly with periodontal space and is higher than it should be. A surgical exploration was undertaken and the radiolucency turned out to be a lateral periodontal cyst.

Clearly then, bitewing and the periapical films are required to investigate OPT observations and to show precise detail.

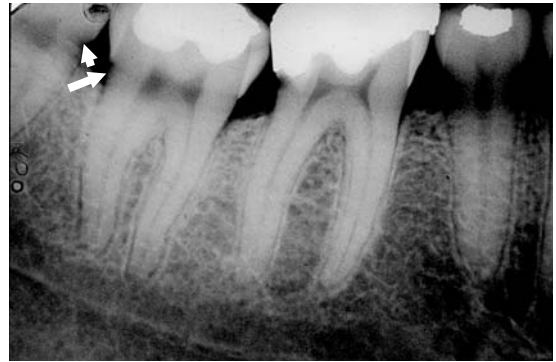It must be remembered that the radiograph is a two-dimensional picture of a three-dimensional entity and is dependent on mineral densities for its image. The depth of a carious lesion can be underestimated by as much as a third on a bitewing, and pulp horns can be superimposed on the caries, whereas they are actually in a different plane.



**Fig. 2.5** Apical film of the suspicious area in Fig. 2.4. The radiolucency is centred on the |2̄, not arising from the apex and turned out to be a lateral periodontal cyst.

Root concavities, particularly in the approximal cervical areas, maybe shown as apparent areas of demineralisation – ‘burn out’ (Fig. 2.6).

Angulation is critical for both films when assessing restoration integrity. Unless the X-ray beam is precisely aligned along a cervical margin, the restoration will obscure the margin and appear sound (Fig. 2.7). The periapical film taken using a film holder and beam-aiming device provides an image with mini-

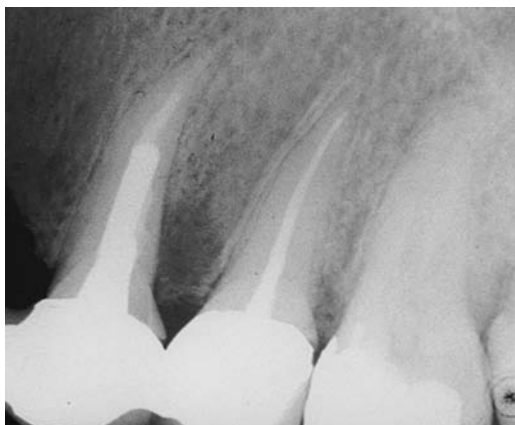

**Fig. 2.6** A periapical radiograph of |7̄6̄| showing cervical radiolucencies (arrowed) mesially on |8̄| and distally on |7̄| that are artefacts caused by the curvature of the teeth. Contrast these with the more clearly defined recurrent caries under the distal margin of |6̄|.

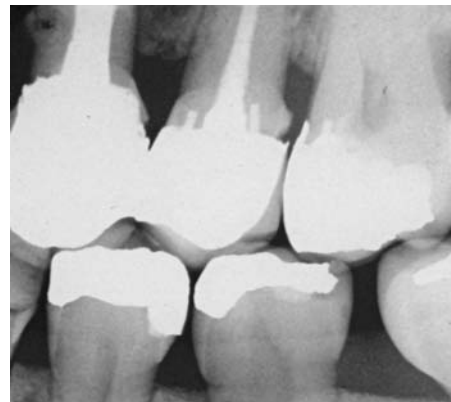
mal distortion which is not the case if the bisecting angle technique is used. Bitewing films provide good definition of the crowns of the posterior teeth.

All radiographic findings should be confirmed wherever possible by repeating the clinical examination with the films alongside. Thus cervical overhangs or apparent approximal caries should be confirmed by gentle probing.

Summary sheets for radiographs taken and their findings should be an integral part of the notes, allowing easy reference and review.



(a)



(b)

**Fig. 2.7** (a) Periapical film of |4̄5̄| taken using the bisecting angle technique showing a bridge retainer with apparently good adaptation at the distal margin; (b) bitewing film with its different angulation reveals a deficiency of the distal margin.

Of course, it almost goes without saying, that the quality of radiographs – both in the taking and in the

processing – has to be of the highest order for accurate conclusions to be made.

### **History and Examination – Summary**

The meticulous collection and collation of all the information provided by the history, clinical examination, special tests and radiographs should provide the basis for the diagnosis and the treatment plan, and the continuing care of the patient. There can never be enough information, but be careful about guessing or taking things for granted. With clinical experience this might be acceptable, but for precision, the information must be accumulated carefully and as fully as possible.

## Chapter 3

# Diagnosis and Stabilisation

The diagnosis is the key to proper treatment planning and therefore of primary importance in the care of patients. In many simple conditions it is too easy to jump from examining the mouth to items of operative treatment. This avoids the discipline of:

- Diagnosis first
- Treatment plan second

Without this discipline, the management of the complex case becomes impossible. Decide what is wrong first *before* you decide what to do about it!

The diagnosis is the summation and conclusions drawn from the assembly of all the separate pieces of information gathered from the patient's story, clinical observations, special tests and radiography (Fig. 3.1). It is an intellectual jigsaw puzzle that is completed as a list of pathological conditions and simple restorative disorders. Each piece of the jigsaw must be placed in its correct position to make the diagnosis (Fig. 3.2). However, in distinction from the conventional jigsaw puzzle there is no picture on a box for guidance and the incorrect interpretation of one or more pieces can create the wrong picture (Fig. 3.3).

The *aetiology* of each condition should also be established so that this can be eliminated, if appropriate, to prevent recurrence of the problem.

In some cases, it will be necessary to carry out some operative investigation, either to confirm a *provisional diagnosis* or to determine the actual diagnosis.

For example, a deep carious lesion will usually need to be opened and investigated to reveal its extent, and to detect the presence of a pulpal exposure. Planning the restoration of such a tooth before investigation would be premature.

*Stabilisation* is a series of procedures that is designed to control actively progressing pathology rapidly, to achieve:

- Pain relief
- Arrest of tissue destruction
- Final diagnosis
- The basis to plan the definitive management

The operative phase is instituted immediately, sometimes before the history and examination has been completed, so that no time is wasted in relieving symptoms. The treatment should be planned to be completed as quickly as possible and the procedures will be short and sharp, e.g. pulp extirpation, extraction.

## Diagnosis

### Caries

Some conditions are obvious; cavitation of the enamel coupled with a brown base and whitened edges usually means caries. Indeed, the jump from what is seen to the diagnosis is so rapid that the intermediate listing of physical signs is somewhat superfluous.

However, the aetiological factors may not be obvious. Is this one of many sites of primary caries, or an isolated recurrent carious lesion around a failing restoration? Is this the middle-aged onset of cervical caries with its problems of rapid spread, or just fissure caries, which in some population groups would hardly qualify for a raised eyebrow?

So the *caries rate* is important, and the *Decayed, Missing and Filled* (DMF) score helps reflect this. But also the number of *active lesions* must be considered as an indication of the severity of the current pathology. *Diet analysis* would be appropriate for many patients with a high active caries rate, in order to determine the aetiology.

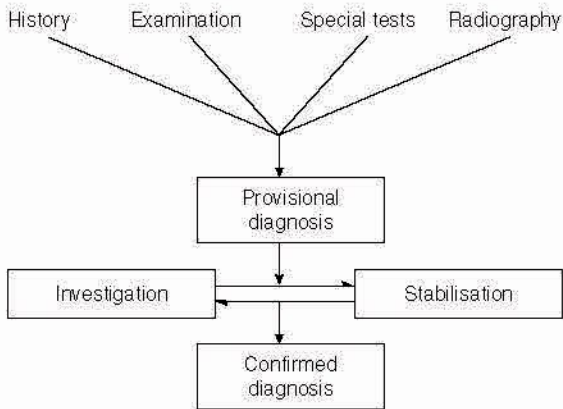


Fig. 3.1 The route to a confirmed diagnosis.

If it is an isolated recurrent lesion, this could be the result of operator error, and, if so, this must not be repeated on replacement of the restoration. Was it incorrectly sited margins, poorly finished enamel or the abuse of a matrix band? How deep has the caries spread around the restoration? Does the radiograph help, or is the lesion masked by the radio-opacity of the amalgam? Only removal of the restoration and the caries will answer this.

### Restorations

The faults that can be diagnosed with long-standing restorations are numerous. There could be corrosion, ditching and fracture of amalgam, or discolouration, marginal staining and surface loss of composite. There could be the technical faults of cervical

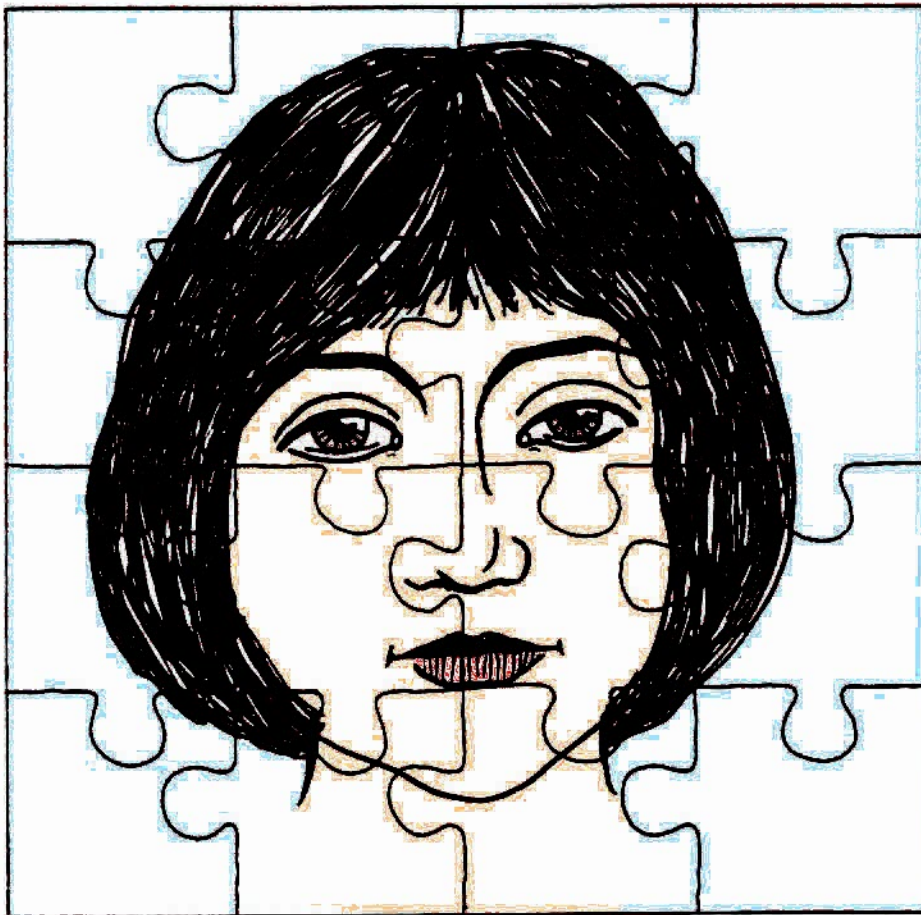



Fig. 3.2 The diagnostic jigsaw correctly completed.



**Fig. 3.3** An incorrect assembly of the pieces will lead misidentification of the diagnosis.

overhangs, negative edges, incorrect occlusion, poor shade matching and perforations.

Having identified the fault, however, there is one very important question to be answered – ‘Has the fault induced any pathology?’ The reason for the question is that some faults are just minor technical errors or normal material behaviour, and to replace restorations purely for these reasons would be wrong.

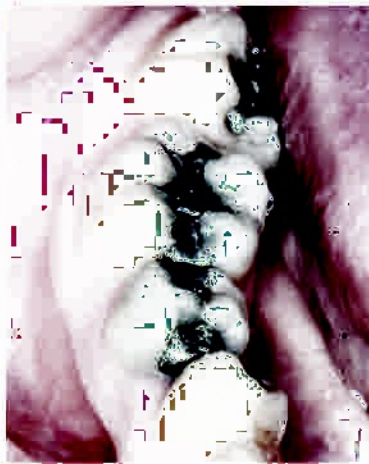
Where pathology is associated with the fault, then clearly something must be done. Figure 3.4a shows ditched and corroded amalgams, which are technically less than pleasing, but in the absence of a positive diagnosis of associated pathology, they should not be replaced. Contrast them with that in Figs. 3.4b and c, with its suspicious fracture line and underlying caries.

### Pulpal disorders

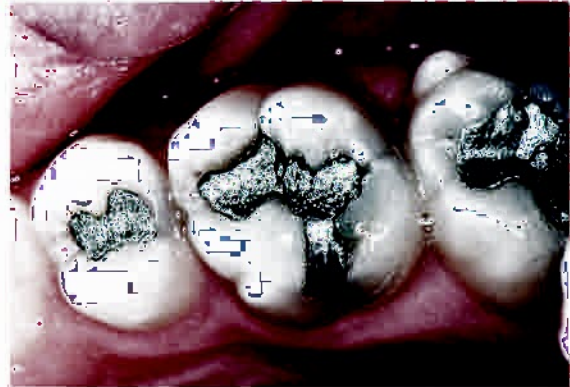
The history, pulp tests and radiography (Chapter 2) would have given some information about the possible state of the pulp. A deep carious lesion with no response to hot and cold, and electric pulp testing, together with apical radiolucency on radiograph, would lead to a certain diagnosis of *pulp necrosis* and *apical periodontitis*.

However, what about the painless deep lesion with an ambivalent pulp testing response and normal apical anatomy on radiograph? Here it would be appropriate to make a provisional diagnosis of *chronic pulpitis* to be confirmed or refuted by operative investigation.

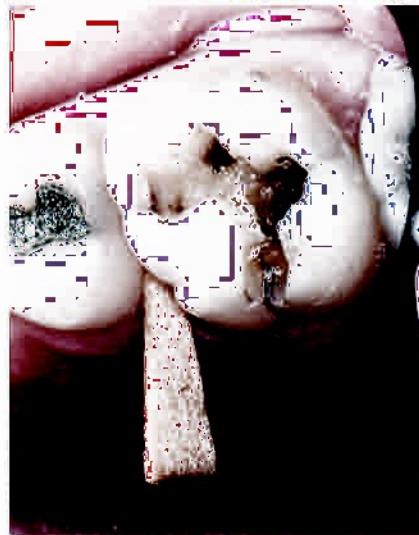Episodes of intense pain, localised to one tooth, with the pain lasting after the initiating stimulus



(a)



(b)



(c)

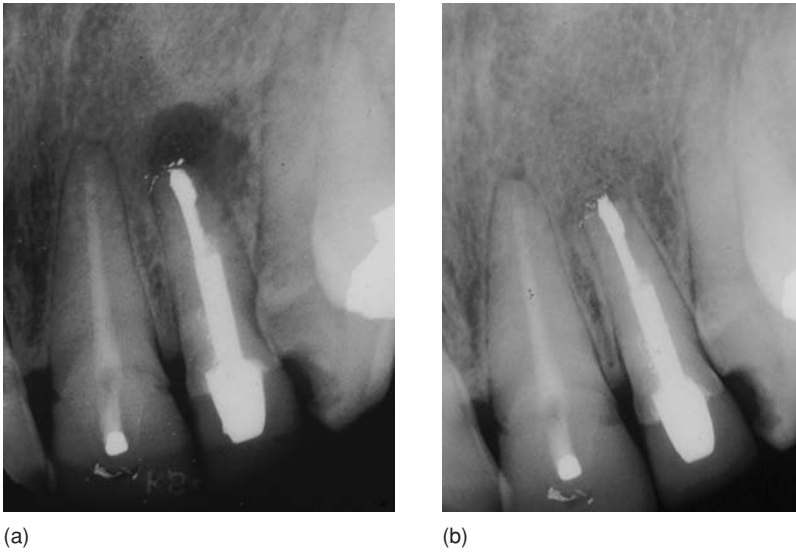
**Fig. 3.4** (a) Ditched and corroded amalgams, but still satisfactory restorations. (b) A ditched and corroded occluso-palatal amalgam, but with a central fracture in it. This is much more suspicious. (c) Removal of the amalgam revealed deep caries in two sites occlusally, together with a mesial lesion. The bitewing of this tooth (6), Fig. 10.12, was not very helpful.

has been removed, with normal apical radiographic appearance would suggest *acute pulpitis*.

### Apical conditions

The diagnosis usually relies on the radiographic appearance of a radiolucent area at the root apex. For differential diagnostic purposes, a negative response to pulp testing is necessary to eliminate neoplasia, such as cementoma, overlying fissural cysts or sim-

ply an anatomical structure, such as a foramen. If the tooth in question is already root filled, the diagnosis can be more difficult. Here, any symptoms and the history of the tooth would be important. Where the tooth is symptomless, an apical area may not be pathological, and serial radiographs are necessary to differentiate between a healing lesion and progressing pathology (Fig. 3.5). A static area may indicate healing by fibrous tissue without calcification that would not be infected.

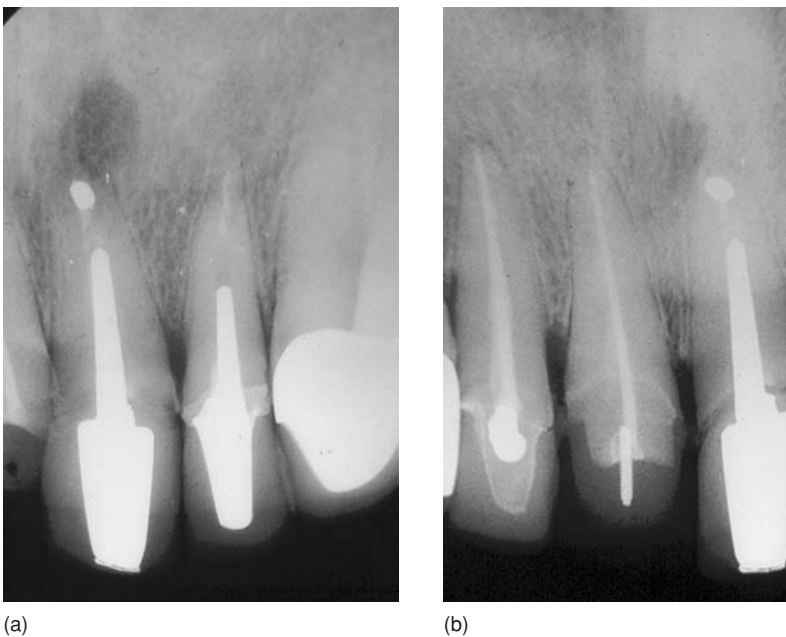

**Fig. 3.5** (a) Periapical radiograph of 12 immediately after apicectomy and retrograde root filling; (b) complete apical in-fill. This took 2 years and the decreasing area shown on films taken in the meantime must be distinguished from apical pathology.

If the history is not clear then the dentist is left to fall back upon his skill in radiographic interpretation. Figure 3.6a shows a central incisor that was apicected 18 months previously. The referring dentist thought that this was a recurrence of infection but there were no symptoms. The periodontal space should be traced around the tooth; does the radiolucency have its origins there? Does it blend with the space? Can the

periodontal space be seen ‘through’ the radiolucency; i.e. is there superimposition? The circular shape of the radiolucency should raise suspicion that it is a foramen. The second film (Fig. 3.6b) confirms that it is the incisive canal.

If there are symptoms, and pain on percussion, then *acute apical periodontitis* is the diagnosis. A ‘silent’ apical area coupled with a negative pulp test will be



**Fig. 3.6** The incisive canal masquerading as an apical area: (a) Radiolucency associated with a retrograde root filling; (b) second film at a different angulation reveals the true nature of the radiolucency.



*chronic apical periodontitis*, an *apical granuloma* or an *apical cyst*. The differential diagnosis between a granuloma and a cyst relies essentially on biopsy, as clinical and radiographic features do not distinguish them from each other.

### Periodontal disease

The complaint of ‘bleeding gums’, the signs of red-ened gingival margins with slight enlargement and bleeding on probing with no pocket formation leads to the conclusion of the almost ubiquitous *chronic marginal gingivitis*.

But the severity of this, together with the amount of *plaque* and *debris* present, must accompany the diagnosis. Is there *hyperplasia* present as well, or just enlargement due to inflammatory oedema? Is the aetiology just *poor oral hygiene*, or are there other local factors such as faulty restoration margins that prevent the patient cleaning efficiently? Could there be systemic disorders, such as blood dyscrasias, present that modify the tissue response to the plaque?

Where soreness and even pain accompany the redness and bleeding, then an *acute gingivitis* may be present.

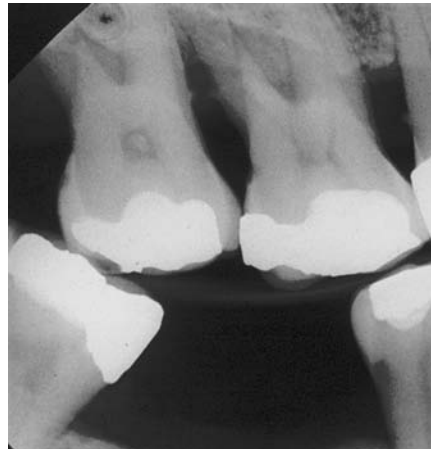A plaque index is essential to accompany the diagnosis. Simple disclosing and the scoring of the extent of plaque coverage as described in Chapter 2 provides a good baseline against which to judge improvements.

The presence of a pathologically deepened gingival crevice, a *pocket*, accompanied by bleeding on probing indicates *chronic marginal periodontitis*. Radiographs, particularly bitewings, may reveal *vertical* or *horizontal* bone loss caused by the inflammation. Vertical bone loss leads to the diagnosis of an *infra-bony pocket* (Fig. 3.7).

### Occlusal disorders

Impacted and malpositioned teeth are obvious diagnoses here. But also, the signs of occlusal derangement following tooth loss should be diagnosed. These are tilting, drifting and over-eruption of the adjacent teeth into the space, which, in turn, may bring pathology such as caries of approximal root surfaces, and periodontal disease from food impaction and plaque accumulation (Chapter 18).

The inefficient restoration of the occlusion by dentures or crowns and bridges should be diagnosed, and the effects of occlusal interferences noted (Chapter 8).



**Fig. 3.7** Radiograph showing an infra-bony pocket distally at  $\underline{Z}$ .

### Investigation of Provisional Diagnoses

The need for investigation in relation to the diagnosis of pulpal disorders has already been mentioned, but perhaps the most dramatic area where considerable investigation is necessary is the diagnosis of facial pain. Detailed descriptions of the various conditions is outside the scope of this book, but there is a considerable overlap of the symptoms of caries and pulpitis, and those of sinusitis, temporomandibular dysfunction, trigeminal neuralgia and atypical facial pain.

It is so important to remember that the most common cause of pain around the lower face and jaws is pathology of the teeth and periodontium.

The dying or moribund pulp can produce the quite atypical symptoms of diffuse pain, unrelated to any stimulus, and radiating to areas served by the trigeminal nerve of the same side. The pulp will often be covered by a large, radio-opaque restoration, quite impervious to X-rays, and impossible to examine by non-invasive vitality tests. Worse still, because of the nature of caries, several of these restorations may exist together.

It is essential that all these restorations are investigated thoroughly, before a committed diagnosis is made. It is very embarrassing to relieve long-standing facial pain by the extraction of a non-vital tooth, when the patient has been taking tegretol for several months!

After careful clinical examination, pulp tests and radiographs, the next step is to remove individual restorations. Clinical experience will tend to suggest

which teeth look suspicious, and which could be innocent.

The restoration removal can be started without local analgesia as a very reliable mechanical pulp test. Explain the purpose of this to the patient, and that an analgesic will be given as soon as any pain is felt. Inspect the pulpal aspects of the cavity carefully, and if no exposure is found and the tooth is vital, place a sedative dressing. If, on the other hand, an exposure is present then several different lines of treatment will be possible. These are discussed in Chapter 11.

## Stabilisation

### Caries

Figures 3.8a and b illustrate a case of so-called acute caries. There is caries in most teeth, with some extensive loss of dentine. It would be quite wrong to approach the definitive restoration of  $\overline{16}$  first, find a carious exposure, root fill it, and then construct a pinned core and a full veneer crown. Whilst this was being done, the caries in the other teeth would be spreading ever onwards. So stabilisation of the caries in the whole mouth is required.

The actual plan must be based on an overall assessment of the patient's expectations and the restorative possibilities. The extent of the caries does not reflect keen dental awareness! However, education is possible, if interest is there.

First of all, make an estimate of how many teeth could be restored simply, how many would require root canal therapy and how many would require crowns. Present this estimate and the implications of

time and effort to the patient, and await the reaction. A keen, motivated reaction would suggest opening, investigating and dressing all the lesions, stabilising the pulp as appropriate (see later) and extracting only those that turn out to be absolutely unrestorable.

A disinterested reaction, on the other hand, would lead to extraction of those teeth whose prognosis was not assured after simple restoration – i.e. those with deep lesions.

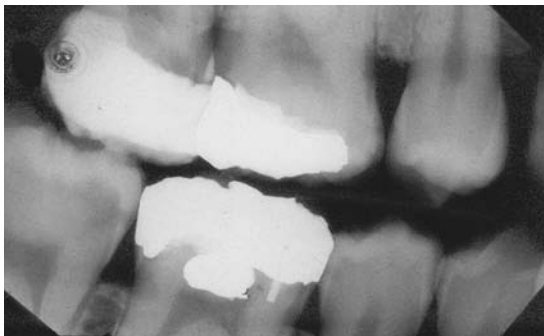### Acute pulpal and apical conditions

The most rapid and effective way of treating these is to extract the tooth. The pulp is removed, and drainage of an apical abscess is very clearly established by this procedure. However, if conservation of the tooth is indicated and root canal therapy is possible and it is restorable after such therapy, then rather different means must be used.

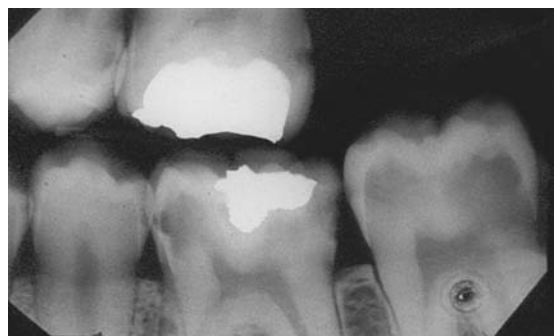### Acute pulpitis

This should be stabilised by pulp extirpation. However, this may not be straightforward, since local analgesia may be sometimes difficult to achieve. This difficulty may be related to the persistence of the pain stimulus altering the nerve impulse conduction and making blocking by analgesic more difficult.

The first approach is to repeat the local analgesic injection, but use a different agent. For instance, if xylocaine was given first, repeat with prilocaine. The two agents potentiate each other. If this does not work, apply a topical corticosteroid paste to the exposed dentine. This will reduce inflammation and ease pain, and in 48 hours or so the patient should return for another attempt under local.



(a)



(b)

**Fig. 3.8** (a) and (b) Bitewing radiographs showing extensive caries which requires stabilisation before definitive treatment is provided. There is deep primary caries in  $\overline{76}$ , recurrent caries cervically in  $\underline{76}$  and early lesions in almost all the other teeth.

Failing all these, the pulp will have to be extirpated under a general anaesthetic.

Ideally, the pulp should be extirpated from the full length of the root canal, so that remnants are not left behind to continue the pain. However, a diagnostic radiograph is necessary to assure this, and the duration of analgesia may not be long enough to allow it.

If only partial extirpation has been achieved, apply a topical corticosteroid as a root canal dressing and complete the extirpation at the preparation stage.

Total extirpation should be followed by root canal dressing with calcium hydroxide in propylene glycol.

### Apical periodontitis and apical abscess

This diagnosis presumes pulp necrosis and the presence of infection or leakage of toxins beyond the root apex. The canal must be cleared of debris and drainage established for the apical exudate, whose accumulation causes the pain.

If an abscess has formed, then cutting an endodontic access cavity will be rewarded by pus leaking from the tooth. Pain relief can be instantaneous. If no pus or exudate appears, then a barbed broach should be used, well short of the apex, to clear any obstruction. If drainage is still not achieved, then passage of a fine (No 8) file through the apical foramen must be considered. This diameter will establish drainage, but will not create the later difficulties in root filling caused by larger apical perforations.

The use of local analgesic should be cautious in the presence of acute inflammation. Restriction of the blood supply to the area could result in spread of the infection. Also, the analgesic may not be effective.

It is better to use an air turbine as much as possible to reduce vibration, and support the tooth, perhaps with a composition splint at the same time. Use a conventional speed handpiece to break the final half-millimetre or so of dentine overlying the pulp.

If an abscess has pointed in the sulcus, this should be incised. Hot salt water mouthwashes should be used to apply heat to the alveolus and drainage should be maintained by the patient sucking the tooth to keep the access clear.

### Systemic antibiotics

These should be restricted to cases where systemic involvement is apparent, i.e. raised temperature, malaise, tender regional lymph nodes, or there is some medical indication. In these circumstances, two high doses of oral amoxycillin are very effective; 3 G immediately and 2 G 24 hours later. Systemic antibiotics should be avoided wherever possible for local 'mechanical' problems where the bacteria are within

a root canal and sheltered from the blood and phagocytosis.

### Review

Open drainage through the root canal should be restricted to 24–48 hours. After this, more will go up the canal, than will come down. To complete the stabilisation, the canal must be fully prepared (Chapter 12). The reason for this is that the walls of the root canal will be infected (in contra-distinction to the acute pulpitis case) and simply irrigating and sealing the canal will not remove the infection.

### Traumatic injuries to the teeth

The immediate objective is the relief of pain and the procedure required will depend upon the site of any fracture and the state of the pulp. The pulp, however, can be concussed by a blow and may not provide a pulp test response for some weeks. Therefore, immediate stabilisation must be followed by review for definitive diagnosis and management.

A complete history is essential in case of future litigation regarding the cause of the accident. All teeth in the area of the trauma should be pulp tested and radiographed, and if there are any soft tissue lacerations and missing tooth fragments, the tissues should be radiographed also.

Where there is any doubt on the whereabouts of fragments, the possibility of facial fractures or any general injury, the patient should be referred to the local casualty department for complete investigation.

The treatment schemes for traumatised teeth are summarised below but for more detailed consideration the reader is referred to a specialised text.

### Enamel-only fracture

Small fracture areas can be simply smoothed, whilst larger defects, which may affect aesthetics or function, should be restored with acid-etch-retained composite. The teeth should be reviewed in 4–6 weeks and the pulp tests and radiographs repeated. Negative pulp tests may indicate that root canal therapy is necessary.

### Enamel/dentine fracture

#### Superficial

The tooth should be dressed with zinc oxide/eugenol cement in a temporary crown to aid pulp recovery. The crown must allow access to enamel for later pulp testing. If vital at review, then an acid-etch-retained composite restoration should be placed. Non-vitality would probably indicate root canal therapy.

**Deep**

This should be treated as if there was a pulp exposure.

**Enamel/dentine/pulp fractures and deep enamel/dentine fractures**

With these the pulp is unlikely to recover and the management depends on whether the root apex has closed or is still open.

**Root formation complete**

Conventional root canal therapy is indicated plus semi-permanent restoration of the crown, usually by composite. A post crown should be avoided if at all possible, especially for young patients playing contact sports.

**Root apex open**

Root formation should be encouraged to finish. If the pulp is vital, pulpotomy is used to remove the coronal pulp, leaving radicular pulp to continue root formation.

If the pulp is non-vital, the canal should be carefully filed short of the apex, and filled with calcium hydroxide in propylene glycol. This material creates conditions favourable for root formation.

In both cases, when the apex has closed, the canal should be root filled.

If the apex does not close, then root canal therapy should be done – this is technically difficult (Chapter 12).

**Root fractures****Apical third**

If symptomless and vital, leave and review. Otherwise, root fill to the fracture line and review. Remove the apical fragment if there is evidence of pathology.

**Middle third**

If the coronal fragment is mobile, it should be splinted to the adjacent teeth. In the absence of symptoms or pathology, it may be possible to place a post through both fragments to increase stability. If the fragments are not in line, this will not be possible, and the tooth should be root filled to the fracture line and reviewed. The fragment may need to be removed and it is possible to use a long post extending into the bone as an implant to increase the stability of the crown. The prognosis for the middle third root fracture is poor.

**Coronal third**

The prognosis depends on the extent to which the fracture goes beyond the epithelial attachment,

usually palatally. A very oblique fracture will be difficult to restore, and the tooth should be extracted.

A more shallow fracture would indicate root filling and the provision of a cast post and diaphragm to prevent root splitting later. The immediate stabilisation is to extirpate the pulp and provide a temporary crown. The easiest way to do the crown is to use the tooth fragment and to acid etch it to the adjacent teeth, over the sealed root access.

**Dislocation and avulsion**

The dislocated tooth can be repositioned and splinted for about a week. Pulp recovery is unlikely and the root canal treatment should be done whilst the splint is in place.

The avulsed tooth can be replanted, but the success of this depends on the length of time it has been out of the mouth and how it was stored during that time. Milk is probably the best storage medium, though a parent could keep the tooth in their own buccal sulcus to be kept moist by saliva.

Before replanting, the tooth should be washed in normal saline, but no other cleaning should be done. Splint the tooth in place and carry out root canal therapy whilst the splint is on. It is unwise to leave the root canal empty.

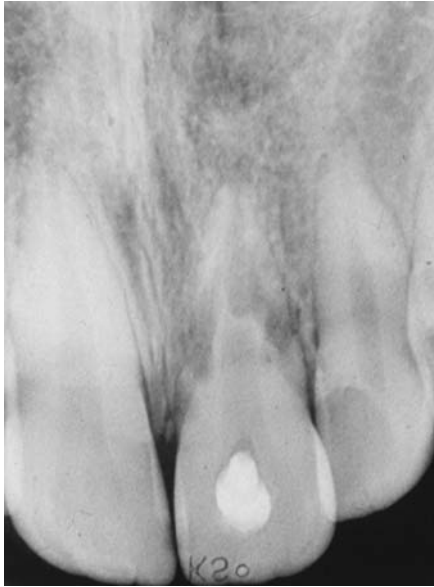Calcium hydroxide has been shown to inhibit external resorption, and this can be left in the canal for some time, with periodic replacement. The splint should be removed after a week.

**Review**

A traumatised tooth will require regular review by radiography, and if vital at the outset, pulp tests. Slow dentine formation can be induced by trauma, leading to the obliteration of the canal and difficult root canal therapy. If this is seen, the tooth should be root filled immediately whilst it is still possible. Late loss of vitality is also possible.

The other main complication of trauma is root resorption, either internal or external. Internal resorption is treated by removal of the pulp followed by root filling.

External resorption can sometimes be arrested by calcium hydroxide being placed in the canal. Hydroxyl ions diffuse to the outside of the root and raise the pH there. This seems to inhibit cell activity. As a sequel to the resorption, the periodontal ligament is replaced by ankylosis of the tooth to bone, and the tooth can remain firm for many years even though it

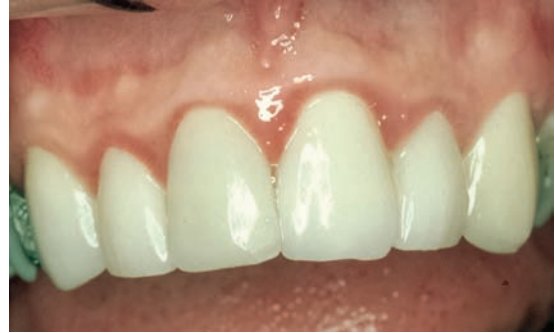

**Fig. 3.9** A re-implanted tooth showing external resorption. The tooth was symptomless and firm, suggesting ankylosis of the root.

has little root (Fig. 3.9). If infection supervenes, the tooth will require extraction.

### Acute gingival conditions and severe chronic periodontal disease

Acute gingival conditions should be treated by mouthwash and systemic antibiotics appropriate to the causative organism.



**Fig. 3.10** Chronic marginal gingivitis associated with crowns on 321|123. The crown margins must be corrected before the gingivae will resolve.

In the presence of severe chronic periodontal disease, most restorative work will be impossible because of gingival bleeding or exudate, or incorrect level of the gingival margin. Scaling and polishing, and instruction in oral hygiene are required first, followed by review. However, if the standard of the existing restorations is contributing to plaque retention, then the faulty ones should be removed, and well-fitting provisionals placed, pending resolution of the gingival problems (Fig. 3.10).

Intracoronary cavities can be provisionally restored with polycarboxylate cement, placed with the aid of a matrix, or even amalgam. This will provide the better gingival and contact area contour. Replacement of the temporary amalgams should be done after resolution of the soft tissue inflammation.

#### Diagnosis and Stabilisation – Summary

- Draw conclusions from the history and examination – the diagnosis
- If the data are inconclusive, make a provisional diagnosis
- Investigate to confirm the diagnosis
- Control active pathology as rapidly as possible
- When stable, draft the definitive treatment plan

# Chapter 4

## General Principles of Treatment Planning

Whilst making a diagnosis is an intellectual challenge, the formulation of the treatment plan has to combine experience, ability and common sense.

There is absolutely no use in compiling an elaborate and technically demanding series of procedures that is inappropriate for this particular patient, with this particular pathology in these particular circumstances.

Once the diagnosis is made, there may be two or three equally 'correct' treatments for the condition.

Making the decision as to which is appropriate is the skill of treatment planning.

### The Treatment Plan

The treatment plan is the basic blueprint for the delivery of care. It combines priorities for therapy with the organisation and management of that therapy. It must combine *prevention* of disease with the eradication and repair of pathology.

The treatment plan must fit the profiles of both the patient and the dentist (Fig. 4.1). As was discussed in Chapter 1, the patient will have some ideas about his dental future, and the dentist will have some resources and technical skills at his disposal to fulfil treatment objectives.

Basically, the resources available, governed by the dentist and his techniques, should, through the medium of the treatment plan, match the resource consumption by the patient, governed by his expectations and his pathology.

Figure 4.2 projects the patient from diagnosis, through agreement and formal *consent* to the treatment and its delivery, to oral health and the very important concept of continuing care.

To a large extent, the left side of Fig. 4.1 will be dealt with in the succeeding chapters, and problems created by the patient himself will be considered here.

### The Patient's Influence on Treatment Planning

#### Motivation, expectations and availability

These go hand in hand – a well-motivated patient will almost always find a way to make himself available for treatment. A string of failed appointments belies initial protestations of interest and desire for treatment!

If there are doubts about the patient's commitment, then this should be reflected in a cautious start to the treatment plan. One or two visits to the hygienist followed by a short appointment with the dentist for a simple restoration and review of oral hygiene would be appropriate. Provided active pathology has been stabilised, then the weaker patient might well benefit from a repeated oral hygiene lesson, together with the message that unless oral hygiene improves, restorative work will not be started. Certainly, this must be the case prior to advanced restorations.

As was discussed earlier, the extraction of a tooth may fit a patient's expectations more than attendance for four or five visits for root canal therapy and a crown. It may be that the restorative treatment is well within the dentist's capabilities, but it will be

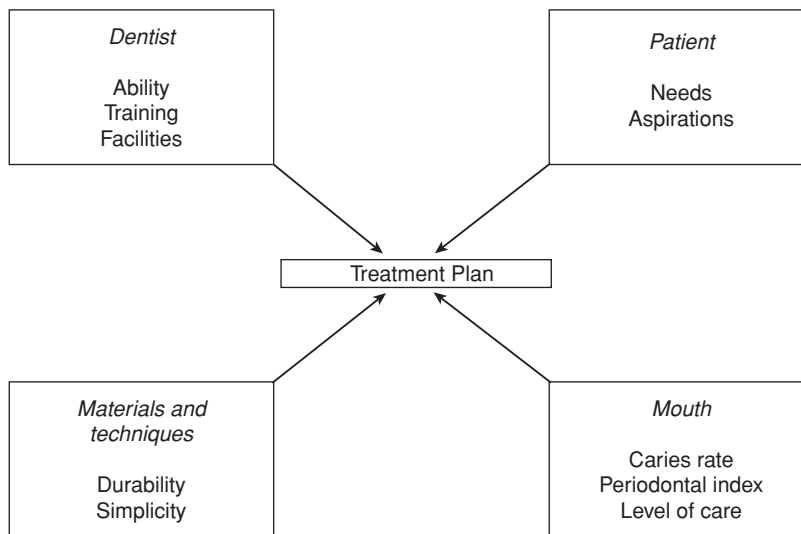


Fig. 4.1 The factors influencing a treatment plan.

somewhat wasted if the patient loses interest after the first hour, when the root canals were being identified. Of course, this is not to suggest that the dentist should not try to educate and inform about restorative possibilities. It could be that the patient never realised the scope of modern dentistry. However, initial enthusiasm must be maintained so that it is not just the product of the dentist's ambitions alone.

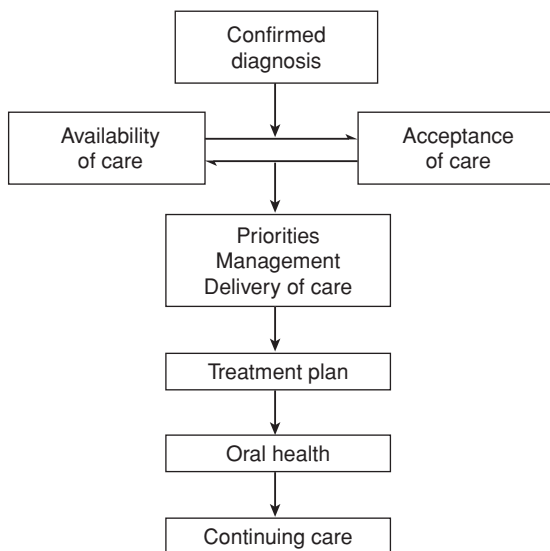


Fig. 4.2 The route to oral health and continuing care.

### Consent to treatment

As has been mentioned, there may be several ways in which a particular pathology could be treated or several methods for restoring or replacing teeth. Whilst the dentist might already have decided what treatment to recommend, for the patient to provide *informed consent* to treatment it is essential that he is made aware of and understands all the possible options that are available not only with this dentist but elsewhere as well. The patient must receive a full explanation of the advantages and disadvantages of the treatment options and their likely outcome.

### Apprehension

No one likes visiting the dentist, mainly in view of the prospect of minor surgery to a very tender area of the anatomy, but also because of the folklore surrounding the profession.

The majority of those who actually come for treatment are able to control their apprehension successfully, but a minority have tremendous difficulty. Often, their apprehension stems from a single unpleasant experience, perhaps as a child, and frequently pain from poor analgesia is remembered vividly. Many of these will respond to sympathetic listening, careful explanations about treatment, an unhurried, relaxed chairside manner and a great deal of patience – *tender loving care* (TLC).

Simple procedures with complete analgesia should be done first to establish confidence, and then more complex work may be possible. The more intractable cases may be candidates for:

- Oral sedation
- Inhalation sedation
- Intravenous sedation
- General anaesthesia

### Oral sedation

The use of a low dose of an anxiolytic drug may reduce mild apprehension so that dental care can be delivered normally. Diazepam is probably the most used and 5–10 mg the night before the appointment and repeated 1 hour before, having arranged the appointment to be in the early morning, is a suitable dosage. However, this must only be a short-term measure; the use of such drugs should be limited to the lowest possible dose for the shortest possible time.

### Inhalation sedation

This technique involves the administration of between 20 and 40% nitrous oxide together with a minimum of 30% oxygen. The level of nitrous oxide is set by observing the patient's response. Appropriate training and facilities are required and these are listed in the national guidelines cited in the Bibliography.

The operator must encourage and reassure the patient during induction and treatment. There is certainly an element of hypnosis in the procedure. Local analgesia must be used for painful procedures.

It is not possible to use inhalation sedation if the nasal airway is obstructed, the patient cannot lie supine or is in the first trimester of pregnancy.

### Intravenous sedation

A few patients are not able to respond to inhalation sedation, and for these the administration of a sedative intravenously is usually successful. Modern, short-acting benzodiazepines, such as midazolam, are very suitable for outpatient sedation. Midazolam has a very short half-life and therefore a short recovery period. It also induces amnesia, which can be very helpful.

The patient should not have eaten for 4–6 hours before the sedation is begun, but may drink small quantities after that. No alcohol should be taken, but regular medication should be taken as usual. Any anxiolytics will probably reduce the dose of sedation required.

The patient should be supine and the drug should be administered through an in-dwelling venous

cannula in the antecubital fossa, hand or forearm. The drug is injected slowly and carefully titrated against the patient's response; oversedation particularly with the elderly is a potential risk. Oximetry is essential to detect hypoxaemia that may result from respiratory depression. Again the reader is referred to national guidelines for further information.

Communication is important as the patient will respond slowly to command. Local analgesia is also necessary. If the sedation becomes less, then a further increment titrated against response should be given.

After the treatment is completed, recovery should be observed and the patient can go home escorted, when he is lucid and capable of walking unaided. The patient must avoid driving, sport and alcohol for 12 hours.

### General anaesthesia

Intubated general anaesthesia in day stay facilities should be reserved for those who cannot be treated in any other way. It may also be appropriate for stabilising urgent cases who will subsequently have definitive treatment under inhalation sedation.

It is really the last resort and is a compromise because of the limited time available – say, about an hour – and the difficult working conditions of an operating theatre. Only very basic conservation should be planned and any teeth of dubious prognosis should be extracted.

The patient should be screened by urinalysis and blood pressure determination to ensure fitness for anaesthesia. Haemoglobin estimation and blood count has been discontinued by most anaesthetists except where a general indication exists. The patient must be starved and not have any acute respiratory infections. Patients with medical problems should be admitted for observation before and after the anaesthetic.

Care must be taken during treatment not to flood the pharynx with water and to ensure that all pieces of tooth, amalgam, etc., are removed from the mouth.

The patient must be accompanied home and looked after for 24 hours. They should return for a normal outpatient appointment for review and occlusal adjustment of restorations, which is not possible in the theatre.

This review visit should also begin an acclimatisation programme to help the patient accept normal dental care. Many patients dislike the experience so much that they are very susceptible to conversion to less traumatic techniques.



## Age

Age per se has a limited effect on treatment planning. The young patient with an immature dentition would probably be unsuitable for conventional bridgework due to large pulps and a developing gingival margin. Playing contact sports would also hazard anterior crowns and bridges but such activity is not necessarily age related. Implants would be contra-indicated because of continuing bone growth.

In the older patient it is the combination of age with infirmity that limits the delivery of care. A fit 70-year-old could well have the same treatment as a fit 50-year-old. However, an unwell 50-year-old could well be more disadvantaged.

Having established this, there are changes in the dentition that will affect the incidence of certain pathologies and make some aspects of dental care more difficult. These changes are discussed in Chapter 5. Gingival recession, a predisposition to root caries and sclerosis of root canals are all problems that may influence the technical aspects of restorative dentistry. These will be compounded if the patient has already had a high experience of dental disease. It is more difficult to maintain an ageing dentition of complex restorations than one with no restorations at all!

An elderly patient may have more difficulty in performing oral hygiene procedures and this difficulty could be compounded by the presence of complex restorations provided in the past. He might not be able to tolerate long periods in the dental chair for complex care and will certainly have more difficulty in adapting to dentures (Chapter 26).

## The influence of medical history on treatment planning and management

The taking of the medical history and its importance was outlined in Chapter 2. Medical conditions may influence:

- The content of the treatment plan and/or
- The way in which care is delivered

For example, some conditions may indicate the extraction of a tooth rather than its restoration, whilst others may indicate that restorations, planned normally, are carried out under special conditions.

### Cardiovascular conditions

Probably the most confusion arises from the influence of a history of *rheumatic heart disease*. Transient

*bacteraemias* may lead to bacteria colonising scarred areas of the endocardium, usually the valve edges, causing *bacterial endocarditis*. Bacteraemias occur every day from chewing or defecation, and certain dental procedures may cause them.

The precise relationship between dental procedures and the development of bacterial endocarditis is still the subject of considerable debate. There are many patients who have had no antibiotic cover for many years of dentistry, including extractions, with no apparent ill effects.

The reader is advised to follow the nationally agreed recommendations which are to provide antibiotic cover for susceptible patients for dental procedures that carry a *high* risk of major bacteraemia. These procedures are:

- Extractions
- Scaling and polishing, pocket probing, root planning
- Surgery involving the gingival margin

There is currently no incontrovertible evidence that endodontic procedures are incriminated in the aetiology of endocarditis, though care must be taken to remain within the confines of the root canal. (This is true for all root canal therapy, anyway.) Suggestions that minor procedures, such as pulp extirpation, gingival retraction or placing a matrix band, are incriminated in the aetiology have been made. The supporting evidence for this is patchy and the provision of an appropriate antibiotic regime for multiple visits for routine dentistry is difficult. Such suggestions will encourage the continued misuse of antibiotics. In all cases, the gingival margins should be cleaned with an antiseptic, such as chlorhexidine prior to treatment.

The definition of the susceptible patient is more difficult. Not all patients who give a history of rheumatic fever will have scarred endocardia, revealed by the presence of a murmur. To prescribe antibiotics for these patients would appear to be wasteful, if not a further misuse of antibiotics. It is safer to request an opinion from a medical practitioner, preferably a cardiologist, as to whether cover is indicated.

Other cases where cover is definitely indicated are patients with:

- A previous history of endocarditis
- A prosthetic heart valve
- Congenital cardiac defects

These patients are at a *high risk* from endocarditis.

The regime for prophylaxis is based on the degree of risk and *any* recent therapy with antibiotics. The

current recommendations will be found in the British National Formulary (BNF).

All patients in the at-risk groups should be informed of the need to maintain good oral hygiene and those patients who are candidates for cardiac surgery should be well restored first.

### Treatment planning

The healthy patient with a history of rheumatic fever should be treatment planned as normal. The higher risk patient, particularly if there is a history of endocarditis, should be planned more radically, because the risks that are much higher. A tooth requiring a possibly difficult root filling should be extracted, and any areas of chronic infection should be regarded with suspicion, and the teeth not given the benefit of the doubt.

Other cardiovascular conditions may make prolonged courses of treatment risky or difficult. This group includes stroke and cardiac infarction. Full recovery from such an episode, of course, should bring no problems, though the dentist ought to be prepared for a recurrence in the chair and revise his management of collapse.

For those patients with incomplete recovery, treatment should be planned to be simple, and provided in short appointments. Blood pressure measurement before, during and after treatment is useful for the assessment of patient stability. The trauma from extraction should be avoided if at all possible.

Stroke patients with residual paralysis may need advice on oral hygiene aids, such as electric toothbrushes, to assist them. It will be sometimes necessary to train the patient's carer to perform oral hygiene procedures.

### Blood-borne viruses and the prevention of cross-infection

The two most important blood-borne viruses in dentistry are hepatitis B virus (HBV) and human immunodeficiency virus (HIV).

Patients who are ill with hepatitis B or AIDS should receive dental treatment under hospital conditions. Those people who are known to be infectious, but are well, may be treated in normal dental practice and should be treatment planned as 'normal'.

Many carriers are unidentified, and these are treated unknowingly as normal patients. These and the known ones constitute a combined hazard to the dentist and his staff, and to the patients following them in the surgery. The basic routine for the *prevention of cross-infection* should be applied to all

patients – *universal precautions* – and the recommendations are referred to in the Bibliography.

In brief, the key recommendations are:

- Protection of the operator and close-support dental nurse by gloves, masks and glasses or visors
- Decontamination and sterilisation of all instruments and equipment that have touched the patient or have been handled by 'contaminated' staff
- Use of single-use equipment wherever possible
- Use of precise surgery routines to avoid contaminating areas, such as inside drawers or the stock of temporary crowns, that will be difficult to sterilise later
- Clean contaminated surgery surfaces and protect them by using tray systems, towels and cling film
- Decontaminate items such as impressions before they are sent to the laboratory
- Decontaminate laboratory work before it reaches the chairside

### Other medical conditions

*General infirmity* or *terminal illness* would indicate a minimum of complex work being attempted. The plan should be to stabilise sources of pain and discomfort as simply as possible.

*Blood dyscrasias* and *diabetes* may give rise to gingival problems because of the reduced resistance to infection and these will preclude anything but stabilisation being carried out. The medical condition should be resolved prior to definitive conservation.

The operator would wish to conserve teeth wherever possible in *epileptics* to avoid dentures, in *haemophiliacs* to avoid extractions, and in cases with irradiated bone where post-extraction healing can be prolonged and difficult.

It is important to see patients before *radiotherapy*, whenever possible, to remove any teeth of dubious prognosis. There should be no exposed bone in the mouth prior to radiotherapy. After radiotherapy the dentist may have a role in advising on the care and management of mucositis, xerostomia and radiation-induced caries.

The management of *xerostomia* will involve advice on the elimination of anything that impairs salivation, such as alcohol consumption and smoking, use of sugar-free chewing gum and use of saliva substitutes containing fluoride.

Altered management of a normal treatment plan would be appropriate for a controlled diabetic, where treatment is best carried out immediately after a meal when the blood sugar is higher.

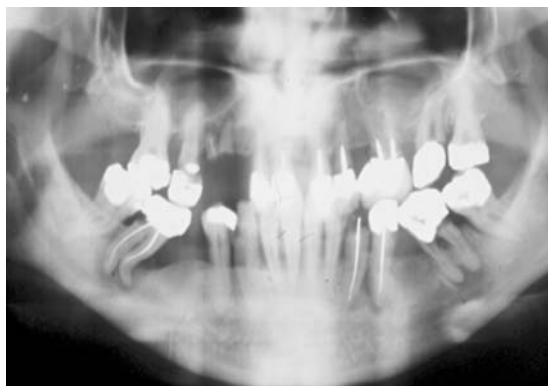
Patients having *orthopaedic joint prostheses* or *indwelling catheters* do not require antibiotic prophylaxis for dental treatment, provided there is no other indication for prophylaxis.

Restorative dentistry for pregnant patients requires some minor modifications. The generally held view is that invasive procedures are best avoided in the first and third trimesters, and radiography avoided totally throughout. However, where urgent treatment including radiography is required, this should be done in any event. It is also important to complete treatment and reach stability in the second trimester, so that treatment is not required later when the patient will be uncomfortable, or immediately after the baby is born, when the mother will have other priorities.

### Level of previous care

The well-restored and cared-for mouth encourages more of the same. It indicates the patient's desire for continuing care and his ability to maintain restorations in plaque-free and caries-free conditions.

Unfortunately, the quality of the previous restorative care, rather than its volume, can also modify a treatment plan. If the restorative work has not been provided to a high standard then, even though the patient has been a regular attender, the sheer volume of replacement work required may inhibit a totally restorative approach (Fig. 4.3).



**Fig. 4.3** Orthopantomogram of a patient who has experienced extensive restorative dentistry. There is now gross caries and periodontal disease. The chances of success for future work are small, and, in any case, the volume of work required is daunting. The patient was treatment planned for a clearance and full dentures.

Several missing teeth and a partial denture might well lead to extraction of a difficult restorative problem and its addition to the denture.

### Oral hygiene and periodontal disease

A high active caries rate may dictate extractions and simple restorations only, and generalised periodontal disease might indicate the same. Oral hygiene must be effective before advanced restorations are contemplated and the use of fluoride and chlorhexidine mouthwashes or gels may be of assistance.

### Occlusion

Evidence of deterioration in occlusal relationships following tooth loss would indicate bridges or partial dentures (Section IV). Inadequate occlusion on bridges or dentures might indicate their replacement.

### Radiographic findings

The major use of radiography is in diagnosis (Chapter 2). However, it is absolutely essential in the planning of endodontics. The presence of patent root canals, absence of obstruction by secondary dentine, pulp stones or curvature can only be decided by good radiographs.

Having diagnosed acute pulpitis clinically, the radiograph will lead the planner to contemplate root canal therapy, or to recommend extraction. It might be very desirable to save the tooth, but it might be technically impossible.

## The General Structure of a Treatment Plan

### Priorities

The simple treatment plan designed to treat chronic gingivitis, caries and failed restorations would begin by preparing the supporting tissues for restorative work – *scaling and polishing*, and preventing the recurrence of gingivitis – *instruction in oral hygiene*. This phase is better carried out by the dental hygienist or therapist, leaving the dentist free to perform more complex functions.

The priorities for simple restorations would relate to size, doing the largest first, unless the periodontium was being influenced by a poor contact area or overhanging margin.

Oral hygiene should be reviewed continually during treatment with encouragement, or further reminders if necessary. If advanced work – crowns or endodontics – is planned, this should be placed at the end of the plan after gingival resolution and the completion of simple restorations. Oral hygiene review should also be satisfactory.

Extractions are best regarded within the framework of stabilisation, since the affected teeth could give rise to pain whilst other work is being done. Also, there is the possibility of damaging new restorations during surgery, particularly of impacted teeth. If the patient is to be referred for oral surgery, then this should be arranged early, but almost certainly the work will not be carried out until after the general practitioner has completed other treatment. At the time the referral is made, it is important to include information on proposed treatment of other teeth, so that the referring practitioner's responsibilities are established.

Any surgery involving the gingival margin, e.g. apicectomy, should be done well in advance of crowns or veneers proposed for the affected teeth.

Partial denture planning should be built-in alongside the planning of restorations since the design may require rest seats, or specially modified crowns.

## Structure

A schematic arrangement for a treatment plan could be:

- 1 Prepare supporting tissues – scale and polish
- 2 Preventive measures – topical fluoride, fissure sealing, oral hygiene instruction, dietary advice
- 3 Design bridges or partial dentures
- 4 Large intracoronal restorations
- 5 Simple restorations
- 6 Root canal therapy
- 7 Review oral hygiene and periodontal condition
- 8 Periodontal therapy, if necessary – root planing, surgery
- 9 Crowns
- 10 Construct dentures/bridges
- 11 Recall and continuing care

## Review and Recall

The simple treatment plan has within its structure the review of oral hygiene procedures, but some other

procedures would require formal review prior to progress in treatment.

For example, apical surgery should not be followed immediately by crowns on the affected teeth. Two or three months should elapse whilst the gingival tissues stabilise and the margins reach a constant level, and an indication of apical healing is apparent.

Extractions and alveolar remodelling should be followed by review, perhaps 6 months later, before permanent bridges are considered.

The listing of a formal *recall* as part of the treatment plan is essential to indicate the responsibility for *continuing care*. The actual recall interval can be decided as appropriate to the patient's condition.

It is essential to perform a *risk assessment* and assessment of *prognosis*. What is the likelihood of further pathology or a failed restoration in the next 3 months, 6 months, 1 year or 2 years? When will it be necessary to see the patient again to monitor plaque control and caries status, and to check for other oral pathology?

Patients with poor plaque control and periodontal disease might be seen at 3-monthly intervals. Young patients with active caries might be seen at 6-monthly intervals. Older and well-maintained patients with good oral hygiene could be left to their own devices for as long as 2 years. A conscious decision must be made that involves the patient's understanding of the issues.

However, it must be remembered that risk can change with a patient moving from a low-risk grade to a higher one. Diet changes, such as starting to use sugar in hot drinks, will upset any previous risk assessment.

Radiographic review of crowns and endodontics is essential. Symptomless loss of vitality under a crown preparation must be detected by the apical condition changing. Progressing healing of an apical lesion following root canal therapy should be monitored. Symptomless crowns, endodontics and bridge retainers should have periapical films taken at about 1 year after treatment and 4-yearly after that.

Teeth with symptoms or signs of continuing pathology will need to be radiographed more frequently.

Again this is based on a risk assessment and the likely diagnostic yield of the radiograph, balancing the risks caused by the ionising radiation against the information that may be gleaned from the film.

### **Treatment Planning – Summary**

- 1 Decide on items for prevention and treatment
- 2 Order these according to priority in the patient as a whole
- 3 Consider the treatment methods that are appropriate:
  - for this patient
  - at this time
  - in this practice
  - with this dentist
- 4 Review oral hygiene and prevention
- 5 Recall to commit the patient to continuing care

## Section II

# The Restoration and Its Environment



# Chapter 5

## Applied Biology of the Teeth

The techniques for the restoration of tooth structure require a detailed knowledge of the tissues against which the material is to be placed. The purpose of this chapter is to describe the hard tissues of the human tooth and their relationship with their environment. The implications for restorative dentistry of enamel and dentine structure and pulp physiology are discussed.

### Introduction

Caries is a microbially initiated disease causing localised destruction of mineralised tissues in the body, including bone. For the purpose of this book only caries of the teeth will be considered and the signs of presence of the disease will be described as the localised destruction of enamel, dentine and more briefly, of cementum. As is the case with other pathological conditions, a clear understanding depends upon a knowledge of the basic structure of the tissues involved.

### Enamel Structure and Chemistry

Enamel is the outer protective covering of the crown of the tooth and is an extremely hard, brittle, white, shiny substance. It is composed basically of billions of crystals of hydroxyapatite that are roughly octagonal in cross section with a diameter of about 360 nm. The length of the crystals has proved difficult to determine but they are thought to be long and ribbon-like, extending for some distance through the enamel. The crystals are tightly packed together so that organic matrix lying between them is minimal, constituting only about 2% by weight of the enamel but much more than this by volume. Between the crystals are therefore micropores or pores, the size of which can be measured with some accuracy, and changes in these spaces is one of the methods of indicating the presence of carious attack. Under these conditions the enamel is said to have developed increased porosity. The methods available for such studies will be discussed in Chapter 6.

### Prisms

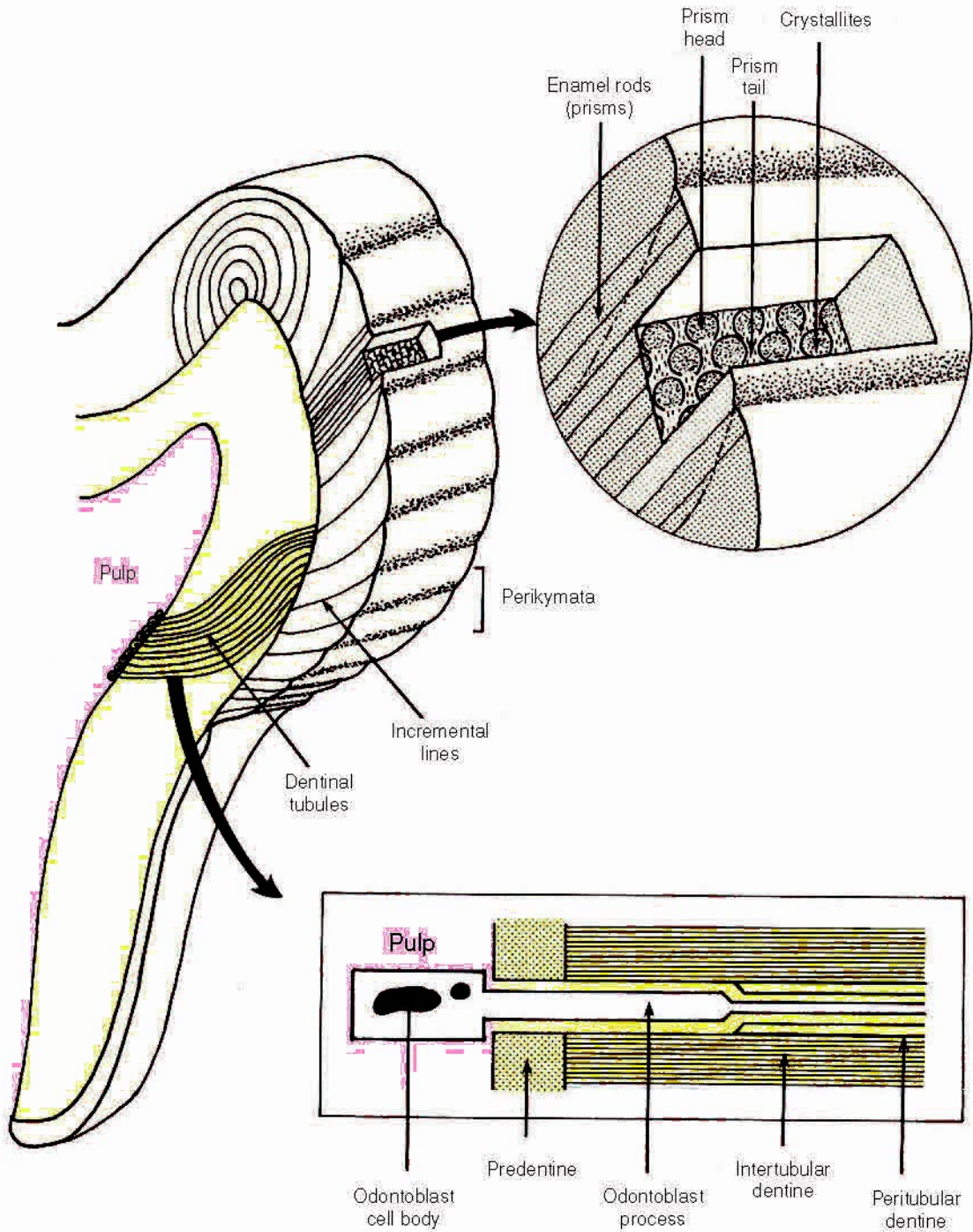
The crystals of enamel are not randomly arranged but are grouped together to form rods or *prisms* of material, extending from the enamel–dentine junction to the surface of the tooth. In the original English literature the preferred term is that of ‘prisms’ whereas in more recent writings the term ‘rod’ is preferred and in fact induces a clearer image of the structure in the mind of the reader. Because the remainder of this book will use the word ‘prism’, the old-fashioned term will be used here.

Each prism has a mean cross-sectional diameter of about 5  $\mu\text{m}$  but because the surface area of the outer enamel is greater than that of the enamel–dentine junction the prisms tend to increase in diameter from the junction to the outer surface. The cross-sectional shape of the prisms has been variously described as octagonal to fish scale or keyhole shaped but this depends to some extent on the angle of section through the prisms. The keyhole concept is the classical construction in human enamel and is shown diagrammatically in Fig. 5.1. The broad part of the keyhole is often referred to as the head and the narrow part as the tail. There is controversy as to what constitutes the boundary of each prism. Current research suggests that prism boundaries may be formed both by sudden changes in hydroxyapatite crystal orientation and by an increased concentration of *organic matrix*.

### Matrix

The nature of the organic matrix has received much attention but because of its small amount has proved difficult to analyse with certainty. In the immature tooth the matrix consists of two distinct proteins, amelogenin and enamelin, and during maturation





**Fig. 5.1** Schematic diagram of the structure of a tooth showing the main features of enamel and dentine.

much of the amelogenin is removed. The cells responsible for secreting and maturing the enamel during development are the *ameloblasts* and they migrate outwards from the putative enamel–dentine junction for a distance equal to the thickness of the enamel at that point on the tooth.

When the ameloblasts have completed their secretory activity, the final thickness of the enamel is determined and this cannot be altered throughout life, since the ameloblasts then degenerate. In principle, enamel is a dead tissue which cannot repair itself. However, we will see later that chemically speaking some repair or re-structuring of enamel is possible.

### Incremental nature

The enamel is laid down by the ameloblasts in increments, arranged rather like the layers in an onion over each cusp of the tooth. In cross section, these appear as concentric rings through the enamel and are known as *incremental lines* or brown striae of Retzius (Fig. 5.1). Each line represents the point that the ameloblasts had reached at a particular time in their functional activity. The incremental line is not pigmented as the name brown striae would suggest but is probably caused by a slight change in direction and diameter of the enamel prisms. These incremental lines reach the surface of the tooth at an acute angle and there is evidence that they modify the progression of caries in the natural lesion.

### Surface structure

Although the enamel prisms have been depicted as extending from the junction out to the surface, in practice this is often not the case. Many of the prisms in certain parts of the tooth and in certain teeth stop short of the surface. The surface layers of the tooth are therefore made up of *aprismatic enamel* that may have been produced because the activity of the ameloblasts changes before they cease secretory activity. Too little attention has been paid to this outer layer on the teeth and it is conceivable that it may be related to caries susceptibility and is certainly of importance when etching and bonding techniques are considered.

### Ionic exchange

Once the teeth have erupted, ionic interchange is possible between the crystals of the enamel and ions in the surrounding environment. For example, the calcium ions may be exchanged for strontium and the

hydroxyl part of the molecule may be replaced by fluoride which appears to protect the tooth against carious attack. Epidemiological studies have shown that newly erupted teeth may be more susceptible to caries than teeth in more mature individuals, so that great efforts are now made by restorative dentists to prevent so far as possible the commencement of carious attack which will become much less likely in the older individual.

## Morphology of Teeth

The overall shape and detailed morphology of the teeth varies considerably between teeth and even within tooth types. Thus, the incisors are quite different in shape to the canines, premolars and molars and in different individuals premolars may themselves vary somewhat in shape. These factors are important in restorative dental procedures and should be studied in greater depth in standard texts of tooth morphology. It is usual in current dental practice to distinguish to some extent between restorative procedures in deciduous teeth and permanent teeth and this is because there are structural differences between them, the most important of which are the relative size of the teeth, the thickness of the enamel and underlying dentine, the relative size of the pulp chambers which are larger in deciduous teeth and the bulbosity of the enamel of deciduous teeth at the cervical margin. However, there is evidence accruing recently that the structure of the enamel of deciduous and permanent teeth may differ and this may affect the rate of progression of caries. For instance, it has been shown using microradiographic techniques that deciduous teeth are somewhat less well mineralised than their permanent counterparts. This may account for their whiter appearance since more porous enamel tends to be less translucent so that the yellowness of the underlying dentine does not show through so clearly.

## Dentine Structure, Chemistry and Sensitivity

### Dentine

The bulk of the structure of the tooth, both crown and root, is made up of a less well mineralised but more flexible tissue known as dentine. This also is composed of hydroxyapatite crystals but in a less concentrated form than in enamel. The majority of

the crystals are arranged more or less parallel to the enamel–dentine junction but in the three-dimensional sense are much more random than those in enamel. They are laid down in a matrix composed of *glycosaminoglycans*, in which have been laid down *collagen fibrils* secreted by the odontoblast cells in their movement inwards from the enamel–dentine junction towards the future pulp. The matrix of dentine therefore consists of a rather dense, rubbery material, the general shape of which is retained even after removal by acids of all of the mineral component. Whilst caries of enamel results in cavitation and loss of the material, at least initially in dentine a rubbery, stained matrix may be retained for some time.

### Odontoblast processes

As the odontoblasts migrate inwards from the junction towards the pulp they leave behind them a cell process which becomes enclosed in a tubule incorporated into the matrix. The dentine is therefore permeated by millions of cell processes radiating out from the odontoblasts through the whole thickness of the dentine at least in the younger tooth. These processes may have side communicating branches so that a syncytium of cells is formed. When the dentine mineralises, crystals are laid down in the ground substance and fibres of the matrix but are not laid down in the cell processes. In the mature dentine, therefore, the cell processes are contained in mineralised tubules running through the dentine. With increasing age these tubules narrow by the deposition of mineralised material in their walls (intra-tubular dentine) and there is still disagreement as to whether mature dentine possesses viable cell processes throughout the length of its tubules.

### Dentinal tubules

Although these tubules radiate from the pulp to the enamel–dentine junction, they do not travel in straight lines. In the longitudinal plane they tend to follow a sigmoid curve from the outer dentine towards the pulp so that the cell body is placed more apically than the periphery of the process (Fig. 5.1). This arrangement has some clinical significance which will be discussed later.

### Mineralisation

Unlike enamel, dentine matrix does not mineralise as soon as it is produced. There is a delay between laying

down the matrix and its mineralisation in the form of calcospherites which finally coalesce to produce a more or less homogeneously mineralised tissue. In some parts of the tooth a failure in this fusion of calcospherites seems to occur. Firstly, in the coronal portion large non-mineralised, star-shaped spaces are left in many teeth following an incremental line below the enamel–dentine junction. These defects are known as *interglobular spaces* and the cell processes of the odontoblasts run straight through them. Their significance in relation to spread of caries is not known. At the periphery of the root just below the cementum, much smaller defects in mineralisation are observed, known as the *granular layer of Tomes*. No clinical significance has been ascribed to this structure.

### Secondary dentine

As the odontoblasts migrate pulpally they lay down the adult form of the tooth completing the root some 2½ to 3½ years after eruption of the tooth. If they were to continue at this rate of production of dentine then clearly the pulp chamber would be obliterated within a few years of establishment of the dentition. Once the mature outline of the tooth has been completed the odontoblasts slow down and although continuing to migrate inwards, do so at a rate enabling the pulp chamber to survive into old age. The dentine laid down in the initial stages of tooth development is known as *primary dentine* and that laid down after the odontoblasts have slowed is known as *regular secondary dentine*. As we will see in Chapter 6, the odontoblasts may change their rate of production of dentine and its type under the influence of carious attack.

### Dentine sensitivity

In order to enable dentine to react in this manner it must be responsive to outside stimulus and many patients who have suffered cavity preparation under inadequate anaesthesia will testify that this is the case. The exact mechanism is still not clear, largely because technical problems of fixation and examination of tissue remain unsolved. The pulp is well supplied by nerves, both non-medullated (controlling blood vessel tone) and medullated (capable of transmitting common sensation and pain). These latter nerves have endings in a plexus close to the odontoblast cell bodies and also have nerve endings on the cell bodies themselves. There is clear evidence that some of these nerve fibres extend some distance into the dentine and

have presumably been incorporated into it during its formation. About 1 in 2000 tubules appear to contain nerve fibres but only for quite short distances. It is interesting to consider that this so-called sparse innervation is probably greater than that found in the fingertips! As has been already stated, there is some doubt as to whether living odontoblastic cell processes extend throughout the thickness of the dentine in the mature tooth. If they do, then loss of enamel may result in osmotic changes at the peripheral end of the processes, thus resulting in fluid exchange and distortion of the processes. This event may be transmitted along the process and then converted by transduction into nerve impulses either at the inner third of the processes themselves or at the cell body region. If the cell processes do not extend throughout the thickness of the dentine then it is conceivable that fluid balance changes in the outer part of the tubules may initiate distortion of the processes resulting in impulses eventually to the nerve plexus.

## Enamel–Dentine Junction

The junction between the enamel and the dentine lies on the original basement membrane separating the enamel organ on the outside from the papilla or mesodermal tissue on the inside at an early stage of tooth development. In most human teeth it is not a flat sheet but is deformed into a crater-like appearance producing on section the appearance of scallops. The concavities of these scallops face towards the enamel and the convexities towards the dentine. That is to say the outer surface of the dentine, if the enamel were to be removed, appears like the surface of the moon with irregularly shaped craters. The inner surface of the enamel is composed of convexities fitting into these craters. This has the effect of increasing the surface area between the two tissues. In some parts of the human tooth, particularly near to the neck of the tooth, the enamel–dentine junction may be more or less flat.

## Smear Layer

During restorative procedures, removal of decayed enamel and dentine and extension of the cavity for prevention, retention and access may be carried out using hand instruments such as chisels and hatchets but is more commonly done using rotary instruments of various types and speeds. Rotating instruments

may result in smearing of the crystal and organic content of both enamel and dentine over the cut surface. This smearing may be a purely physical effect or may be engendered by heat at the point of cutting and grinding. Hand instruments, however sharp, may also cause heavy smearing on the enamel surface especially on the floor of an approximal box. The clinical implications of the smear layer will be discussed later.

## The Pulp

The pulp and the dentine cannot be separated either anatomically or functionally. Anatomically, the cell bodies of the dentinal processes lie in the peripheral region of the pulp and the *odontoblast cells* and their processes are therefore intimately associated both with dentine and pulp tissue. Functionally, the reaction of both dentine and pulp to external stimuli is dependent upon both the cell processes and bodies of the odontoblasts and therefore reaction is a combined function of both tissues. The three-dimensional shape of the *pulp chamber* varies in different teeth. Thus, in an upper incisor the coronal part of the pulp chamber is somewhat flattened buccolingually and broad mesiodistally and the radicular portion of the pulp chamber is roughly triangular in shape and conical in length. In multirooted teeth such as the molars the form of the pulp chamber is obviously much more complex. It is important for the restorative dentist to appreciate the general form of the pulp chamber in each tooth type, although variations exist even between teeth of similar notation. A standard text on tooth morphology will provide this information. It has already been stated that the relative size and shape of pulp chambers in deciduous teeth is larger than that in permanent teeth and therefore exposure of the pulp chamber is considered by many to be a greater hazard in deciduous dentitions.

The healthy pulp is of a jelly-like consistency having a ground substance of glycosaminoglycans in which is interspersed a loose and sparse network of collagen fibres. These collagen fibres are produced and maintained by fibroblasts which are the commonest cell type in the healthy pulp. There are also macrophages, pluripotential histiocytes and occasional monocytes. There is a complicated vascular supply consisting of arteries entering the apical foramen and dividing into an extensive network of arterioles, particularly in the peripheral parts of the pulp. These arterioles connect directly with venules so that arterio-venous shunts

exist. There is an extensive capillary plexus particularly in the region of the odontoblast cell bodies at the periphery of the pulp. Although difficult to demonstrate, there is an adequate lymphatic drainage from the pulp and veins and lymphatics leave together through the apical foramina. Innervation of the pulp has already been discussed in relation to sensitivity of the dentine.

## The Periodontium

The tooth is supported in its bony socket by a specialised connective tissue – the *periodontal ligament*. At the cervical margin or neck of the tooth it is continuous with the connective tissue underlying the *gingivae*. At the apex, it is continuous with the tooth pulp. It bridges the gap between the root cementum and the alveolar bone and is approximately 0.2 mm in width. It is composed of fibres in a gel-like ground substance that contains nerves, blood vessels and cells.

### Fibres

Most of the fibres in the ligament are Type I collagen, although some Type II collagen and specialised oxytalan and elastin fibres are present in small amounts. The collagen fibres are arranged in bundles which pursue a complex wavy course. At their cementum end the bundles are smaller in diameter than at their alveolar bone end. They form branching networks around the neurovascular bundles but no single fibre bundles appear to traverse the whole distance from tooth to bone. The collagen bundles are incorporated into bone and cementum in the same way as are tendons, that is to say, in the form of mineralised Sharpey's fibres. The fibre bundles are 'crimped' along their course and the fibre bundles overlap each other. It has been suggested that this allows response to loading under occlusal forces. The functional activity of the ligament will be described later. The fibre bundles are arranged in specific named groups associated with the gingival, crestal, radicular, apical and interradicular portions of the tooth. Their arrangement is shown diagrammatically in Fig. 5.2.

The oxytalan fibres lie parallel to the length of the tooth root and are attached to cementum at one end. They have been implicated in both tooth eruption and support and may be involved in support of blood vessels.

## Ground substance

The major components are hyaluronic acid, glycoproteins and proteoglycans. Hyaluronic acid and the polysaccharide components of proteoglycans are glycosaminoglycans. Water content is about 70%.

## Vasculature

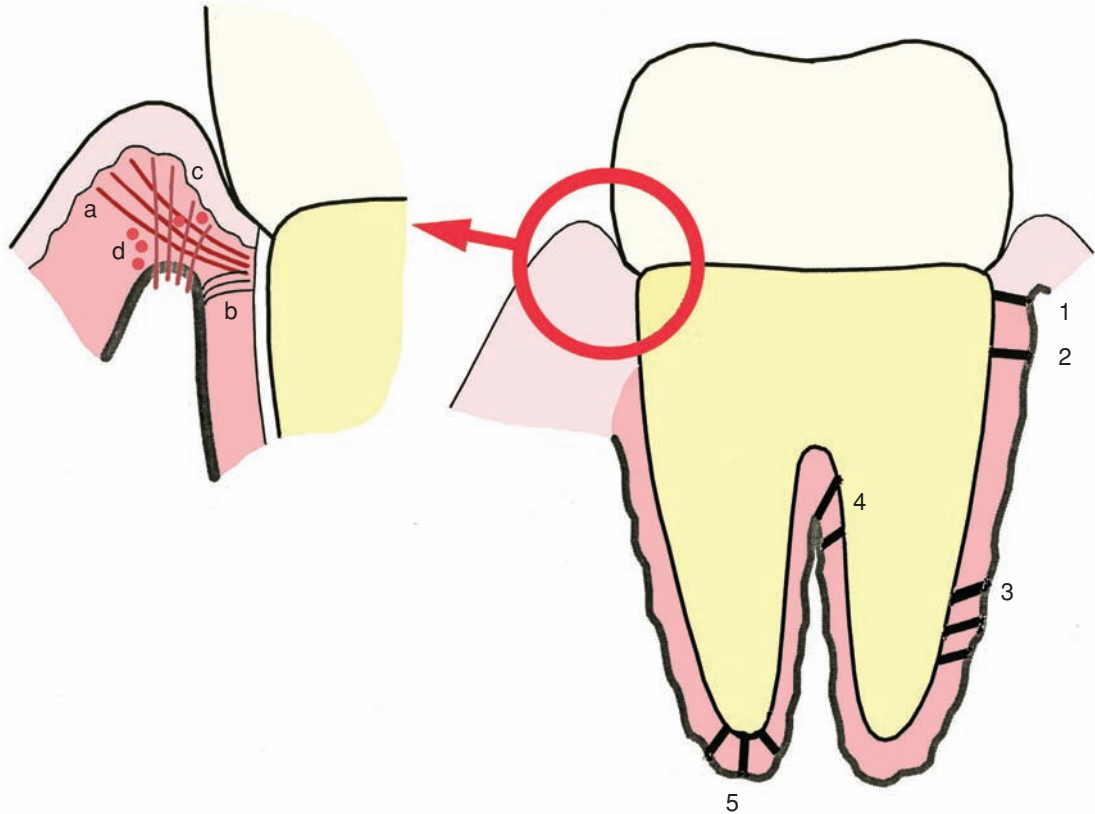
The periodontal ligament is well supplied with blood vessels that are mainly derived from the superior alveolar branches of the maxillary artery or from the inferior alveolar artery in the mandible. There may be other sources deriving from the buccal, masseteric or lingual arteries in the mandible or from the palatal or facial arteries in the maxilla. The veins drain into larger veins in the inter-alveolar bone and usually do not follow the route of the arteries. Within the ligament itself the blood supply is most extensive in the cervical part and least extensive in the middle third. Most of the vessels enter the ligament as perforating arteries from the intra-bony vessels and they run parallel to the long axis of the tooth, passing between the principal fibre bundles of the ligament. Many branches arise from these vessels and they form a capillary plexus that is more complex at the bone surface than at the cementum surface of the ligament. There appear to be arterio-venous shunts in the cervical part of the ligament and these resemble renal glomeruli. There is some evidence that in older patients, the vascularised spaces are larger and encroach upon areas previously occupied by fibres and bone.

The actual rate of blood flow has not yet been reliably determined but is controlled by both  $\alpha$ - and  $\beta$ -adrenoreceptors, allowing both constriction and dilation of vessels.

There are lymphatics present, although not in great numbers, and they tend to follow the venous drainage.

## Nerves

These are derived from either the superior or inferior dental nerves. Some of the bundles of nerve fibres run from the apical region of the periodontium towards the cervical margin of the tooth. They are joined by nerves passing through foramina in the bone to enter the ligament horizontally. Large fibres are myelinated and terminate in specialised nerve endings that are associated with mechanoreceptor activity. These monitor forces on teeth and may be involved in reflex jaw opening and masticatory control. Small fibres



**Fig. 5.2** Schematic diagram of the structure of the periodontium. Principal fibre groups: (1) alveolar crest, (2) horizontal, (3) oblique, (4) inter-radicular, (5) apical. Gingival ligament groups: (a) dentogingival, (b) dentoperiosteal, (c) alveogingival, (d) circular.

terminate as free nerve endings associated with appreciation of pain. Autonomic nerves are present and they control regional blood flow in the ligament.

### Cells

Most of the cells of the ligament are fibroblasts. They are responsible for the unusually high 'turnover' rate in this tissue resulting in the fibres being constantly synthesised, removed and replaced. The fibroblasts are spindle shaped, large cells and they align themselves along the length of the fibre bundles. They are able to both produce and remove collagen fibres so that diseases affecting their function can seriously damage the ligament.

Some of the epithelial cells (Hertwig's sheath) responsible for mapping out the shape of the tooth root

remain in the ligament as cell 'rests' and they may subsequently proliferate to produce periodontal cysts.

There are undifferentiated cells of mesodermal origin and it is probable that they can differentiate into any type of mesodermal cell in the ligament.

Since the ligament is bounded on the tooth surface by cementum and the outer surface by alveolar bone, there are cementoblasts and osteoblasts present. Bone remodels readily so that osteoclasts are seen in the ligament. Cementum is much more stable so that in adult teeth (but not deciduous) cementoclasts are rarely seen.

### Response to movement and load

Clearly, the ligament is responsible for the support of the teeth and attaches the tooth to the bone. There is

still debate, however, as to how the ligament functions during normal physiological activities such as eruption or response to loading in an axial or tangential direction. It has been suggested that the ligament may contract during eruption, that migration or contraction of fibroblasts may occur, or that pressure may be exerted by vascular or fluid elements. The evidence is complex and largely derived from experiments on rodent teeth. It seems that the vascular theories are the most probable.

Mesial drift or movement of erupted teeth towards the mid-line has been attributed to activity in the periodontal tissues. At the present time there is conflicting evidence and physiological mesial movements in response to tooth loss or wear cannot be fully explained.

In respect of functional loading on the teeth there is also controversy. The weight of evidence suggests that the ligament does not behave purely as a suspensory ligament but that it behaves in a viscoelastic manner. It is now thought that all the components act together like a hydraulic shock absorber. In this case the fibres, ground substance, blood in the vessels and tissue fluids are all important. The system is very complex and is as yet imperfectly understood.

## Age Changes in Teeth

It is sometimes difficult to distinguish between changes occurring in tissues due to age and changes occasioned usually in the older person because of increased exposure to external stimulation. This is particularly so in the case of the hard tissues of the teeth.

### Enamel

In the case of enamel, although it is in principle a non-reactive tissue, most of the changes that occur as age progresses are due to ionic exchange between the external environment and the tooth. These have been described earlier. They may result in an enamel with a slightly changed refractive index so that the colour of a person's tooth may change somewhat with age, usually becoming rather darker. The small but important organic content of the teeth, especially in relation to lamellae, may also take up staining as life progresses contributing to this change in colour. Because enamel is non-replaceable in bulk, certain parts of the tooth tend to become worn as age progresses. Whilst not a true age change, this phenomenon of surface loss is often used by anthropologists to age individuals

although considerable information is required as to the diet responsible for the wear pattern.

### Dentine

In the case of dentine there do seem to be changes more directly associated with age. There is evidence that the amount of intra-tubular mineralisation increases with age and this occurs from the periphery of the odontoblast tubules working inwards towards the pulp. The effect of this is to produce sclerotic dentine where the refractive index and homogeneity of the tissue is more uniform. This phenomenon occurs particularly under regions of surface wear or caries in the crown but is strikingly evident in the apical part of the tooth, spreading upwards from the apex to, in old age, two-thirds or more of the way along the root. On tooth section, this *sclerotic dentine* gives a transparent appearance to the root dentine and its extent provides a standard method of ageing dead bodies in forensic investigations. Its clinical significance will be discussed later.

### The pulp

The pulp, although reducing in size as age progresses, may also change in consistency. It is reported that the fibrous content of the pulp increases relatively with age and there is evidence that the number of viable odontoblasts reduces.

### Cementum

Cementum was a tissue of lesser interest to restorative dentists in the past but with the advent of interest in root caries may assume a greater importance in the future. It is for this reason that the tissue structure has not been discussed in detail. It has been reported recently that incremental lines in cementum may be related to seasonal changes and therefore may be used to age an individual. Whilst this seems a possibility in hibernating animals, the prospect seems unlikely in the human tooth.

## The Microenvironment of the Tooth

When the tooth erupts into the mouth any cellular remnants on its surface are quickly lost. This brings the enamel surface in direct contact with the saliva, some of the proteins of which are instantaneously deposited on the enamel surface.

## Saliva

Flow rates of *saliva* are at a maximum during masticatory activity and there is also a diurnal rhythm. It is not clear whether salivary flow rates are reduced to zero during sleep but they are certainly very low. Saliva contains anti-bacterial agents and is also of some importance in the initial digestion of food. This is brought about by its content of amylase. It is also functionally necessary for the sense of taste since substances can affect the taste buds only when in solution. To the restorative dentist, apart from the physical problems of dealing with it clinically, saliva is largely viewed as a protective medium for the teeth. It contains mucus mainly secreted by the submandibular and sublingual glands and it is this mucus which forms the protein coating on newly erupted teeth. It is a self-cleansing material since it washes the teeth following meals and as already mentioned it has some anti-bacterial and possibly anti-viral activity (secretory IgA). Two features of saliva, however, are of great interest to the restorative dentist. Firstly, saliva is an excellent buffer, largely due to its content of bicarbonates and to some extent its proteins. A buffer is a substance which tends to prevent changes in pH. During mealtimes when perhaps acid substances are ingested or when the products of breakdown of food produces acid, the buffers in saliva tend to neutralise this acid. The increased flow of saliva at mealtimes produces increased buffering activity. Secondly, saliva is supersaturated with calcium and phosphate ions. It is therefore largely the source of ionic interchange between the microenvironment of the mouth and the tooth itself. Fluorides may be contained in saliva and may be concentrated by plaque forming on the surface of teeth.

## Dental plaque

*Plaque* is a bacterial deposit on the protein pellicle of the tooth and its ecology is complex and variable. In most people it consists of a basic bacterial flora of the streptococcus mutans type perhaps along with lactobacilli. In older plaque, filamentous organisms of the actinomyces type become apparent. Many of these organisms, particularly streptococcus mutans, breakdown refined carbohydrates producing extracellular glycans and large amounts of acid. As will be seen later, the relationship of the numbers and types of various micro-organisms to the prevalence of caries is an extremely difficult problem and it must be remembered that caries is a multifactorial disease and

studies of any one factor may be unrewarding. As an illustration of this point it is known that plaque on the surface of teeth is capable of concentrating fluorides so that in an external environment of one part per million there may be eight to ten parts per million in the plaque. This concentration of fluoride may be toxic to some bacteria, although there is evidence that many bacteria combine the fluoride and remain metabolically active. The suggestion has been made that the presence of some young plaque capable of concentrating fluoride may be useful to the tooth surface in that interchange with the surface hydroxyapatite crystals may be aided. Most clinicians, of course, would recommend removal of plaque, thereby denying the production of low pH and the formation of carious lesions.

## Restorative Implications

In our descriptions of enamel, dentine, saliva and plaque, the reader will have detected that the information is rarely academic but is necessary for a full understanding of the process of carious attack and of the dentist's ability to prevent or repair it. Important aspects of basic dental science and clinical restorative dentistry will be emphasised by a few examples.

### Enamel prisms

The reader will have appreciated that the detailed orientation of the enamel prisms is complex since it varies in different parts of the tooth. In the cuspal region the prisms follow a wavy and complex course, probably adding to the strength of this part of the enamel. In the cervical region they may slope towards the cervical margins and in deciduous teeth, may be more horizontal in this part of the tooth.

### Surface preparation

It is important that unsupported prisms are not left since these may be extremely friable and the restorative dentist seeks to ensure that the periphery of his preparation lies along the general direction of the prisms. This produces maximum strength and reduces the likelihood of future fracture at the periphery of his restoration. Clinical practice must be tempered with common sense and it is recognised by most restorative dentists that sometimes the load on a particular part of a restoration part is minimal and it may not be necessary to follow these guidelines. The same



principles apply to the preparation of the surface of a cavity and attempts are often made to avoid leaving loose enamel crystals present even though these are invisible to the operator. Thus, some operators advocate the cleaning and disinfection of a cavity before placing a restoration. It is probably less important in relation to enamel than to dentine unless bonding techniques are anticipated, in which case the prisms of the enamel must be exposed in order to produce a good key for the bond. This latter consideration may be important not only in relation to finishing cavity margins but in preparing surfaces of enamel where bonding to unprepared enamel is required.

### Remineralisation

It will be clear from the description of enamel that in biological terms it is a non-healing tissue. This is why most approaches to dental caries in the past have been not so much treatment as repair of an untreatable defect. This has now changed and it has become established that at least in the early stages of carious attack demineralisation or increased pore spacing in enamel may be repaired to some extent by removing the attacking medium and allowing the super-saturated nature of saliva to take its effect or if necessary by applying super-saturated remineralisation solutions to the early carious lesion. It is now well recognised that caries is not a continuous process but is a start–stop phenomenon. It seems logical to assume therefore that the condition in its early stages is reversible and this fact forms the basis for most restorative, preventive and early treatment regimes.

### Saliva and plaque

The importance of saliva and its consequent plaque formation on teeth has already been touched upon. Current opinion holds that removal of plaque by adequate oral hygiene procedures, especially during the first two decades of life, will prevent or markedly reduce the prevalence of caries. Extensive restorative procedures are therefore contra-indicated in patients unable to control their plaque formation and initially the prevention of caries in children and eventually the management of established caries in adults depends as much upon oral hygiene procedures, diet and fluoride application as upon excellent technical restorative procedures.

### Secondary dentine

Odontoblastic processes in their tubules follow a sigmoid course as they traverse towards the pulp. This is especially the case in the radicular part of the tooth. This means that the cell bodies associated with a particular tubule are much more apically placed than the carious attack at the periphery of the tubule. Any reactive secondary dentine will therefore not be developed directly at the base of the cavity but will be placed more apically. This is important to recognise since the protective effect of secondary dentine distancing the attack from the pulp is useful in the apical portion of the cavity but exposure of the pulp is much more likely more cervically.

### Progress of caries

The rate of progression of caries through enamel and dentine is not known with precision but it appears to take 3–4 years for an early lesion to progress through enamel. It is then believed that the rate of progression through dentine is much more rapid. Clinically, it is obvious that when the lesion reaches dentine it spreads laterally along the enamel–dentine junction and this may be a reflection of the lower mineral content of the dentine and also of the inter-connecting lateral processes of the odontoblastic processes. The importance clinically is that caries has to be followed laterally at the enamel–dentine junction, thereby producing undermined enamel which will need to be removed subsequently.

### Dentine sensitivity

The question of reaction of dentine to external stimuli is one of the most important factors in aiding the dentist in his control of carious attack. We have already noted that progress of caries through dentine is more rapid than through enamel but this is limited by the fact that the dentine will react to attack producing irregular secondary dentine, sometimes known as tertiary dentine. Perhaps the interesting question concerning the sensitivity of dentine is not how it is brought about but why it is necessary in the first place. Sensation in most parts of the body is a defence mechanism, allowing the organism to withdraw from noxious stimuli. A patient cannot readily withdraw the teeth, although they might conceivably seek to place unpleasant foods in another portion of the mouth. It may be that the sensitivity of dentine is concerned more with trophic mechanisms controlling the health

of the pulpal tissue and may be associated in some way with the response of the odontoblast and their processes to outside stimuli. A major difference between dentine and enamel is that the former is capable of responding to carious attack or wear or fracture of the tooth and has a potential for healing. This will

be discussed in greater depth in Chapter 6, but the living nature of the odontoblastic processes, cell bodies of the odontoblasts and the continuing ability of the tissue to lay down pre-dentine mineralising into dentine, enables the tissue to respond to loss of tooth substance by walling off the vulnerable pulp tissue.

## Chapter 6

# The Pathology of Caries and Pulpal Disorders

An understanding of the pathology of caries and the way it affects the pulp is fundamental to much of restorative dentistry. This chapter considers the scientific evidence associated with the aetiology of caries, the ways in which enamel and dentine are destroyed and the effects on the pulp. The clinical implications of these processes are discussed.

### Introduction

Caries is essentially an attack on the mineralised tissues of the body, resulting in demineralisation and in some cases in destruction of the matrix. In principle, it may occur in all of the hard tissues including bone but for the purposes of this book discussion will be restricted largely to enamel and dentine. In the young, healthy human the dentine of the tooth is entirely protected by enamel or by the gingivae and periodontal tissues in the root area. Caries therefore must commence at the enamel surface. In older individuals where gingival recession and loss of periodontal and bone support have occurred the root of the tooth may be exposed to the mouth and caries may then occur *de novo* on the cementum and dentine.

### Factors Influencing Caries

The crown of the tooth is in a microenvironment of its own, mainly that of the saliva, microbial deposits derived from the saliva and other sources, food debris and other dietary constituents. Whether caries commences or not seems to depend upon the quality of this environment, the ability of the tooth to resist demineralisation, immunological reactions by the host and the length of time for which all these factors are in operation. The disease therefore has been described as *multifactorial* and in some texts as many as 50 factors have been described in relation to carious attack. It is more profitable to group the factors into three: firstly, those associated with the host including the quality of the saliva and the bacterial flora therein; secondly, outside factors associated with diet and the substrate on which these bacteria act and finally, the

tooth itself and those features which either predispose to or resist carious attack (Fig. 6.1).

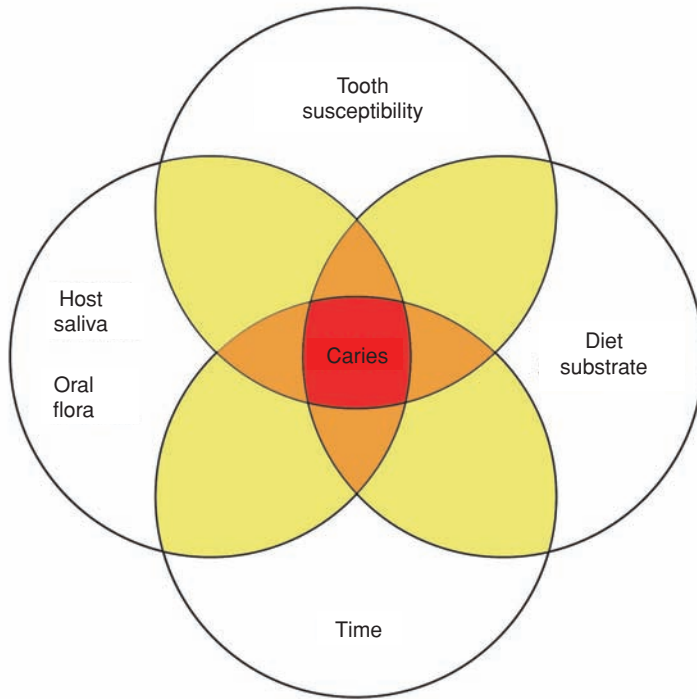
### Host factors

When a tooth is developing within the alveolar process its enamel surface is protected by means of an *organic pellicle* and cellular covering. As it erupts into the oral cavity much of this protection is lost but immediately on contact with the saliva a secondary organic pellicle is immediately laid on the enamel surface and it is to this that organisms within the oral cavity attach themselves.

### Micro-organisms

Initially most of the organisms are streptococcal in nature, producing an immature plaque on the surface of the tooth. If this is allowed to be maintained, other organisms of filamentous nature such as actinomyces will also be involved and the plaque is said to be mature. The organisms colonising the plaque will depend upon those present in the oral cavity and may therefore vary from individual to individual. However, it has been shown that breast-fed children may acquire streptococcus mutans from their mother so that in this sense caries may be thought of as an infectious disease.

There has been a great deal of research to establish the nature of organisms associated with dental caries, much of which lies outside the scope of this chapter. Some of this work has been carried out on gnotobiotic animals where it was shown that the difference between animals which were caries active and those which were caries resistant lay in the fact that the latter lacked particular micro-organisms. In human enamel caries large numbers of organisms have been described on the enamel surface but in



**Fig. 6.1** Factors influencing the onset and spread of dental caries. Microbial breakdown products of dietary components may produce an adverse local environment that, if operative for sufficient time, may result in caries in a susceptible tooth.

caries-susceptible individuals it seems that the most obvious organisms are *lactobacilli* and *streptococcus mutans*. In older plaques, actinomyces species are present but most studies have not implicated these particularly in the development of the early lesion. In the case of root caries the most commonly isolated organisms are of the actinomyces type followed by lactobacillae, *Streptococcus mutans* and *Streptococcus sanguis*.

### Saliva

Not only is the saliva responsible for the microenvironment of plaque organisms but is also in itself important in the development of early carious lesions. This is because caries is essentially a demineralising disease requiring a fall in pH at the surface of the tooth. If the saliva is capable of resisting this change in pH because of *buffering capacity* then caries is less likely to ensue. It is known that high flow rates of saliva improve its buffering capacity so that caries is dependent not only on the quality of the saliva but also upon its quantity. It is for instance well known that caries increases in patients with xerostomia following irradiation of tumours in the oral region but

there may also be changes of diet associated with these problems. Saliva is a super-saturated solution of calcium, phosphate, hydroxyl and fluoride ions and these may reduce the solubility of enamel and promote remineralisation of early lesions. In addition, the saliva contains non-specific antibacterial agents such as lysozyme, lactoperoxidase and lactoferrin and in addition contains immunoglobulin ICA molecules and in those patients with inflammation of the periodontal tissues IGC may be present in the serum exudate. It has been suggested that it may be possible to immunise patients against caries but in western society where caries prevalence seems to be falling it seems unlikely that this will be an acceptable procedure.

### Oral hygiene

The final host factor of importance in caries is the ability to improve oral hygiene thereby removing the plaque from the surface of the teeth and preventing the production of acids initiating caries. Oral hygiene is usually considered to be mechanical using toothbrushes, toothpastes, floss and similar methods, but it must be remembered that oral hygiene is also a natural phenomenon which some individuals do well and

others do not. The use of the tongue as a means of oral hygiene has received relatively little study but may well be a factor in reducing caries.

## Diet

The second main group of factors associated with caries of the teeth is that of diet. Microbial plaque on the surface of teeth is disastrous only if there is sufficient substrate for these bacteria to work upon. Fermentable carbohydrates need to be present for acid to be formed. The problem is that in the presence of fermentable carbohydrates, the plaque bacteria produce acid rapidly so that the pH in relation to the plaque falls precipitously very quickly. The recovery from this position to normal pH levels is an extended process. The major part of our dietary fermentable carbohydrate is sucrose, but lactose is present in milk and maltose is derived from the hydrolysis of starch. It seems that it is the frequency of fall in pH which is important and this information enables dentists to plan dietary advice for their patients. Attempts have been made to replace these fermentable carbohydrates by other types of sugar such as xylitol which is a sugar alcohol but is not metabolised to acid by the plaque organisms. There are however difficulties in changing the habits of a lifetime.

## Tooth susceptibility

The third factor related to caries incidence appears to be the structure of the teeth themselves.

## Morphology

Caries tends to occur at certain points on the teeth such as the depth of the fissures and below the contact areas and cervical margins and this suggests that the shape and morphology of the tooth is important along with its ability or otherwise to shed food debris or to be cleansed by the patient's musculature or salivary flow. Packing of food between teeth which are malaligned may also constitute a problem. Fissures which are deep and difficult to cleanse may well be more liable to caries than shallow, cleanable fissures but the details of tooth morphology are best studied in texts related to that subject.

## Chemistry

Using techniques of microprobe analysis and microbiopsy, it has been possible to show that tooth structure varies chemically between different individuals. For example, fluoride levels vary between individuals

and this in itself may have an influence on their caries resistance.

## Surface structure

It has become clear that the outer surface structure of enamel is extremely variable and indeed in many patients in some of their teeth and at certain sites the prisms of the enamel may in fact not reach the surface. The surface of the tooth in contact with the microenvironment is therefore said to be *apristmatic* but the relationship of this structural variation to caries resistance is not clear.

## Research Methods

Most of the modern techniques of scientific investigation have been applied to caries over the decades. These have included epidemiological studies on the incidence of the disease and biochemical studies on the environment of the mouth and of the teeth themselves. It is beyond the scope of this book to discuss these in any detail. However, in order to understand the principles of restorative dentistry it is necessary to have a working knowledge of the pathology of the lesion itself.

## Ground sections in polarised light

Most of the early work in this area consisted of the production of ground sections through teeth containing natural early lesions and much of it was directed towards the technology of producing sufficiently thin sections to be of use in these studies. Sections between 50 and 100  $\mu\text{m}$  in thickness have now been achieved and these may be examined either in the light microscope or more profitably and commonly in the polarised light microscope. *Polarised light* is vibrating in one plane and this plane may be rotated by suitable crystalline materials. Enamel is such a material as is dentine by nature of its hydroxyapatite content and its collagen matrix. When polarised light is passed through enamel it is rotated both by the crystals themselves and by the arrangement of the crystals in the form of prisms. The former is said to be intrinsic birefringence and the latter form birefringence. In the case of dentine the light is rotated by the crystals of hydroxyapatite and also by the repeat pattern of the collagen. Carious attack affects both the size and the shape of the crystals and the spaces between them and the overall outline of the enamel prisms. In the case of dentine it may alter the collagen component

as well. For these reasons carious lesions exhibit altered birefringence, the direction and extent of which not only indicates the extent of the lesion but may be used quantitatively to deduce the degree of demineralisation.

### Transmission electron microscopy

The availability of the transmission electron microscope (TEM) in the early 1960s held promise of detailed investigation both of normal and carious enamel, but it proved almost impossible to produce sections of sufficient thinness for this technique to be fully exploited. Thin sectioning is possible in partially demineralised enamel but there is doubt as to whether the sectioning procedure may alter the crystalline structure of the material being examined. Attempts were made to solve this problem by cutting thick sections through the lesions and taking carbon replicas which themselves could be examined in the TEM and considerable progress was made using this technique.

### Scanning electron microscopy

A decade later the scanning electron microscope (SEM) became available and since this records information from a cut surface by excitation of secondary electrons, thin sectioning was no longer needed. Although the method has been exploited to some extent in studies of caries, interpretation of the images and particularly the formation of smear layers during sectioning has proved difficult. Methods of removal of the smear layer using either chemical or preferably ion etching techniques are now in progress and back scatter electron imaging which provides information from beneath the cut surface is a recent promising advance. Modern SEMs allow analysis of emitted X-rays from the specimen being studied and electron microprobe analysis of this nature allows chemical analysis to be made in various parts of the lesion. X-ray and electron crystallography have also featured in studies of caries.

### Microradiography

Since carious lesions in both enamel and dentine are characterised by loss of mineral, microradiographs can be used to demonstrate changes of mineral density within the lesions. It is necessary to use a graduated step wedge in order that a standard may be compared with the radiographic image and plane or

parallel sections of known thickness are required in order to make the necessary calculations of mineral loss.

### Microbiopsy

Microbiopsy techniques have been evolved so that small portions of a carious lesion from a known position can be excised and analysed using some of the methods previously described. These biopsies are also available for biochemical study. Using such techniques the distribution for instance of fluoride ion within a lesion may be determined.

All of these methods have now been applied both to natural human lesions and to artificially induced lesions in human and in animal teeth so that the process of caries in mineralised tissues is now more fully, but still incompletely, understood.

### Caries of Enamel

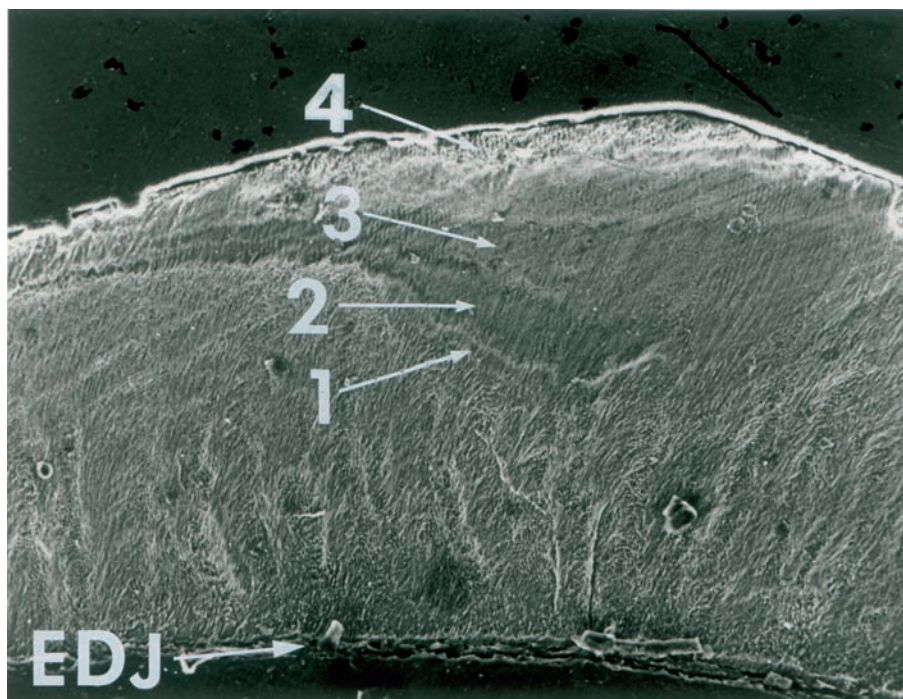
When mineral is removed from the enamel by carious attack, the individual crystals making up the prisms diminish in size and the enamel is said to become more porous.

### White spot lesion

Even a slight increase in porosity of the enamel changes its optical characteristics and in the initial stages it becomes less translucent so that the earliest evidence of caries is known as a white spot lesion. At this stage the surface of the enamel is still intact and the lesion may be difficult to detect clinically. Histological studies using polarised light have shown that the lesion at this stage is not continuously progressive but may *remineralise* so that processes of both destruction and repair are occurring simultaneously. When examined under the polarising microscope in water, the lesion is described as cone shaped with its base just below an intact surface zone. The body of the lesion appears to be dark in colour and the incremental lines are accentuated. The use of quinoline as an inhibition medium of different refractive index allows further details of the early lesion to be described. Four zones may be seen in an early white spot lesion (Fig. 6.2).

### Advancing front

Zone 1 is a translucent zone present at the advancing front of the lesion and is usually only seen in sections



**Fig. 6.2** Scanning electron micrograph of a ground section of an early 'white spot' carious lesion. It consists of four zones: (1) translucent zone; (2) dark zone; (3) body of the lesion; (4) surface zone.

examined in quinoline. This zone is more porous than sound enamel having a pore volume of about 1% compared with 0.1% in intact enamel.

### Dark zone

Zone 2 is known as the dark zone and lies superficial to the translucent zone. It appears dark when examined in quinoline. Polarised light studies have shown that the pore volume is increased to 2–4% in this region. It is thought that the dark appearance is occasioned because some of the pores are too small to allow quinoline to enter so that they retain air following sectioning. It has been speculated that some remineralisation may be occurring here reducing some of the pore sizes.

### Lesion body

Zone 3 is the body of the lesion and since more than 5% of the enamel is porous and the size of the pores are large enough to allow water to enter, the body appears dark when examined under polarised light in water but translucent when examined in quinoline. In some parts of the body the pore volume may increase to 25%.

### Surface zone

The fourth zone is known as the surface zone and is best seen in sections examined in water. It is an intact surface layer with a pore volume of less than 1% and is usually between 20 and 50  $\mu\text{m}$  in thickness. Thus, the early lesion is more demineralised in its depth than at its surface and although it was first thought that the surface zone was caused by a hyper-mineralised zone at the surface of the tooth, it may be reproduced following removal of this surface layer. It is now thought that it may be caused by re-crystallisation of dissolved mineral elements from deeper in the lesion.

### Fissure caries

The foregoing description is that of an early lesion on the smooth surface of a tooth and in the case of early fissure caries similar appearances are noted around the fissure wall. It should be noted that in many fissures examined in sections there is an enamel defect at the base so that the lesion spreads very quickly into dentine. This may explain the recently described phenomenon of 'bomb' caries in teeth that have been subjected to fluoride ions during development or

subsequently. The enamel around the sides of the fissure is resistant to carious attack by reason of its fluoride content but the lesion spreads rapidly into dentine spreading along the enamel dentine junction and cavitating the dentine although the fissure may appear clinically to be intact.

### Electron microscopy

Electron microscope studies on early carious lesions have provided conflicting evidence. In most cases the inter-prismatic regions seem to be preferentially dissolved but also larger, unusually shaped crystals may be seen in this region and these may represent a remineralisation phenomenon. The biopsy techniques previously described have shown that in the translucent zone the cross section diameter of the crystals is 25–30 nm compared to 30–40 nm in sound enamel. In the dark zone of the lesion crystal diameters may be 50–100 nm whereas in the main body of the lesion they may be only 10 nm in diameter. These findings again support the view that remineralisation of crystals is occurring in various parts of the early carious lesion.

### Microradiography

Microradiographs of sections through the early lesion are sufficiently sensitive to demonstrate loss of mineral if this is more than about 5%. The body of the lesion therefore shows up well using this technique and the intact surface zone is also readily seen. In high-resolution microradiography the outline of the incremental lines may be visible within the body of the lesion.

Biochemical studies using biopsies of the lesion or electron probe microanalysis have confirmed these changes in enamel caries and have also shown that fluoride levels are high in this artificially porous material.

### Progress of the lesion

As the lesion progresses through the enamel its apex may reach the enamel–dentine junction before collapse of the intact surface zone occurs so that lesions may be quite deep before they are easily detectable clinically. The enamel lesion, however, is extremely porous by this stage so that acids are able to diffuse easily across the junction and into the dentine. The implication is that dentine may be involved even when lesions appear to be restricted to enamel on standard clinical radiographs.

## Caries in Dentine

Caries spreading to dentine may be either subsequent to enamel caries having reached the enamel–dentine junction or in certain circumstances, that is, exposure of the root of the tooth, it may commence *de novo* in the cementum and spread to the dentine directly.

### Coronal caries

Involvement of dentine in the crown of the tooth may be either underneath smooth surface caries, usually at the contact area or immediately below it, or may be an extension of caries in an occlusal fissure. When the carious process reaches the enamel–dentine junction, it tends to spread laterally involving the dentine on a wider front. In this way the enamel is undermined so that the resultant cavity preparation requires removal of sound enamel in order that the infected dentine may be approached and also to remove unsupported enamel prisms which under areas of stress will tend to fracture. Lesions of the occlusal fissures may directly involve dentine since in many cases enamel is deficient at the base of the fissure.

### Root caries

In patients where the root surfaces have become exposed usually due to chronic inflammatory periodontal disease, but also in continuing eruption to compensate for occlusal wear, the root becomes directly exposed to plaque and carious attack. Chronic infective periodontal disease and continuing eruption due to occlusal wear are both commonly seen in older people so that root caries tends to be a disease of old age. Root caries may extend from lesions at the cervical margin of the enamel or may attack dentine exposed directly by the aforementioned means. Root caries can be of two types. Active root caries is soft and pale in colour, whereas arrested lesions, possibly caused by good oral hygiene techniques, tend to stain and be hard and dark brown.

Dentine is a living reactive tissue and must be considered in association with the living pulp tissue beneath. Reactions to dentine caries therefore involve consideration of both the dentine itself and the underlying pulp tissue. The reaction and response of the pulp will be considered later.



## Micro-organisms

Once the enamel has been penetrated, bacteria can gain access directly to the dentinal tubules and so the tissue becomes infected. The initial invasion of dentine appears to be mainly acidogenic, the acid presumably diffusing ahead of any micro-organisms. The first organisms to invade the dentine appear to be lactobacilli and also cariogenic streptococci, notably streptococcus mutans. Underneath the enamel–dentine junction the microbiological population is mixed and organisms producing proteolytic hydrolytic enzymes may be found. At the advancing edge of the dentinal lesion is a zone of demineralised dentine that bacteria have not yet penetrated. This is because the tubules are smaller than the diameter of most bacteria and only when the tubules have become laterally enlarged by dissolution of the inter-tubular matrix do bacteria enter. Superficial to the demineralised dentine is a zone of penetration in which bacteria are present in the tubules. Superficial to that again is a zone of complete destruction where the mineral content and organic matrix of the dentine have both been destroyed.

## Effect on dentinal tubules

Once the dentine is infected it may react in several different ways. Those tubules directly located in the centre of the demineralised zone may appear to be empty because the cell processes of the odontoblasts have withdrawn. During section preparation these empty tubules may be filled with air producing a dark colour under the light microscope often referred to as a dead tract. Odontoblastic cell processes less acutely involved in the carious process, that is, usually those at the periphery of the lesion may react by laying down calcified material as the cell processes withdraw, thereby equalising the refractive index of the dentine and producing a transparent or translucent sclerotic zone. The crystals in these tubules, when examined in the electron microscope may have larger and more irregular crystals than in the normal dentine. They are considered to represent the result of remineralisation. Sclerotic dentine may be considered as an extension of the normal process of production of peritubular dentine. The sclerotic dentine may consist initially of fine crystals of whitlockite and at later stages of mineralisation of a mixture of whitlockite and hydroxyapatite. The final obliteration of the tubule appears to be by hydroxyapatite crystals.

## Secondary and tertiary dentine

The lesion eventually spreads towards the pulp of the tooth and the stimulus may cause reactionary tertiary dentine to be laid down in the pulp at the depth of the lesion in an attempt to wall off the advancing caries from the pulp. It may be a relatively well-formed tissue containing dentinal tubules and may be similar in structure to normal secondary dentine. It may also be an abnormal tissue with very few tubules and numerous inter-globular zones. Reactionary dentine is most frequently formed when the stimulus is mild and the blood supply to the pulp is good so that it is more likely to be seen in younger teeth. If the stimulus is overwhelming, the odontoblast cells lining the pulp may be killed and then of course no reactionary dentine can be produced. Under these circumstances the carious lesion will directly involve the pulp and this will be discussed in the next section.

## Response of the Pulp

In the early stages of infection, the pulp reacts as would any other healthy tissue.

## Hyperaemia

An inflammatory reaction occurs and in its initial stages this is characterised by hyperaemia. The pulpal blood vessels dilate, become more permeable and fluid and defence cells pass out into the surrounding pulp tissue. This increases the pressure within the pulp and this pressure, unlike in soft tissues, cannot be relieved because of the enclosed nature of the pulpal tissue. The pressure, therefore, rises and the patient suffers pain. Initially, this may be the case when transient stimuli such as very hot liquids or very cold liquids are placed in contact with a carious lesion. The pain may only last as long as the stimulus is applied. Once the carious lesion has approached closely to the pulp the stimulus may be continuous and the reaction of the pulp will depend upon the duration and the intensity of this stimulus.

## Chronic inflammation

If the lesion is progressing slowly towards the pulp then toxins and thermal stimulation may be of a low-grade nature and the result is chronic inflammation. Lymphocytes, plasma cells, macrophages and

monocytes can be seen in the pulpal tissue and the tissue may survive. There may be no increase in intra-pulpal pressure and therefore no symptoms.

### Acute inflammation

If the stimuli reaching the pulp are stronger, then the blood vessels dilate, fluid passes out into the tissues and the pressure builds up to such an extent that the arterioles entering through the apical foramina may be occluded. Polymorphonuclear leucocytes are the main cells involved in acute inflammation. The increase in intra-pulpal pressure leads, usually, to severe pain.

### Pulpal necrosis

The rise in intra-pulpal pressure may occlude the pulp's blood supply. This may be accompanied by an overwhelming bacterial infection from the carious lesion. The result of both of these is pulp death and the ceasing of any pain.

It is possible for a necrosed pulp to remain quiescent for many years with no evidence of such pathology. The apical foramen may become blocked with calcific deposits – a natural root filling.

On the other hand, the apical foramen may remain patent and there will be pathological effects in the periapical region.

### Periapical Involvement

The first effects of the pulpal infection will be the leaking of bacterial toxins and tissue breakdown products through the apical foramina to the periapical tissues. The response of these tissues may also be either acute or chronic in nature, depending upon the severity of the stimulus. Later, bacteria may pass out into the tissues.

### Acute periapical infection

The acute inflammatory reaction at the apex is also enclosed, this time by bone. The fluid exudate and the presence of oedema tends to force the tooth out of the socket and it will be painful to bite on and there will be a continuous throbbing pain. If this is left untreated then there will be continued pressure built up and the pain will become intense. The pressure of the exudate and pus so formed will lead to bone resorption and the fluid will track through the

bone along the line of least resistance. Eventually the periosteum may be penetrated resulting in a release of pus and consequent reduction or relief of pain. A symptomless, progressively enlarging swelling is a common finding.

### Chronic periapical infection

This is the more common sequel to pulp death and may arise from low-grade irritation from the root canal, i.e. bacterial by-products leaking out into the apical tissues, or from the partial resolution of an acute response.

The precise pathology is again related to the virulence of the organisms and the host tissue reaction. The lower grade activity results in a more gradual removal of bone and the formation of granulation tissue. It is usually symptomless and often only discovered by radiography.

Alternatively, the chronic response may, if the balance changes in the lesion, exacerbate into an acute one with the symptoms described above appearing.

The apical response is usually induced by toxins and tissue breakdown products only. The bacteria remain within the pulp chamber undisturbed by phagocytes. If any do pass beyond the apical foramen they are usually killed by inflammatory cells. If on the other hand the bacteria leave the root canal in sufficient numbers and/or the inflammatory response loses its potency, then infection of the apical tissues, as opposed to irritation, will follow. The lesion may remain chronic though, with no evidence of the different circumstances.

The apical tissue response in a chronic lesion is usually granulomatous and may be accompanied by proliferation of epithelium. The epithelium originates from the cell rests of Malassez that are the remnants of the epithelial root sheath of Hertwig. The inflammatory process appears to stimulate the growth of the cells. The *chronic apical granuloma* is a mass of chronic inflammatory cells, variable amounts of strands or sheets of epithelium and perhaps some pus, all surrounded by a fibrous tissue capsule.

In certain circumstances the epithelium forms a *periapical cyst*. Various theories of cyst formation have been proposed. These are:

- The block of proliferating cells enlarges and the central cells break down to form a cavity
- Cavities in the granuloma due to pus formation allow the epithelium to proliferate along the surface to form a continuous lining

- Strands and sheets of epithelium join up into a shell by chance

Once the epithelium lines a cavity, osmosis occurs. Fluid passes through the cell layer and the osmotic pressure causes slow expansion. For all this to happen and be seen takes some time, maybe 2 years.

In the chronic periapical lesion therefore there may be a cyst or small cysts within a granuloma or a lesion that is essentially a cyst surrounded by a fibrous capsule, with no granulation tissue outside it. The cyst may become infected, depending upon the movement of bacteria from the root canal.

## Relationship to Clinical Management

It should be clear from this description of the pathology of the carious lesion that in its earliest stages, i.e. the white spot lesion, there may be considerable difficulties in clinical diagnosis.

### Early caries

The surface of the enamel will still be intact and therefore the lesions can only be diagnosed either visually or radiographically. The use of a mirror and strong lighting may indicate a slight change in optical density below the contact area and high-intensity transillumination with a small fibreoptic probe may be more useful. Bitewing radiographs are unlikely to pick up the very early lesion and it is said that by the time a lesion is visible using this means it may well have progressed towards the enamel–dentine junction. All is not lost however, since changes in oral hygiene practice, removal of plaque, administration of fluorides and good dietary control may cause such lesions to remineralise even though they were never diagnosed.

### Remineralisation

Since these early lesions are cycling between destruction and repair, the clinician aims to tip the balance towards repair. There is some evidence that such remineralised lesions may resist further attack better than normal enamel. It may be that many patients diagnosed as caries free have in fact remineralised early lesions from their own saliva.

Once cavitation of the surface has occurred, remineralisation will not replace the normal contour of the tooth. For this reason probing should not be used in diagnosis of early lesions, since cavitation may be

produced by the clinician. The early diagnosis of carious lesions has been discussed in Chapter 2.

Very early caries is perhaps best diagnosed by a study of the risk factors to which the patient is subjected. Therefore, a good diet history will be needed and it is clear that the younger patient is at greater risk than the older. The adequate secretion of saliva and its buffering capacity should be investigated and it may be useful to look at the types of organisms present in the saliva so that the high-risk *Lactobacilli* and *Streptococcus mutans* may be discerned.

### Excavation of caries

Once the caries has involved the dentine it will be necessary to remove softened and infected necrotic material. It is clear from the progression of the lesion that this may involve a larger cavity than at first appreciated since the lesion will have extended along the enamel–dentine junction. It is believed necessary to remove all of the infected dentine at the junction. When the softened dentine in the bulk of the lesion has been removed the decision has to be made on how to deal with the infected area of dentine overlying the pulp. The approach that has been followed for many years is to remove the infected dentine leaving the demineralised but uninfected translucent zone over the pulp intact.

Newer techniques involve leaving bacteria in situ and killing them with a disinfection process. This is discussed in Chapter 11. Providing that the tooth has been symptomless and appears to be vital, the translucent area of dentine covering the pulp may be capped with a calcium hydroxide paste, the rationale here being to protect the pulp and induce the formation of reparative dentine. If there is clinical evidence of acute or chronic inflammation of the pulp, usually by symptoms, then the inevitable sequel may be death of the pulp requiring eventual root canal therapy or extraction.

The reactions of the pulp underlying carious lesions may give some clinical information to the dentist as to the health or otherwise of the tissues. Thus, a patient who complains of transient pain following hot and cold drinks, the pain lasting for the duration of the stimulus, may well have pulpal hyperaemia which may be reversible if stabilisation of the cavity is achieved using the methods described. Once the pulp has become infected it may, if the inflammation is chronic, produce no symptoms. Under these circumstances the patient may complain of no pain and the pulp may eventually recover. However, it may

slowly die without symptoms and the dentist should be aware of this possibility and keep future checks on the health and vitality of that particular tooth. If the patient complains of continuous lancing pain then the tooth pulp is almost certainly acutely inflamed and a vital removal of the pulp or the tooth is probably indicated. In patients where this has not occurred the acute continuous pain may eventually resolve for a time as the inflammation expands through the apical foramen and the pressure is released. During hyperaemia the patient may be able to localise the intermittent sharp pain to a particular tooth but when acute pulpitis intervenes the pain may radiate over a larger area. As the inflammation extends into the periapical tissues and in the absence of the satisfactory response by the patient it may eventually involve alveolar bone. The pain may then become deep seated and throbbing and may be localisable because the tooth is tender to

percussion or biting. If the infection extends through the bone, producing a localised osteitis, it may track through the bone, reducing the pressure somewhat and therefore the pain but then raise the periosteum either buccally or lingually to again produce severe pain and the presence of an apical abscess. If this abscess discharges into the buccal or lingual sulci the pain may again cease because of reduction of pressure. However, it may spread above the level of attachment of the muscles of the mandible and maxilla and the final sequel is a *cellulitis* or facial swelling over the area. Patients are likely to seek emergency dental treatment at any point where the pressure is high either in the pulp, the periapical tissues, the bone or in the facial tissues. Reduction of pressure at certain stages of the advance of the infection explains why patients may report decrease or absence of symptoms even though the lesion is progressing.

# Chapter 7

## The Periodontium in Health and Disease

This chapter and Chapter 13 will summarise those areas of periodontology that are of clinical relevance to an understanding of the disease, its treatment and restorative dentistry. The text will be almost entirely devoted to gingivitis and chronic periodontitis. The space available does not allow for an exhaustive text on periodontology and readers are referred to the Bibliography for additional reading.

### Introduction

Periodontal disease, which encompasses gingivitis and periodontitis, is highly prevalent in all populations. The development of gingivitis is due to the accumulation and maturation of supragingival plaque and subgingival plaque is associated with the advancing lesions of periodontitis. As periodontitis progresses, bone loss will compromise the integrity of teeth resulting in looseness and/or drifting out of their normal alignment. In planning restorative dental procedures the periodontal status of the individual must be considered and rectified, if unhealthy, before commencing restoration of the dentition. As importantly, the consequences of particular restorative procedures to periodontal health should be evaluated, particularly in the treated periodontal patient who clearly has a susceptibility to the disease.

### The Healthy Periodontium

#### Definition

The periodontium comprises the tissues investing and supporting the teeth, namely the *gingiva*, *alveolar bone*, *periodontal ligament* and *cementum*.

#### The gingiva

The gingiva is the only tissue of the periodontium that is visible and comprises the *marginal* and *attached* gingiva that are separated from each other by the *free gingival groove* and from the alveolar mucosa by the *mucogingival junction*. The tissue is pink in colour and may be stippled to produce an 'orange peel'

appearance. The colour may be modified by different degrees of melanin pigmentation and keratinisation.

The structure consists of keratinising stratified squamous epithelium attached to the alveolar bone by connective tissue. There are collagen fibres embedded in an extracellular matrix that are arranged in groups by virtue of their orientation and named:

- Circular (around the teeth)
- Transeptal (joining teeth)
- Dentogingival (cementum to free gingiva)
- Dentoperiosteal (cementum to attached gingiva)
- Crestal (alveolar crest to attached gingiva)

The *marginal gingiva* forms a cuff 1–2 mm wide around the tooth and fills the interdental space as a labial and lingual papillae joined by a *gingival col* between the tooth and below the contact point. It forms the gingival crevice (0–2 mm deep) and here is lined by crevicular epithelium that is non-keratinising stratified squamous epithelium.

The marginal gingiva is joined to the tooth at or just above the cemento–enamel junction by the junctional epithelium that has cells arranged parallel to the tooth surface with wide intercellular spaces, and contains small numbers of neutrophils.

The *attached gingiva* is a mucoperiosteum tightly bound to the alveolar bone and has a variable width that does not correlate with health. The absence of attached gingiva is not necessarily pathological providing plaque control is adequate.

*Alveolar bone* consists of cancellous bone covered by a thin layer of compact bone that supports the teeth and is tooth dependent; it resorbs to a variable degree when teeth are lost. The bone adjacent to the tooth root is perforated (the *cribriform plate*) and receives the insertion of the periodontal ligament fibres.

The alveolar crest maintains a relatively constant distance of 1–2 mm from the cemento–enamel junction (*biologic width*).

The *periodontal ligament* suspends the tooth in the socket and acts like a viscoelastic shock absorber permitting small movements of the teeth when under load. It consists of principal collagen fibre bundles (*Sharpey's fibres*), namely *alveolar crest*, *horizontal*, *oblique* and *apical*, all of which extend from the cementum to the alveolus. It has a very high connective tissue turnover.

*Cementum* is the usually thin layer of calcified connective tissue covering the whole of the root surface and into which the periodontal ligament fibres are inserted. There are two types, *acellular* (cervical area) and *cellular* (mid and apical area), depending on the presence of cementocytes within the structure.

## Periodontal Disease

This section will consider *gingivitis* and *periodontitis* as essentially separate entities. At present, there is insufficient evidence to permit the conclusion that factors relevant to gingivitis are relevant to periodontitis. The concept that plaque causes gingivitis and, in time, gingivitis inextricably progresses to periodontitis that in turn, left untreated, leads to tooth loss, is no longer accepted.

Nevertheless, gingivitis and periodontitis are not mutually exclusive nor unrelated; indeed gingivitis is one aspect of periodontitis (see definition of periodontitis). Data indicate that not all gingivitis progresses to periodontitis and populations with poor oral hygiene and severe gingivitis have incidences of periodontitis little different from those populations with less plaque and gingivitis.

Gingivitis is thus a poor predictor of future periodontitis in the as yet unaffected individual or tooth site. Even in individuals treated for periodontitis and therefore by definition susceptible to the condition, the recurrence of gingivitis is a poor predictor (30%) of recurrence of periodontitis.

Conversely, and most importantly, the absence of gingivitis is highly predictive (99%) of no recurrence of periodontitis. Taken together, the evidence supports the concept that periodontitis is always preceded by gingivitis and the prevention of gingivitis through supragingival plaque control will prevent the occurrence or recurrence of periodontitis. This concept has widespread implications for public health preventive programmes for periodontal disease and is

also of major relevance to the total care and long-term management of the restorative patient. A high standard of supragingival plaque control must be practised by all patients, particularly those who already exhibit a susceptibility to periodontitis.

## Gingivitis

### Definition

Gingivitis is inflammation of the marginal gingiva without loss of attachment.

### Clinical features

Inflamed gingiva exhibits redness, variable swelling, bleeding, usually in response to minor trauma such as tooth brushing, and increased flow of the crevicular fluid. Pain is not usually present, although vague sensory symptoms may be reported by some individuals (wedging, tingling, itching).

### Aetiology

Epidemiological data have shown a strong correlation between plaque and gingivitis (correlation coefficient  $\approx 0.8$ ).

Controlled clinical trials have proved a direct cause and effect relationship between plaque and gingivitis. This forms the basis for the prevention of gingivitis and logically, therefore, periodontitis through the control of supragingival plaque.

### Plaque formation

Enamel in the mouth is always covered by a salivary pellicle of glycoprotein that increases in thickness with time to several micrometres. Even if removed by polishing, pellicle reforms in minutes. Primary plaque forming bacteria, gram-positive facultative streptococci such as *Streptococcus sanguis* and some gram-negative actinomyces species, attach to this pellicle. These primary plaque formers are essential for the attachment of other bacteria.

The adsorption mechanism is complex and involves a number of forces and physical interactions between the bacteria and oral surfaces. Compatible surface free energies, hydrophobicities and specific attachment sites are important factors in bacterial adherence. Bacterial seeding is slow and the plaque mass increases mainly by bacterial division.

Over a period of a few days increased proportions of anaerobic gram-negative cocci attach and proliferate. These are followed by rods and filamentous bacteria such as fusiforms and finally spirochaetes and other motile rods can be found. Supragingival plaque

thus develops in thickness and complexity and these are almost certainly mutually dependent processes. It is in association with the later stages of plaque development that the clinical features of gingivitis appear.

### Pathogenesis of gingivitis

Bacteria are not thought to penetrate crevicular epithelium but induce an inflammatory response in the gingiva by chemical by-products. Bacteria release a range of enzymes capable of damaging all cellular and supporting tissues of the gingiva and these also allow the penetration of high-molecular-weight bacterial endotoxins through crevicular epithelium. The net result is an inflammatory response with elements akin to both acute and chronic inflammation. Neutrophils and macrophages accumulate in the connective tissue and pass into the gingival crevice. Vascular dilatation and vascularity increases with fluid extravasation and lymphocytes and plasma cells appear within the tissues.

### Epidemiological considerations

Gingivitis is considerably less prevalent and less severe in the primary dentition whilst periodontitis affecting deciduous teeth is rare and usually a feature of an underlying systemic disease affecting host defence, e.g. cyclical neutropaenia.

Gingivitis is highly prevalent (100%) in the permanent dentition from a young age whilst the severity and number of sites affected varies at the extreme in individuals. The most important factors influencing the severity of gingivitis relate to those that influence the oral hygiene practices of individuals by either directly or indirectly affecting compliance and dexterity.

In general, oral hygiene and gingival health are worse in:

- Low social classes
- Males compared to females
- Pre-teenage years compared to teenage (further increase in age has little effect on oral hygiene)
- Individuals who brush less than twice daily (further increases in tooth brushing frequency do not improve oral hygiene)
- Smokers
- Physically and mentally handicapped individuals
- Right buccal quadrants of the dental arches in right-handed tooth brushers
- Individuals wearing removable dental prostheses or fixed or removable orthodontic appliances

Oral hygiene and gingival health is little affected by:

- Tooth crowding
- Mucogingival anomalies such as high fraenal attachments and shallow sulci
- Narrow zones or absence of attached gingivae

Gingival health is *always* compromised by restorations that encroach upon the gingival crevice.

### Modifying factors

The gingival response to supragingival plaque appears to be exaggerated or changed by certain local and systemic factors including:

- Incompetent lips and mouth breathing, particularly during adolescence
- Puberty
- Pregnancy
- Contraceptive pill
- Drugs – notably epanutin, ciclosporin, nifedipine and other calcium channel blockers, notably amlodipine, felodipine and lacidipine, that may result in gingival hyperplasia
- HIV infection
- Neutropaenias, notably cyclical neutropaenia
- Leukaemias, particularly acute leukaemias where marked swelling may occur due to gingival infiltration with large numbers of leukaemic cells
- Nutritional deficiency, notably of ascorbic acid

*Note.* Some of the modifying factors listed above for gingivitis do not appear or have not been proven to modify periodontitis (see Periodontitis).

### Strategies for the prevention of gingivitis

The basis for the management of gingivitis is supragingival plaque control. Two aspects are important:

- Preventing the development of a mature pathogenic plaque (*primary control*)
- Removing or modifying factors that facilitate plaque formation and retention (*secondary control*)

*Primary control* may be achieved by mechanical and chemical approaches namely:

- Preventing bacterial attachment (*antiadhesive approach*)
- Preventing bacterial proliferation (*antimicrobial approach*)
- Regularly removing accumulated plaque (*mechanical and chemical cleaning approach*)

All of these approaches are possible and have been achieved in other conditions where microbial plaques pose problems. In the oral cavity success to date has only been achieved realistically with the antimicrobial and mechanical cleaning approaches (see Chapter 13).

*Secondary control* has preventive and therapeutic implications for restorative treatment that involves:

- The preparation and placement of restorations
- Positioning of margins in relation to the gingiva
- The design and precision of construction of fixed and removable prostheses

Therapeutic considerations concern the replacement or removal of fixed or removable restorative plaque traps, treatment of carious cavities and the removal of supragingival calculus.

## Periodontitis

### Definition

Periodontitis may be defined as gingivitis with loss of attachment, typically producing a *periodontal pocket*. This is a useful definition since it describes the histological lesion of periodontitis and suggests an approach to management that is based on preventive and therapeutic strategies.

### Clinical features

Loss of attachment whereby the junctional epithelium migrates along the root surface resulting in the formation of a pocket. The *true pocket* is measured from the cemento–enamel junction to the base of the attachment, whereas *pocket depth* is the distance from the gingival margin to the base of the pocket.

Pocket depth may therefore be greater than the loss of attachment when the gingival height is above the cemento–enamel junction or be less than the loss of attachment when the gingival margin is below the cemento–enamel junction (recession).

Colour change is variable in periodontitis. The gingival margins may exhibit all the features of gingivitis or appear perfectly normal. Usually, however, there is bleeding on probing when the probe is inserted to the base of the pocket and a purulent exudate may also be seen at the pocket orifice. Pain is not a feature of periodontitis although vague sensory symptoms may be reported, such as awareness of the teeth.

### Aetiology of periodontitis

Sub-gingival plaque, derived from supragingival plaque, is always associated with the advancing

lesions of periodontitis. The progression of gingivitis to periodontitis is thought to occur when *periodontal pathogenic micro-organisms* act upon a *susceptible host*.

### Periodontal pathogens

In excess of 400 species of micro-organisms have been found in periodontal pockets and about a third of these have yet to be identified. To date approximately 20 are considered putative pathogens and most of these are obligate anaerobes.

Strong evidence exists for the following organisms to be considered actual pathogens:

- *Aggregatibacter actinomycetemcomitans* (facultative anaerobe)
- *Porphyromonas gingivalis*
- *Tannerella forsythia*

Less strong evidence supports *Campylobacter*, *Eubacterium*, *Fusobacterium*, *Prevotella*, *Peptostreptococcus* and *Eikenella* as periodontal pathogens. The mere presence of these organisms in periodontal lesions is not necessarily indicative of progressing disease.

Microbiological diagnosis is therefore of little or no value in the diagnosis and management of periodontal disease; this includes the decision to use antimicrobial therapy and the choice of agent.

The micro-organisms associated with periodontitis can be found at several sites:

- Periodontal sites:
  - Root surface
  - Pocket lumen
  - Pocket epithelium
  - Dentinal tubules
- Oral sites:
  - Tongue
  - Tonsil
- Extra-oral sites:
  - Spouse/partner
  - Family pet

### Susceptibility

There is some evidence for a major gene effect in some forms of aggressive periodontitis that dictates susceptibility. Similarly, a specific variation of the IL-1 gene cluster regulating IL-1 production has been associated with increased susceptibility to severe chronic periodontitis.



Neutrophil defects are associated with increased or rapid periodontal breakdown that even affect the deciduous dentition. These include cyclical and other neutropaenias, leukaemias, Chediak–Higashi syndrome, Down's syndrome and Papillon–Lefèvre syndrome.

Smoking is a risk factor, probably due to adverse effects on host defence mechanisms, and the response to treatment in smokers appears compromised.

Limited evidence suggests diabetes mellitus, particularly when uncontrolled, is a risk factor and conversely periodontitis may compromise diabetic control.

Stress is suspected as a risk factor for periodontal breakdown but evidence is lacking. Part of the increased susceptibility with smoking, diabetes and stress may be adverse effects on polymorph function.

Excessive occlusal loading and food packing appear to be co-destructive factors in periodontitis, although a definition of what constitutes 'excessive' loading is elusive.

### Pathogenesis

Periodontal lesions typically develop as loss of epithelial attachment at the cemento–enamel junction. Associated with this is widening of epithelial spaces, ulceration of the sulcular epithelium, breakdown of collagen and ground substance and bone resorption.

For this to occur, pathogenic factors must overcome or exceed protective mechanisms. The latter are derived from the intact nature of the sulcular epithelium, gingival crevicular fluid, rapid tissue turnover and non-specific and specific defence and immune systems. The major pathogenic factors are the bacterial enzymes and toxins that can have direct destructive effects and/or initiate adverse host immune responses. These adverse host immune responses include the production of cytokines and host enzymes such as collagenase, probably initiated by bacterial lipopolysaccharide.

### Epidemiological considerations

Chronic periodontitis shows a very low incidence in the second decade of life but increases progressively in succeeding decades. Approximately 60% of 60- to 70-year-olds will have chronic periodontitis affecting one or more teeth. The average rate of progression of periodontitis, measured by radiographic bone loss or loss of attachment, is approximately 0.1 mm/year.

In any population only a small proportion (8–10%) exhibit advanced periodontitis (loss of attachment >6 mm) at one or more sites. A relatively small

proportion of individuals and a small percentage of sites in those individuals account for most of the advanced periodontitis in any population.

## The Periodontium and Restorations

The relationship between the periodontium and the provision of restorations involves certain key areas:

- Prevention
- Treatment planning
- Technical execution
- Maintenance

Whilst gingivitis is almost universal, the accurate prediction of the susceptibility of individuals and particular intraoral sites to periodontitis is not possible. Even in those patients who are known to be susceptible, the site specificity for rapid breakdown cannot be predicted. Therefore, *prevention* of gingivitis or the recurrence of periodontitis must be a high priority for all patients undergoing restorative dentistry.

The provision of restorations for most patients must be viewed as having the potential to influence adversely their susceptibility to gingivitis and possibly periodontitis. Virtually all restorations compromise plaque control and the procedures used to place them may be harmful too. The more complex the restoration so the higher the risk. Treatment plans should therefore be based on providing the minimum number of restorations of the simplest and least plaque retaining types.

When considering the design of bridgework (Section IV) whilst direct masticatory loads are modified by biofeedback where the periodontium is reduced, excessive twisting or tilting forces widen the periodontal membrane space and can cause tooth movement and/or physiological mobility but not loss of attachment. The viscoelastic nature of the periodontal ligament has to be considered when restorations are linked between teeth as in fixed bridgework or when teeth are linked to osseointegrated implants, that have no mobility.

Technical aspects of restorations of importance in prevention or initiation of periodontal disease relate particularly to the effects on the gingival sulcus.

Mechanical instrumentation and restoration margin placement in the gingival sulcus may directly produce loss of attachment, particularly if there is encroachment on the biologic width. The gingival sulcus limits the subgingival extent of restorations and may therefore introduce aesthetic restrictions, particularly

in the anterior region. Subgingival restoration margins always result in a variable degree of bacterial-associated gingival inflammation but this may not necessarily progress to periodontitis. However, overhanging subgingival restorations cause loss of attachment and alveolar bone loss.

Lost interdental papillae can also have implications for aesthetics and surgical mucogingival techniques to rebuild papillae are difficult and unreliable. Once gingival recession occurs, loss of cementum rapidly results thereby predisposing sites to dentine hypersensitivity.

Operative treatment may be required to remove aetiological or co-destructive influences on periodontitis, such as marginal overhangs, negative edges or incorrect restoration contour.

For the maintenance of periodontal health, restorative dentistry must be of the highest quality both in design and in execution. In addition, patients have an equal role to play in performing regular and efficient plaque control. The dentist must ensure that appropriate oral hygiene measures are taught and periodically reinforced as part of the continuing care programme.

### **The Periodontium – Summary**

Plaque control is the key to prevention and management of periodontal disease.

Periodontitis is not a natural progression from gingivitis; patient factors influence the disease process.

Restorations of all types contribute adversely to plaque retention.

## Chapter 8

# Functional Anatomy of the Occlusion

Occlusion is probably the most daunting and confusing subject within restorative dentistry. Much of this confusion arises because there is little scientific evidence to support clinical practice and terminology is often random. There is considerable work on the anatomy and physiology of occlusal function but the establishment of generally agreed principles for occlusal restoration and therapy remains elusive.

This book tries to take a pragmatic approach and considers:

- What constitutes 'normal' occlusal anatomy and physiology (Chapter 8)?
- What are the basic requirements for restoration of the occlusion (Chapter 14)?
- What are the causes and management of 'occlusal dysfunction' (Chapter 28)?

Whilst the word 'occlusion' refers strictly to the act of closing the teeth together, it has come to include the way in which:

- The mandible moves in relation to the skull
- The teeth are aligned in each jaw
- They contact each other during the complicated movements of chewing or speaking
- The dentition should be restored
- Disorders of the masticatory apparatus should be managed

The study of occlusion in a functional sense therefore includes the temporomandibular joints and the neuro-muscular control of mandibular movement, as well as the teeth themselves.

The masticatory apparatus is unique in the whole body because of the close interactions between differing structural entities. Malfunctions in the joints themselves, the muscles operating them, the neuro-muscular reflexes controlling them or imperfections in the interdigitation of up to 32 teeth may all result in dysfunction of the masticatory apparatus as a whole.

### The Temporomandibular Joints

The articulation between the fused right and left portions of the maxilla and mandible is by the temporomandibular joints (TMJ). Each is unique in the body in terms of function since it is the only place in which left and right joints are linked via a relatively inflexi-

ble bone, the mandible. This means that movements of each joint may not take place independently of the other and therefore it is possible that undue stresses on one joint may be transmitted to the other. The joints are also unique in that their pattern of movement and the forces transmitted to them are modified by the teeth.

### Anatomy

The upper part of the TMJ is composed of the *glenoid fossa* which is an oval depression in the base of the temporal bone. This depression is bounded anteriorly by the *articular eminence*, a bony swelling down which the head of the *mandibular condyle* will move during function.

The glenoid fossa lies immediately in front of the external auditory meatus, and its posterior border is limited by the squamo-tympanic fissure and the post-glenoid tubercle. The tubercle is a small, conical eminence separating the articular surface from the anterior margin of the tympanic part of the bone.

The roof of the glenoid fossa is sufficiently thin to be transparent if transilluminated in a dried skull which suggests that the joint is not adapted to bear much stress.

The other half of the joint is the *condylar process* of the mandible, a rounded structure about 15–20 mm in the mesiolateral dimension and 8–10 mm antero-posteriorly. The long axis of each condyle is angulated so that lines drawn through them will meet at a point posterior to the mandible itself. This is because the

condyles appear to be set at right angles to the main body of the mandible on each side.

In the adult, the articulating bony surfaces of both condyle and glenoid fossa are composed of dense cortical bone that is covered by dense fibrous connective tissue.

## Ligaments

The ligaments probably do not support the joint during normal function, but restrict the *border movements* of the mandible, and therefore define the *envelope* within which all movements occur. There are four ligaments associated with the joint.

The *temporomandibular ligament* extends from the base of the zygomatic process of the temporal bone and the articular tubercle, and runs downwards and backwards to be inserted into the neck of the condyle. It appears to be separate from, and lateral to, the *capsular ligament* that forms a kind of collar around the neck of the condyle and runs upwards to be attached around the periphery of the glenoid fossa.

The capsular ligament completely surrounds the joint cavity to form a synovial capsule.

During opening of the jaw, the temporomandibular ligament restricts hinge movement, but when wider opening occurs, the head of the condyle moves forward onto the articular eminence. This relaxes the temporomandibular ligament and causes the third ligament, the *sphenomandibular*, to become taut. This ligament is situated some distance from the joint itself, and arises from the spinous process of the sphenoid bone, passing downwards and forwards to be inserted into the lingula on the lingual side of the ramus of the mandible.

The fourth ligament is the *stylomandibular*, which extends from the styloid process to the posterior border of the angle. This also limits the anterior movement of the mandible.

## The temporomandibular disc

The joint cavity is divided into upper and lower compartments by a bi-concave, oval-shaped disc of fibrous tissue that is sandwiched between the head of the condyle and the bone of the glenoid fossa. Its inferior surface is concave and its superior surface is convex, and it has the appearance of a baseball cap placed over the head of the condyle with the peak pointing anteriorly.

The crown of the cap is thickened by a posterior band of dense connective tissue, and, at the junction

of the crown and the peak of the cap, there is a second thickening, the anterior fibrous band. Between these bands is a less dense intermediate zone, and behind the posterior band is the bilaminar region, consisting of an upper part attached to the posterior wall of the glenoid fossa and a lower part attached to the back of the condyle (Fig. 8.1).

The borders of the disc are attached to the fibrous capsule of the joint, except anteriorly, where the peak of the disc is attached to fibres of the lateral pterygoid muscle. There may be some attachment of the disc laterally to fibres of the masseter and temporal muscles.

Posteriorly, the disc is attached to a thick layer of vascularised connective tissue, and in this region the disc contains elastic fibres. The part of the capsule inserted into the disc from above, and which is attached to the glenoid fossa, is loose and therefore permits extensive sliding movements of the upper joint compartment.

The lower part of the capsule that attaches the disc to the neck of the condyle is much denser, allowing only hinge movement in the lower joint compartment. A synovial membrane, composed of connective tissue with many capillaries, lines the peripheral parts of the disc and the capsule but does not cover the articulating surfaces. It secretes synovial fluid into the joint spaces. This fluid has a jelly-like consistency and is composed largely of hyaluronic acid. The amount of synovial fluid present in normal function is very small and it is assumed that the joint spaces are normally collapsed.

## Microscopic anatomy of the joint

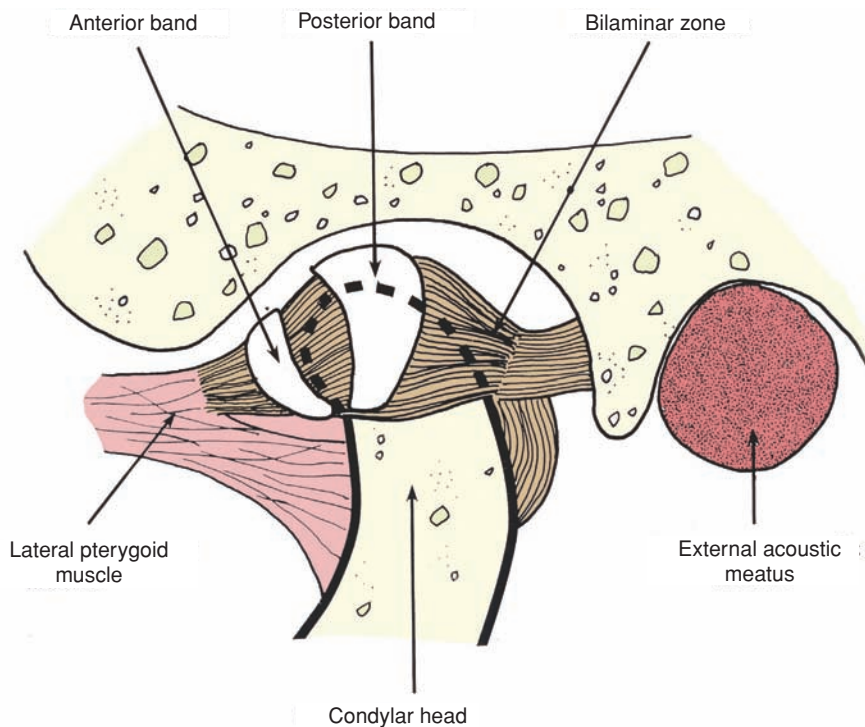
### The bones

The articular surfaces consist of fibrous connective tissue overlying undifferentiated mesoderm that itself overlies a thin layer of hyaline cartilage. This cartilage is most predominant in younger joints, and is a growth cartilage taking part in the normal development of the joint, and may be involved in remodelling processes in adulthood.

Below the layer of cartilage is compact bone covering the cancellous bone of the internal structure of the mandible. In old age, not only may the cartilage zone be lost, but so may the fibrous tissue covering at least some areas, resulting in denuding of the compact bone layer.

### The disc

The central part of the disc consists of dense connective tissue, but peripherally it has a looser texture, rich



**Fig. 8.1** Schematic diagram of the anatomy of the temporomandibular joint showing the articular disc (meniscus) as the shape of a 'baseball cap' lying over the condylar head, and dividing the joint space into upper and lower compartments.

in vessels and nerves, particularly posteriorly in the bilaminar region. The capsule and parts of the disc are innervated by branches of the auriculo-temporal nerve that are arranged so that they are not compressed during movements of the joint.

The blood supply to the temporomandibular joint is from the superficial branch of the external carotid artery.

### The Muscles of Mastication

These may be divided simplistically into closing and opening muscles. However, it must be remembered that relaxation of the closing muscles is necessary to allow the opening muscles to operate, so that all the muscles are operational during mandibular movement.

The *masseter* is made up of two main bundles of muscle fibres originating from the lower border of the zygomatic arch and running downwards and slightly backwards, to be inserted on the lateral side of the ramus of the mandible. Its major function is to close

the jaws together with great force, although it may also protrude the mandible slightly during this movement.

The *temporal* muscle has a broad origin from the lateral surface of the parietal bone and its anterior fibres run more or less vertically, its middle fibres obliquely, and its posterior fibres almost horizontally, all to be inserted into the coronoid process. It is used to position the mandible during closing movements. Usually, the anterior fibres contract first, elevating the mandible, followed by the others to control fine positioning.

The activity of the temporal muscle is extremely complex and unilateral contraction is involved in lateral mandibular excursions. The muscle is extremely important in dysfunction (Chapter 28), since the pain arising from its spasm is reported by patients as headache.

The *medial pterygoid* muscle originates in the pterygoid fossa and its fibres run downwards, backwards and outwards to be inserted into the inner aspect of the ramus. It is able to elevate the mandible and position it laterally. During protrusive and lateral

movements, the activity of this muscle is greater than that of the temporalis.

The *lateral pterygoid* muscle has two heads, one arising from the outer part of the lateral pterygoid plate and the other from the base of the sphenoid bone. The two heads come together and are inserted into the neck of the condyle and, through the anterior wall of the capsule, into the disc. The main function of this muscle is to draw both the head of the condyle and the disc forwards during opening movements. Unilateral contraction will produce lateral movement of the mandible in association with the other muscles.

There are *minor muscles of mastication*, which include the *digastric* and the *buccinator*.

The digastric is an opening muscle running from the mastoid process to a bursa on the hyoid bone and up to the genial tubercles of the mandible. Contraction will draw the chin downwards, but this is aided considerably by gravity so that the muscle is most prominent in the final opening movements.

The buccinator muscles are concerned with maintaining the muscular activity of the cheeks and retaining food on the occlusal surfaces of the teeth.

## Temporomandibular Joint Function

As was described above, the TMJ is capable of two movements:

- Rotation
- Sliding (translation)

Rotation occurs in the lower compartment and the axis for this is the mandibular *hinge axis*. When the condylar heads are in their most posterior superior (retruded) positions in the glenoid fossae, the axis of rotation is referred to as the *terminal hinge axis*. The path of rotation is then called the *retruded arc of closure* or *reflex arc of closure*.

Sliding or translation occurs in the upper compartment.

The disc should locate on the head of the condyle throughout, though during sliding it lags behind the condyle somewhat so that the condyle comes to bear on the anterior fibrous thickening. The lateral pterygoid muscles are the principal protruders of the mandible, moving the discs anteriorly as well. The return movement of the mandible is caused by the elevator muscles of mastication but the disc is returned posteriorly only by the elasticity of the bilaminar zone.

If the discs get out of phase with the condylar heads or the bilaminar zones lose their elasticity, then

‘clicks’ occur during movement. The disc may become trapped anteriorly to the condylar head on closure and the click occurs as the condylar head rides backwards on the posterior band. On the next opening movement the disc is released and moves sharply posteriorly as the condylar head moves forward.

When the mandible moves to open the mouth from its retruded position with the teeth touching, it will initially describe an arc about the terminal hinge axis. At about 15 mm open, further hinge movement is impossible and the condyles slide forwards, taking their discs with them, and continue the rotation on a wider arc until maximum opening is reached (Fig. 8.2). The pathway described forms the posterior boundary of the envelope of border movements (*Posselt's envelope*). The superior boundary of the envelope is determined by the teeth and the remainder to a large extent by the ligaments around the TMJ.

Lateral movement of the condyles within the fossae occurs as the mandible moves to the left or right and is called *side shift*.

## The Teeth

### Centric occlusion

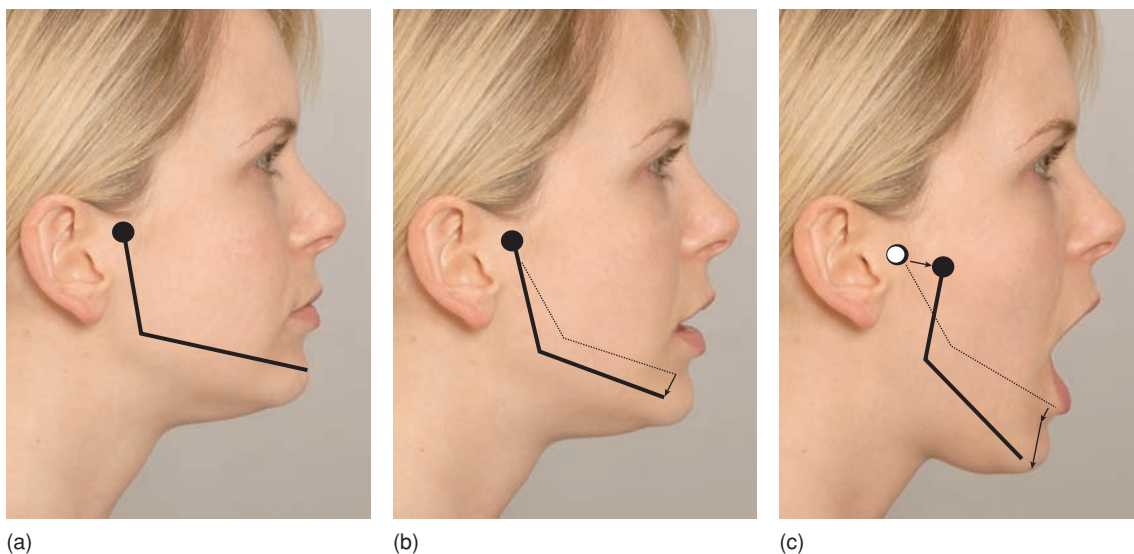
Centric occlusion (CO) is the position of maximum intercuspation of the teeth and is also referred to as the *intercuspal position* (ICP); because it is usually the position where exact interdigitation occurs it may be called the position of ‘best fit’.

CO is used in function to stabilise the mandible for swallowing or as a position for resting during mastication. Most individuals swallow with their teeth together with the lips forming the anterior oral seal. Whilst individuals close their teeth into CO automatically, the position is learnt behaviour and appears to be in the short-term memory.

As a minority behaviour, tooth apart swallowing is recognised. This may be caused by discrepancies in arch form, tooth position or soft tissue morphology; the reader is referred to texts on orthodontics for further reading on this subject.

CO is a position that is used hundreds of times each day for swallowing saliva and is the major reference position for occlusal restoration. The vast majority of restorations are adjusted to CO with the patient being asked to ‘close together onto their back teeth’.

The basic unit of centric occlusion is the *cusp/fossa relationship*, with a *supporting cusp* occluding with a *centric stop* (Fig. 8.3a). The centric stop may be a



**Fig. 8.2** Opening the mouth from the retruded contact position (a), the mandible first describes an arc on the terminal hinge axis (b), followed by protrusion and rotation to wide opening (c). This movement is the posterior border of Posselt's envelope. Opening from centric occlusion would trace an arc slightly anterior to this.

fossa or a pair of marginal ridges or a single sluiceway (Fig. 8.3b). Each cusp will rest in a fossa in a stable relationship having reached this position by eruption. The position of the teeth in CO is maintained as *occlusal stability* with either inclined planes opposing each other (Figs. 8.3 and 8.4) or by the tips of cusps occluding with flat areas – either as a result of wear or because of a natural shallow fossa anatomy. The palatal cusps of the upper teeth and the buccal cusps and incisal edges of the lower teeth are all supporting cusps occluding into central fossae, marginal ridge or cingulum contacts.

If three inclined planes interact to form the cusp/fossa relationship, this is called a *tripod* (Fig. 8.4). Some authorities believe this to be a fundamental occlusal relationship. It is, though, exceedingly difficult to reproduce in restorations and even if it is, the properties of the restorative material may not maintain it (see Chapter 14).

Loss of the cusp/fossa relationship contacts will lead to loss of occlusal stability and tooth movement may follow leading to over-eruption, tilting or rotation.

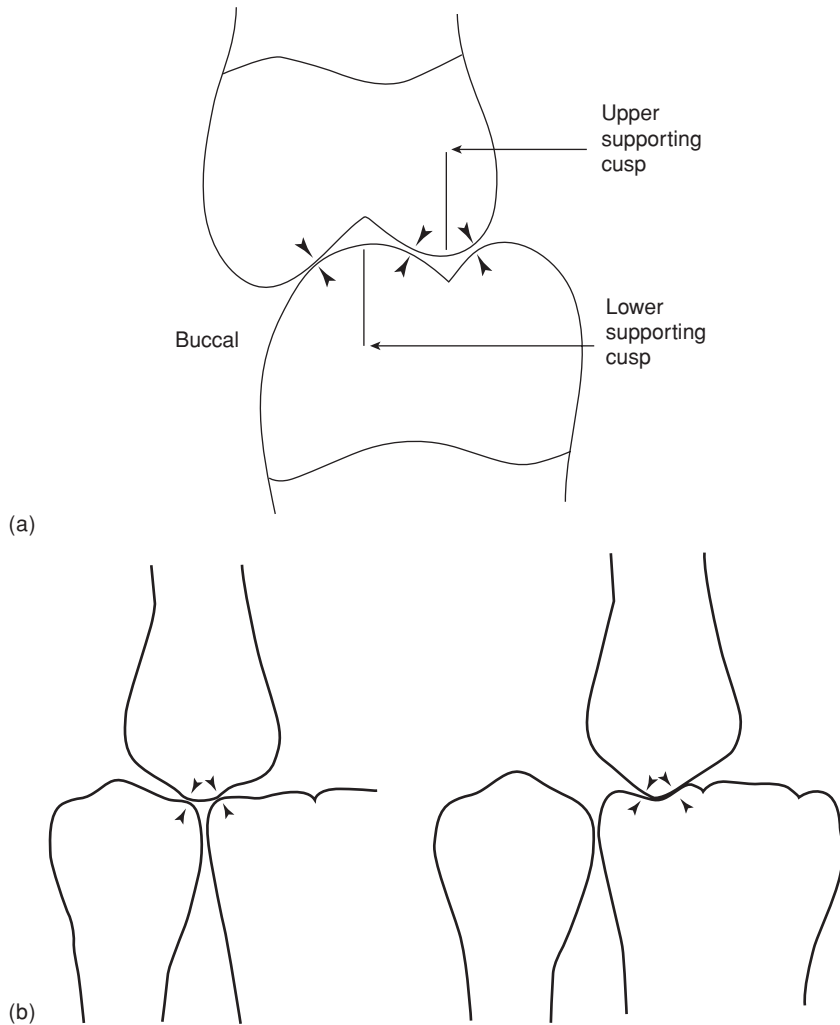
The buccal cusps and incisal edges of the upper teeth and the lingual cusps of the lower teeth do not participate in the arrangement for occlusal stability and are termed *non-supporting cusps*. These cusps have no opposing contacts in centric occlusion

but may contact teeth in the opposite arch in lateral excursions and protrusion (see later). An alternative terminology uses *stamp cusp* instead of supporting cusp and *shear cusp* instead of non-supporting cusp.

### Centric relation

When centric occlusion has been lost, in full dentures for instance, or is unsatisfactory, another reference position must be used for restoring the occlusion. This is *centric relation* (CR). It is important to recognise that this position has been defined for the convenience of restorative dentists and is not a physiological position. This may explain the several definitions that exist for the position.

CR, sometimes referred to in removable prosthodontics as centric jaw relation (CJR), is a position of the condyles within the glenoid fossae unrelated to tooth position. The most common definition used in the United Kingdom is 'the most retruded position of the condyles in the glenoid fossae from which unstrained lateral movements are possible'. However, this is a difficult concept to operate in practice and a rather better definition for practical, clinical use is 'the most superior, posterior position of the condyles in the glenoid fossae'. Some American authorities prefer two other closely



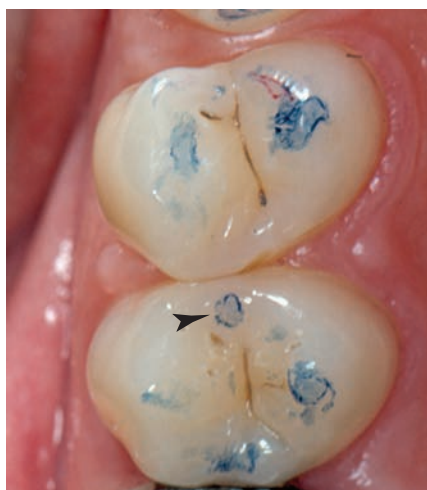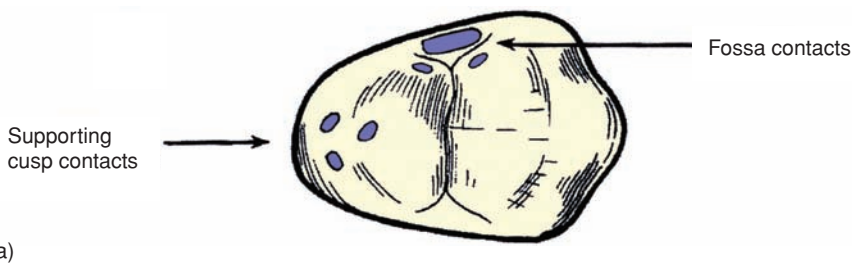
**Fig. 8.3** (a) Cusp/fossa relationship in bucco-lingual section. Stability is provided by the accurate meeting of the inclined planes. (b) Cusp/fossa relationships in mesio-distal section. The upper supporting cusp may occlude with two marginal ridges, or into a sluiceway.

related positions; 'the most superior position' and 'the most superior anterior position'. It is outside the scope of this book to consider the arguments proposed for these but the most important consideration is to obtain a *reproducible* and *symmetrical* mandibular position around which to reconstruct the dentition.

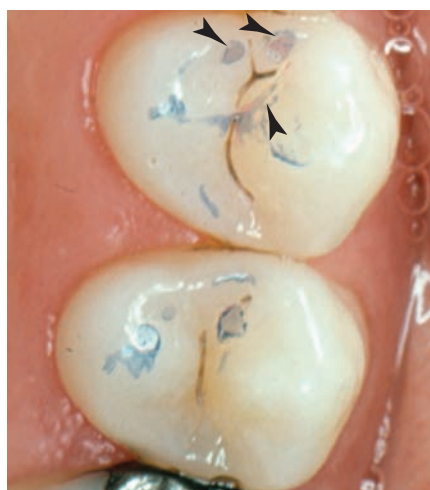CR is usually found by manipulating the mandible and pushing the condyles upwards and backwards. The condyles will then be centred on the terminal hinge axis and the mandible can be 'rotated' by the operator on the retruded arc of closure.

As the operator moves the teeth together, there will usually be tooth contact before CO; this is the *retruded contact position* (RCP), and the teeth involved exhibit a *premature contact*. The movement of the mandible from RCP to CO will have a superior or 'vertical' component, an anterior or 'horizontal' component and perhaps a lateral component (Fig. 8.5). The magnitude of this *mandibular slide* or *displacement* is often defined as the ratio between the vertical and horizontal movement. The shorthand for the ratio is either Vh (pronounced as 'big V, little h') where the vertical component is greater than the





(b)



(c)

**Fig. 8.4** Cusp/fossa relationships. (a) Occlusal view of an upper premolar showing classic tripod contacts, one set in the sluiceway fossa and the other on the tip of the supporting cusp. (b and c) Clinically, this may be obscured by folding of the articulating paper in the fossae, or by natural variations in relationships. The fossa contact in (c) is almost a tripod, whilst that in (b) is a flat contact on the top of the marginal ridge.

horizontal or Hv (pronounced 'big H, little v') where the horizontal component is greater.

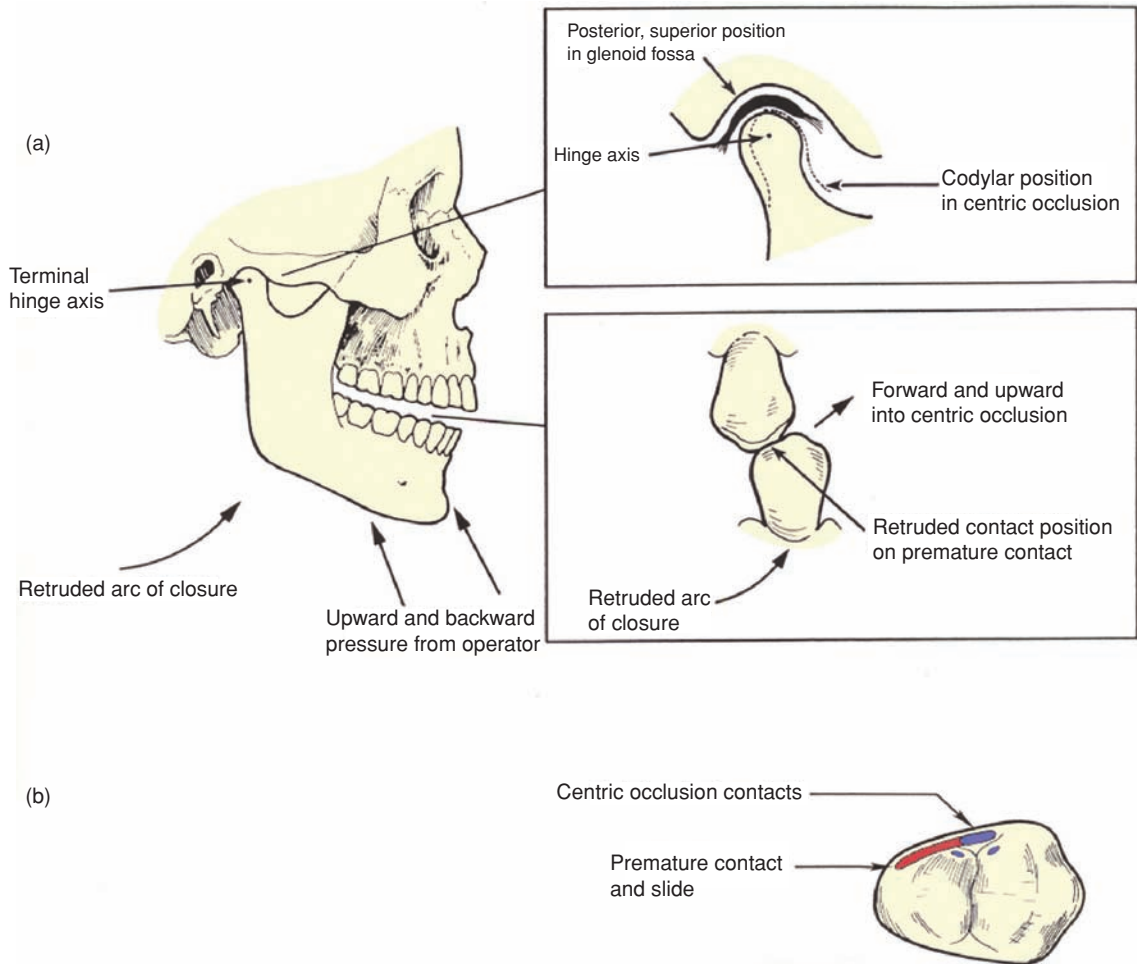
In a minority of patients no mandibular displacement will be seen such that centric relation is coincident with centric occlusion. However, this diagnosis can be suspect in view of the difficulty that can be experienced in the manipulation of the mandible (see Chapter 14).

The significance of mandibular displacements is disputed. A posterior–anterior slide with Vh is very common and it would appear that a separation of CR and CO is natural. The condylar position in CO is between 0.5 and 2 mm anterior to centric relation in the majority of individuals. It may be that this posterior–superior position whilst useful for dental reconstruction is not a position that is used physiologically. When reconstructing the

dentition, the new centric occlusion is made with the condyles in CR, though some limited evidence exists to suggest re-establishment of a more posterior CR within 2 years of reconstruction in dentate patients.

Lateral displacements are less common as are those with Hv. It is possible that a slight asymmetry in mandibular position might lead to muscle fatigue as might a long horizontal component in the mandibular displacement. This is discussed in more detail in Chapter 28.

When individuals close naturally into CO, the prematurities are not contacted; it is part of the learnt behaviour mentioned above to avoid them. Closure occurs straight to CO on a favoured arc of closure. Intrusion by stress, anxiety and so on, into the central nervous system may interfere with the co-ordination



**Fig. 8.5** (a) The retruded arc of closure and a precentric premature contact on two premolars. Following this contact, the mandible slides upwards and forwards into centric occlusion; (b) plan view of articulating paper contacts made during the movement made in (a).

of this behaviour. This may lead to temporomandibular dysfunction (Chapter 28).

### Mandibular guidance

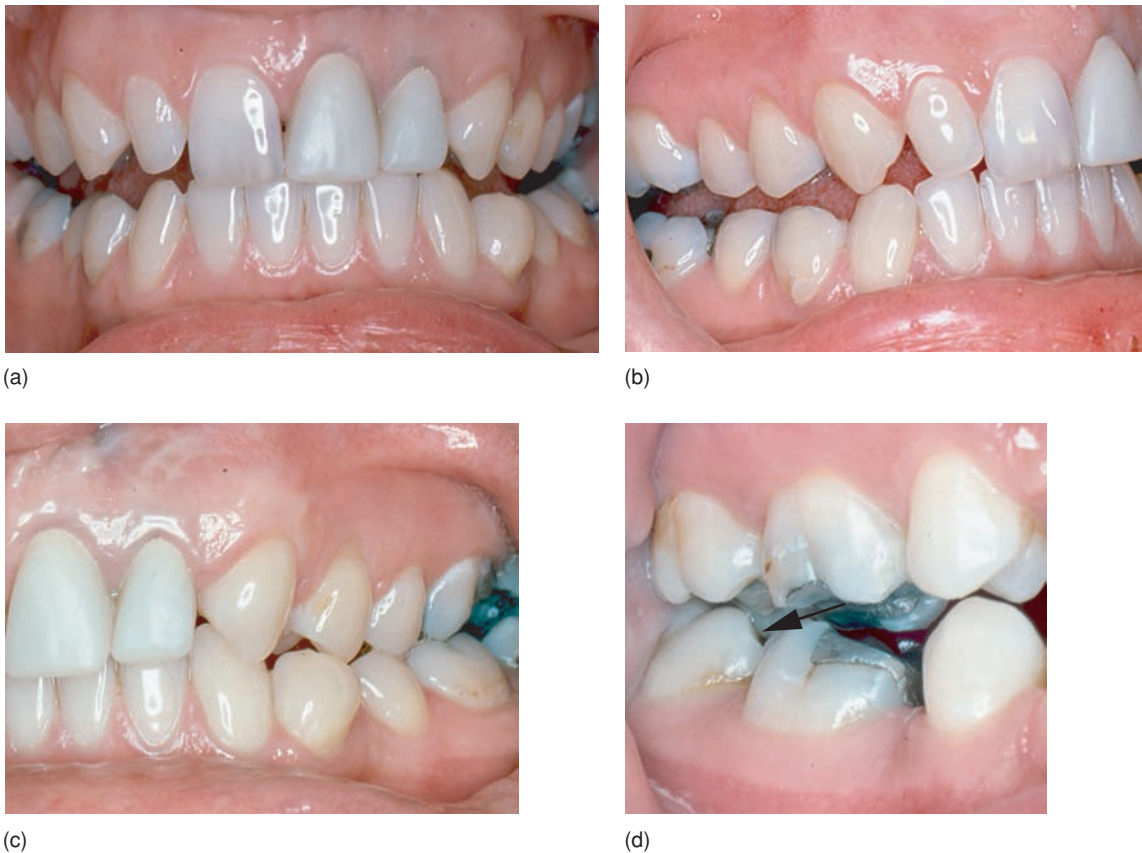The hard tissue guidance of mandibular movements comes from the condyles and their relationship with the glenoid fossae – the *condylar guidance*, and if the teeth are in contact, the tooth-to-tooth contacts – *tooth guidance*. Tooth guidance is made up of *anterior (incisal and canine) guidance* and *posterior guidance*.

Because the condyles can turn and slide, and thus adapt to tooth positions, in practical terms, the

condylar guidance is not as important as the tooth guidance.

### Protrusion

Anterior movement of the mandible from CO results in contact of the lower incisors with the palatal surfaces of upper incisors and the mandible has to open. It moves forward and downwards to incisal edge contact. The posterior teeth are *discluded*, but the amount of disclusion depends upon the height of the anterior guidance, the steepness of the curve of Spee, the cusp height of posterior teeth and their slopes (Fig. 8.6a). The anatomy of these features must be in harmony so that the posterior teeth do not prevent incisal edge contact.



**Fig. 8.6** Tooth guidance. (a) *Anterior guidance*. In sliding forwards with the upper and lower incisors together, the mandible also moves downwards, discluding the posterior teeth. This patient has a high anterior guidance. (b) *Canine guidance*. The movement of the mandible to the right and downwards is dictated by the contact of the upper and lower canines and the slope of the condylar guidance on the left, non-working side. (c) *Group function*. There are multiple contacts between the upper and lower teeth when the patient moves to the left. (d) Non-working interference between the upper and lower second molars (arrowed).

### Lateral excursions

This is also referred to as *mandibular side-shift*. The lateral movement is usually also accompanied by a downwards movement caused by the tooth guidance. The side towards which the mandible is moving is the *working side*. The opposite side is the *non-working side*. In complete denture prosthetics the non-working side is referred to as the *balancing side* because of its relationship to denture base stability (see Chapter 26).

During lateral excursions, the non-working or *orbiting* condyle moves smoothly down the articular slope and medially towards the working side. The angle of the medial movement is the *progressive side-shift*. The working side condyle merely turns without coming forward. In some individuals, there may be also a bodily movement of the mandible

and both condyles as soon as the lateral movement commences – the *immediate side-shift*.

The tooth guidance for the lateral movement may be *canine guided/protected* or in *group function*. In canine guidance, the lateral movement is guided only by upper canine to lower canine contact, coupled with the condylar guidance from the non-working side condyle (Fig. 8.6b). All other teeth should be discluded. In group function, on the other hand, multiple contacts of the cheek teeth occur (Fig. 8.6c).

There have been arguments as to which of these guidance arrangements should be used in reconstruction of the dentition. The ‘popularity’ of group function as a restorative scheme arose from studies of primitive peoples who ate an abrasive diet, thus losing cusp tips and bringing several teeth into contact

in lateral movement. This is therefore argued as the 'correct' scheme for man. However, in western races, canine guidance predominates in people under 40 years of age, whilst group function tends to occur after this age due to tooth wear.

Therefore, to favour one scheme to the exclusion of the other would seem to be illogical. As will be described later, it is better to conform to the scheme already present, unless there are positive contraindications.

In both canine guidance and group function there should be no tooth contact on the non-working side. If there is contact, this is referred to as a *non-working interference*. Classically, on lateral excursion, the second molars of the non-working side may be in contact (Fig. 8.6d). This is considered to be a departure from occlusal norms and might be a predisposing factor in temporomandibular dysfunction. The 'proper' relationship is that the mandible should have tooth guidance on the working side, but only condylar guidance on the non-working side.

### Tooth contacts in function

The teeth do not usually meet during mastication since the food is between them. They attain tooth contact in centric occlusion for swallowing or for rest between a series of chewing strokes. During eating, the mandible describes some form of 'tear-drop' pathway, with a favoured chewing side.

Mouth empty movements, *parafunction*, may involve tooth contacts and these may be habitual. In terms of restorations, it is important to reproduce exact and accurate tooth morphology so that this type of sub-conscious movement is not impeded with the possible result of occlusal dysfunction.

## The Physiology of Mastication

When an individual is at rest, with maximum relaxation of the jaw muscles, the teeth are not in contact but are separated by the so-called *freeway space* of about 2 mm. This is the physiological rest position of the mandible. There appears to be electrical activity in the jaw muscles even when at maximum rest, suggesting that the freeway space is maintained by muscle tone monitored by muscle spindles (see below), rather than by the elastic properties of the muscles and surrounding tissues.

The control of mastication is an extremely complicated activity and only the main principles can be covered here (Fig. 8.7). Insofar as brain mechanisms

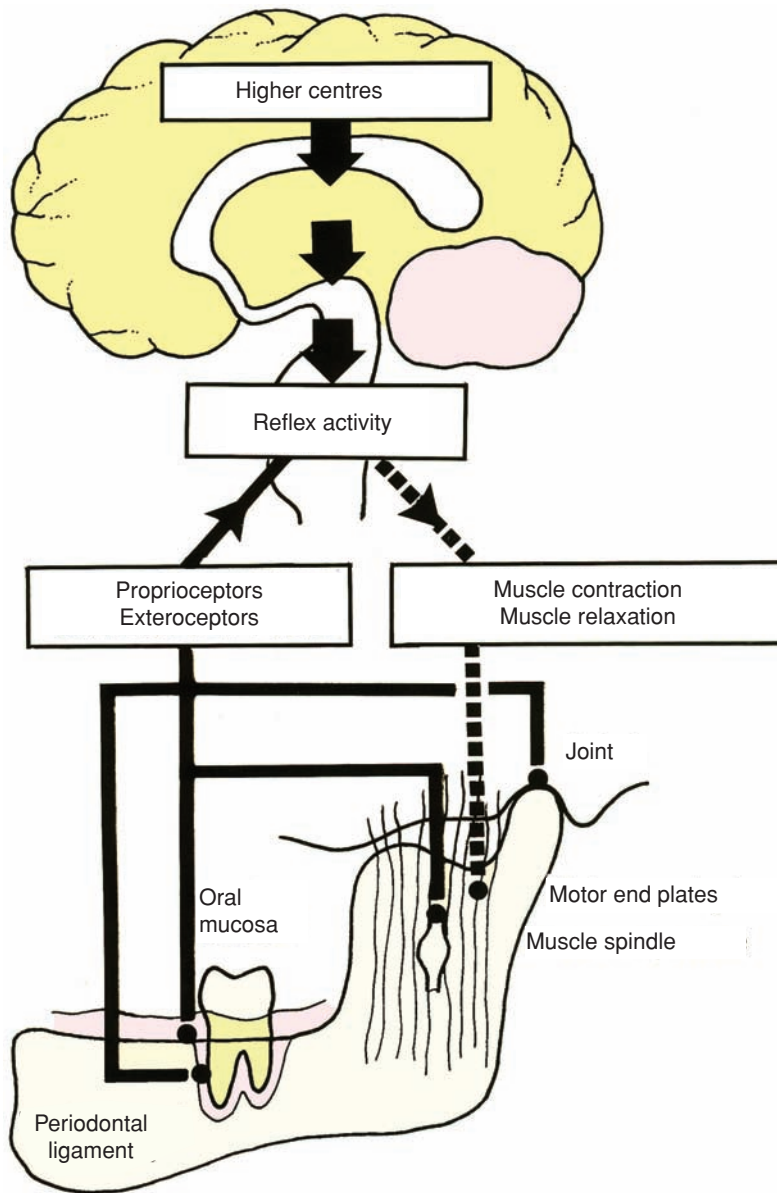
are concerned, it appears that there are centres in the cortex, in the hypothalamus and limbic systems, and in the brain stem itself, each of which has central pathways to the trigeminal nucleus and thus controlling the muscles of mastication. In addition, the jaw movements used during speech are controlled quite separately. Disturbances in the central mechanisms controlling mandibular movements may result in clinical conditions such as bruxism (Chapter 26).

The direct control of the muscles of mastication is via the trigeminal motor nucleus lying in the middle level of the pons. Each individual muscle is innervated by a motor neurone in a particular region of the motor nucleus.

The activity of the muscles is monitored continuously via their proprioceptive reflexes, which are largely controlled via the muscle spindles that exist in all the masticatory muscles. They are found in large numbers in the jaw elevator muscles, but much less in the depressors. The muscle spindles consist of specialised intrafusal fibres enclosed in a thin capsule and lying parallel to the main extrafusal muscle fibres or ordinary contractile fibres. Each muscle spindle contains both nuclear bag and nuclear chain fibres, the stretch in which is monitored by primary myelinated group I afferent nerves and thinner myelinated group II nerves. Stretching of the main muscle results in stretching of the muscle spindles, resulting in information being sent to the central nervous system. These spindles therefore monitor the stretch reflex of the muscles.

Information from the central nervous system and alpha efferent nerves returns to the extrafusal or main muscle fibres causing them to contract. The sensitivity of the muscle spindles is adjusted by motor enervation of the intrafusal fibres within the spindle. These consist of two types called static and dynamic fusimotor fibres, and are supplied by gamma I or gamma II nerve endings. This system means that when normal muscle tone is maintained, the spindles are detecting stretching or shortening of the muscle.

However, if the muscle contracts considerably, the spindles would no longer detect slight changes of length. At this point, the gamma motor neurones shorten the spindle so that it is again able to monitor muscle tone. Information is also sent to the central nervous system from Golgi tendon organs that are much less sensitive than muscle spindles. Information from these appears to have an inhibitory effect on the motor neurones so that the muscle spindles and Golgi tendon organs work together to maintain functional activity of the muscles.



**Fig. 8.7** Schematic diagram of the neural control of mastication. Proprioceptive and exteroceptive information from the muscles and oral tissues is processed in the brain stem. Under the influence of higher centres, motor impulses are relayed to the muscle end organs.

These reflex arcs control various reflexes in the masticatory cycle. These are jaw-opening reflexes, a variant of which is the horizontal jaw reflex occurring in lateral or horizontal movement.

There is also a jaw-closing reflex, which 'operates' the reflex arc of closure. However, the normal path of closure is not the reflex one, but the habitual one that achieves centric occlusion efficiently.

In addition to the information from the muscle spindles and Golgi tendon organs, information is fed

to the central nervous system from receptors in the joints, particularly in the capsule of the TMJ and in the peripheral parts of the articular disc. There are also receptors in the periodontium that range from non-specialised nerve endings to more complex structures. Pain is monitored via sensory nerve endings and directional sensitivity may be associated with mechano-receptors. The presence of food in the mouth is monitored by exteroceptors in the oral mucosa.

## The masticatory cycle

It seems that when food is placed in the mouth its contact with the oral mucosa initiates, through sensory nerve endings, the commencement of the masticatory cycle. The size, hardness, taste and texture of the food is appreciated and this information is processed by an 'oscillator' system in the brain stem close to the trigeminal nucleus so that rhythmic chewing movements begin. These movements are modified by reflex activity originating from nerve endings in the muscles of mastication, the periodontium, the oral mucosa and the TMJs, and are modified by the guidance planes provided by the joints, but more particularly by the teeth themselves.

When the information reaching the central nervous system suggests that the food is well comminuted and

formed into a bolus, *deglutition* begins. The relevant part of this is that the mandible goes into centric occlusion to be 'locked' in that position so that the pharyngeal constrictors and the tongue can operate from a firm base, and an anterior seal can be provided.

In such a complex system, instability of teeth, missing teeth, teeth in malocclusion or premature contact, pain in any tissues of the mouth, disturbances in the joint itself or influence from the central nervous system require considerable adaptation by the individual to maintain efficient function. Clinical dental procedures are aimed at restoring the harmony between all the components of the masticatory system but often depend on the patient tolerating and managing to use the restorations.

### Functional Anatomy of the Occlusion – Summary

The anatomy and physiology of the temporomandibular joints, ligaments and muscles of mastication and their relationship to the function of the teeth is the basis of occlusion.

The many terms used in describing the function of the teeth and the joints are a source of confusion and there are conflicting forms of terminology proposed by different authorities. The terms defined here are used throughout the book.

The success of much restorative dentistry depends upon the correct shaping of the functional surfaces of restorations to comply with the functional anatomy described here.

## Chapter 9

# Properties of Restorative Materials

Understanding the formulation, basic properties and clinical behaviour of restorative materials is the key to their correct usage. All materials have limitations and must be used to their best advantage within a well-considered treatment plan. Restoration design is to a large extent governed by the properties of the material chosen. This chapter considers the commonly determined physical and chemical properties of materials, how these compare with those of tooth substance and the implications, in general terms, for clinical practice.

The mouth is a hostile environment for restorative materials. Within this environment they are subjected to physical and chemical stresses from the occlusion, the diet, plaque and the behaviour of the patient. The various effects are listed in Table 9.1. It is against their behaviour in this environment and their ability to be handled easily that materials must be judged.

The requirements of an ideal restorative material are:

- Physical properties equivalent to those of tooth
- Insoluble in oral fluids and diet
- Adhesive to tooth, sealing and stabilising the tooth/restoration interface
- Dimensionally stable
- Chemically inert, non-toxic
- Cariostatic and bacteriostatic
- Tooth coloured
- Easy to handle
- Cheap

In relation to the first requirement, various physical properties of tooth tissues are shown in Table 9.2, but what these values do not reveal is the way in which a tooth, a very complex composite structure, functions. Also, as with many physical properties, the physical values vary not only with the site of the tissue, but also with the way in which it is tested.

Whilst enamel is a brittle crystalline solid, dentine is viscoelastic, being able to deform under load and recover subsequently. The combination of the two make a very interesting engineering structure with the response to an applied load revealing it to be very durable, much better than if the two tissues act alone. However, in analytical terms their combined constants are almost impossible to determine abso-

lutely. Add to this the elasticity of the periodontal ligament that absorbs some occlusal loading, and the puzzle is complicated even further.

Therefore, one can only sympathise with the bio-materials scientist who is called upon to design replacements for lost or excised tissues.

### Physical Properties of Restorative Materials

Various physical criteria may be used to describe materials and test their ability to restore teeth. Table 9.3 lists some physical properties that are often quoted to justify clinical usage.

Historically, the basis for acceptance of a new material was to select a group of clinically successful materials and characterise it by laboratory tests. The new material could then be judged against the values for the materials already in use for that particular application.

Unfortunately, this approach is very restrictive of new developments, and the application and significance of some 'standard' tests is open to question. Also, many materials are used in combination: metal-ceramics, dentine adhesives and composites, gold and luting cements. A successful restoration will depend on the combinations working well. However, the measurement of the properties of one component alone will not tell the whole story.

### Mechanical properties

Mechanical properties give an indication of material quality, but the testing method may not mimic the

**Table 9.1** Possible deleterious effects of intraoral function on restorations

Function	Agent	Possible effect on restorations	
Mastication	Acids in diet or plaque	Surface degradation	
	Abrasive food	Discolouration	
		Dissolution	
	Deformation by load	Fatigue and fracture	
	Temperature change	Dimensional change and adhesion failure with tooth	
	Saliva and dissolved or suspended compounds	Discolouration	
Habits			
	Tooth brushing	Abrasive	Surface loss
	Pipe smoking	Pipe stem	Surface loss
	Bruxism	Opposing teeth	Fatigue and fracture

forces applied clinically; these vary in nature, magnitude and rate of application. Whilst considerable efforts have been made to develop clinically realistic tests, such as the ‘artificial mouth’, these are inevitably complicated and costly.

Mechanical properties tests also give an indication of possible handling problems, in that specimen preparation is often as crucial as the method of test. If a material causes problems, inconsistent specimens and a large scatter of results will be seen. This point is illustrated by the problems of adhesion testing where clinical inconsistencies are also reflected in a very wide scatter of results in the laboratory.

### Modulus of elasticity (Young’s modulus)

This is a fundamental property that characterises the *rigidity* of a solid in tension or compression, when it is deformed elastically.

Stiff materials, such as ceramics and metals, have high elastic moduli and materials like impression rubbers have low moduli, with polymeric materials such as methyl methacrylates forming an intermediate group. The modulus reflects the amount of *deformation* or *strain* a material will undergo when a certain load or *stress* is applied.

When stress is plotted against strain, a characteristic curve is produced (Fig. 9.1). The slope of the linear portion where stress is proportional to strain is the modulus.

The *proportional limit* shows where the plot ceases to be linear and the *elastic limit* indicates the onset of

plastic deformation, where the removal of the load is followed by incomplete *recovery* to the original dimensions (Fig. 9.2a).

Before the elastic limit, removal of the load would be followed by full recovery. If the recovery took time to occur (Fig. 9.2b), the material would be *viscoelastic* and this is a characteristic of the majority of restorative materials.

Full recovery is an important property of impression rubbers after they have been removed from undercut areas of the mouth, so that these may be reproduced accurately. However, because of their viscoelasticity, recovery is not instantaneous, and they should not be cast for at least an hour to allow recovery to take place first. If, though, the undercuts were severe, the material might be taken beyond its elastic limit and recovery would not be; it would have a *permanent set*.

On the other hand, if *ductility* is required of a metal for swaging, then the permanent deformation beyond the elastic limit, but before the *yield point*, is an essential property.

A complication of viscoelastic behaviour is that the rate at which loading takes place influences the strain, and results for modulus will vary accordingly.

Brittle materials, such as ceramics, do not have an elastic limit, and exhibit rapid *brittle failure* when the stresses exceed the proportional limit. Viscoelastic materials subjected to low loads that are intermittent, may eventually *fatigue*, i.e. show reduced recovery and then deterioration by *ductile failure*.



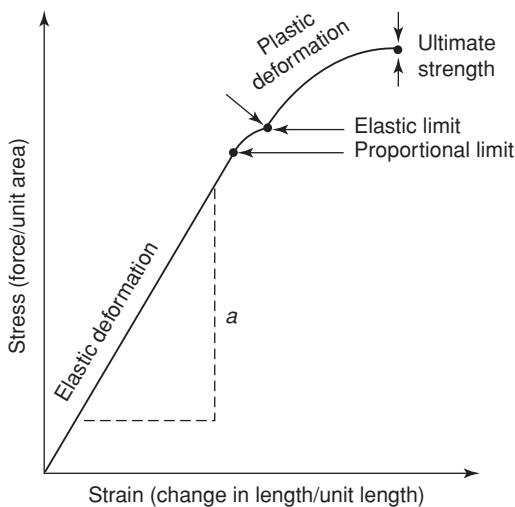
**Table 9.2** Some properties of restorative materials compared with tooth substance (indicative values)

Property	Enamel	Dentine	Amalgam	Composite	Glass ionomer cements	Cement base	Gold type III
Modulus of elasticity (GPa)	85	15	55	Hybrid 20 Microfine 6	Acid base 4 RMGIC 8	Polycarboxylate 5 Zinc oxide Eugenol 2	100
Compressive strength (MPa)	380	300	350–510	250–400	Acid base 250 RMGIC 300	Polycarboxylate 70 Zinc oxide Eugenol 26	N/A
Tensile strength diametral (MPa)	10	105	48–60	50–90	Acid base 40 RMGIC 80 ( <i>Uniaxial</i> )	Polycarboxylate 12 Zinc oxide eugenol 3	450 ( <i>Uniaxial</i> )
Vickers hardness (kg/mm <sup>2</sup> )	300	60	100	60	40	40	400
Thermal coefficient of expansion × 10 <sup>-6</sup> /°C (across crown)	11.4	8.3	25	25–60	Acid base 10 RMGIC 15	35	400

**Table 9.3** Physical properties of restorative materials

Mechanical properties	
■	Modulus of elasticity
■	Creep
■	Compressive strength
■	Tensile strength
■	Flexural strength
■	Fracture toughness
■	Abrasion resistance
Physical constants	
■	Coefficient of thermal expansion
■	Thermal conductivity and diffusivity
■	Dimensional changes on setting
Degradation	
■	Sorption and solubility
■	Corrosion
■	Colour stability
Handling characteristics	
■	Mixing time
■	Working time
■	Setting time
■	Surface finishing

As a concept it is important to decide which type of failure mode will occur in a given circumstance, and it is then possible to design a material for the application. However, as both types of failure may



**Fig. 9.1** Stress/strain curve. The ratio of  $a/b$  is the modulus of elasticity.

be seen intraorally, depending on the material in use, design decisions are difficult, if not impossible!

Progressive time-dependent permanent deformation under load is termed *creep*, which is a particular failing of dental amalgam. The loading by the occlusion causes the restoration to deform, and the margins, being thin, are the first areas to fatigue during the repeated loading. Corrosion of the metal hastens the fatigue cracking. The more successful amalgams have low creep values and lower corrosion rates. Interestingly though, the very lowest creep values do not seem advantageous, possibly because this is accompanied by brittle behaviour, with the material being too rigid to absorb stress.

Creep is measured by applying a *static* load for a given time and measuring the change in length of the specimen. However, intermittent loading is more realistic and *dynamic creep* is the measure of this.

### Compressive strength

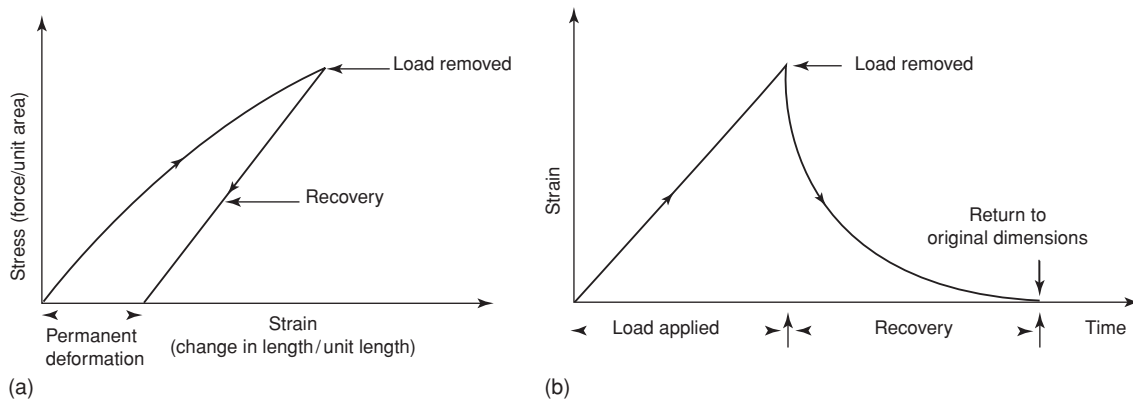
This is determined by applying a steadily increasing compressive stress to a cylindrical specimen until the specimen fractures (Fig. 9.3). It might represent the loading of a restoration by the occlusion, but takes no account of the support provided by the cavity walls or absorption of stress by the periodontal ligament. Further, the incidence of compressive loading depends upon the site of the restoration, with Class III and V types receiving none.

The test gives some indication of the quality of a material but is not a definitive guide, since there is little point in having values above that of enamel, and this could be deleterious to opposing teeth. It is also not a very discriminatory test in terms of differentiating between materials of similar generic type.

The rate of loading of the specimen can significantly affect the results; strain rates during test of 1 mm/min are common, but apparently higher strengths can be recorded if higher rates are used. Attempts have been made to relate strain rates to those encountered during chewing, and 190 mm/min has been suggested.

Misleading results can also be obtained in composite materials whose filler particles will be compacted during testing, increasing the forces recorded prior to fracture.

The rapid attainment of an adequate compressive strength is an essential requirement for a cavity base that must resist the subsequent forces of restoration insertion. Compressive strengths of lining cements measured at 24 hours, rather than the realistic 10 minutes, therefore have little clinical relevance.



**Fig. 9.2** (a) Stress/strain curve showing loading of a specimen past its elastic limit, resulting in a permanent deformation after the load has been removed; (b) strain plotted against time for a viscoelastic material. After the load has been removed, some time is necessary for full recovery to take place.

There is some correlation between the early (1 h) compressive strength of amalgam and its clinical success.

### Tensile strength

To determine this property, two opposing pulling forces are applied to the specimen in its long axis (Fig. 9.3). Tension is quite likely to be encountered in the mouth, for instance, across the occlusal isthmus of a Class II restoration under occlusal load.

It is a better test of material quality than compression, but the test specimens are more difficult to make and alignment during testing is critical to ensure the loading is uniaxial. The results are much lower than compressive strengths, partly due to sensitivity to the specimen defects mentioned above as well as the difficulties of test. As with the compressive strength test, the results are strain rate dependent.

To overcome these difficulties, *diametral tensile strength* has become popular. Here, the load is applied to a cylindrical specimen on its side (Fig. 9.3).

The application of a compressive load in one plane is converted to a tensile strain at right angles to it. It is, however, only suitable for brittle materials since it is assumed in the calculation that there is no distortion of the specimen prior to fracture. This is not the case with polymers and many composite materials and quite erroneous results can be obtained that will flatter the material under test.

### Flexural strength

The application of a bending force to a beam (Fig. 9.4) induces both compressive and tensile forces, and therefore the results should indicate a combined

property. The test is useful for polymers and ceramics, and is simple to perform. Again, the results are strain rate dependent and can be affected by specimen defects as with other tests.

More recently *biaxial flexure* tests have become popular. Here the specimen is a disc supported on an annular knife edge and the load is applied to the centre of the disc. This removes the concerns about edge effects as these are outside the area of the specimen under test. In both uniaxial and biaxial flexural strength tests, if the deflection of the specimens exceeds more than 10%, the theory for calculation is invalidated.

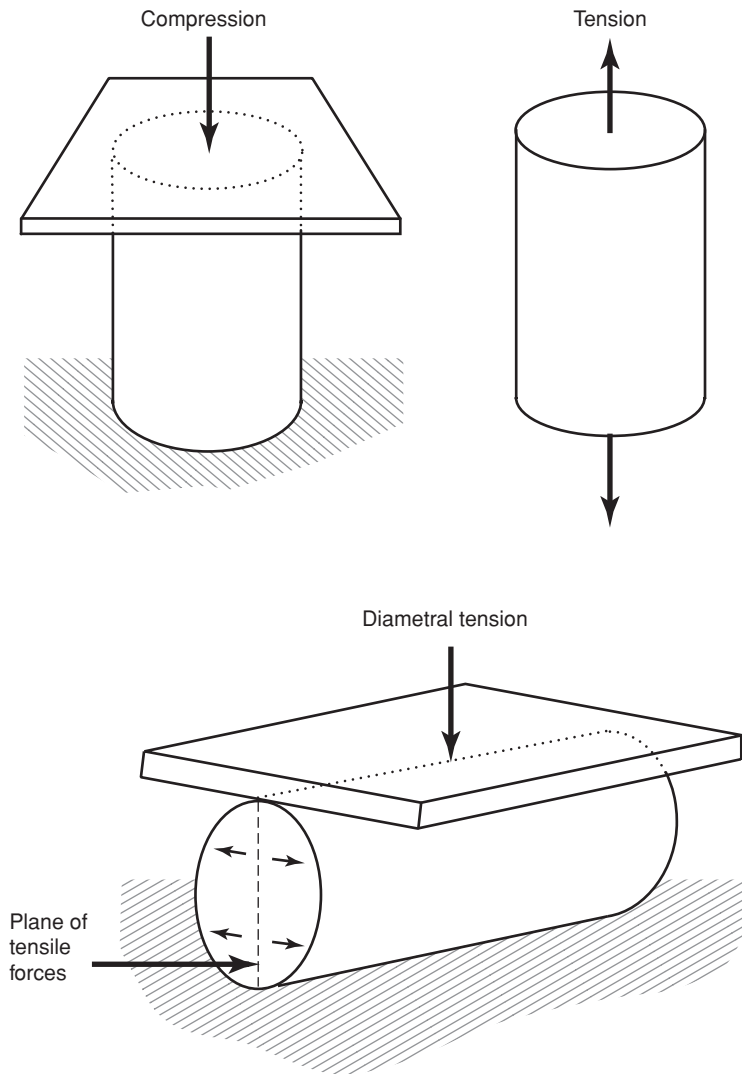
### Fracture toughness

Complex tests under this heading endeavour to measure the energy required to propagate a crack within a material and create new surfaces. This is superficially attractive since crack formation is an integral part of intraoral failure. However, results are often modulus dependent and ranking of materials by using this type of test can be at variance with clinical findings.

### Hardness and abrasion resistance

These properties give some guidance on the possible effects of surface degradation by physical as opposed to chemical agents. However, because of the very complex processes involved intraorally, their results can be very misleading.

Several types of wear tests have been devised that try to mimic oral conditions, but these have been disappointing as they tend to produce a ranking order that only fits one generic group of materials.



**Fig. 9.3** Schematic diagrams of the test configurations for the determination of compressive strength, tensile strength and diametral tensile strength.

### Coefficient of thermal expansion

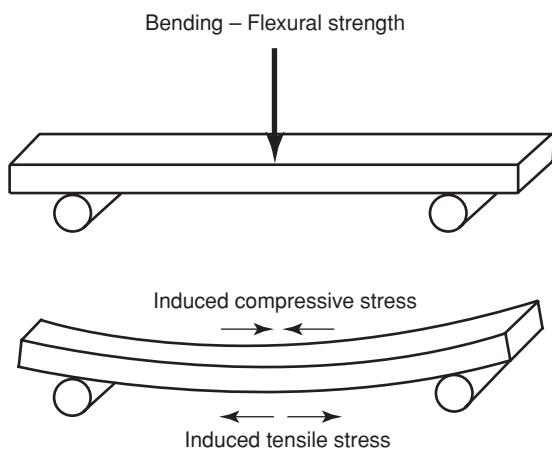
A mismatch of the coefficients of thermal expansion of the restoration and tooth will result in differential expansion and contraction during intraoral temperature changes. This will stress the restoration/material interface and a space will form between the two. This allows the ingress of fluids and bacteria, known as *microleakage* (see later).

These transient temperature changes lie between 5 and 65°C and their effects are made worse by capillary action as the expansion/contraction occurs.

The worst material from this respect is unfilled acrylic, whilst the best are ceramic and glass ionomer cement.

### Thermal conductivity and diffusivity

Thermal conductivity indicates the amount of heat passing through a standard volume of material when the specimen and its surroundings are at a steady temperature. This steady state is rarely reached in the mouth and it is better to consider the thermal



**Fig. 9.4** The fracture of a beam to determine flexural strength by three point loading. During bending, the upper surface is subjected to compression and the lower to tension.

diffusivity of any material which shows the rate of temperature change from one side of a specimen to the other during transient changes in temperature. This type of change is typical of intraoral conditions.

With metals, these properties are of considerable significance since the heat transference is so rapid that the underlying structure will reach oral temperature very rapidly. With polymers, the rate of heat transfer will be considerably slower and composites show a surprising range of diffusivities that may relate to filler loading, size and type. The less well-appreciated phenomenon is that once the temperature of these materials changes, recovery to oral temperature is much slower.

The ideal would be to match the material's diffusivity as closely as possible to that of dentine, as this acts as a very effective heat sink, both because of its bulk and its low diffusivity value.

### Dimensional changes

Ideally, materials should undergo no change after placement in the cavity, but almost all setting materials shrink as new compounds are formed.

Polymerisation of monomers leads to contraction and it may be quoted as volume or linear shrinkage. Whilst this gives some guide as to the amount of space that may form around restorations, its effects are moderated by the strength of mechanical or chemical bonds between the cavity wall and the

material, and its configuration. The development of high-molecular-weight monomers of low shrinkage is very important.

Conversion of monomer to polymer during setting is usually inefficient in dental materials, about 40% for chemical initiation and 60% for light activation, and exposure to temperature changes intraorally induces further reaction leading to a *post-cure* shrinkage.

Water sorption causes expansion of dental polymers including composites, but the effect is reduced by the containment of the material by the cavity and compensation for shrinkage does not occur.

The acid/base setting reactions of cements such as zinc cements and conventional glass ionomer cements are usually dimensionally stable if they are maintained at constant humidity. Loss of water leads not only to shrinkage but to weakening of the cement matrix, hence the need to coat glass ionomer cements with an impervious polymer layer during cement maturation.

The setting reaction of amalgam is complex, with an initial shrinkage caused by solution of the components, followed by expansion caused by crystallisation of new phases. The net result in modern mechanically mixed materials is a small shrinkage.

### Intraoral Degradation

As was mentioned at the beginning of this chapter, the hostility of the mouth towards restorations causes many forms of degradation. All materials are affected in some way or other.

### Sorption and solubility

Ideally, these properties should have values of zero. The sorption of fluid by polymers depends on their degree of cross-linking. Polymethyl methacrylate absorbs about 2% by weight of water and, in the long term, this reduces its physical properties. Other polymer-based materials, such as composites, exhibit less uptake, but the amount still has a significant effect on their properties.

Similarly, there is a loss of material from most polymers with time, as the lower molecular weight compounds slowly dissolve out. The solubility decreases as the molecular weight of the polymer increases and as more efficient conversion occurs during polymerisation.

These properties are usually measured over a period of 7 days for standard tests, but in the mouth the exchange of fluid continues for a considerable time until equilibrium is reached. This is frequently not for many months.

Loss of material, which tends to include plasticisers, inevitably affects the mechanical properties adversely.

Whilst water is the recognised test medium, other solvents found intraorally, such as ethyl alcohol, and acetic and lactic acids, are likely to have deleterious effects. The solubility values for luting cements are important as an indicator of these materials' durability. Polycarboxylate and glass ionomer cements, when fully matured, have the lowest values.

### Corrosion

This affects both metals and glasses, but by different mechanisms.

### Amalgam

There may be some advantage in some corrosion of amalgam since the products are bactericidal and also seal the cavity wall/material interspace. However, the corrosion occurs in the weakest phase of the set amalgam and causes the whole structure to weaken and particularly leads to 'ditching' of the margins.

The main product of the setting reaction of conventional alloys is a cored structure of unchanged alloy powder surrounded by the silver–mercury  $\gamma_1$  and the tin–mercury  $\gamma_2$  phases. The removal or the reduction of the latter phase has been the prime objective, since it is by far the weakest of the phases. The presence of saliva and plaque sets up corrosion cells that results in the slow breakdown of the  $\gamma_2$  phase with the formation of sulphides and chlorides, and also the liberation of mercury that continues to react with the unchanged alloy.

The high copper amalgams show a marked reduction or even elimination of the  $\gamma_2$  phase. The copper has a greater affinity for the tin than the mercury, and copper–tin complexes are formed preferentially. These are themselves not entirely resistant to corrosion but the rate of corrosion is considerably reduced. The end products take some time to form and the elimination of the  $\gamma_2$  phase is very dependent on mercury concentration during mixing.

Corrosion and creep are all increased by the presence of excess mercury and the mixing and handling of the materials must be carefully controlled. Certain high copper materials perform better than

others and there is an overlap in performance with the poorer high coppers and the best conventional materials.

### Glasses

The ceramics employed in both composite materials as reinforcing fillers, and as inlays and crowns are corroded by saliva.

In the composites, water is absorbed by the polymer and comes into contact with the filler. Metallic ions pass from the glass and the accumulation of corrosion products causes stress cracking in the polymer. Long-term immersion studies have shown dramatic decreases in strength of conventional composites. Glasses containing barium strontium or zinc salts to confer radio-opacity are more vulnerable than alumino–silicate combinations.

However, the microfine materials are more resistant to corrosion because the filler particles are surrounded by heat-cured polymer that exhibits a lower water uptake. The clinical durability of the microfines has been greater than would be expected from simple mechanical properties tests and this illustrates another problem in predicting clinical performance. Their performance clinically was very similar to the more highly filled composites but the trend has been to abandon the microfines in favour of hybrid filler configurations.

Ceramic materials used in the construction of crowns and inlays are also liable to a form of corrosion. This is particularly common where glazing materials are applied the surface of cast ceramics. The rate of material loss is slow but leads to an irregular surface that may be quite abrasive. The corrosion of the body of the ceramic is a cause of fracture in the long term.

### Colour stability and staining

This applies principally to the polymer-based materials. Loss of tooth matching colour may be due to setting reaction by-products, degradation of the base polymer or the accumulation of extrinsic stains on a degraded surface.

Amines are used as initiators in both self-cured and light-cured materials and they remain after the reaction as potential discolourants. If the amine concentration is too high, perhaps in order to accelerate setting, then colour instability will result in the long term. Accelerated ageing tests will reveal this.

The principal base monomer of many composites is bis-GMA and this yellows gradually when

exposed to ultraviolet light. UV absorbers are added to counteract this, but they are not wholly satisfactory. The polymer also changes colour due to sorption.

However, the most critical aspect of the composites is their tendency to accumulate stain on the surface. This is partly due to the degradation of the silane coupling agent that bonds the filler to the polymer and partly to the abrasion of surface polymer leaving a rough surface. Porosity, that results from air inclusions during mixing and placement, also collects stain.

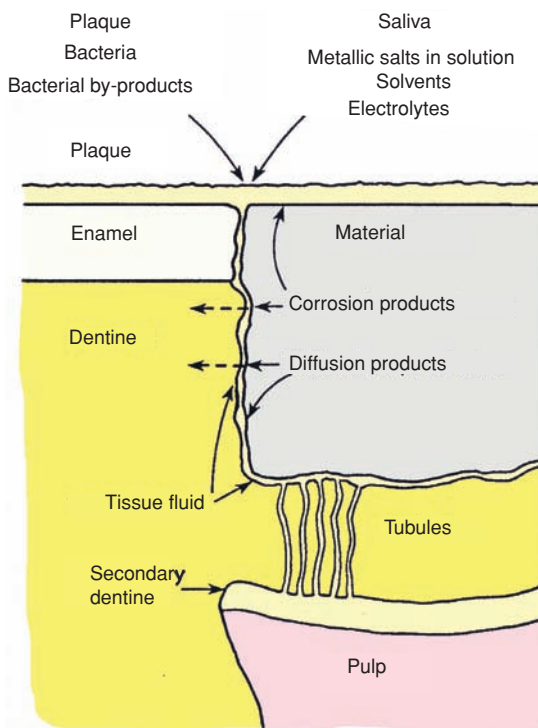
### Microleakage

The interface between restoration and cavity wall is an area of weakness that is under the influence of the properties discussed above. In the absence of an adhesive, mechanical interlocking between tooth and restoration is all that maintains a seal. As shrinkage and subsequent temperature changes occur, the links are broken, and fluid and bacteria pass in. The space becomes an area of transit for all types of compounds that cause staining and pulpal sensitivity. Bacteria are the least welcome as they are able to colonise the dentine surface and are implicated in the pulpal reactions to restorative materials.

Various techniques and materials have been developed to overcome the problem, the first being the cavity varnishes used with amalgam. Even these were soluble and the success of the restoration depended upon corrosion products blocking the space.

The development of dentine adhesives or restoratives that adhere to dentine offers the best hope for the reduction of leakage (see later).

Ion exchange across the interface is of considerable interest. For example, fluoride migrates from the glass ionomer cements and inhibits caries initiation at the restoration margins. The fluoride is incorporated in the glass as a flux to aid manufacture and intraorally it slowly diffuses into the surrounding matrix from which it passes into the tooth tissue (Fig. 9.5). The compomers are the best fluoride releasing polymer-based restoratives available but the rate of release is substantially less than that from conventional and polymer-based glass ionomer cements. Surprisingly, there is little evidence of the appropriate levels of fluoride release needed for restorative materials. Recent work has shown that the higher levels of fluoride release may have some effect on inhibition of bacterial growth on the restoration leading to reduced plaque formation.



**Fig. 9.5** Microleakage. Tissue fluid together with corrosion and/or diffusion products from the material passes out and bacteria, toxins and various salts in solution pass in.

### Handling Characteristics

Materials must be formulated so that they can be manipulated easily. Any material that is difficult to use or is oversensitive to handling techniques is likely to be a failure, no matter how good its final properties.

### Mixing

The most efficient way of ensuring the correct proportions of components and a satisfactory mix is to use encapsulated materials. With amalgam, encapsulation has the added advantage of improving mercury hygiene.

The cements, particularly glass ionomers, are the most sensitive to errors in proportioning and mixing. Care must be taken to follow the manufacturer's instructions exactly.

Mixing also incorporates air into the material that may lead to surface problems. Single component materials, particularly those, such as the light-cured composites, that are vacuum packed as well as being

delivered in single dose ‘compules’, help reduce the problem.

### Working time

Adequate time must be available to mix and form the restoration before the setting reaction increases the viscosity of the material to a level at which it is not workable. The self-cured composites were the most dramatic example of this problem. They tended to be overinitiated to please the clinician with a short setting time. Unfortunately, this severely restricted the working time leading to poor cavity wall adaptation and surface clefts if placement was not rapid. This was one of the driving forces for the development of light-activated materials.

These materials have become known as ‘command setting’ materials. They use external energy, currently light within the wavelengths 410–490 nm, to excite an initiator in the material. However, the working time is not unlimited as the operating light also emits light of a similar wavelength. Unless an appropriate filter is fitted to the operating light, the working time can be quite restricted. This may lead to the placement of material that is already starting to polymerise.

Rapid setting amalgams, mainly spherical particle or microcut types, also have a restricted working time. If this is exceeded, increments may not amalgamate with each other, leading to ‘layering’ within the restoration.

### Setting time

A rapid set seems to be clinically desirable to reduce chairside time. However, this brings with it the loss of working time discussed above, and also in polymeric materials, the chain growth is restricted, leading to inferior physical properties. A long setting time can be equally deleterious, since great patience is required from the clinician. The early glass ionomer cements were very slow setting due to the low reactivity of the glass and early contamination with saliva led to rapid breakdown of the restoration.

### Surface finishing

The final restoration should have very low surface energy so that it does not collect plaque and other intraoral deposits. Often, the ‘as set’ material will require a finishing stage to impart a smooth surface. This must be as simple as possible and ideally done at the placement stage. However, very few materials

have achieved their optimum properties at this time and finishing must be delayed until maturation has occurred.

### Adhesion

Many attempts have been made to achieve chemical attachment of the restoration to both the enamel and dentine. These may be divided into two distinct groups:

- Bonding directly to the substrate by the restorative (polyacid-based cements)
- Bonding to the substrate by the use of an intermediate bonding compound


#### Bonding directly to the substrate by the restorative

The oldest successful adhesive system is that using polyacrylic acid as found in the polycarboxylate and glass ionomer cements. Two reactions appear together. The first is a simple chelation reaction in which the calcium in the enamel and dentine reacts with the polyacrylate ion. The carboxylic acid groups of the cement polyacid displace phosphate and calcium from the hydroxyapatite surface with the formation of an intermediate layer of fluoridated carbonapatite. The second is a limited chemical reaction between the organic phase of the dentine and the polyacrylate ion. This mechanism of attachment has not been clearly defined but it is reported that the bond to *decalcified* dentine is very difficult to break.

The bond appears to be a dynamic phenomenon. The polymeric nature of these cements ensures a multiplicity of bonds between substrate and cement so that under clinical conditions the severance of a single bond does not lead to failure. Although the bond strength of glass ionomer cement to dentine is not high in comparison with other adhesives, the bond appears to be the most durable and reliable of the currently available materials.

The surface must be clean and free of pellicle. Various cleaners, or *conditioners*, have been used, starting with citric acid. This, though, produced mild pulpal irritation and rapidly degraded. More recently the use of tannic acid and, more commonly, polyacrylic acid has become more accepted. It is now thought, however, that the bond strengths to freshly cut dentine are no different from those found with treated dentine.





**Fig. 9.6** A scanning electron micrograph of a smear layer at the cavity margin. It is an incomplete layer with some patches of underlying enamel showing through.

### Bonding to the substrate by the use of an intermediate bonding compound

#### The smear layer

The cutting of both enamel and dentine produces a layer of amorphous material, rich in calcium, that is smeared over the surface of the enamel and dentine, the *smear layer* (Fig. 9.6). While the smear layer on dentine has been well defined that on enamel is still not elucidated clearly. Dentine smear consists of globules approximately 0.05–0.1 mm diameter separated by water-filled channels. It is thought that these globules contain aggregations of fractured inorganic crystallites bound together with denatured collagen. Etching this type of structure will not result in complete dissolution and small fragments of crystallites may remain within the collagen gel. The enamel smear is thought to be larger fractured crystallites bound together by salivary proteins forming a crust to the surface of the cut enamel.

The amount of smear created depends on the type of bur used. The ranking order from most to least is white stone, blank metal, diamond and tungsten carbide burs. The tenacity of the smear layer has never been determined, but it appears to be rather variable. Its presence confers two advantages:

- Sealing of the dentinal tubules
- Provision of a calcium rich layer

The smear layer blocks the cut ends of the dentinal tubules and therefore may be a factor in pulp protection from microleakage.

#### Bonding mechanism

Bonding to both enamel and dentine is now regarded as a hybridisation process infiltrating the tooth tissue

to provide a complex polymer–tooth tissue continuum.

Bonding to enamel is achieved primarily by etching the enamel surface with an acid using phosphoric acid gel and then impregnating the etched surface with a low viscosity monomer forming what is classically known as a ‘tag’ layer that mechanically locks the substrate to the polymer.

More recently the ‘total etch’ of both enamel and dentine has led to the use of systems that contain hydrophilic monomers. These appear to optimise the infiltration of the acid-etched enamel encouraging the hybridisation of the enamel by encapsulating and infiltrating the crystallites exposed by the acid-etching process. This has culminated in the use of self-etching adhesives. These are not regarded as ideal for use on enamel as they are particularly aggressive and may completely dissolve thin sections of enamel.

Bonding to dentine is now regarded as a substitution of monomer for the inorganic constituents of the dentine. The monomer diffuses into the interstices of the dentine after removal of the inorganic phase by etching. Once this monomer substitution has occurred, the polymerisation process leads to micro-mechanical interlocking with the remaining tooth tissue.

There is some evidence of additional bonding between residual calcium and some monomers, but this is not entirely certain. Predicting the outcome of bonding to dentine is a much harder than that to enamel as the dentine substrate contains inorganic and organic moieties and also a large proportion of water. Further the bonding site on the tooth and any pulpal fluid outflow will influence the outcome. The common adhesive systems fall into two groups: etch-and-rinse adhesives and self-etch adhesives. The main difference between these two groups is that when using an etch-and-rinse adhesive, the process involves at least two stages. Initially the dentine is etched and the smear layer removed, either in its entirety or in part, and the residue is rinsed away before the application of the monomer phase.

In the self-etch group both processes are carried out without the removal of the decalcified material, which is incorporated within the hybridised layer.

There was originally some concern as to the effect of the adhesive primers on the underlying dentine structure and the odontoblast processes but this appears to be unfounded, except where the floor of the cavity is close to the pulp.

The process of dentine hybridisation involves the demineralisation of the outer surface of the dentine using a range of acids to partly remove the smear layer and widen the lumen of the dentinal tubules. This also partly demineralises the intertubular dentine leaving the collagen as a fibre web. This is then impregnated by the monomer producing micromechanical entanglement within the fibre scaffolding.

The effect is confined to the outer 10–15  $\mu\text{m}$  of the dentine. Polymer tags pass down the lumen of the fluted dentinal tubules and the intertubular dentine is hybridised to a depth of 1–3  $\mu\text{m}$ . Care must be taken during the priming process since excessive demineralisation of the dentine leads to a collapse of the collagen network and less penetration of the monomer with a resulting reduction in bond strength. Currently, the bond strengths that are obtainable are in excess of 20 MPa (exceeding the bond strengths observed to enamel). However, the results are somewhat variable and depend on the type of dentine used to conduct the test and the method of test itself (see below).

One of the main reasons for bond failure is the force exerted by the polymerisation shrinkage of the composite.

## Methods of adhesion testing

### Bond strength

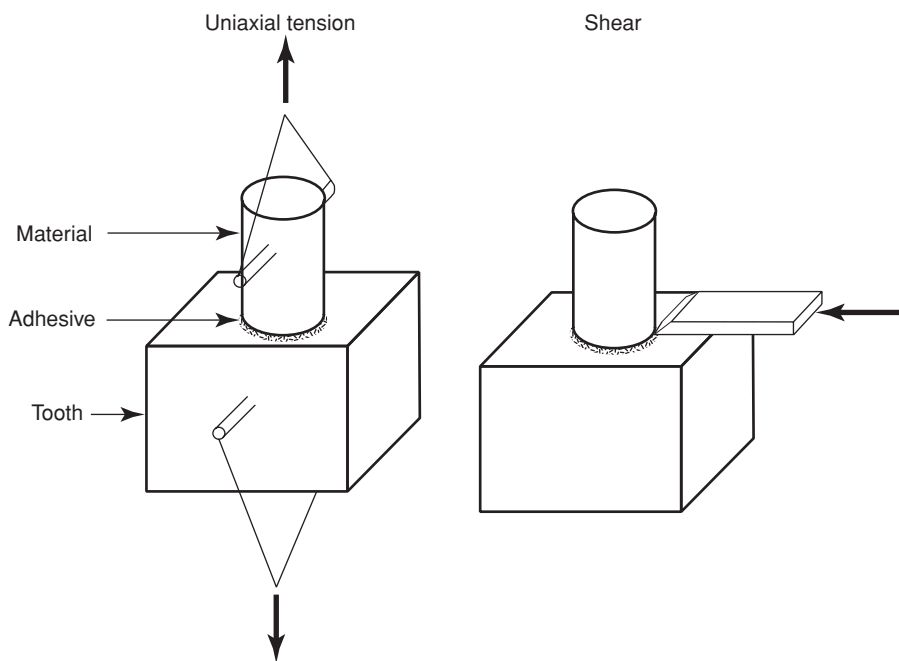
The demonstration of effective bonding and its absolute measurement is desirable to support the efficacy of a particular system. Mechanical bond strength measurement is unfortunately fraught with potential systematic and random errors.

Forces designed to rupture the bond can be applied in several ways. The most common are tensile and shear forces (Fig. 9.7) and many individually designed test apparatus have been proposed to apply these.

Sources of error in testing may be due to the use of an incorrect substrate, surface preparation and standardisation, specimen handling, and peel and shear forces created as a result of the alignment of the specimen during testing.

In view of the shortage of human teeth, several substitutes have been used. These include animal teeth, particularly bovine, and synthetic hydroxyapatite. Both types of substitute are similar chemically to human teeth, but have structural differences. They are useful in screening potential adhesives, but finally there is no substitute for human teeth.

Variations in bond strength will also be found in parallel with compositional differences of the teeth.



**Fig. 9.7** Adhesion testing. The arrangement for the determination of tensile and shear bond strengths.

For example, age or position of dentine in relation to the pulp will vary the mineral content of the specimen surface.

The surface area for bonding must be carefully and accurately defined and the method must not contaminate the surface. For ease of analysis, the surface must be flat and, to avoid mechanical interlocking contributing to the bond, as plane as possible. Handling the specimen after bonding will need extreme care if the bond is not to be stressed prematurely.

A universal joint system is usually incorporated into tensile testing assemblies to align the specimen and substrate with the direction of the applied force. However, during this alignment the bond can be stressed non-axially by peel and shear forces.

### Microleakage

The measurement of the intrusion of an agent, such as a dye, into the space between the material and the tooth also is a common test for the demonstration of adhesion. This should reflect the effects of inclusion in a cavity rather more than the simple flat surface bond strength tests.

Many intrusion agents have been used such as radio-isotopes, bacteria, electrolytes and air. However, the hydrodynamics of the dentine cannot be reproduced, and results may not correlate with clinical observations.

### Biological Compatibility

Biological compatibility is of paramount importance for any material that is placed permanently in living tissues. By virtue of compounds leaching from the material, local or systemic effects are possible.

Dental materials are often placed at a time when they are chemically active, after which they set and become essentially inert. A series of *in vitro* and *in vivo* tests have been devised to screen the biological properties of restorative materials.

The *in vitro* tests begin with a simple screening of cell cytotoxicity, after which the material will be tested in animals. The animal tests are implantation in the tissues and simulated in-use tests in the teeth.

For the in-use tests, the material is placed in standardised cavities and the pulpal response noted at various time intervals after placement. There are a

number of problems with this test in terms of reproducibility and variability but, in the absence of any reliable alternative, it is the best guide to compatibility for restorative materials.

The laboratory tests at the cellular level tend to eliminate materials that are acceptable in other tests. For instance, the cytotoxicity is reduced if fully set material is used instead of freshly mixed material.

The presence or absence of an intervening layer of dentine between material and pulp alters the response of pulp tissue to the material very considerably. Zinc oxide/eugenol cements are the classic example of this, in that if they are applied to exposed pulp, they induce inflammation, whilst they are obtundent to the closed pulp.

In recent years there has been concern about long-term cumulative effects of small amounts of chemicals passing from dental materials. These may have effects locally on soft tissues, for example, bis-GMA has been implicated in the formation of lichenoid lesions of the oral mucosa. There may also be systemic effects following ingestion that are even more difficult to investigate and quantify. Latex allergy is now a serious problem with the use of protective gloves and rubber dam.

The dentist and his staff are at risk from handling materials. There may be allergic reactions in the skin and the effects of inhalation of volatile materials such as methylmethacrylate monomer. Mercury has been recognised as a health hazard to dental personnel for many years but is now considered to be more of an environmental hazard (see Chapter 10).

### Clinical Testing

Following laboratory testing, the materials are subjected to clinical trials. An initial *explanatory trial* using controlled conditions and a small number of clinicians is followed by a *field trial* where the material is used by many operators in general practice conditions.

The time scale for these assessments is inevitably long and the trials are costly. It might be as long as 5 years between invention of a material and its marketing, but there is no avoiding this. Realistic accelerated tests are difficult to devise in primates and are not representative of human intraoral conditions.

## **Conclusion**

The combination of laboratory tests, animal studies and clinical trials ought to provide the clinician with considerable valuable information on the likely behaviour of a material when it is placed in the mouth.

Unfortunately, this is not the case, since there are so many unquantifiable biological factors that influence clinical success. Not least of these is the skill of the clinician in handling materials. Proper attention to detail and the understanding of the quirks of each material is an essential component of the dentist's education.



# **Section III**

# **Clinical Management and Techniques**



# Chapter 10

## Intracoronar Restorations

The evolution of materials, cutting instruments and techniques, together with a better understanding of the structure of the dental hard and soft tissues and of the carious disease process, has resulted in modifications to the principles of cavity design propounded by G. V. Black over a hundred years ago. The advent of adhesive materials coupled with the more precise diagnosis of caries by radiography has led to different concepts. The need for retention created by the cavity shape has been reduced and the lesion is treated at a much earlier stage. These factors have led to smaller cavities and greater conservation of sound tooth tissue. The range of materials available for the restoration of an intracoronar cavity is large.

### Indications for Treatment

#### Primary carious lesions

There is considerable evidence to support the remineralisation of the early carious lesion in enamel (Chapter 6). Only when the lesion shows positive evidence of having reached the dentine should operative treatment be commenced. Figure 10.1a shows a radiograph of an early lesion for which the application of topical fluoride coupled with regular radiographic review would be appropriate.

Figure 10.1b, on the other hand, shows clear evidence of caries in dentine, and this lesion should be excised and the tooth restored. The diagnosis of caries must be aided by high-quality radiographs that have been taken and processed by standardised techniques.

#### Failed restorations

Restorations may fail because of recurrent caries, deterioration of restorative materials or fracture of the surrounding tooth. The diagnosis of these was discussed in Chapter 3 as was the difficulty associated with accurate diagnosis of when to replace a restoration or when to accept apparently minor faults.

### Cavity Design and Preparation

The extent of the excision of the caries and the final shape of the cavity depend upon:

- The size of the lesion, or cavity to be re-restored
- Its position with regard to aesthetics
- The need to conserve tooth substance
- The choice of restorative material
- Caries incidence and oral hygiene

These factors are interrelated considerably. The sequence for cavity preparation is:

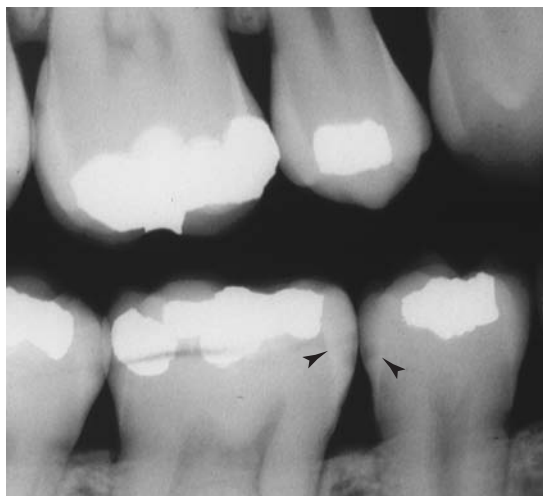- 1 Obtain access and explore the lesion
- 2 Choose the restorative material
- 3 Complete the cavity design and preparation

This is in total contrast with the old traditional teaching of cavity preparation, blamed on Black though perhaps aided by subsequent teachers, where particular ‘standard’ cavity shapes were defined and applied, without thought being given to the lesion, the tooth and its environment.

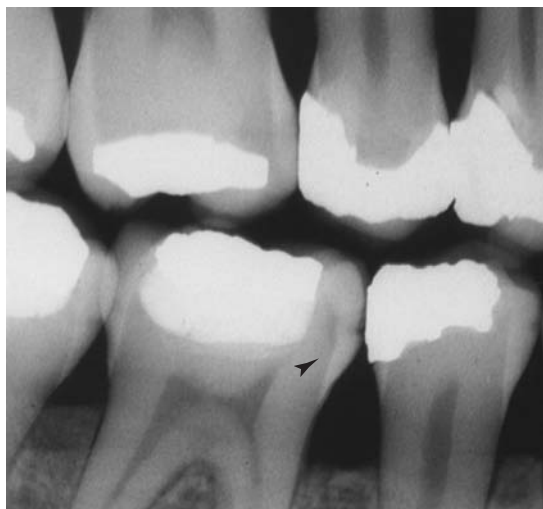
#### The lesion

An initial assessment of the extent of the lesion will be based on clinical and radiographic appearance. However, both methods may underestimate the actual size and exploration is essential prior to making a decision on restoration type. Remember that enamel and dentine cannot be replaced once removed so a cautious approach is necessary. Use small rotary instruments to gain direct access to the lesion, clear the enamel–dentine junction and the dentine floor and then consider the likely restoration type (Fig. 10.2).





(a)



(b)

**Fig. 10.1** (a) Bitewing radiograph showing early enamel caries (arrowed) which should receive topical fluoride application, rather than restoration; (b) Bitewing radiograph showing an approximal carious lesion (arrowed) which extends into dentine. This lesion should be excised and the tooth restored.

### Choice of restorative material

The choice for intracoronal cavities is often a compromise between aesthetics and long-term durability. The principles of the material types and adhesion to tooth were discussed in Chapter 9. The range of materials available for intracoronal restorations is large. It includes:

- Direct composite
- Glass ionomer cement
- Silver amalgam
- Compomer
- Composite inlay
- Ceramic inlay
- Gold inlay

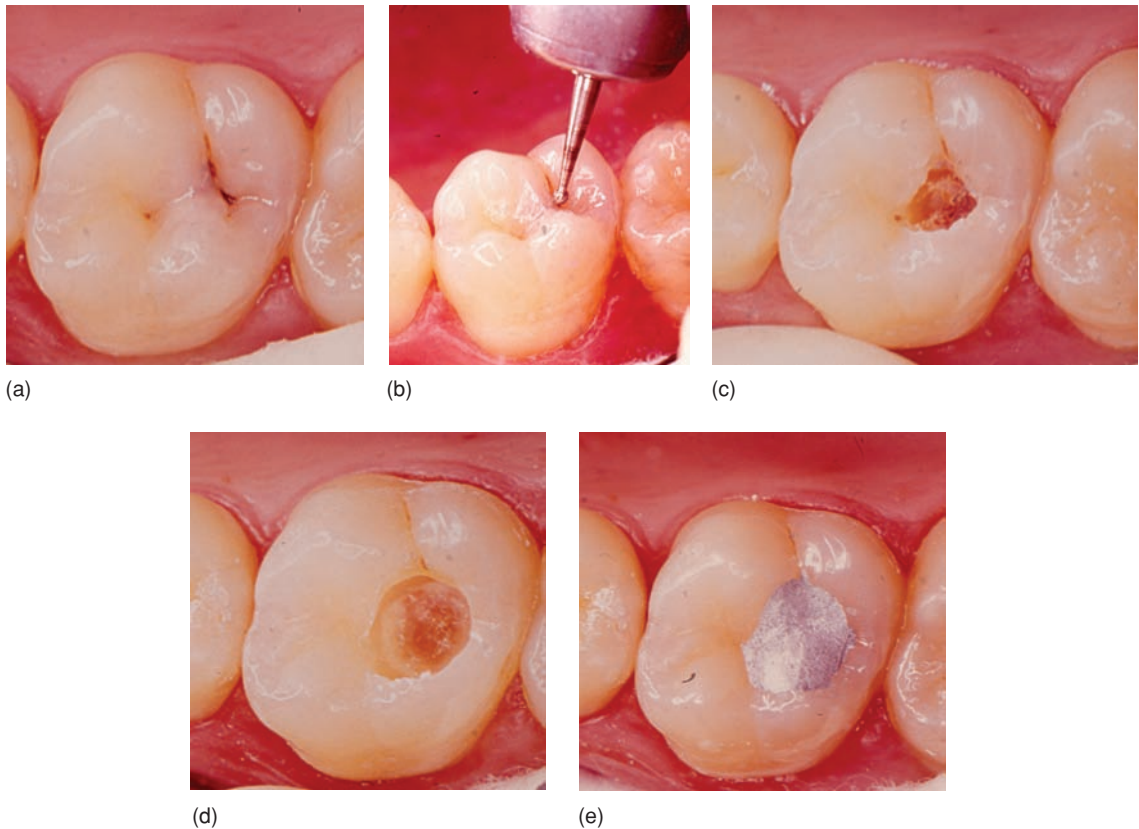
### Composite

Forty years of relatively successful usage has seen this group of materials become well established for anterior use. They are now becoming more established for use in minimal cavities in posterior teeth and there is a worldwide trend to use composite exclusively for all intracoronal restorations. This is partly because of patient demand for good aesthetics and partly because of concerns about the safety of amalgam (see below).

The composites are currently regarded as the principal material for small to moderately sized cavities. In spite of developments, their use in occlusal load bearing restorations ought to be viewed with caution since they are technically much more demanding to use than amalgam and may not maintain occlusal contacts as well. They have acceptable wear characteristics in small cavities but in larger cavities surface loss may be seen within five or so years (Fig. 10.3). Marginal breakdown may be associated with the occlusion and the late effects of polymerisation shrinkage.

Current materials are almost exclusively of the blue light/camphoroquinone initiated type though newer photoinitiators, such as phenylphosphine oxides, have been developed. Two component self-initiating materials are now reserved for practice locations with poor electricity supply. The by-products of the amine-peroxide self-curing system lead to colour instability, and in light-activated materials there is no peroxide, and the amine concentration is reduced. However, even these materials will change colour slightly during the polymerisation process and will still darken with age.

Light-activated materials are dispensed in a single component format and this permits the manufacturer more flexibility in the production of the material, and multi-functional monomers are common. The original bis-GMA polymer has been replaced in many materials by others such as urethane dimethacrylate; these have enhanced physical properties. Further, the single component can be packed at the factory under vacuum, mixing is eliminated and the risk of air inclusions is reduced.



**Fig. 10.2** Clinical exploration of a carious fissure. (a) The occlusopalatal fissure is darkened with shadowing under the enamel; (b) a small round bur is used to obtain access to explore the lesion; (c) the lesion turns out to be large; (d) the periphery is cleared and then the pulpal floor is excavated. Some residual staining is left; (e) the completed amalgam restoration. (A composite might be suitable for this cavity.)

The other principal development has been in filler technology with denser fine particle hybrid materials now being the commonest formulation. The microfine materials have provided good clinical service but the vagaries of the market place have reduced their usage.

The restriction of the light-initiated materials is their *depth of cure*. Only those parts of the material that are reached by the light are initiated and therefore if either the light source is too far away or the unpolymerised layer is too thick, there will be incomplete polymerisation. Restorations that are deeper than 2 mm must be built in separately polymerised layers. This makes the restoration tedious and costly to construct.

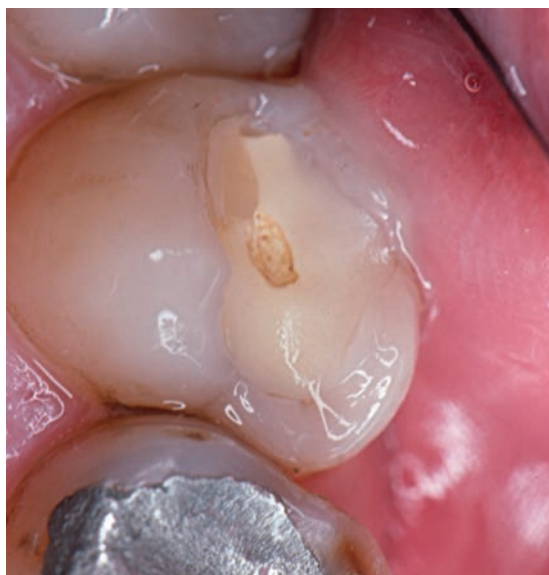### Glass ionomer cement

Glass ionomer cement (GIC) has undergone considerable development in the past 15 years. The original acid–base reaction setting materials are still regarded

as being effective but the incorporation of polymers in the composition has led to several different material types – the *resin-modified glass ionomer cements* (RMGIC). These materials were produced to counter the limitations of the conventional GIC that were slow build-up of mechanical properties and sensitivity to moisture.

All RMGICs have, to a greater or lesser extent, an acid–base setting reaction that is accompanied by a polymerisation reaction. The accompanying water-soluble monomer system, usually *2-hydroxyethylmethacrylate* (HEMA), may be polymerised by:

- Blue light via a photoinitiator, usually camphoroquinone – *light cure*
- A redox amine–peroxide self-initiating system – *dark cure*
- A combination of the two – *dual cure*



**Fig. 10.3** Occlusal wear of a direct composite restoration.

Monomer substitution of the water using HEMA has produced materials that have early mechanical properties that are similar to those of a mature (three to four months old) conventional GIC. The initiation of the polymerisation reaction by light provides a form of command set although the acid–base reaction will continue for some time afterwards. The materials leach fluoride in a similar manner to the GICs but they are less susceptible to changes in moisture content.

The addition of HEMA has led to a setting exotherm that is markedly greater than the composites and there is a substantial polymerisation shrinkage. It has been suggested that this can be compensated for by the high water sorption but saturation of the restoration takes several weeks. The marked polymerisation shrinkage subjects the bond to tooth tissue to substantial stress during the setting stage and the durability of the bond is uncertain. On the evidence currently available, the RMGIC are more appropriate for the restoration of anterior teeth.

Attempts to achieve radio-opacity for conventional GICs have been made with varying degrees of success. The majority have been associated with the modification of the glass to include a radio-opaque element, frequently strontium.

Silver particles may be sintered with the glass during its production to form a *cermet*. Another method is the addition of amalgam alloy particles at the chair-side. Both these methods provide radio-opacity and

also enhance the mechanical properties if added in appropriate proportions.

The cariostatic properties are advantageous. Fluoride ions released from the glass during the setting reaction leach out from the filling matrix to the surrounding tissue. There is also evidence that there is a reverse flow when fluoride ion concentration in the surrounding medium is raised. It is now inferred from this that the GICs may act as reservoirs for various ions. This is of considerable significance since it has been demonstrated in a number of studies that there is caries inhibition around these restorations.

Conventional GICs may in the long-term suffer from erosion in areas where plaque accumulation occurs. This phenomenon leads to substantial loss of material but the underlying tissue appears to be sound.

### Compomers

This further group of materials has been developed to combine some aspects of GICs with those of composites. The filler is generally a fluoro-alumino silicate glass. These materials, more precisely known as ‘*poly-acid modified composites*’, have a novel monomer that contains both carboxylate groups and methacrylate side groups. The setting reaction, usually blue light initiated, is the same as that of the conventional composites where the methacrylate groups polymerise. However, once the restoration is exposed to the oral environment, water is absorbed and any free carboxylate groups will react with this and the surface of the glass filler. This leads to an acid–base reaction. The carboxylate groups react with the surface of the filler to form a salt matrix, and fluoride is released. The mechanical properties of these materials are similar to the hybrid composites. As with composite materials, they require the use of an intermediate dentine bonding agent to achieve adhesion to the tooth tissue.

### Summary

The bewildering array of materials described above can be regarded as occupying a spectrum ranging from pure acid–base reaction ‘salt matrix’ materials at one end, to purely polymer-based materials, the composites, at the other. In between there are various combinations of the two with a lack of clarity about what the user should expect from a particular formulation.

Clinical choice is to a large extent personal and empirical and in Table 10.1 the basic properties are compared. There is no doubt that the average general dental practitioner is attracted to a rapid setting

**Table 10.1** A comparison of glass ionomer cements, composites and their derivatives as restorative materials

Property	Composites and compomers	Glass ionomer cement (GIC) (acid–base reaction)	Resin-modified glass ionomer cements (RMGIC) (blue light activated/dual cure)
Adhesion	Intermediate agent(s) required	Inherently adhesive	Intermediate agent(s) usually required
Fluoride	Composites – mostly none Compomers – low diffusion	Good diffusion	Good diffusion
Setting reaction	Blue light – rapid Surgery light initiates cure	Slow	Blue light – rapid Self-cure component of dual cure – slow
Setting shrinkage (average)	Significant (1–3%)	Minimal	Significant (3%)
Flexural strength (average)	High (120–150 MPa)	Low (60 MPa)	Moderate (80 MPa)
Finishing	Immediate	Delay until mature	Immediate (with care)
Colour stability	Marginal staining and darkening in time	Surface stain	Surface stain
Abrasion resistance	Good except under occlusal load	Poor	Moderate
Aesthetics	Good	Variable	Good

material that can be finished immediately, is not sensitive to water content and has good aesthetics. These criteria reduce the popularity of the original acid–base reaction GICs in favour of the RMGICs and composites. The implications of this are that dentists seem willing to accept having to use additional bonding agents and the deleterious effects of polymerisation shrinkage.

### Silver amalgam

The material of choice in the posterior teeth where the cavity is moderate to large and involves substantial occlusal contacts remains *amalgam*. It is simple to use and is durable. The major question is over its safety and a review is cited in the Bibliography. To summarise:

- Mercury is a tissue poison and the prime risk is to the dentist and his staff. Improvements in mercury hygiene with capsulated amalgam and the careful control of waste have reduced this risk to a minimum. Good mercury hygiene is the primary means of reducing risks to staff. This includes the proper disposal of the unused material.
- Environmental concerns have led to legislation in some countries seeking to eliminate amalgam from use. Other legislation concerns the disposal

of amalgam waste into the public sewers and amalgam separators may be installed on dental units to prevent this. However, it is possible that normal particle filtration systems found in suction and spittoon units are as effective as some separators.

- The most emotive area is the allegation of health risks to the patient. Reports on this are far from conclusive and to date no clear unequivocal scientific evidence exists to support the elimination of amalgam from dental practice; notwithstanding this, advice has been given that removal or placement of amalgam restorations should be avoided in pregnant women where clinically reasonable.
- As was mentioned in Chapter 9, there are various components of other restorative materials that may have local adverse effects or that are ingested with possible systemic effects. Essentially, there is no material that can be described as risk free.

Clearly, reduction in the use of amalgam is possible. Where restorations will be lost in a short period, as in deciduous teeth, then other materials should be used. However, the current amalgam replacements are all materials that introduce technical difficulties in placement and their long-term performance in larger cavities is not as cost effective and durable as amalgam. Their general popularity is driven by aesthetics.

### Composite inlays

Composite inlays have now fallen out of use. They were initially produced as a means of compensating for the polymerisation shrinkage of direct composite materials. The shrinkage took place in the laboratory and the use of a fine luting resin was considered an effective means of cementation. The disadvantages of the systems are the cost of the additional processing and the inherent weakness of the luting composite. The inlays were vulnerable in occlusal contacts and marginal staining and fracture where the lute was broken down was common. This type of material may be useful for provisional crowns and bridges.

### Ceramic inlays

Ceramic materials are the most durable of the tooth coloured materials and have been in use for many years as very successful crown materials (see Chapter 15). Refinements in formulation and firing technique have now made the construction of accurate inlays possible. They have the advantages of maintaining the occlusion more reliably than polymers and they have far superior colour stability (Fig. 10.4). In particular, the milled or cast materials offer much enhanced fit when compared with the original furnace-fired ceramics.

Their disadvantages are the inherent brittleness of ceramic that may lead to marginal fracture and the problem that besets all indirect restorations, the lack

of durability of the cementing material and interfacial bond failure.

### Gold inlays

Gold inlays are very much out of favour even though when well constructed they are arguably an excellent restoration. They are the restoration of choice for maintaining occlusal stability and have no adverse effects on the opposing enamel surface. However, the skills required, coupled with the weakness of the cement lute, make them inferior in the majority of operator's hands to the average amalgam restoration. This is not to say that the placement of amalgam does not require a high level of skill – it does – but the technique is more forgiving.

### Treatment of the minimal dentine lesion

#### Occlusal caries – the preventive resin restoration

A minimal lesion in an occlusal fissure should be treated by local excision of the carious dentine, through the overlying enamel. The access should be of sufficient size to allow good vision of the affected dentine. The other fissures on the occlusal aspect should be inspected for evidence of caries, rather than just staining, and should not be removed unless carious dentine can be seen under them. Occlusal stops will be unlikely to be removed by such a preparation, and therefore GIC can be used because of its adhesion to dentine, low pulp irritation and fluoride diffusion. Composite may also be used.

The remainder of the fissure pattern should be acid etched prior to the insertion of the GIC, and fissure sealed after insertion. The fissure sealant should be extended over the GIC to protect it from water (Fig. 10.5).

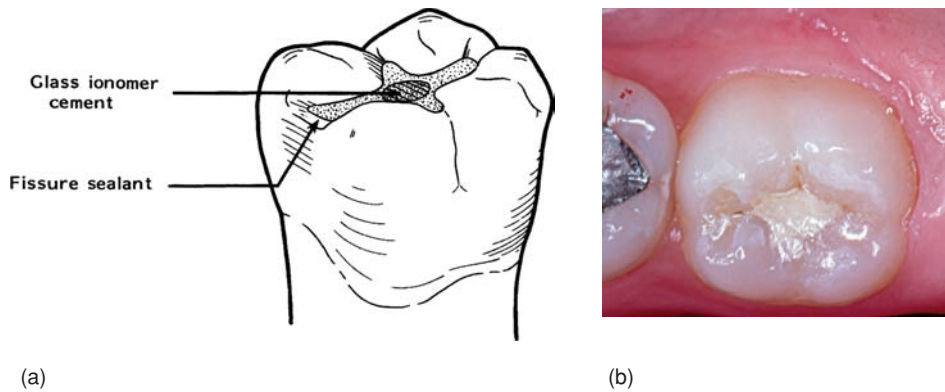
If the fissure is very steep, so that the sealant will not enter it fully, or there is suspicious staining, then fissure widening may be used. A fine tapered diamond is run along the fissure at the depth of the enamel-dentine junction (Fig. 10.6). Any caries revealed by this can be removed locally by a round bur running slowly and the cavity extended and restored appropriately.

#### Approximal caries

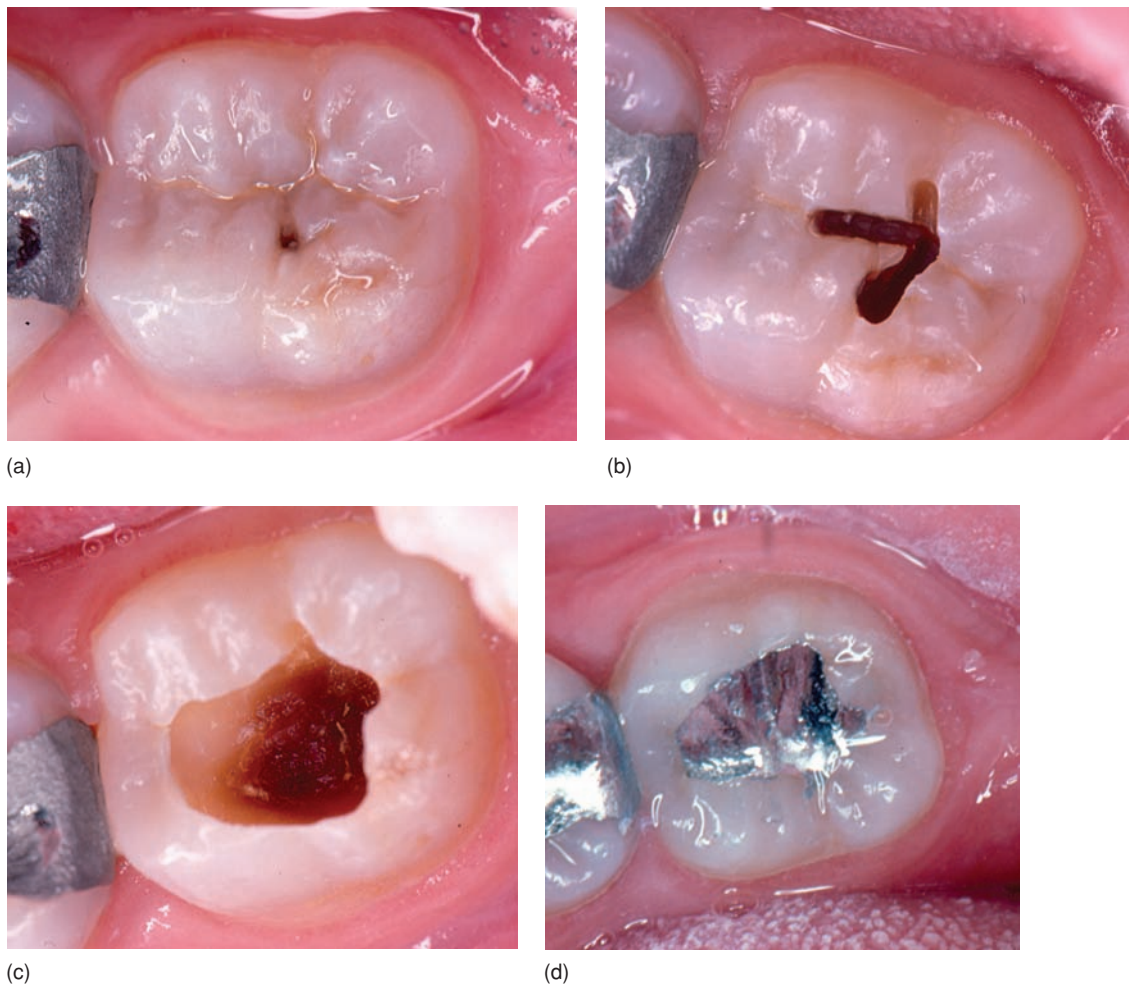
A number of designs to deal with minimal lesions have been suggested. All of these rely on very precise control of fine cutting instruments, and the unique properties of GIC. It is essential to use magnification

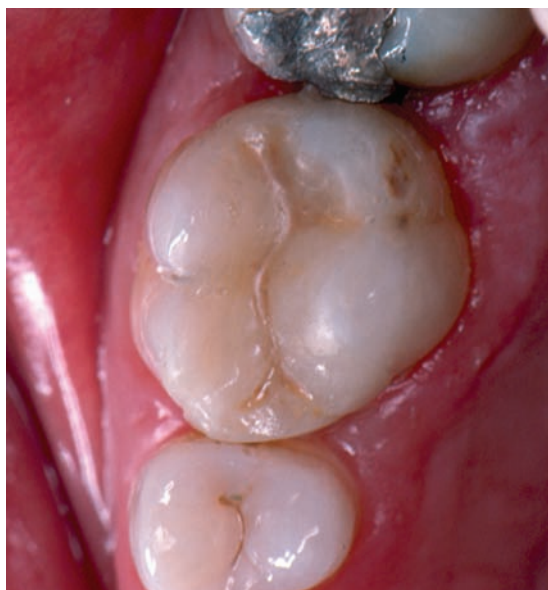

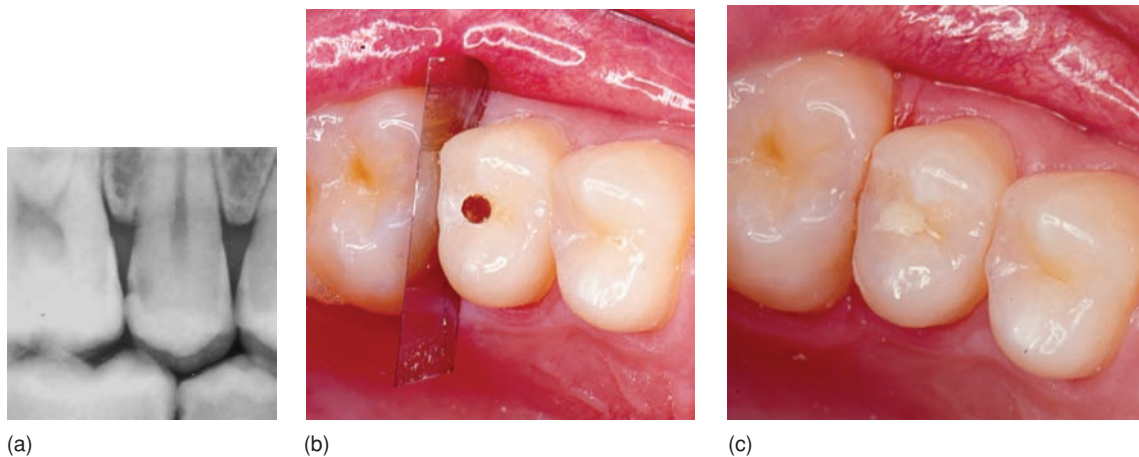
Fig. 10.4 Ceramic inlay. An MOD in an upper molar.



**Fig. 10.5** The preventive resin restoration. The deeper part of the cavity is filled with glass ionomer cement, and this, plus the fissure system, has acid etch resin applied to it.



**Fig. 10.6** Fissure exploration. (a) An apparently innocent pit; (b) careful exploration reveals extensive caries under the enamel; (c) the periphery has been cleared and some altered dentine has been left on the pulpal aspect; (d) the completed amalgam restoration.



**Fig. 10.7** Tunnel preparation. (a) Bitewing radiograph of 51 showing minimal approximal caries in dentine; (b) The approximal lesion is approached via an occlusal access having placed a section of matrix band to protect the adjacent tooth; (c) Glass ionomer cement is placed to restore the 'tunnel'. This must be chemically cured since the marginal ridge will obscure the approximal section from the curing light. The GIC and the fissures are covered with fissure sealant.

for accurate vision whilst cutting this type of preparation.

The commonest of these is the *tunnel preparation* (Fig. 10.7) that maintains the marginal ridge, but care must be taken not to touch the adjacent tooth as the tunnelling emerges approximally. Sight of the approximal lesion is obtained by widening the occlusal access bucco-lingually. GIC is suitable for small lesions; in a larger cavity it can be used for the approximal part, but it may be surfaced with composite occlusally. Modern condensable GICs may be an alternative material for the whole restoration. The principal disadvantage of the tunnel preparation is the limited access it creates to the lesion and therefore the inability to be sure of removing the caries. An alternative design involves removal of the marginal ridge (Fig. 10.8).

### Moderate lesions

#### Conservative Class II cavity

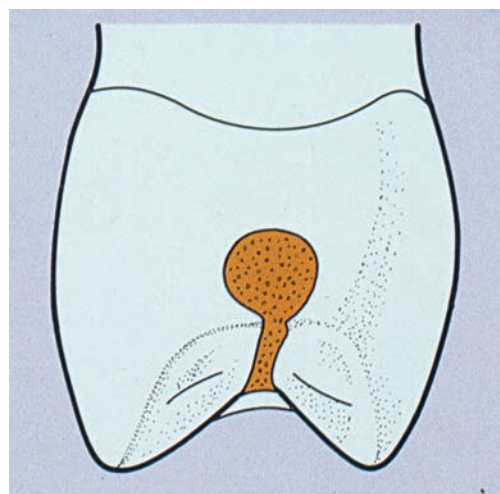
The overriding considerations are:

- Conserve as much tooth substance as possible
- Maintain occlusal contacts on enamel

The preparation is begun by obtaining access to the approximal lesion to inspect its extent and make a provisional decision on the likely restorative material. The occlusal section will be prepared in accordance with any carious attack in the fissures and should

extend just below the enamel–dentine junction so that this may be inspected for caries. Localised areas of caries should be removed either with excavators or with slow running large round burs. It is necessary to avoid cutting enamel centric stops if at all possible since occlusal stability may be lost if the restorative material is not shaped correctly or loses its shape during function.

One of the main problems associated with the approximal preparation is a failure to be aware of the



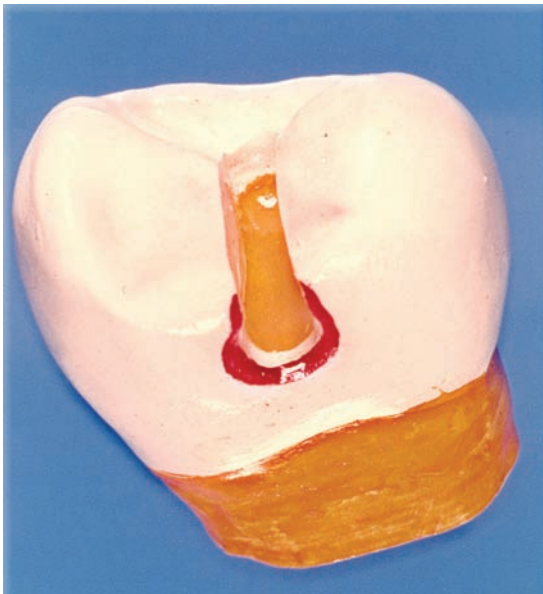
**Fig. 10.8** Diagram of a minimal restoration involving the marginal ridge.

site of the carious lesion in all three planes before starting. The initial penetration of the marginal ridge should be made directly towards the lesion with extreme care. If the lesion is not located properly, there may be a tendency to remove more tissue than is necessary. Slightly rotated teeth are a particular problem.

The margins of the preparation should just clear the contact with the adjacent tooth, buccally, lingually and cervically, meaning that the outline follows the embrasure shape as well as the shape of the lesion.

Thought must also be given to the mechanics of placing the restoration. If the margins are not cleared from contacting the adjacent tooth there may be problems in placing the matrix later (see below). Adequate space must be provided for the entry of instruments to place bonding agents and the final material (Black's 'Convenience Form').

When using composites, microleakage is reduced by the bond to acid etched enamel. To achieve this bond, prisms must be etched in their long axis and bevelled margins are necessary to expose prism ends in certain areas. The approximal preparation margins should be bevelled, but not the occlusal section. Here the enamel is cut transversely by the normal preparation because of its slope towards the fissure (Fig. 10.9).



**Fig. 10.9** Model of a cavity for composite with approximal bevelled margins.

## Instrumentation

Limits on the extent of cavity preparation are imposed by the bur dimensions, the precision and state of the handpiece bearing, and the visual acuity of the operator.

### Burs

Burs used may be divided into those that *abrade* away the surface and those that *cut* the surface. The first category includes the diamond instruments that have a fine grit of diamond embedded in the matrix of the bur. Their method of production limits their effective diameter to not less than 0.8 mm, and the wear on a bur of such a size is very rapid. These abrade away the surface of the dentine producing a surface of uniform roughness.

Tungsten carbide burs have blades with cutting edges that may be serrated to increase the cutting rate. Even these burs tend to grind the tooth rather than truly cut the surface. Here again there is a limit to how narrow these burs can be before the risk of fracture of the metal becomes unacceptable; their diameters must be greater than 0.8 mm. At any thickness, though, they are very prone to fracture if any lateral stress is placed on them. This fracture will be either at the shank or within the structure of the bur itself, depending on the design. This limitation plus the eccentricity of the handpiece means that the minimum possible width of cavity that can be obtained realistically is about 1 mm.

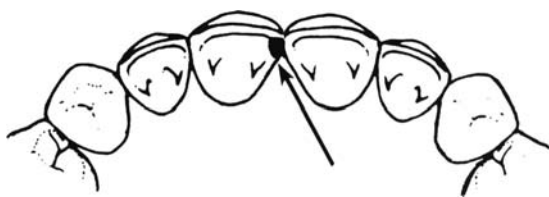
Burs with a sharp terminal profile, such as the inverted cone or flat fissure, introduce stress concentrations in the line angles of a cavity, and round profile burs, such as the dome fissure, are preferred.

## Anterior restorations

Here all that is required is excision of the lesion with the minimum removal of tooth substance. The old kidney-shaped Class V cavity is aesthetically unsatisfactory and quite unnecessary.

*Cervical lesions* may be restored with composite, GIC or RMGIC if they have enamel margins and by GIC if they are sited in dentine alone. GIC has durable bonding to dentine and the important advantages of fluoride exchange and better stain resistance. The compomers, the fluoride releasing acid modified composites, may also be used. There is some evidence of reasonable survival but the initial polymerisation shrinkage appears to put any adhesive bond at risk. RMGICs show even greater polymerisation shrinkage and are therefore less suitable. Where cervical root





**Fig. 10.10** Direction of access to a mesial lesion on an incisor. The marginal ridge is preserved by this line of approach.

caries has appeared in areas of gingival recession, or in sensitive abrasion cavities, GIC is the material of choice.

Because the adhesion of both composite and GIC is variable, it is unwise to rely on it totally for retention, and mechanical undercuts must be provided. However, as was discussed in Chapter 9, marginal leakage is considerably reduced.

For Class III lesions it is desirable to adopt a palatal approach for the approximal lesion wherever possible for aesthetic reasons, and to angle the bur into the lesion under the marginal ridge to maintain enamel in the occlusion (Fig. 10.10). The labial extension should be just through the contact, and whilst this may result in a very thin layer of enamel and dentine or enamel alone, the modern aesthetic materials offer the advantage of supporting this layer through bonding; this produces a better aesthetic result. As with the Class V, though, it is still preferable to include some mechanical retention as well. This would take the form of gingival and incisal pits and grooves, providing these do not weaken the remaining tooth.

The choice of restorative material is between GIC and composite and their hybrid relatives, with the GIC having a positive advantage in individuals with high caries rates. Composites and compomers have an advantage in respect of colour match and translucency.

### Large lesions and amalgam replacement

Here it must be remembered that the amalgam restoration is a solid block of metal that has no adhesion to tooth and that the interface between the material and the tooth allows marginal leakage and on the surface is a plaque trap. In addition, the material is weak in tension and cannot reinforce unsupported enamel.

Therefore, the cavity design for amalgam restorations needs:

- Mechanical retention by undercut walls
- Margins placed in zones that can be cleaned
- Sufficient width for strength of the material
- Removal of enamel that is not supported by dentine

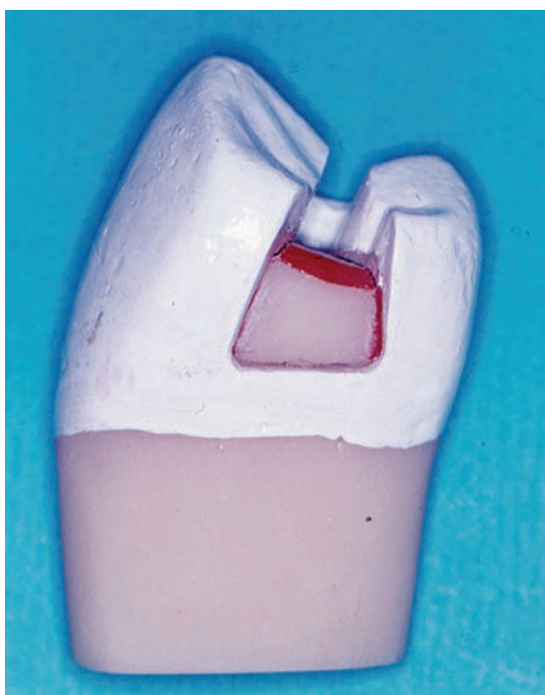### Approximal section

Usually referred to as a 'box', this area is created by removing the lesion (and the failed restoration) and extending the margins to the buccal and lingual embrasures and cervical to the approximal contact area. Unsupported enamel should be removed from these margins. Resistance to displacement in an occlusal direction (*retention* or *stability*) is provided by undercutting the lateral walls of the box in relation to each other (Fig. 10.11).

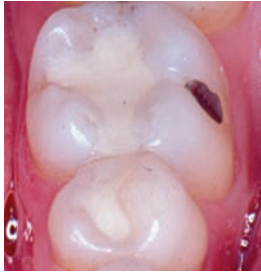In addition, the approximal box requires resistance to prevent displacement towards the adjacent tooth, and this should be provided by the occlusal portion of the cavity.

### Occlusal section

The *occlusal key* or *lock* is cut to one-quarter to one-fifth the inter-cuspal distance; this reduces the risk of weakening the remaining tooth structure to a



**Fig. 10.11** Approximal box for an amalgam cavity.



**Fig. 10.12** Two composite restorations that have replaced amalgam. The outlines are not ideal for minimising the exposure of material to the occlusion.

minimum and may maintain the enamel occlusal stops. It is shaped so that it is wider at its opposite end from the box to create the resistance to approximal displacement of the box. If there are two approximal boxes, as in an MOD cavity, these will be mutually supporting.

The floors of both the occlusal section and the box should be flat to resist loading from the occlusion.

### **Amalgam replacement**

When replacing an amalgam restoration with a different material, the choice is between a composite and an inlay. The difficulty is that the cavity will have been extended to suit amalgam and not composite and that it will be undercut which is not appropriate for an inlay.

Figure 10.12 shows two composite restorations that, on the request of the patient, were replacements for amalgam. There is considerable exposure of the composite to the occlusion which may lead to deterioration of the composite surface.

Ceramic and gold inlays are discussed below.

### **Cavity finishing**

Different opinions exist as to whether cavity walls should be left as they are cut or smoothed with some form of blank or multi-bladed finishing bur. The surface produced by different burs is striking but did not seem to be critical for clinical results until the arrival of adhesives.

The quality of the adhesive bond is dependent to a large extent on the morphology of the substrate to which it is applied; this will vary according to the instruments used. The rougher the surface, the more difficult will be the wetting of this by the adhesive. The result will be air pockets under the restoration that will be a route for microleakage, in spite of the

adhesive. Theoretically the smoother the surface, the more efficient will be the adhesive process.

## **Pulp Protection – Linings**

On completion of the cavity a decision should be made regarding the need for further pulpal protection. In the majority of minimal cavities, the protection afforded by the dentine from both chemical and mechanical irritation is adequate. But once the cavity extends beyond minimal size, additional pulpal protection is required.

Lining materials may be *bases* or *liners*.

### **Bases**

The primary purpose of these materials is to protect the pulpal tissue from mechanical and chemical irritation. Their properties also allow their use as a dentine replacement. They are usually used in thick section to act as thermal insulators. For clinical use, it is important that they reach a substantial strength quickly, otherwise the restoration placement, particularly the condensation of amalgam, will be compromised.

The principal bases are zinc oxide–eugenol materials, polycarboxylate and GIC. Zinc phosphate is now little used.

### **Zinc oxide eugenol cements**

These are derived from the original simple zinc oxide eugenol (ZOE) cement that was used as a sedative dressing. In its crudest form the material was not strong enough to be used as a base or as a long-term temporary dressing. It did, however, have an obtundent effect on pulp symptoms as long as dentine remained over the pulp. On exposed soft tissue, the material is an irritant.

The basic ZOE cements have been modified by the addition of a variety of materials. *Zinc stearate* and *zinc acetate* were first included as a means of increasing the strength and shortening the setting time, and either *polystyrene* or *ethoxybenzoic acid* have been added to reinforce the materials further.

Whilst still the weakest of the bases, mixed correctly it provides good service. However, incorrect proportioning is common, which means that the material is used at powder/liquid ratios well below those which would achieve the optimum properties.

The importance of having a strong base has been demonstrated by work which shows that there is a

displacement of the restoration under load and that the displacement is directly related to the type of cement used as a base.

The other disadvantage of the eugenol-based materials is that they are not compatible with all restorative materials. Polymer-based materials are plasticised by the eugenol and their polymerisation is retarded.

### Polycarboxylate cement

The powder consists of a mixture of zinc oxide and magnesium oxide with vacuum dried polyacrylic acid; this is simply mixed with water.

The resulting material, that has a zinc polyacrylate matrix, is stronger than the ZOE bases but its main advantage is that it possesses adhesive properties to tooth structure. Its disadvantage is that it is difficult to mix and tends to stick to instruments. Some versions have added fluoride salts which will permit a limited short-term release of fluoride ions into the dentine.

### Glass ionomer cements and Resin-modified glass ionomer cements

This family of materials has, in addition to the restorative materials described earlier, derivatives for use as linings. The conventional GICs provide a material with similar compressive strength to polycarboxylate cement and have a tenacious bond to tooth. The RMGICs offer greater mechanical strength initially but at the expense of a considerable polymerisation shrinkage and a marked exotherm during this setting phase. This may well affect the adhesive properties of the cement. Some concern has been expressed about the monomer addition to these materials, HEMA. This has been reported to have adverse effects on skin and allergic reactions have been reported.

### Linings

These materials form a thin layer over the pulpal floor of deep cavities and the commonest form is the calcium hydroxide cements whose therapeutic action is discussed in Chapter 11. The calcium hydroxide is combined with a polymer base that may be self-curing or light activated.

Self-curing liners have poor mechanical properties in comparison with the bases discussed earlier, but they are valuable as chemical insulators in shallow cavities and as sub-linings in deep ones. In deep cavities, it is desirable that they should be covered by a structural base because of their weakness.

The development of light-activated polymer-based liners has changed the materials considerably. Their advantage is the increase in the mechanical properties, but there is a reduction in the pH of the cement from 11 down to 7 and this property influences secondary dentine deposition that is reduced. It is possible that these materials will not be as effective as pulp capping agents. They also set by an exothermic reaction and this can lead to substantial temperature rises.

### Linings – conclusion

The use of bases is reduced in current clinical practice because of the use of dentine bonding agents and the ‘total etch’ techniques referred to in Chapter 9. The ease of use of the calcium hydroxide liners has resulted in these being the most popular lining for most small to moderate restorations. It is now considered that one of the main requirements for any material used beneath the restorative should be to effectively seal the underlying tissue from bacterial ingress.

### Matrices

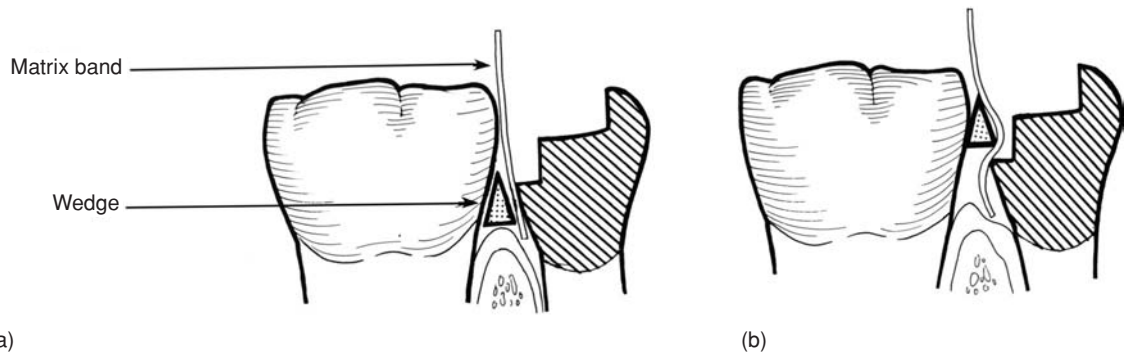
A plethora of matrix retainers and bands is available and it is difficult to single out any one particular type as being the ideal. However, there are a number of desirable features for any system:

- The approximal contour should be reproduced accurately
- The band should be thin enough to provide an adequate contact and yet be rigid enough not to buckle or crease
- The bands must be of sufficient variety to match various tooth shapes
- The retainer should be stable and allow correct tightening of the band at the cervical margin

The problems of the current systems are that only a few produce the concavo–convex outline of the natural tooth and most produce a flat surface with the contact usually at the marginal ridge rather than one-third of the way down the approximal surface.

The Sigveland type is usually the easiest to use but will produce a poorly contoured approximal surface unless it is burnished to shape. It should also be cut after packing, so that it can be removed laterally through the contact. If this is not done, there is a danger that removal will take the marginal ridge with it.

It is essential to wedge all bands, and failure to do this will result in overhangs that are difficult to



**Fig. 10.13** Wedging technique. The subpart (a) shows the correct position for the wedge and (b) shows it too high, buckling the band.

remove in amalgam but almost impossible to detect or remove with composites without damaging the tooth.

The choice and use of wedges is also important. The wedge must hold the band against the cervical margin of the cavity. Frequently, this is not achieved and the wedge rests on the margin interfering with the contour (Fig. 10.13).

Matrices for the anterior region are ill developed, and improper use can ruin the restoration. The most difficult restoration is the Class V, since the acute convexity of the buccal aspect together with the complex shape in the longitudinal plane of the teeth will frequently result in poor contour. The contoured soft metal matrices are the most satisfactory but are unusable with light-activated materials.

Transparent matrices for anterior cavities are well developed but those marketed for approximal cavities were difficult to adapt and metal bands are better.

## Restorative Materials – Handling

### Composites

Clinical usage of light-activated composites is complicated by:

- Restricted depth of cure
- Activation by the operating light
- Occlusal shaping
- Deterioration in the halogen-light-activating units
- Differing wavelengths available from LED light sources

The activating light intensity is reduced if it is obstructed by tooth or is some distance away from the material, as with the floor of the approximal box in a Class II restoration, and therefore the restoration

must be built in individually cured increments that are no more than about 2.0 mm thick. The depth of cure is also reduced with the use of darker or opaque shades.

Halogen curing units produce light over a range of wavelengths between 410 and 510 nm and have varying energy outputs. This can seriously affect the curing potential of the system. It may also be affected by variations in the power supply voltage that reduce the energy emitted at the 470-nm wavelength. A reduction in the voltage shifts the energy distribution towards the higher wavelengths. The bulb should also be changed at least every 6 months to maintain efficiency, and the continuity of fibres in the fibre optic type should also be checked regularly as these are prone to breakage.

Devices are now available for testing the light output and this should be done regularly.

The newer LED light curing units avoid some of the problems of the halogen systems but themselves create difficulties. The emission characteristics mean that while they have a constant energy output from their delivery until failure, the wavelengths emitted are much narrower than those from a halogen bulb. This means that the peak excitation of the photoinitiator must be more closely matched to the wavelength of light emitted. Failure to do this will mean that the composite will not polymerise satisfactorily. With newer initiators being included in some materials it is essential that the user confirms that his LED unit is suitable for the material he has chosen to use.

### Class II restorations

The placement of composite in a Class II cavity requires meticulous completion of each stage in turn, and consequently much time.

The sequence of placement is:

- 1 Pre-wedge to open contact area
- 2 Prepare cavity with rounded line angles and bevelled approximal margins
- 3 Line with eugenol-free base
- 4 Acid etch enamel, apply thin layer of 'enamel bonding agent' and air-disperse
- 5 Place dentine bonding agent – follow manufacturer's instructions
- 6 Place matrix, re-wedge
- 7 Apply and cure 0.5 mm of composite at the cervical margin to avoid shrinkage and marginal failure
- 8 Build and cure remainder in 2-mm increments
- 9 Complete occlusal surface

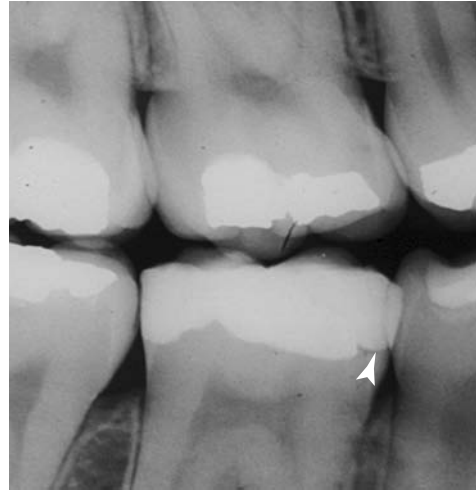
The occlusion is difficult to restore, as free hand carving leaves an oxygen-inhibited surface that should be cut back. This may be avoided by overfilling and cutting back after curing. This is tedious and produces a relatively inaccurate occlusal morphology with the inherent risk of removal of tooth tissue since differentiation between tooth and restorative is frequently difficult. An occlusal index can be prepared pre-operatively to mould the composite, or, rubber dam permitting, the patient can close into centric occlusion with the composite covered with a piece of cling film. This latter technique gives a quick and simple guide to the occlusal stops.

There is a higher incidence of post-operative pain following composite placement. The polymerisation shrinkage causes cuspal flexure and marginal leakage, and halogen light is a potent source of heat. Some materials stick to instruments and are thus pulled away from cavity floors, leading to leakage (Fig. 10.14).

### Glass ionomer cements

All the materials are sensitive to water contamination in the early stages of setting and should be protected from early exposure to saliva after placement by either copal ether varnish or unfilled polymer. However, a certain amount of water is required, and they must not be allowed to dry out, otherwise they will crumble.

Mechanically mixed encapsulated materials provide a much more reliable and consistent material since the method of mixing is the greatest problem with GICs at present. Poor results are usually due to incorrect proportioning and mixing, and the materials are often blamed rather than the operator or nurse's inability to follow the instructions.



**Fig. 10.14** Bitewing radiograph of  $\bar{6}$  restored with posterior composite. There is a failure of adaptation at the mesial cervical margin (arrow).

### Amalgam

The variables that can seriously alter the properties of the material and the durability of the restoration are:

- Proportioning
- Mixing
- Condensation
- Carving
- Polishing

### Proportioning

For hand mixing it was necessary to use an excess of mercury, with mercury/alloy ratios of 8:5 or 7:5, and even after condensation, excess mercury remains, with consequent reduction in physical properties. This problem has been reduced considerably by mechanical mixing and encapsulation which, because it is more efficient, requires a ratio of about 1:1.

### Mixing

The correct ratio must be mixed for the correct time. An under-mixed amalgam will be dry and crumbly. The ideally mixed material should be a cohesive ball that can be pushed to thin film without breaking up, with the over-mixed material being soupy, difficult to remove from the capsule and frequently hot to touch. Over-mixing reduces the working time and increases creep values, whilst under-mixing leads to an unusable mix.

## Condensation

Undercondensation by using inadequate pressure or a large surface area condenser will result in inadequate expression of excess mercury and also lead to microporosity. Here the admixed and spherical particle alloys show some advantage, since they may be condensed with less pressure, and puddling of the alloy produces a satisfactory restoration. In fact, the use of a small condenser is contra-indicated with these alloys as the tip will push through the amalgam and leave sub-surface porosities. Mechanical condensation is also disadvantageous.

## Carving

Correct reproduction of the occlusal contacts, together with removal of the mercury rich excess layer, is essential. In Chapter 8, the difficulty of reproducing exact anatomical cusp/fossa relationships was described. Occlusal stability can be achieved, together with axial loading of the tooth, by carving flat centric stops to receive the opposing supporting cusps, rather than attempting tripods (see Fig. 14.12). If the tripods have one or more contacts missing, the tooth will move to find a stable position. This may create occlusal interferences.

The amalgam restoration should hold shimstock, and if it does then a shiny mark(s) will be seen on its surface; this is not necessarily a 'high spot', and an amalgam with no shiny marks will be out of occlusion. Unfortunately, the majority are taken out of occlusion for this reason and occlusal instability ensues.

## Polishing

Polishing should correct any carving errors, such as excess at the margins or occlusal problems, but must not eliminate the occlusal stops already produced. When using finishing burs or polishing pastes, it is undesirable to produce local hot spots on the surface since this will probably cause changes in the phases of the amalgam. It will also cause excess mercury to come to the surface and this will in turn weaken the material.

## Inlay techniques for gold, composite and ceramic

The basis for all indirect restorative techniques is the cutting of a non-undercut preparation, the reproduction of this through an impression and laboratory model, laboratory construction of the

restoration and finally its fitting and cementation in the mouth.

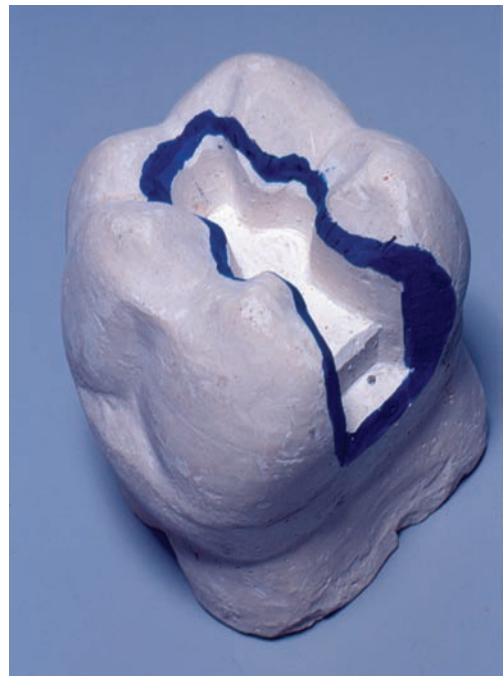Variations around these basic principles are brought about by the physical properties of the inlay material and the cementing medium.

## Gold inlays

Here the technique has been developed over many years to compensate for the lack of adhesion and the solubility of the cement, originally zinc phosphate. Gold inlays have to be mechanically retentive without the cement being present. This is achieved by near-parallelism of cavity walls and by having a single and long path of insertion. A cavity taper of 5–10° is necessary.

The cement is protected from oral fluids by a bevelled margin on the inlay that can be swaged on to the tooth surface, covering the cement lute. The excellent strength of gold alloys allows this thin layer to be manufactured and manipulated (Fig. 10.15).

The cement provides the final stability for the inlay by mechanical interlocks with the cavity wall.



**Fig. 10.15** Model of a cavity for a gold inlay. The cavity must not have any undercut and requires a marginal bevel.

### Ceramic inlays

A bevel cannot be constructed in this type of material because it is brittle and will fracture in thin section. There will therefore be no protection for the cementing medium that is exposed to both oral fluids and the occlusion. Retention of these inlays is heavily dependent on the adhesion of the cementing material.

The cements may be fluid polymer composites of low filler concentration whose physical properties are considerably lower than those of restorative composites. These are literally the weak link. Their degradation leads to marginal staining and lack of support for the inlay margin that is then prone to fracture.

Clinical studies suggest that these problems are seen at about 5-year service.

#### Intracoronary Restorations – Summary

Techniques for small restorations have changed dramatically in the last few years. Advances in the diagnosis of caries, materials and cavity design have eclipsed Black's original concepts. Understanding the pathology of caries, the anatomy of the tooth and the properties of restorative materials is essential for the design of modern cavities. These designs are based on individual circumstances and not learnt by rote.

Tooth tissue should be regarded as a precious resource, only to be removed if essential. Small cavities cause less trauma and do less harm to the natural occlusal relationships.

A large range of restorative materials is available. All have limitations and some have not been in general clinical service for long enough for their longevity to be established.

# Chapter 11

## Management of the Deep Cavity

Management of the deep cavity requires accurate assessment of pulpal condition, the restorability of the tooth and the method of restoration.

This chapter discusses pulp testing, pulp capping, the use of auxiliary retention and the choice of restorative material.

In distinction from the treatment of the small to moderate carious lesion, the deep cavity requires not only a decision on the restorative technique to be used, but also, and most importantly, an assessment of the state of the pulp.

Clinical assessment of pulp conditions can be unreliable, and for this reason it is far preferable to institute regular and risk-assessment-based examinations to avoid, amongst other things, the problems of managing deep caries. This is particularly important in the young patient, where there is less mineralisation of the dentine, and the response to carious attack by the pulp cannot keep pace with the advancing lesion.

In the older patient the rate of spread is slower, and the pulpal response of laying down secondary dentine and increasing the mineral content of the dentine, is able to provide some chance of pulp defence (see Chapter 6).

### Pulp Assessment

The clinician has very poor information to guide him – he has no opportunity to biopsy the diseased tissue! He needs to make the fullest use of:

- Symptoms
- Clinical appearance
- Vitality (pulp sensitivity) tests
- Radiographic appearance

The correlation of symptoms with pulpal pathology is poor. However, the following sequence may act as a guide:

- 1 Transient low grade pain on eating sweet foods – *early lesion in dentine, pulp normal*

- 2 Transient mild pain on hot and cold foods – *deeper lesion in dentine, pulp normal*
- 3 More severe pain lasting after the stimulus has gone – *pulp pathology*

Provided the symptoms are transient, it is fairly certain that the pulp tissue is not involved in the pathology, and the response can be regarded as essentially physiological. It is only if the pain continues after the stimulus is removed that there is a strong possibility that the pulp has started to respond at a cellular level.

The more severe the pain, the less chance there is of pulp recovery after removal of the caries.

Of course, this nicely ordered picture may not be seen, since the chronic nature of the lesion may not give rise to symptoms at all. Alternatively, there may be odd diffuse pain which is poorly localised.

Unfortunately, the absence of pain is no guarantee of pulpal health and the possible maintenance of vitality.

The visual appearance of the lesion – extent of breakdown, colour of tooth and so on – will provide a valuable indication of the likely depth of the lesion. This, coupled with the radiographic appearance and the results of vitality tests (Chapter 2), will put the clinician on the right track on the flow chart (Fig. 11.1).

### Operative Treatment

This is best done under rubber dam to reduce the risk of salivary contamination of any exposure to a minimum.

The objective is to remove all the peripheral caries, thus obtaining good access to the body of the lesion,



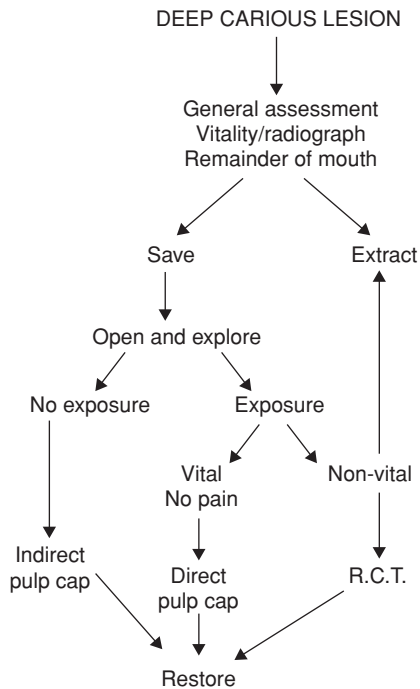


Fig. 11.1 Management of the deep carious lesion.

and then carefully remove the caries that lies directly over the pulp.

### Management of the lesion without exposing the pulp

The ideal is to excise the whole lesion, leaving sound dentine as the base of the cavity. However, when a pulpal exposure might result, it is permissible to leave a zone of altered dentine at the base. It is the identification of the proximity of the pulp and the dentine that may be left, which present the problems.

It is very difficult to be sure of the three-dimensional relationship of the lesion with the pulp, though, with experience, an educated guess is possible.

In all circumstances, soft mushy dentine must be removed. However, where there is slight softening, but the dentine appears structurally intact, it is possible to leave this, if the risk of exposure is high. The means of determining the extent of the penetration of the caries are very limited and the use of the conventional dental probe to detect softening could easily lead to penetration of a very thin layer overlying the pulp.

The dentinal caries is explored carefully with either an excavator or a large slow running round bur. It is important to understand the two zones within the lesion:

- 1 *Zone of destruction* – extensively or total demineralised dentine, containing a large volume of bacteria
- 2 *Zone of bacterial penetration* – areas of partial demineralisation of dentine with invasion by clusters of bacteria

The structure of the first more superficial zone is totally disorganised, whilst the second deeper zone retains the basic ordered structure of dentine. It is the deeper zone that can be remineralised in favourable conditions (Fig. 11.2).

There is no infallible method for determining where Zone 1 ends and Zone 2 begins; clinical experience is necessary to make the judgement.

If the removal of the infected material has been completed, and no exposure has resulted, and if the tooth is restorable, an *indirect pulp cap* is placed.

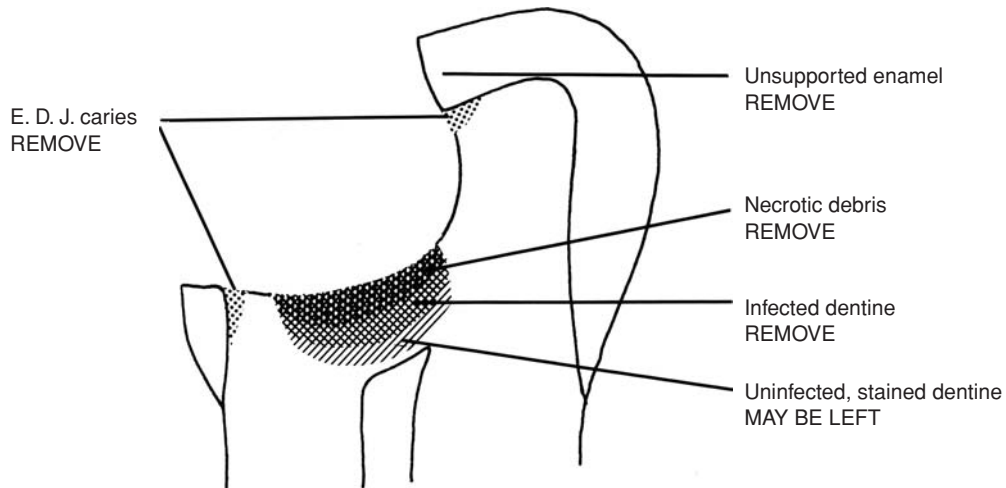
The most reliable material is calcium hydroxide, usually in a polymer base, which has two effects. Its high pH of 9–11 will reduce the activity of any bacteria still remaining as the environment changes from acid to alkaline, and also it provokes remineralisation of the softened dentine and the deposition of secondary dentine beneath the lesion by the pulp. Since this effect appears to relate to pH, there is some concern about the therapeutic efficacy of recently produced materials that have a pH of 7.

However, these new materials do have the advantage of being stronger mechanically and can more readily withstand the occlusal load transmitted via the restoration. The older materials required an extra structural base to absorb this.

Other techniques attempt to kill the residual bacteria in the zone of bacterial penetration and thereby mean less removal of dentine. These include the use of *ozone* or *photo-activated disinfection*. Special equipment and chemicals are required for these techniques whose early results are encouraging.

Yet another suggestion is to seal and entomb the bacteria within the dentine, thereby leaving much of the original lesion intact. Provided the bacteria are deprived of substrate, they will die. However, this presupposes that the restorative materials are capable of maintaining a long-term seal and this cannot be guaranteed.

There has also been the reintroduction of an old technique, now called *stepwise excavation*. Here



**Fig. 11.2** Schematic diagram of the zones of a deep carious lesion.

some of the lesion is removed, the cavity sealed and then in several months time, the cavity is opened and more of the lesion removed. The expectation is that in the intervening period, reparative dentine will be formed and the complete removal of the lesion will not expose the pulp.

### Management of the lesion with a pulp exposure

If the removal of the softened dentine results in an exposure, then the whole lesion should be excised immediately. Contamination of the pulp will have occurred and infected dentine should not remain in the area. It is now necessary to consider *direct pulp capping*.

Again success depends upon the absence of cellular changes in the pulp, as may be indicated by symptoms. A number of physical criteria also determine the success of the procedure:

- **Size of the exposure:** the larger the exposure, the less likely is a successful outcome since contamination of the pulp with infected dentine debris will have occurred. Also, haemorrhage will be increased. Ideally the exposure should be less than 0.5 mm in diameter, and one over 1 mm in diameter has a very poor prognosis.
- **Contamination with saliva:** this will reduce the success rate greatly since there will be bacterial contamination.
- **Marginal leakage:** any leakage can result in bacterial ingress and direct access to the pulp.

Once the exposure has been located, all the dentine debris should be removed. Any haemorrhage must be arrested, preferably without massive blood clot formation. Evidence suggests that the presence of a large clot reduces the success rate.

The exposure is then treated with calcium hydroxide materials that are free from zinc oxide/eugenol. Again the use of a structural base to prevent displacement of the calcium hydroxide liner is necessary.

Success rate is variable for carious exposures, whilst traumatic exposures are considerably better.

It is, of course, very important to see that there is pulp tissue present. Calcium hydroxide applied to an empty pulp chamber has little value.

*Pulpotomy* may be attempted for large exposures. This involves opening the pulp chamber and amputating the coronal pulp, leaving what is hoped to be healthy pulp in the roots. The root canal pulps are covered with calcium hydroxide.

The success of the procedure depends on the infection being limited to the coronal pulp only, and this will be far from certain. However, if the root canals cannot be negotiated by conventional instruments, pulpotomy gives some hope of retaining the tooth.

### Post-operative assessment

The patient should be warned of possible pulp symptoms and told to return immediately if there is pain. Regular review using vitality tests and radiographs is essential to ensure that any changes in pathology of

the apical tissues may be detected. Calcium hydroxide may cause excessive deposition of secondary dentine that may occlude the root canal. Should this occur, intervention and endodontic therapy may be indicated before the canal is obliterated.

## Restoration

In many cases where indirect or direct pulp capping has been necessary, the tooth will have lost a considerable amount of tissue. The plan for restoration should consider, in particular, the retention and stability of the proposed restoration, and the occlusion. Interim temporary dressing should be avoided if possible, since subsequent removal of this and more preparation can insult the pulp further.

Anterior teeth may be restored by acid etch retained composite, but as will be discussed in Chapter 15, this may have some limitations aesthetically and functionally. Once large amounts of what are small teeth are lost, then elective devitalisation, root filling and a post crown are almost inevitable.

In posterior teeth, where all cusps remain intact, or only a single cusp has been lost, restoration with amalgam is the most reliable solution. Here retention will usually be obtained from the remaining tooth substance and free-hand carving will reproduce occlusal stability adequately.

Where more tooth has been lost, then the accurate reproduction of the occlusion will almost certainly require a crown or inlay. In order to provide a proper foundation for the crown, a core will be necessary.

## Choice of core material

Three materials may be used for core construction:

- Amalgam
- Metal reinforced composite
- Glass ionomer cement

### Amalgam

This has several advantages. It can be well condensed around pins and may be contoured to anatomical form easily. It has good long-term durability if crown construction is to be delayed, perhaps whilst oral hygiene is being improved. If there is any dissolution of the cement lute during the life of the crown, corrosion of the amalgam will provide a barrier to leakage. Amalgam offers resistance to the burs used in crown preparation which is therefore more easily controlled.

## Metal reinforced composite

Several materials have been developed specifically as core materials. They are self-curing composites with metal particles, such as titanium, added to improve the resistance to crown preparation cutting. The dark colour of these materials provides good contrast with tooth so that the core/tooth junction can be seen clearly.

However, these materials are more difficult to handle than amalgam and may not adapt completely around pins. Crown failures have been reported due to separation of the core from the pins. Ideally, the material needs to be placed with pressure rather than by condensing as if using amalgam. Some manufacturers have produced core-forming moulds for this purpose. Alternatively a temporary crown form is a good substitute. Care must be taken to remove cervical excess when using either technique, hence the requirement for a contrasting colour to permit easy identification of the excess.

The materials are often used in conjunction with dentine adhesives and thereby avoiding pins. However, it is unwise to rely on current adhesive systems alone to retain large volumes of composite without a good bulk of supporting tooth tissue.

## Glass ionomer cement

Currently, it is essential that GICs are supported by a considerable volume of tooth structure for their successful use as core materials. Cermets and condensable glass ionomers have increased the applications of GIC derivatives for cores but clinical results are few. Whilst the presence of fluoride, adhesive properties and their dimensional stability are advantages, manipulation is more difficult, and amalgam has the proven durability. It would be unwise to rely on the adhesion of GICs to support a crown and not use pins.

## Core placement

Amalgam will always require auxiliary retention, though when it is not to be reduced by subsequent crown preparation, careful use of the remaining tooth tissue to provide undercuts can be successful.

It is important to remember that any additional aid to retention will weaken the tooth and the dangers of excessive use of pins must be recognised.

The principal means of adding retention are:

- Pits and grooves
- Pins

## Pits and grooves

The objective is to place the grooves or pits in opposing walls to resist the displacement of the restoration either vertically or laterally. However, their effectiveness can be limited, and they certainly weaken remaining walls. To be of use, any groove must be opposed by another groove or other retentive feature. The two features will then act in concert.

Unless they are of adequate depth and undercut to allow for the setting contraction of the amalgam or composite, they will serve little purpose. It is also imperative that the core material is adequately condensed into them.

It is important to visualise what tooth substance will be left after preparation of the crown. If the preparation will remove the tooth tissue that was used to retain the core, the process will be wasted.

## Pins

Pins, whilst aiding retention of the restoration, also introduce planes of weakness in the material and stress concentrations in the tooth. A balance must be established between adequate retention and a restoration that fractures under occlusal stress.

Three types of pin are available:

- Self-threading
- Friction grip
- Cemented

### Self-threading

The pin hole is prepared by a twist drill, the diameter of which is slightly smaller than the pin. The pin, usually integral with a bur shank, can then be tapped into place using slow speed. The pin shears off the bur shank as it meets the resistance at the base of the pin hole. These are the most convenient and safest of the types available, but a number of difficulties can occur during placement:

- 1 *Oversized pin hole.* This is either the result of the handpiece chuck running eccentrically due to a worn bearing or by lack of positive control of the handpiece as the hole is cut
- 2 *Dentine failure.* The speed of rotation or weakness of the dentine can lead to the thread that has been tapped, shearing as the pin reaches the bottom of the hole. The pin then comes back with its shank
- 3 *Incomplete seating.* This is a particular problem with the self-shearing varieties and can be caused by running the handpiece too fast, or by variations in the elasticity of the dentine resulting in the pin shearing early

The first two may be corrected by either cutting the next larger hole and trying again with the larger pin, or cementing the pin in place. The latter is difficult, but may be the only solution.

The failure to seat properly may lead to excess pin intruding into the occlusion and also weakness in the support for the pin. If the pin is secure, then it will need bending or cutting. It is better, though, to try to remove it and start again.

Even the successful placement of this type of pin is potentially damaging to the dentine causing crazing and stress concentrations.

### Friction grip

Here again the pin hole is prepared to a slightly smaller size but the pin is pushed home using a holder. This type of pin relies on the elasticity of the dentine to accommodate and retain it, and again there is a risk of stresses and fracture of the dentine under load.

### Cemented

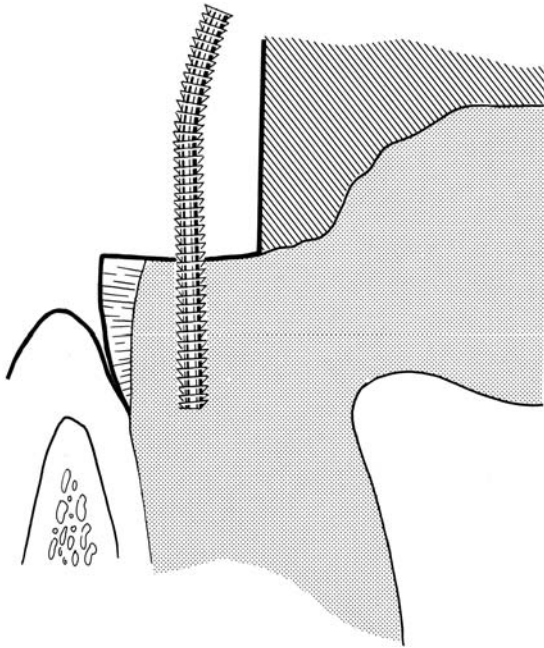
These pins are cemented into place in slightly over-size holes using low viscosity polycarboxylate or cyanoacrylate cements. Increased retention may be obtained by sandblasting the pin to produce a mechanical interlock between the dentine, cement and pin. Introduction of the cement and the pin into the pin hole can be a challenge!

### Pin placement

This is particularly important since the pin must be placed in an area that provides support for the restoration and that does not weaken the tooth. It must also not perforate the pulp or periodontal tissues. There are, therefore, a limited number of sites where pins may be positioned.

Pins should be placed in dentine and to ensure an adequate bulk of dentine surrounding them (Fig. 11.3), they should be about 1 mm inside the enamel–dentine junction. Any closer to the junction, there will be a high risk of fracture of a plate of enamel and dentine away from the side of the tooth. Repair of this, so far below gingival margin level, can be impossible.

The anatomy of the pulp chamber and the interface between the root and the periodontal ligament dictate the angulation of the pin. The pin hole should be parallel to the external root surface and a good guide to this is to place the tip of the bur, or the blade of a flat plastic, in the gingival crevice against the root. The bur may then be placed at the same angle on the dentine.



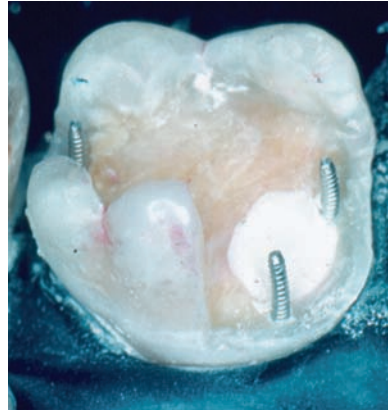
**Fig. 11.3** The position of a pin. It should be surrounded by dentine, 1 mm inside the enamel–dentine junction, 2–3 mm deep and bent to fall within the contour of the restoration.

The commencement of the pin hole may be assisted by the cutting of a small depression with a small round bur. The pin hole itself should be cut to a depth of about 2–3 mm, with some brands having a collar fitted to the burs to limit the depth of the hole. The pin should extend the same length above the surface.

After placement, pins should be bent to fall within the contour of the final restoration and sufficient amalgam must overly the pin so that it does not crack away either during carving or subsequent crown preparation (Fig. 11.4).

Considerable care is necessary during bending since injudicious bending will stress the dentine and cause crazing. A number of devices are available to do this and they work on the principle of gripping the pin just above the point of entry into the dentine. The cemented pins offer the advantage of pre-bending prior to cementation.

Adequate clearance must be obtained between the top of the pin and the surface of the restoration. Failure to do this will result in the exposure of the pin either during carving or subsequently during crown preparation. Reduction of the length of the pin is dangerous, and the most effective way is to use a diamond in an air turbine. Under no circumstances should a



**Fig. 11.4** Three pins in place and correctly contoured.

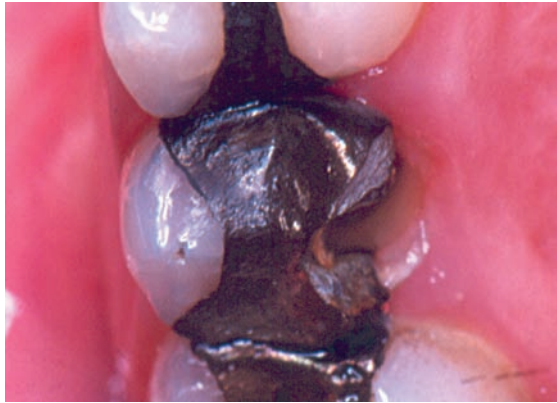tungsten carbide bur be used as it is likely to fracture. Care should be taken with both self-threading and friction grip pins that they do not start to work loose during this procedure and the patient's pharynx must be protected against swallowing or inhaling the pin.

A rough guide to the number of pins that should be placed is one per cusp lost, with a minimum of two. There should be at least one at each end of a core so that when the occlusal reduction for the crown preparation is done, one section of the core does not drop away (Fig. 11.4).

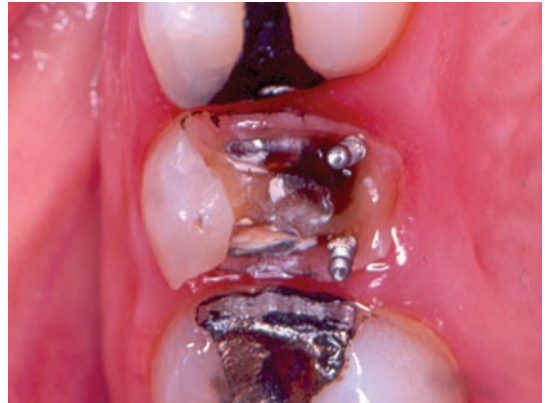It is possible to overstate the risks of pin placement and become averse to placing pins and rely solely on tooth undercuts or adhesives. This is unwise. A crown is an expensive restoration and without a sound, firm foundation, it will not give appropriate service. As an example, Fig. 11.5a shows a premolar that has lost its palatal cusp leaving a large unsecured MOD amalgam. Removal of the amalgam leaves only the buccal cusp; the pulp was vital. In order to provide a crown, a core is necessary and there is clearly insufficient tooth tissue to retain this; two pins were placed (Fig. 11.5b).

### Matrices

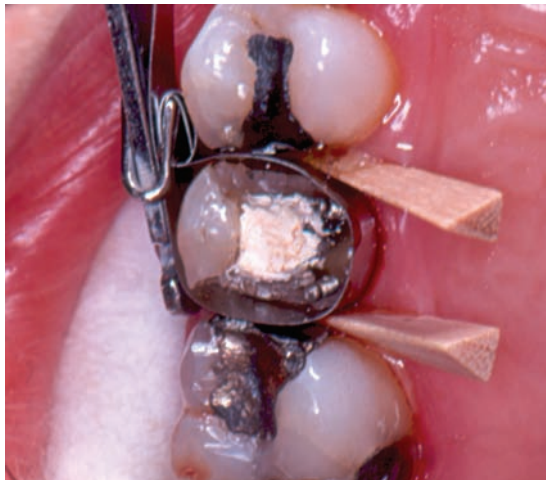Placement of matrices on the badly broken down tooth presents a particularly difficult problem. The Siqveland can be very difficult to use since as the band is tightened, it may ride up the tooth and slip over the cavity margin resulting in a negative margin or a space through which amalgam will be exuded. Careful stabilisation of the retainer by one hand during packing can help.



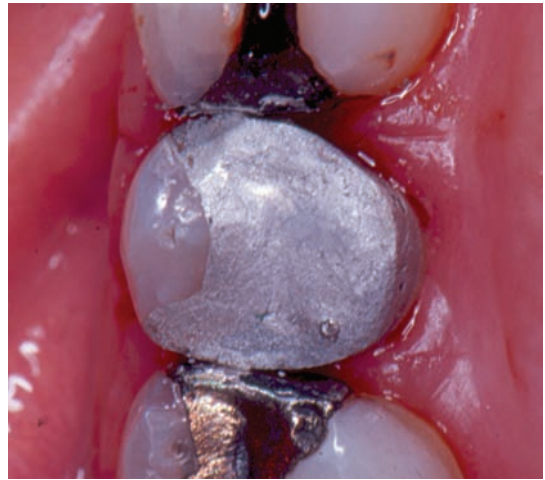
(a)



(b)



(c)



(d)

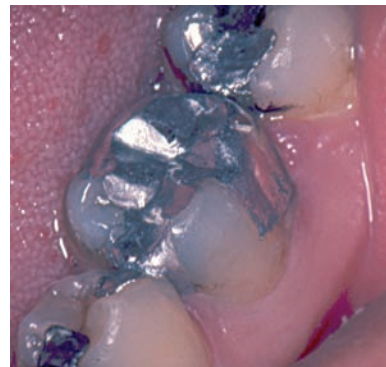**Fig. 11.5** (a) An upper premolar that has lost its palatal cusp; (b) the amalgam removed and two pins placed; (c) the cavity lined and a matrix placed and wedged; (d) the completed core.

The Tofflemire holder with its larger selection of bands may be better and is usually easier to adapt to irregular margins.

Wedging is essential for any matrix so that the band is firmly adapted to the margins of the tooth (Fig. 11.5c). Care is necessary to avoid the wedge riding up over the preparation margin (see Fig. 10.13). Failure to establish a stable, adequately contoured matrix will lead to difficulty in the construction of the core.

### Packing and carving

Several successive mixes of amalgam should be used, rather than one large one, since the later ones will be workable at the end of packing. Carving of a core



**Fig. 11.6** A completed pinned amalgam which would be suitable as a medium-term restoration.

should aim to maintain the contacts with adjacent teeth and stabilise the occlusion. Elaborate anatomical detail is not necessary, provided the crown is to be prepared within a short time (Fig. 11.5d).

However, if the aim is to produce a medium-term restoration, then tooth anatomy should be reproduced to maintain the occlusion and periodontal health (Fig. 11.6).

#### Management of the Deep Cavity – Summary

- 1 Assess the pulpal condition as accurately as possible
- 2 Remove all peripheral caries
- 3 Remove pulpal caries with caution and attempt to prevent an exposure
- 4 Can the tooth be restored? Is a crown necessary?
- 5 Indirect pulp cap/direct pulp cap with calcium hydroxide
- 6 Provide auxiliary retention, often by pins
- 7 Restore with amalgam posteriorly, composite anteriorly
- 8 Review pulpal and apical condition regularly

# Chapter 12

## Root Canal Treatment

The field of endodontics and root canal therapy in particular has seen a large number of changes in techniques, equipment and materials in the last few years.

There are now more methods of preparing and filling a root canal than for any other small restorative procedure – the subject is ‘technique intensive’!

Fortunately, the basic principles underlying all methods remain the same and this chapter considers these to the exclusion of detailed descriptions of all the various twists and turns of new techniques.

The maintenance of pulp vitality should be one of the primary objectives of restorative dentistry. However, as more teeth are retained by a population of increasing average age, so the incidence of pulp pathology increases. Whilst the prevention of the need for root canal treatment is very desirable, knowledge of its techniques is essential for modern day practice.

The *object* of root canal treatment is to maintain a functional tooth with a healthy periodontal ligament in the dentition following pulp pathology and its sequelae (Chapter 6).

### Diagnosis and Treatment Planning

The choices in formulating the treatment plan depend very much on the general factors discussed in Section I, and the local need to keep a particular tooth within the context of the mouth as a whole.

The investigation of the deep cavity and the principles of pulp management were discussed in Chapter 11 and this chapter deals with the extremely local problems of dealing with the restorable, non-vital tooth or a tooth chosen for elective devitalisation.

Diagnostic procedures for root canal treatment follow the same basic guidelines presented in Section I, but particular note should be made of:

- Symptoms
- Problems of pulp testing
- Radiographic appearance
- Restorability of the crown

The first two relate to the achievement of a precise diagnosis of pulp condition, the third to the mechanical problems of preparing a root canal and the fourth to the subsequent and final stage of restoration.

Following the decisions that the pulp is non-vital and the tooth should be conserved if possible, the crucial factors are that the root(s) must be amenable to root filling and that the tooth should be restorable afterwards. The treatment plan should include a provisional decision on the restoration type.

The *technical objectives* of root canal treatment are to:

- Remove all accessible infected and contaminated tissue
- Disinfect infected tissue that cannot be removed
- Shape the canal to an appropriate form to receive the chosen filling material
- Obturate the whole canal to block and seal the dead space to prevent recurrence of infection

To remove all infected tissue, which includes both pulp and dentine, the full length of the root canal must be prepared to the apical constriction.

The root filling material must be chosen before the preparation is started, so that the preparation is shaped accordingly. For example, an apical master cone system will require precise preparation of the apical region of the root, whilst a fluid injectable system might be able to penetrate areas that simply have had infected tissue removed.



## Root canal morphology

As a basis for successful root canal therapy the dentist must have a comprehensive knowledge of the anatomy of the pulp chambers and root canals of all teeth. Variations in anatomy are common and canals cannot be regarded as simple tubes running from crown to apex. Single roots often contain more than one canal and there will be other features such as transverse anastomoses, fins, lateral canals and apical deltas. Accessory canals are important also; these may pass from the pulp chamber into the furcation areas of molars or occur in the main root area.

The most common variations in root canal anatomy are:

- A single canal running to the apical foramen
- A root containing two separate small canals that unite in the apical region and exit through a single foramen
- A root containing two completely separate canals that exit through separate foramina
- A root containing a single canal that divides in two in the apical region and exits through two foramina

The most likely teeth to have more than one canal in a single root in descending order of incidence are:

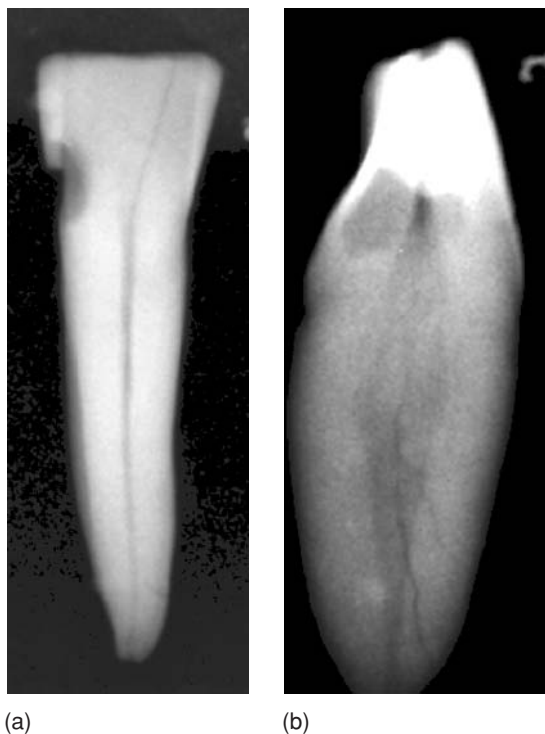- Lower molars: mesial roots
- Single-rooted upper premolars
- Upper first molar: mesio-buccal root
- Lower incisors
- Lower premolars

The canal anatomy for an individual patient though must be assessed by radiography, and the radiographs must be of high quality and free from distortion.

When looking at the radiographs, each root to be treated should:

- Have evidence of a patent, unobstructed root canal reaching the apex
- Be negotiable by root canal instruments, i.e. not excessively curved

The actual canal though is usually nothing like the rather reassuring image seen on a conventional radiograph. Figure 12.1 shows a lower incisor X-rayed in the usual labio-lingual view accompanied by the mesio-distal view, which, of course, is not seen and can only be guessed. Far from being a conical tube, the canal is irregular, probably has two main branches for part of its length, and exhibits sharp curves. In addition, the microscope would reveal connecting



**Fig. 12.1** Radiographs of a lower incisor, showing (a) the conventional labio-lingual view and (b) the 'unseen' shape of the canal when seen from the side.

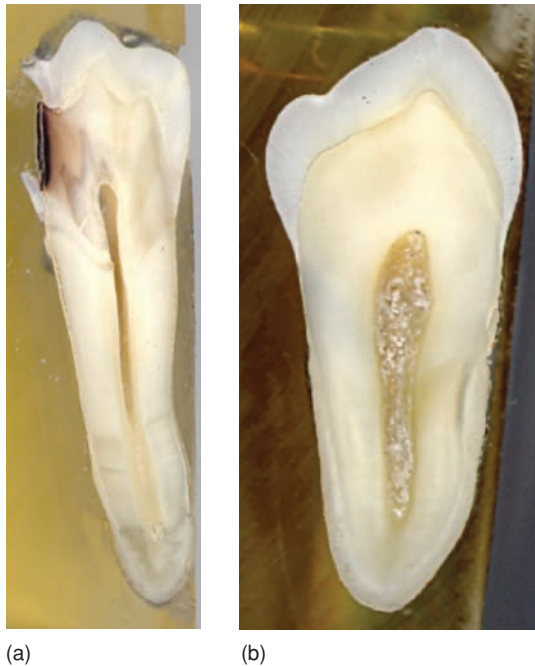
branches of pulp, blind and patent lateral canals, and various fin-like projections.

This type of appearance may also be seen in the sections of two extracted premolars (Fig. 12.2). Figure 12.2a shows the bucco-lingual view with its reassuring tube-like image whilst Fig. 12.2b shows the mesio-distal view with a wide canal shape.

Difficulties in interpretation can be produced by overlying anatomical structures – such as the zygomatic arch in the upper molar region, sclerosis of root canals, hypercementosis and overlap of individual roots. The last problem must be overcome by re-angulating the X-ray tube to throw the roots clear of each other (Fig. 12.3).

In some cases, sclerosis may not be complete but the radiograph may not show a canal. Here it is worth trying to find canals operatively.

Very thin roots may not have sufficient radiodensity to be visible within the denser bone. An instrument in such a root can sometimes appear to be leaving the crown through a perforation. The X-ray tube angle should be changed to concentrate on the problem root.



**Fig. 12.2** Longitudinal sections of lower premolars. (a) the pulp chamber seen from the buccal aspect (the 'radiographic view') and (b) the pulp chamber seen from the mesial aspect (the 'unseen view').

### Apical anatomy

The apical foramen is not usually at the anatomical apex of the root and is likely to be on the side of the end of the root. The foramen may be single or multiple and can lie at the confluence of two (or more) root canals. The mature root shows an apical constriction where the canal narrows dramatically at its apex, caused by dentine and cementum deposition (Fig. 12.4).

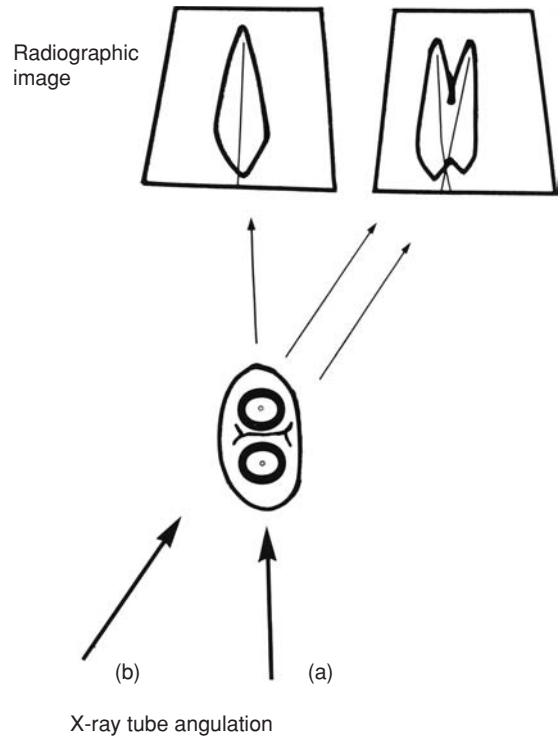
The apical constriction is the upper limit of the ideal canal preparation and is located 0.5–1 mm from the anatomical apex.

The radiographic apex can be distorted by the angulation of the X-ray beam in relation to the film, and precise detail of the apical foramen is not usually clear on radiographs. Occasionally, though, an apical delta can be seen, as can lateral canals.

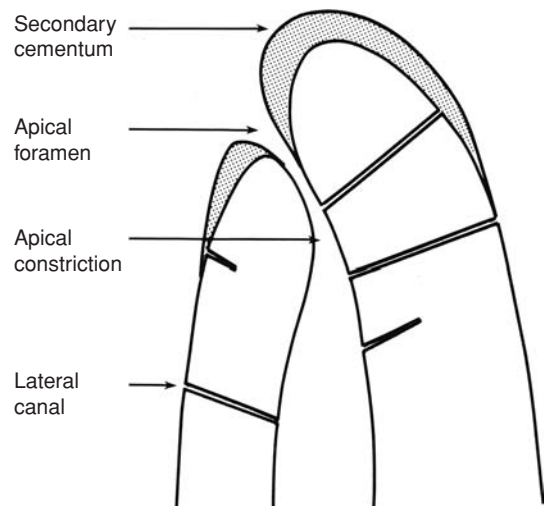
### Pre-Endodontic Preparation

Before root treatment is commenced:

- The tooth must be caries free
- The crown should be provisionally restored



**Fig. 12.3** Angulation of the X-ray tube to separate the images of two roots on a single tooth. (a) Conventional periapical view; (b) the tube is moved mesially to give separate root images.



**Fig. 12.4** Diagram of the anatomy of the root apex. The apical constriction is between 0.5 and 1 mm below the apical foramen.

The latter stage should aim to maintain tooth position, seal the entrance to the canal(s), provide support for the rubber dam and restore aesthetics.

The removal of caries might well have been done at the provisional planning stage to assess restorability, but all stained dentine and unsupported enamel must be removed prior to root canal preparation so that disease progression is stopped.

Posterior teeth will often need pinned amalgam cores or well-retained temporary crowns. Some thought must be given to the final restoration, because when the root treatment is completed, a new core will be required, and the old pins could well be lost. Some 'free' dentine should be left to receive the permanent pins later.

When constructing the pre-endodontic restoration, it is important not to obstruct access to the root canal(s). If, for example, the whole crown was filled with amalgam, it would be exceedingly tedious and dangerous to find the root canals through this. The roof of the pulp chamber should be overlaid with a weak cement that is easy to remove later.

Anteriorly, if enough coronal dentine is present, a composite provisional restoration will be satisfactory. Problems arise if there is little coronal dentine and the root canal must be used to retain the crown. Here a conventional provisional post crown is made that is removed at each preparation and filling stage. Of course, this brings complications for rubber dam placement (see later).

## Canal Preparation

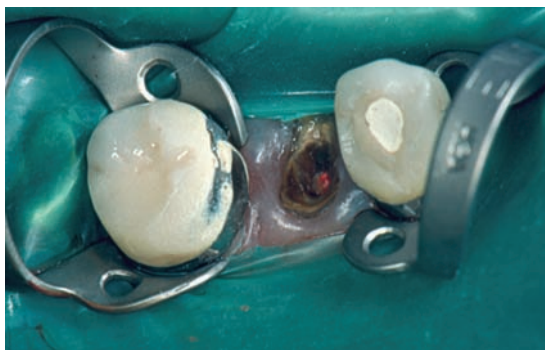### Isolation

Rubber dam is essential to:

- Protect the oro-pharynx
- Minimise contamination of the open root canal
- Retract soft tissues

In some areas, it is possible to avoid the use of clamps which has the advantage that the radiographic appearance is not obscured by metal.

The problem of isolating the crownless root has to be dealt with by using the adjacent teeth for stability, and joining the holes in the dam (Fig. 12.5). A caulking compound may be applied around the margins of the dam to assist sealing. However, care must be exercised if chemical irrigants, other than saline, are used. There would be a risk of fluid passing into the mouth.



**Fig. 12.5** Rubber dam applied to  $\overline{15}$  which has had its temporary post crown removed to allow root canal treatment. A caulking compound may be applied to the cut edges of the dam to improve sealing.

### Vision and magnification

Manipulation of small instruments into root canals requires precise control and this is aided by improving visibility. Magnifying loupes or, now more popular for endodontics, operating microscopes are recommended.

### Access

#### Pulp chamber

Access must be obtained through the coronal tissues to reach the apical constriction. The preparation of the access cavity must remove the 'roof' of the pulp chamber so that the floor of the chamber and the opening(s) of the root canal(s) can be seen clearly. The access cavity must be placed so that it lies in as near a straight line with the apex as possible; this allows efficient instrumentation with little bending of the instruments.

The final breakthrough into the pulp chamber must be done with slow speed, and not the air turbine, to prevent air or water under pressure entering the root canal and passing into the apical tissues. Also, and perhaps more importantly, when obtaining access to molars, the roof of the pulp chamber is often very close to the floor, and rapid cutting may perforate the roof, the floor and the furcation! In some circumstances the use of an excavator to remove the roof is a distinct advantage.

There is a compromise between excellent endodontic access, where removal of the crown to gingival level would expose the root canals very obviously (!), and the restorative requirement where as much tooth substance as possible should be conserved.

The access cavity must be extended to enable removal of all coronal pulp, particularly in anterior teeth where residual necrotic tissue may cause discolouration.

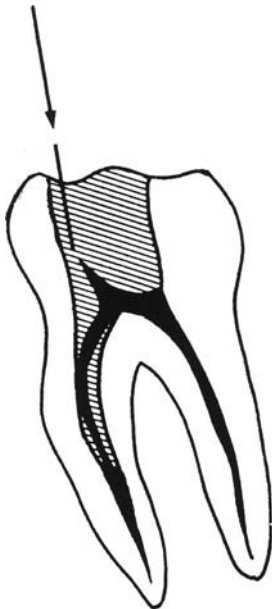
### Root canal orifice enlargement

Access into the root canal system and preparation of the coronal one-third of the root canal is performed at this stage. Fine canal orifices will be located with ISO 08 or 10 files and knowing where to look is essential to avoid excessive removal of dentine.

Orifice enlargement should create a smooth entry route for files later and also begin the straightening of curved canals (Fig. 12.6). Once the orifices have been positively identified and slightly enlarged by filing, Gates–Glidden burs, size 1 or 2 initially, or orifice enlargers, are used to remove dentine rapidly. Care must be taken to remove dentine appropriate to the canal straightening objective and not to enlarge the orifice symmetrically around the original canal into areas of little dentine. The pulp chamber must be irrigated continually during this procedure (see later).

### Pulp extirpation

The timing of pulp extirpation, if necessary, is difficult. It will be facilitated by the orifice enlargement



**Fig. 12.6** The preparation of a curved root requires removal of the shaded areas, so that it is effectively straightened.

but it needs to be done at the peak of local analgesia. Pragmatically, many dentists choose to remove the pulp as soon as pulp chamber access has been done to avoid causing pain.

A barbed broach should be inserted carefully along the canal wall and kept short of the apex to avoid *apical perforation*. To engage the broach in the pulp tissue, it should be twisted and withdrawn in a smooth, gentle action. Sharp movements should be avoided to prevent tearing and incomplete removal. In fine canals, a Hedstroem file of small diameter may be better, since the barbed broach could bind and lodge in the canal.

If the tooth is non-vital, then necrotic tissue should be removed with a file and by irrigation with a 1% sodium hypochlorite solution. The apical portion of the canal must not be prepared in any way before the working distance has been determined.

The problems of obtaining local analgesia for pulp extirpation were discussed in Chapter 3.

### Working distance determination

The position of the apical constriction in relation to a fixed reference point on the crown of the tooth should be determined as accurately as possible ( $\pm 0.5$  mm). This is essential to ensure correct mechanical preparation that, if *short*, will leave:

- Necrotic material and bacteria at the apex
- Untreated pulp space apically

If the working distance is *long*, the preparation will:

- Destroy the apical constriction
- Damage the apical tissues
- Make filling difficult

The working distance may be determined by an electrical conductivity measurement device, an *apex locator*, by radiography or a combination of the two. Apex locators are now more reliable but may give erroneous values. It is recommended that root lengths determined by apex locators be confirmed by radiography.

The sequence for the radiographic technique is:

- 1 Select the largest file that will pass easily into the canal for good radiographic definition
- 2 Measure the pre-operative radiograph and compare the root length with average values and if taken, the apex locator result. Decide on the likely working length and set a stop on the file to this length

- 3 Note a reference point on the crown (if no crown, use an adjacent tooth)
- 4 Insert the file slowly; stop and X-ray if obstructed
- 5 When at provisional working distance, X-ray

*Note:* X-ray film holders for use in conjunction with endodontic instruments can be very cumbersome and difficult to use, particularly with rubber dam obscuring the area. Rigid digital sensors make this problem worse; thinner phosphor sensors should be considered even though these introduce a delay in reading the image. Patients find this stage very uncomfortable.

- 6 Measure the radiographic image of the file – it should be  $\pm 1$  mm of reality to indicate minimal distortion; retake if wrong
- 7 Measure the distance from the tip of the file to the radiographic apex
- 8 If this is greater than 5 mm, increase the insertion of the file, re-X-ray
- 9 From an undistorted radiograph, and when the tip of the file is close to the apex, measure the distance from the tip to the apex and add this to the known file length, in millimetres
- 10 Subtract 1 mm from the measurement – this is the average position of the apical constriction and is the working distance (Fig. 12.7)
- 11 Record the distance in the patient's notes

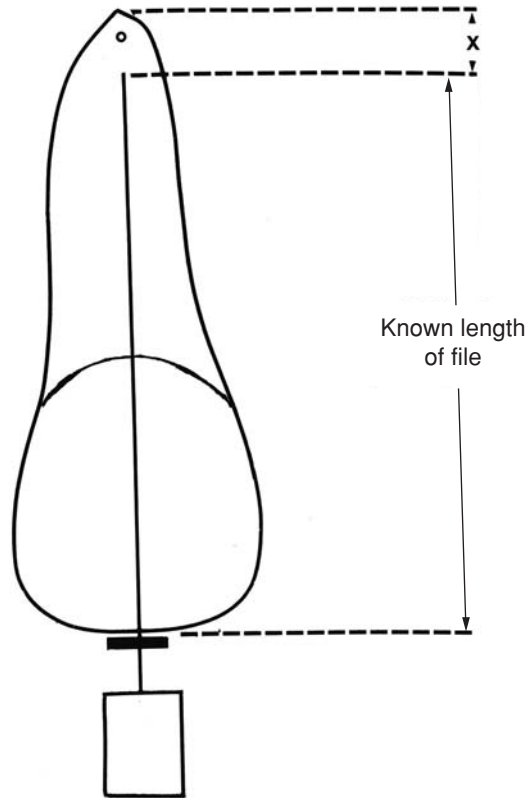
### Canal preparation

The preparation must:

- Remove accessible infected or degraded dentine
- Modify the shape of the pulp space so that it can be filled efficiently
- Disinfect areas of the canal system that are inaccessible to instruments

The properties of the root filling material will influence preparation shape and this principle is the same as that applying to cavity preparation (Chapter 10). Table 12.1 lists the types of root filling materials that are available. The ideal material would be:

- Easy of use within the canal confines
- Controllable during application to avoid over or underfilling
- Condensable into canal wall irregularities
- Biocompatible
- Unaffected by tissue fluid
- Non-resorbable
- Adhesive to dentine
- Dimensionally stable



**Fig. 12.7** The determination of the working distance.  $(X - 1)$  mm is added to the known length of the file, as long as the radiograph is not distorted and  $X$  is small.

- Radio-opaque
- Easy to remove in the event of problems

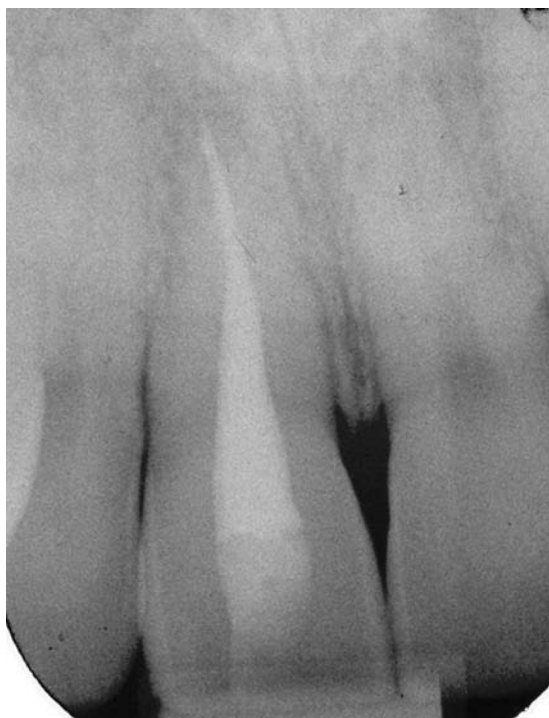Currently the preferred technique is to use *gutta-percha* in the form of a master cone and accessory cones together with a root canal sealer. Whilst tedious to use, the control provided in the positioning of the root filling exactly at the apical constriction and the density of the filling achieved is not provided reliably by any other material.

The optimum shape to receive laterally condensed and sealed gutta-percha is a smooth-walled tube with a continuous taper from the apical constriction to the access cavity. The last 1 mm of the apical region should be of round cross-section to receive the *master cone* (Fig. 12.8).

Perhaps the most important thing to remember during canal preparation is that the canal morphology is extremely variable, some of which cannot be prepared mechanically. Therefore, all that is prepared are the main, accessible areas, and this mechanical

**Table 12.1** Root canal filling materials

Material type	Principal components	Technique	Advantages	Disadvantages
<i>Semi-solid</i>	Gutta-percha	Cones/lateral condensation with sealer	Compressible Controlled insertion	Difficult to use in fine, curved canals
		Thermomechanical compaction. GP melted by friction of compacting instrument; minimal sealer	Good condensation	Excessive heat generated Shrinkage on cooling
		Warm vertical condensation with heated spreaders; no sealer	Good condensation	Time-consuming Soft GP may pass through apex
		Thermoplasticised injection with vertical compaction	Time saving due to extraoral softening	Variation between systems Shrinkage on cooling Soft GP may pass through apex
<i>Solid</i>	Silver Titanium	Single cone with sealer	Ease of use in curved canals due to rigidity	Poor adaptation Canal space blocked with metal – difficult to remove Corrosion of silver
<i>Hybrid</i>	Gutta-percha coated steel	Cone heated to soften GP; then warm vertical condensation	Good condensation	Canal space blocked with metal core – difficult to remove
<i>Pastes</i>	Zinc oxide–eugenol based plus various additives: iodoform, paraform, steroids, antibacterials	Spiral paste filler in conventional handpiece spins material into canal	Simple to use	Difficult to control Extrusion/voids easily done Vital structure damage reported from paraform extrusion Resorbable
<i>Root canal sealers</i>	Zinc oxide/eugenol, Calcium hydroxide/ZOE  Epoxy resin Glass ionomer cement Mineral trioxide aggregate (MTA)	All used with master cones	Biocompatible Biocompatible	Solubility Solubility
			Slow setting Biocompatible	Apical irritation reported Vulnerable to water contamination rapid set
			Biocompatible	Expensive, handling difficult



**Fig. 12.8** Root-filled upper central incisor showing the flared canal preparation.

preparation must be accompanied by an antimicrobial chemical process.

### Instrumentation

There are several instrumentation systems for canal preparation; they all require the use of files, and these may be specially developed for the particular system.

The principal method for many years has been the use of steel hand files but now this is rivalled in popularity by high-torque slow-speed handpiece motor systems used in conjunction with nickel–titanium (NiTi) files. The two systems may be used in parallel. There are also handpieces that operate in reciprocating motion, and systems that use sonic or ultrasonic energy.

The files themselves are also being developed rapidly. Whilst some files are sharp tipped and only cut on the withdrawal stroke, there are newer designs that have safe, blunt tips that can cut when moved in either direction. This latter design of file reduces the canal irregularities, such as zipping and ledges, which may be produced by sharp-ended files.

NiTi files are *super-elastic* having a low modulus of elasticity and therefore greater flexibility. The files will recover from greater strains than steel files and can negotiate sharp curves and return to their original shape afterwards.

In addition, the NiTi files are produced in greater tapers than the original files; these commonly had a 2% taper, but now in order to improve the efficiency of preparation and improve the funnel shape of the preparation, tapers of 4 and 6% are common. Hand files are now produced in orifice enlarger shapes and in greater tapers. Root filling cones are also produced in matching tapers.

### Techniques

The precise manipulation of the file required to achieve the desired canal shape and remove debris has been the subject of considerable research. There are at least eight methods that have been advocated by endodontists in recent years – there will be more!

*Hand filing.* The most efficient way to prepare the apical stop and remove debris is to insert the file towards the apex until it binds, either at the working distance or short of it and make a quarter to half a turn clockwise to engage the cutting blades into the canal wall.

Then, if using single direction cutting files, withdraw the file completely bringing the debris out with the file.

If using two-directional cutting files with blunt tips, maintain the apical position of the file and turn it anticlockwise one turn. Provided the file being used can cut on the upstroke, this action will remove the dentine that had been engaged by the clockwise turn. This is the *balanced force technique*.

The preparation should be done with copious irrigation and with care to clean debris from both the canal and the files. Irrigants are described later.

When the file reaches the working distance and does not bind on turning, change to the next file up and continue with the chosen action.

Do not enlarge the apical stop any more when both:

- The diameter has reached the minimum size for the material (no. 25 for GP) and
- The canal wall consists of sound dentine

The remainder of the canal (that excluding the apical 1 mm) should now be prepared by *circumferential filing* to flare it outwards towards the crown. It is now unnecessary to twist the file to engage the blades, since pressure can be applied via the handle. Also, the canal

profile will be oval and the simple turning and cutting action used for the apical stop will simply cut a round shape in the oval, leaving the periphery unprepared. The majority of radiographically straight canals have some degree of curve in the apical third and the *step back technique* provides a controlled method of negotiating and enlarging this curve.

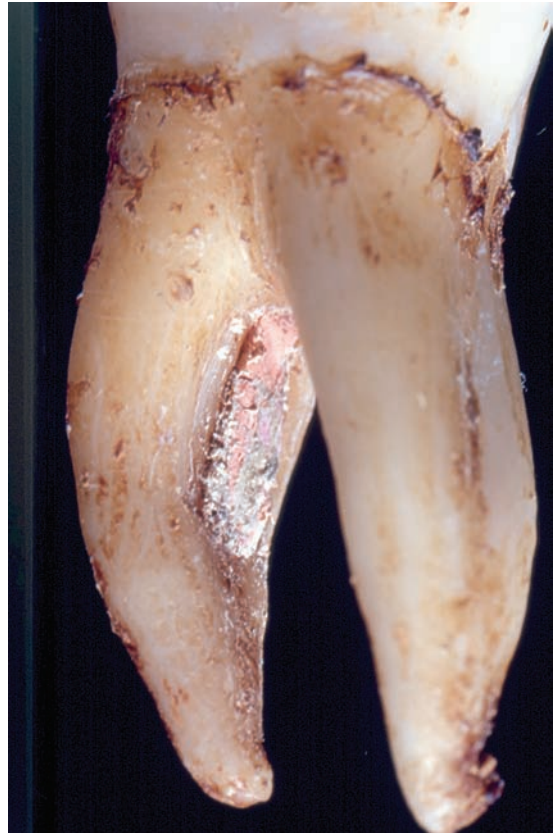
The canal is prepared progressively short of the working distance with progressively larger instruments. Care must be taken not to create ledges or elbows by trying to take stiff instruments around the bend. Steel files larger than no. 35 will not negotiate a curve at the apex, even when pre-curved before insertion in the canal.

The danger of the progressively shortening preparation is the tendency for debris to remain ahead of the files. The working distance must be re-established at each progression by the original apical stop size file – *recapitulation*, with slight turning to engage and displace the debris. The shape will be determined basically by the original canal morphology, and it is necessary to remove an even amount of dentine from its periphery. Preparation should continue until the even tapered shape is achieved and the canal walls offer firm resistance to cutting.

Stiff files, used around a curve, may create a separate channel away from the main canal. A new apical foramen may be created and whilst this is essentially a lateral perforation the term *apical transportation* is used to describe the outcome. As with many of the canal preparation faults, it is very difficult to correct. Pre-curving a fine file and trying to re-establish access to the real apical constriction is the only solution.

Canals that are curved in their middle third should be prepared by filing the inner aspect of the curve, to ‘straighten’ the canal within the curved root – *anti-curvature filing*. The danger here is of filing too much and perforating the inner aspect of the root – a *strip perforation* (Fig. 12.9).

A further technique advocated by some is *patency filing*. This involves passing small instruments through the apical foramen every so often to remove dentine debris, pulp tissue remnants and micro-organisms that tend to become lodged at the end of the canal and create a plug. This debris can obstruct instruments reaching the working length, thus shortening the prepared canal, and may deflect instruments against the canal walls thus creating ledges and zips. However, there is no evidence to support this technique whilst there is some to show that a plug of clean dentine dust in the apical foramen may act as a matrix for cementum to form during apical healing.



**Fig. 12.9** Strip perforation on the inner aspect of the mesial root of a lower molar.

#### *Hand instrumentation – summary.*

- Use safe-ended instruments that cut on the upstroke as well as the downstroke
- Use copious irrigation to lubricate instruments and introduce antibacterial solutions to inaccessible areas
- Clear debris by frequent cleaning of instruments
- Maintain control of the working distance
- Never force an instrument if it binds
- Do not miss out an instrument in a series
- Discard damaged instruments
- Clear blockages as they develop by irrigation together with the use of small, curved file

*High torque motor, NiTi files.* The great advantage of nickel–titanium alloy is its flexibility which has allowed manufacturers to produce instruments with increased tapers that will negotiate curves. This type of instrument will automatically produce the necessary degree of flare when preparing canals and therefore



can be used without the need to stepback. This saves much time and wear on the fingers!

The instruments must be used with electric or air motors that are capable of very slow speeds of around 150–600 revolutions per minute with good control of torque. Different systems require different speeds of rotation and, in general, more rapid rotation creates stresses within the instruments that may result in fracture.

The disadvantages of these systems are that they are expensive and require training and experience using extracted teeth before using them on patients.

The preparation technique requires a crown-down approach with canal orifices being enlarged for access as mentioned earlier. When preparing the body of the canal, rotation and movement of the file must be maintained from before entering the canal, throughout time the file is in the canal and until the file is out of the canal. A *glide path* is established so that the file passes into and out of the canal with light pressure. Much lubrication is required and it is common to use compounds that include chelating agents, such as ethylenediaminetetraacetic acid (EDTA), to assist dentine removal. The instrument should only remain in the canal for short periods of about 10 seconds as it is moved in and out; the movement is referred to as *pecking*.

It is difficult to control apical position of the file in this way and care must be taken not to go beyond the working distance. Normally the apical stop will be prepared with a file of 2% taper and the remainder of the canal with progressively increasing tapers (4%, 6%) to create the flared shape.

The risk of fracture of files means that damaged files must be discarded and narrow files should be used for only one patient. Larger files may be used on several occasions but the difficulty in stock control may lead to all files being discarded after one use.

Rotary systems are not without their problems and it is important to appreciate some of the anatomical problems that will interfere with their action. These include canals with acute apical curvatures, 'S'-shaped canals, wide canals becoming narrow, or with two canals merging into one apically.

Because of these problems a general pattern has been evolving such that hand files are necessary for the control and definition required in the preparation of the apical region but the mechanical systems may make bulk preparation of the remaining canal easier.

## General problems

*Haemorrhage* should not be seen during canal preparation. If it is, this may indicate:

- Pulp remnants still present at the apex
- Apical perforation
- Lateral perforation
- Furcation perforation

A radiograph should be taken with the apical stop file in place and the working distance checked. *Pulp remnants* may be removed by filing since they will often be inaccessible to a barbed broach; local analgesia is necessary. *Apical perforation* may allow extrusion of material at the root filling stage. The correct working distance should be re-established and an apical stop created. Small *lateral perforations* and *furcation perforations* can be sealed at the root filling stage after the correct line of the canal has been re-established. Large lateral and furcation perforations are difficult to seal and therefore have a poor prognosis.

After preparation, the canal should be dried first with a cotton wool pledget and then by careful use of paper points. To dry the apical stop, the paper point should be capable of passing into it. That is, do not use no. 60 points in a no. 25 canal!

## Irrigation and antibacterial techniques

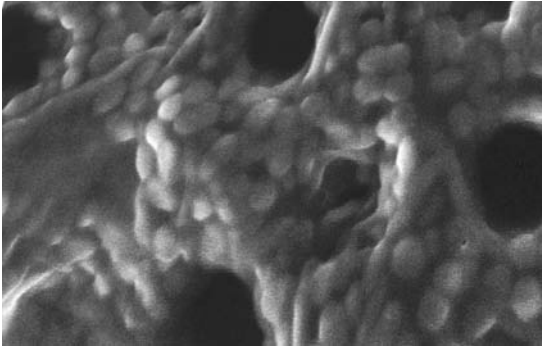
As already mentioned, copious irrigation is necessary to lubricate files and remove debris. In addition, it is now recognised that removal of bacterial contamination from both within the canal and within the lateral canals and opened dentinal tubules is important. Such antibacterial action may also be enhanced by removing any smear layer (Chapter 9) that has formed on the wall of the canal as a result of the preparation.

So to summarise, an irrigant should:

- Remove debris
- Lubricate instruments
- Assist the removal of dentine during preparation
- Remove smear layer
- Disinfect the canal system

There is no compound available that is effective at achieving all of these roles by itself.

For many years, the two common irrigants were normal saline and 1% sodium hypochlorite. The hypochlorite dissolves organic matter and is mildly bacteriocidal, whilst the advantage of saline is that it is non-irritant if passed through the apex.



**Fig. 12.10** Biofilm. Scanning electromicrograph of bacterial biofilm taken from a dentine surface after 24 hours. There are substantial numbers of bacteria in a web of extracellular material.

In many cases, bacterial contamination within a root canal has developed over a long period and the bacteria have had the opportunity to develop a favourable environment for their survival. Particularly, near the apex of the canal a substantial biofilm will have developed in which a range of bacteria will survive symbiotically with one another. The biofilm also provides protection for the bacteria against both mechanical and chemical disruption. Thus, during the preparation of the canal, the biofilm must be mechanically disturbed. Failure to achieve this, particularly in cases where there is a substantial build up in biofilm thickness, means that any disinfectant will require substantial time to pass into the biofilm and have any effect (Fig. 12.10).

The irrigants which are currently used may be split into cleaners and disinfectants.

### Cleaners

The primary role of these materials is to debride and clean out dentine dust from the canal. They may also have a secondary function in assisting in the removal of the smear layer created by the root canal preparation. Examples of cleaners are saline, 17% EDTA, 20% citric acid and 0.5–5% sodium hypochlorite. The only one of these with some bacterial potency is sodium hypochlorite. There is no evidence to support the use of concentrations of hypochlorite greater than 1% and proprietary bleach preparations that are marketed for household disinfection should be avoided because they usually contain compounds in addition to the bleach which may be toxic and also alter the pH to high alkalinity. They would also be used outwith the manufacturers' intended purpose for the

product with possible legal consequences if there are problems.

### Disinfectants

Disinfection during and after cleaning is essential and sodium hypochlorite is effective if used in copious volumes. It is not, however, effective against some of the bacteria associated with persistent infections such as *Enterococcus faecalis*. Sodium hypochlorite used in conjunction with chlorhexidine and povidone iodine have been used to address the limited efficacy of hypochlorite alone.

Recent additions to the disinfectants include two systems, one based on ozone and the other referred to as photo-activated disinfection (PAD). The PAD system consists of a dilute solution containing pharmaceutical grade tolonium chloride and a low-power 635-nm laser light source that activates the solution through a disposable handpiece tip. In this way singlet oxygen, which is a potent bactericide, is produced in the root canal.

All these systems require that the active agents must reach the bacteria and this highlights the importance of biofilm disruption.

### Medication

After preparation, canals may be filled by some type of dressing material that could have an antimicrobial effect. Many substances ranging from antibiotic mixtures to very irritant disinfectants have been used. No conclusive evidence exists regarding the efficacy of canal medication.

The waiting of a week or so between preparation and filling does allow any acute apical reaction to pulp extirpation or debris being pushed through the apex to subside without pain. The inflammatory exudate can pass into the partly empty canal. It is essential that the temporary restoration seals the access to the root canal effectively.

A mild antimicrobial with very low irritation is calcium hydroxide in a propylene glycol vehicle. While this has proved to be reliable, there is some doubt as to its efficacy against the bacteria associated with recurrent endodontic infections.

Calcium hydroxide is sometimes successful in resolving a persistently oozing canal if left for 4–6 weeks, though replacement is necessary every 10 days or so to maintain activity.

Single visit root canal therapy is possible, provided there is no infection present. This has the advantage

that the canal is open for a relatively short period, there being no temporary dressing that may leak and contaminate the canal.

## Root Filling

After preparation, and before root filling, the tooth should:

- Be symptomless
- Not be tender to percussion
- Have no exudate in the root canal(s)

If any one of the above is present, it indicates continuing pathology. Wash the canal to remove the dressing, dry it, re-establish the working distance with the apical stop file, re-disinfect and re-dress. Review in a week to 10 days.

When obturating the canal, the master cone must match the file size as closely as possible, but some variation in the GP cones is inevitable because of difficulties in manufacture. After placement of the master cone, lateral or accessory cones are condensed into place together with the sealer. This means that the working time of the sealer should be sufficiently long to allow this.

The sequence for root filling is:

- 1 Remove the dressing from the canal, re-establish the apical stop with the appropriate file. Wash, disinfect and dry
- 2 Select the GP point of the apical stop size and mark the working distance on it; insert it into the canal slowly
- 3 Make sure the point reaches the working distance and is a good fit ('tug back')
- 4 X-ray to check that the GP fits to the working distance

If the point does not fit to the working distance when tried in, or is short when X-rayed, repeat the preparation of the apical stop to either clear debris, or extend the preparation if it is short. Re-check the diameter of the GP point on a gauge, and if necessary, try another one of the same nominal size. The GP try-in also checks the preparation in addition to checking the master cone fit.

Then:

- 5 Mix sealer and place a range of accessory cones with their tips in the sealer
- 6 Select a file size smaller than the apical stop and coat this with sealer and, with an anticlockwise

rotation, coat the canal walls with sealer, up to the stop

- 7 Coat the master cone with sealer, insert it carefully (beware hydraulic effects causing pain or extrusion) to the marked working distance
- 8 Using lateral spreaders, beginning with the smallest, make room for accessory cones alongside the master cone and build up the full filling sequentially
- 9 Take a post-operative radiograph and seal the access cavity

If the canal is overfilled, tell the patient and keep it under review. If the canal is underfilled because of technical error, remove the root filling and start again.

If this underfill goes to the working distance which is short because of some obstruction, then again tell the patient, and keep it under review.

## Problems Encountered During Root Canal Therapy

The almost blind instrumentation of a series of natural channels of variable anatomy is inevitably accompanied by risk. Table 12.2 sets out the major problems that might be encountered during root canal therapy. Some of these have been or will be discussed in more detail within the text.

It is important that the patient understands the technical difficulties that may be encountered during root canal therapy. This will be the basis for their informed consent. In the event of a complication, such as a lateral perforation or a fractured instrument, the patient must be informed about what has happened and its likely outcome.

### Fractured instrument

The current techniques of filing rather than reaming and the construction of modern files means that broken instruments are less common. Forcing instruments around canal bends or jamming them in the apical constriction are recipes for disaster.

The most likely instruments to fracture will be fine files in a curved apical region or the tips of Gates–Glidden burs in the canal orifice. The former are usually impossible to remove. The canal preparation should be completed, perhaps with by-passing of the fragment, and gutta-percha condensed around it.

Overflexing is the usual reason for Gates–Glidden fracture and the main shank of the bur is supposed to be the fracture zone of the instrument. However, tips

**Table 12.2** Root canal therapy problems

Stage	Problem	Action	Comments
<i>Access</i>	Incomplete analgesia	<ol style="list-style-type: none"> <li>1. Repeat LA with 3% prilocaine or 5% xylocaine</li> <li>2. Steroid dressing for 48 h; retry LA</li> <li>3. If all fails, general anaesthesia for pulp extirpation</li> </ol>	<ol style="list-style-type: none"> <li>1. Second agent potentiates the first</li> <li>2. Pulpal inflammation is reduced, neural pain pathway recovers, LA then becomes effective</li> <li>3. Ensure that GA is justified on likely success rate of RCT</li> </ol>
	Perforation – furcation or lateral	Re-establish correct canal line If small, pack perforation with calcium hydroxide or MTA; this will be supported by the RCF later	Prevention is better than cure Note root angle before cutting especially if there is an artificial crown present that may obscure the true angle
<i>Canal preparation</i>	<i>Incorrect working distance</i> from radiographic distortion	Retake radiograph	Avoid calculating working distance if: <ul style="list-style-type: none"> <li>• the image of the file is not 1:1 with reality</li> <li>• the file does reach to within 5 mm of the apex</li> </ul>
	<i>Obstructions</i>		
	Secondary dentine, pulp stones	Dentine softening agent, e.g. EDTA, slow reaction – seal and leave	
	<i>Canal anatomy</i>		
	Curves, fins, apical delta, lateral canals, accessory canals, internal resorption,	Prepare only those major channels that allow file access	
	<i>Preparation faults</i>		
	Ledges, zips, elbows	Attempt to re-establish correct preparation path	
	Apical transportation	Pre-curve instrument, attempt to reach correct apex	Hand instruments only
	Apical perforation	As open apex; see text	
	Strip perforation, lateral perforation	Attempt sealing at RCF stage	Prognosis for large perforations is poor If accessible, consider surgery. (see Chapter 29)
<i>Fractured instrument</i>		If at the apex and tooth symptomless, root fill around fragment	
		If in main body of canal, remove (see Chapter 29) or by-pass using canal anatomy	The round instrument will not obstruct all of an oval canal
		If irremovable consider apical surgery	Always inform the patient
<i>Fractured root</i>	See Chapter 3		
<i>Open apex</i>	See text		

Continued

Table 12.2 cont.

Stage	Problem	Action	Comments
	<i>Post crown present</i>	If crown sound, consider apical surgery If inadequate, remove, re-root fill and re-restore	
<i>Medication</i>	Persistent exudate and/or symptoms	Check working distance and preparation; re-dress with calcium hydroxide Consider apical surgery	
<i>Canal obturation</i>	Overfilling	Radiographic review if symptomless If symptoms, remove or consider apical surgery	
	Underfilling/ under-condensation	Remove RCF and re-fill	If found at review: leave if no pathology Re-root fill if to have new restoration even if no pathology

may break in the canal and because these are usually superficial, they can be retrieved using a file or excavator. Failing this, the Masserann kit (see Chapter 29) may be used.

Ni-Ti instruments, particularly if re-used, may suffer tip breakage. Various innovative techniques have been proposed to attempt the removal of these pieces, e.g. bonding a new file to the fractured piece by cyanoacrylate adhesive and removing it.

### Open apex

This may occur as a result of incomplete root formation (Chapter 3) or because of instrumentation beyond the apical constriction (apical perforation). It makes root filling difficult because there is no restriction to the escape of sealer in to the apical tissues. In the immature root, the canal is funnel shaped, becoming wider towards the apex. Conventional condensation is then almost impossible.

The preparation of the immature canal should be done by careful circumferential filing, since the apical diameter is usually larger than the largest file. The root filling should be made up, by trial and error, from warming and coalescing several GP points into a large single cone of the right diameter. This can be tried-in in the usual way and then sealed carefully, avoiding extrusion into the tissues.

Filling a canal with an apical perforation is also difficult. The length of insertion of the master cone

must be controlled carefully, and it should be held against the crown whilst inserting lateral cones, so that the spreaders do not push it past the apex. Lateral condensation must be gentle, to avoid extrusion of sealer.

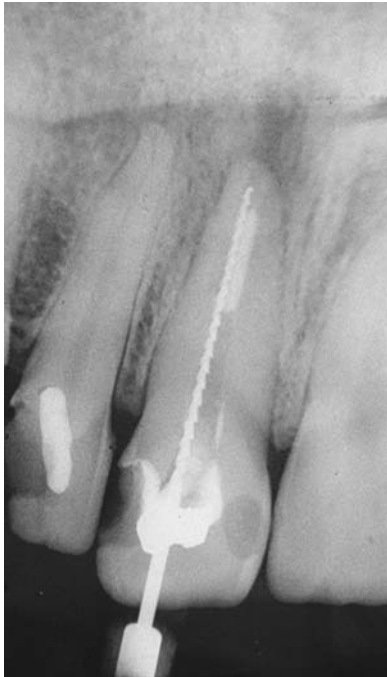### Review

Apical tissues take time to heal, and progress should be monitored radiographically, in the absence of symptoms, at about 1 year after filling, and then every 4 years. There is an incidence of recurrent infection around apparently successful root fillings that may relate to lateral canals, or to short zones of unfilled apical canal.

More frequent radiographs, perhaps yearly, might be necessary to monitor the healing of a large apical radiolucency to ensure that reduction in size is proceeding.

Healing of the root end is by the laying down of cementum across the apical foramen and possibly the presence of clean dentine dust will help this. There may be a very small zone of clean compacted dentine chippings at the final extent of successful root fillings.

The final coronal restoration should be completed as soon as possible after the root filling. There is evidence to suggest that leakage from the crown will contaminate the root filling and promote bacterial growth.



**Fig. 12.11** The removal of a GP point by a Hedstroem file. This file is ideal because of its rearward facing barbs.

## Recurrent Infection

Symptoms, or radiographic appearance of an increasing area of radiolucency at the apex indicate pathology and failure of the root filling. Consider either:

- Removing the root filling and repreparing the canal(s)
- Apical surgery
- Extraction

Do not intervene in cases of long standing, symptomless over or underfilled canals, though there could be an exception to this if the tooth was to receive a crown or be a bridge abutment. Residual apical radiolucency may be accepted in the absence of symptoms provided that the apical area is less than 5 mm in diameter.

## Management of old root fillings

This is usually the main problem in retreatment. If the canal is filled by a single GP cone, it is usually possible to insert a file, preferably a Hedstroem type with its backward facing barbs, alongside the cone, engage the blades and pull the cone out (Fig. 12.11).

On the other hand, if the root filling, or fragment of instrument, cannot be removed, it may be possible to by-pass it and then incorporate it into the new root filling (Fig. 12.12).

Once the root filling has been removed, it will then be necessary to start the root filling preparation from the beginning, establish the working distance and prepare the canal (Fig. 12.13). Sometimes the old root filling may be short because of a canal obstruction which may prevent the re-preparation. This can only be ascertained once the root filling has been removed so there will be some uncertainty in predicting outcome before commencing retreatment.

Clearly, a further alternative to retreatment is extraction of the tooth and the patient must understand the expected success of the proposed procedure and have the option of extraction explained. In general, retreatments are not as successful as root treatments provided from scratch. In all cases, teeth with established apical infection have a poorer outcome in comparison with uninfected teeth.

## Apical Surgery

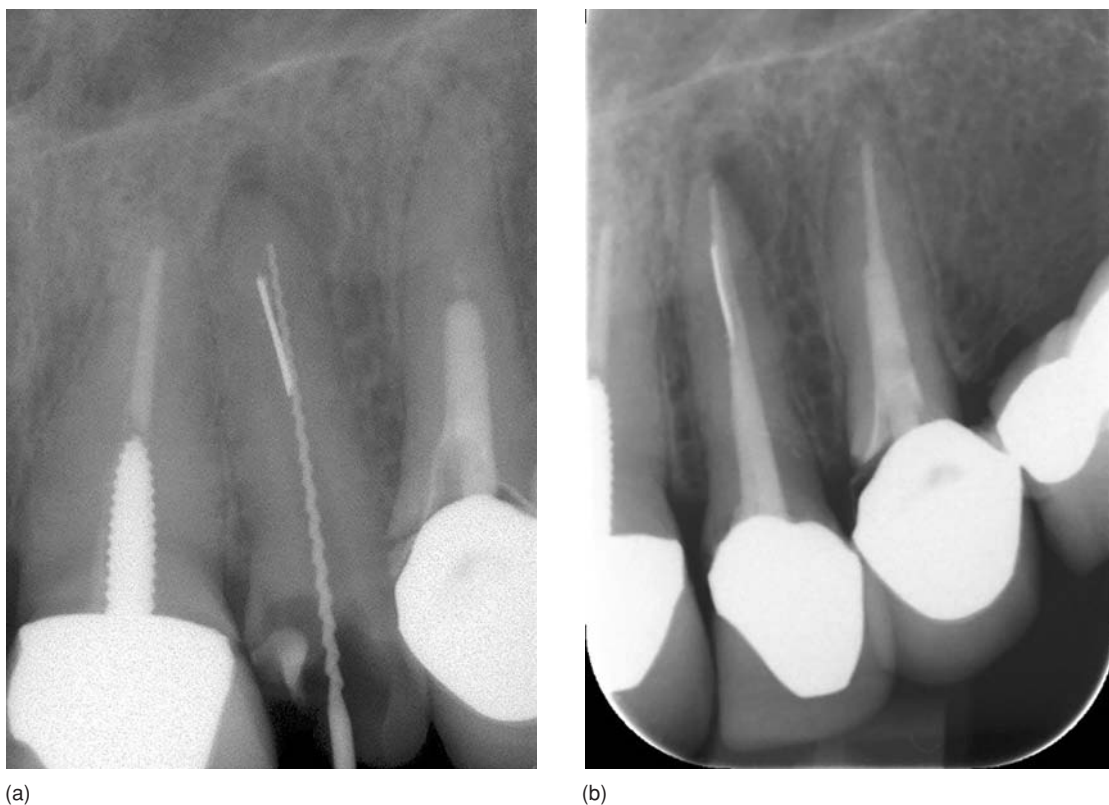
The surgical approach to the root apex is required to place an apical seal when the conventional approach through the root is impossible, or when an apparently well executed root filling has failed. Surgery should be reserved for these cases and should not be used to correct symptomless and signless filling errors.

The circumstances in which to consider surgery are, in the *presence of infection*, canals that are non-negotiable or difficult to fill because of:

- Secondary dentine, curves, pulp stones
- Fractured instruments
- Post crowns (Fig. 12.14)
- Unremovable root fillings
- Lateral canals
- An open apex

Surgery may also be used to provide root canal treatment rapidly or to deal with infection that persists in spite of repeated dressing.

If the unremovable root filling is an apical silver point or a retrograde amalgam, and the remainder of the canal is empty, then the cause of the infection may be leakage past the filling into the canal. Bacteria can obtain their nutrient from the leakage and toxins pass out into the tissues. In these cases it is worth trying to prepare the empty canal and fill it up to the existing root filling (Fig. 12.15).



**Fig. 12.12** (a) Upper left lateral incisor having an apical area associated with a sectional silver point. Exploration of the canal led to reaching the apex without removing the point. (b) the canal has been filled around the silver point

### Apicectomy technique

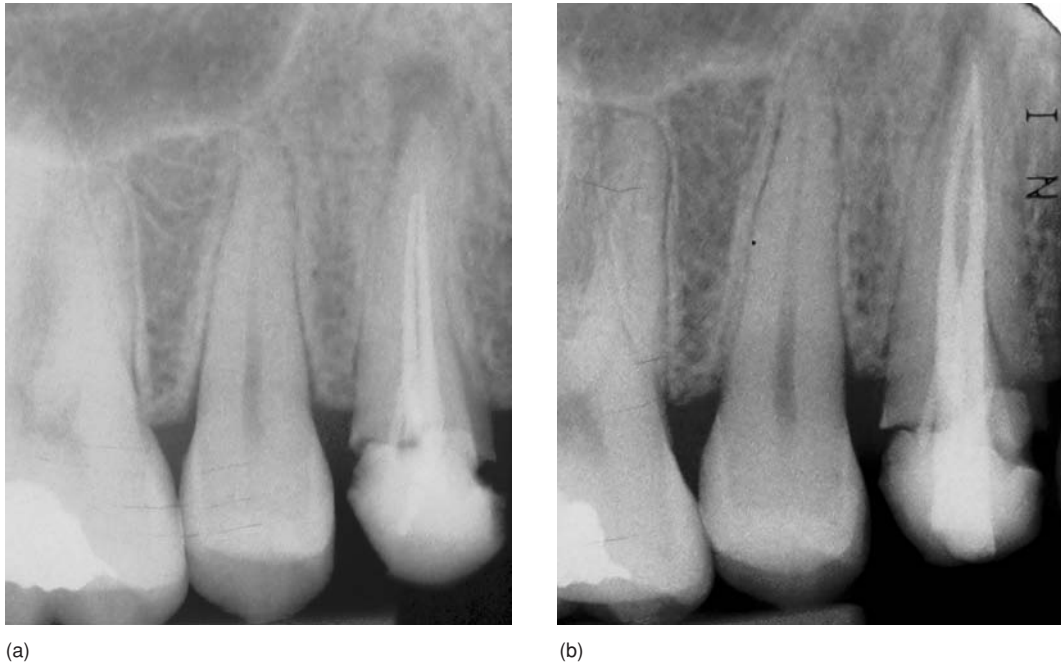
Local analgesia is usually acceptable for most single teeth. Intravenous sedation or general anaesthesia may be indicated for several teeth or apprehensive individuals.

The analgesia must be effective, with palatal and incisive canal blocks being necessary for upper anterior teeth.

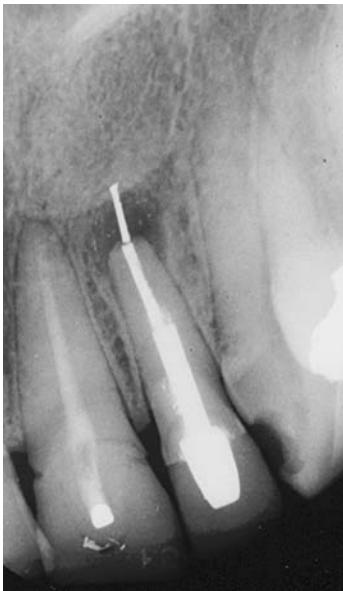
The sequence is:

- 1 Analgesia
- 2 Raise full gingival flap with bevelled incision at the papillae (Fig. 12.16); this gives good access and little scarring
- 3 Identify the apical region by pressure with an excavator to try perforating the cortical plate over the infected area. Otherwise measure the root length from the pre-operative radiograph
- 4 Remove cortical bone with slow speed burs with copious irrigation
- 5 Avoid scarring the root by working higher than the apical level initially
- 6 Obtain clear access to the root apex and identify any anatomical structures of relevance, e.g. antrum, mental nerve
- 7 Clear any soft tissue around the apex – *excision biopsy*
- 8 Reduce the apex by a bevelled cut, so that the root face is angled towards the operator
- 9 Cut a 2- to 3-mm-deep undercut cavity in the root canal end; this may be assisted by ultrasonic instruments
- 10 Wash, dry and pack the bone with ribbon gauze to isolate the apex
- 11 Place retrograde root seal (see below)
- 12 Remove gauze and excess sealant, irrigate, close and suture

Systemic antibiotics should be prescribed pre-operatively for medical problems, or post-operatively for the prevention of infection in a large bony cavity.



**Fig. 12.13** Retreatment of an upper premolar. (a) The tooth has an apical area associated with two short and underprepared root fillings; there appears to be root canal beyond the points. (b) The tooth has been retreated by removing the root fillings, re-establishing the working distance, re-preparation and re-filling. The two canals terminated in a single apical foramen.



**Fig. 12.14** Extruded GP in  $\overline{12}$  associated with symptoms and a sinus. There is a very good post crown present, and the extruded filling probably could not be retrieved anyway. The tooth was apicectomized. The post-operative radiographs are shown in Fig. 3.5.

The more posterior the tooth, the more difficult will be the surgery and the more likely there will be anatomical complications.

The palatal roots of upper premolars are difficult to reach and see. Palatal roots of upper molars would require a separate palatal flap, but these roots are straight and can usually be root filled conventionally. The buccal roots are easily accessible by surgery.

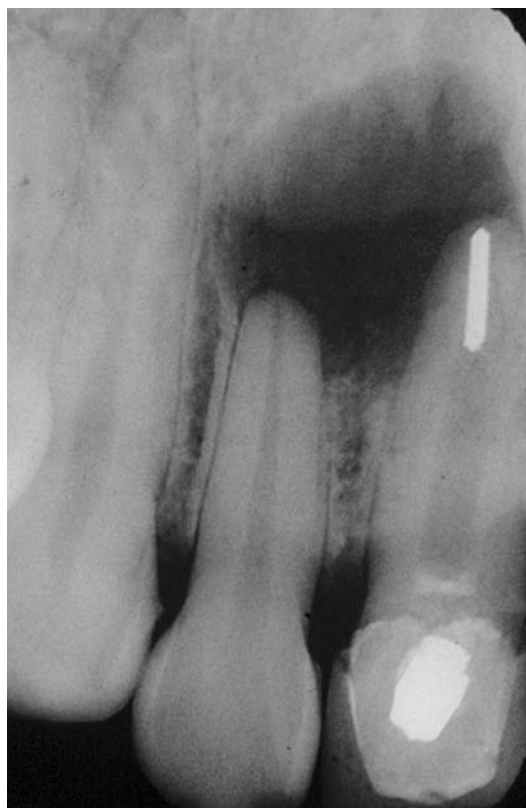The maxillary antrum lies close to the upper premolars and molars. Antral perforation does not usually give rise to problems because the flap closes it. The patient should be given systemic antibiotics and told not to blow his nose.

The mental nerve is a complication with lower premolars, and the hazard of mental anaesthesia must be mentioned when consent to apicectomy in the region is sought. Many now consider that apical surgery of lower premolars is contraindicated because of the possibility of this complication.

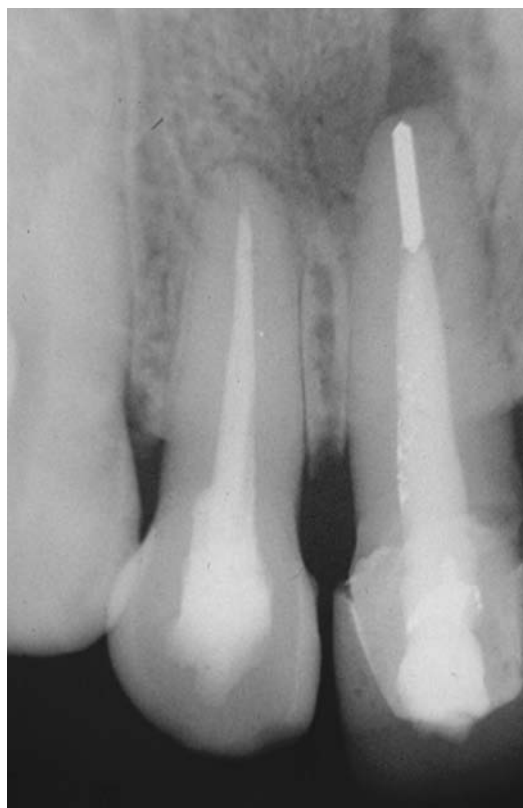The inferior dental nerve is close to the lower molars – do not apicect these teeth.

Finally, always place a retrograde seal; do not rely on the sealing ability of the existing root filling, which may be disturbed when cut.





(a)



(b)

**Fig. 12.15** (a) Apical infection associated with a non-vital  $\underline{2}$  and an apical silver point in  $\underline{1}$ . (b) This was treated by conventional root canal therapy of  $\underline{2}$  and root filling the  $\underline{1}$  up to the silver. The result was complete resolution of the infection without surgery.

### Retrograde root sealer

For many years amalgam was the recommended material for retrograde root filling. The success rate of this material was good but in view of the concerns about the toxicity of amalgam discussed in Chapter 10, other materials for retrograde root filling have been suggested.

The glass ionomer cements and EBA reinforced zinc oxide–eugenol cements have been used with reported success equivalent to that of amalgam. The sensitivity to moisture of both materials and the solubility of the ZOE cements could be disadvantages when in contact with tissue fluids.

The preferred material is currently *mineral trioxide aggregate* (MTA) which is essentially Portland cement mixed with sterile water. The handling of this material is not easy and it is expensive. However, it has been shown to have good biocompatibility and clinical results are favourable.

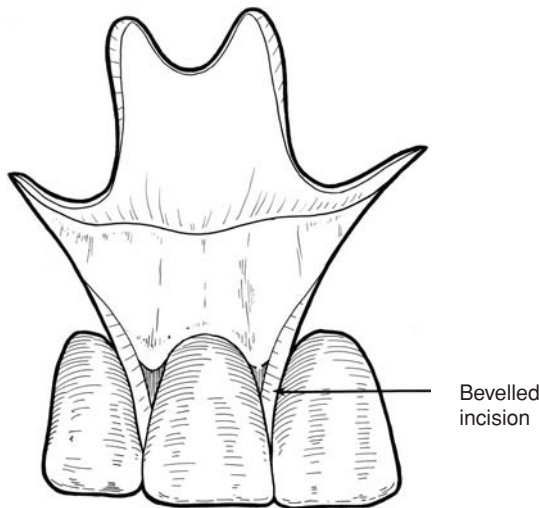
### Through and through technique

Where a post crown is to be placed, the post should be made first before the surgery, in case the post-preparation displaces the apical seal later. The surgery is performed by a *through and through* technique where the canal is open to both the mouth and the apical tissues. The canal is dried and the post cemented with the apical tissues protected from excess cement (Fig. 12.17). The through and through technique may also be used where there is an open apex and an empty canal. The canal is root filled with the flap raised and a retrograde seal placed afterwards.

### Review and treatment options

Apical bone may take several months, sometimes over a year, to fill in. This should be monitored radiographically at regular review (see Fig. 3.5).

When considering apicectomy as a treatment option, it should be remembered that this is an



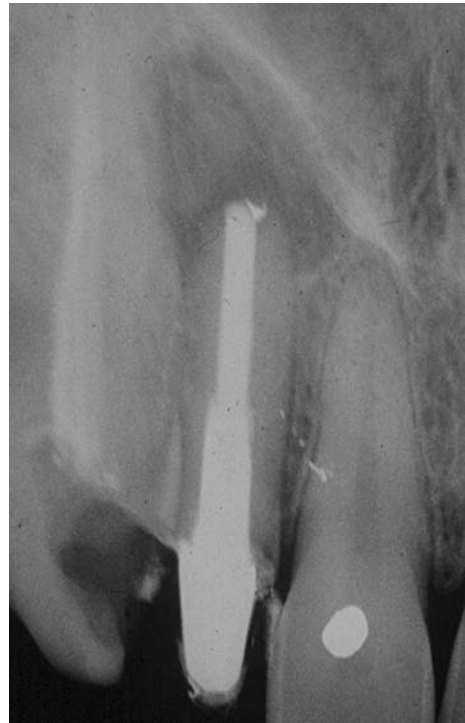
**Fig. 12.16** Full gingival flap for apical surgery. The incision at the gingival papillae is bevelled to provide a broad area for replacement, which reduces recession.

unpleasant and sometimes painful surgical procedure with an uncomfortable immediate post-operative period. Success rate studies suggest an overall rate of about 80% but studies running for over 4 years are rare. The success of implant therapy is considerable higher and more predictable, and this should be considered as being more desirable than trying to save a tooth on its last legs (Chapter 22).

### Success Rate of Root Canal Therapy

Outcome analysis in restorative dentistry is generally inadequate, particularly from general practice. Whilst success rate studies have been reported, these are often retrospective and therefore pre-operative criteria are not established and various techniques may be employed. The studies often include a large number of operators. Clinical trials of restorative materials are an exception, probably because they are easier to conduct with clear trial entry criteria, proper control groups, pre-trial training of operators. Assessment criteria are well established and short-term analysis means that most of the original cohort of patients can be reviewed. On the other hand, the design factors for fixed prosthodontics are very difficult to study.

In root canal therapy, success rate studies rely to a large extent on radiographic interpretation and the reproducibility of some of these is notoriously poor. The acceptance of new instrumentation techniques is



**Fig. 12.17** A long post has been inserted in 2| at the time of apical surgery prior to the placement of the retrograde seal. A provisional crown is placed at the same time to wait for gingival healing.

based on laboratory studies rather than clinical outcome studies.

The highest success is found with single-rooted teeth with little or no infection (>90%) whilst the lowest is with multi-rooted teeth with established and long standing apical areas particularly in the mandible (<60%). Bacteria can remain undisturbed in such tooth sites as lateral canals and non-obtured areas of main canals and within well established apical areas. The problems described in Table 12.2 all reduce the success rate. Underpreparation and underfilling are associated with lower success than overfilling.

The clinical studies show that the principal factors influencing success are:

- Root canal morphology
- Quality of canal preparation and filling
- Presence of apical infection

The overriding requirements of root canal therapy are to remove viable bacteria from the canal system or kill them, and to prevent their re-establishing themselves there again.

### **Root Canal Therapy – Summary**

Base treatment planning on accurate radiographs and a realistic assessment of outcome.

Thoroughly debride as much of the canal system as possible and disinfect the rest.

Shape the canals in accordance with the choice of root filling material.

Obturate all the prepared space.

Review apical condition regularly.

# Chapter 13

## Management of the Periodontally Involved Dentition

This chapter will consider aspects of diagnosis, treatment planning, treatment and follow-up for a patient having periodontal disease together with comments on the broader restorative implications of the management of the disease.

### Introduction

The planning and execution of treatment for any disease or condition is dependent on careful diagnosis. Having defined periodontitis in Chapter 7, the disease should be easily diagnosed by noting gingivitis accompanied by loss of attachment. Unfortunately, this alone is of little value to treatment planning for an individual patient and the diagnosis of periodontitis needs to be qualified. Such qualification requires:

- Identification of aetiological and predisposing factors
- Qualification of disease severity
- Appreciation of patient factors relevant to management

The disease itself arises from the interaction of a pathogenic subgingival flora on a susceptible host. Therapy aims to eradicate the former but can do little to alter the latter so for this reason recurrence of the disease is always a possibility. Long-term successful treatment of the patient with periodontal disease depends on a considered management programme where pre-and post-treatment care is as important as the actual treatment itself.

*Management of periodontitis* is based upon initiatives for:

- Removal of subgingival plaque (*therapeutic phase*)
- Prevention of recurrence through the control of supragingival plaque (*preventive phase*)

The therapeutic phase is highly operator dependent whereas the preventive phase is highly patient dependent. Both are based on mechanical debridement of supra and subgingival plaques and clearly the efficiency of the procedures used, whether in the surgery or at home, will have a direct bearing on success.

Chemical agents, largely against micro-organisms and antimicrobial, may be employed both locally and systemically. Modification of the host response to plaque is an alternative possibility.

### Diagnosis – Qualifying Factors

Once loss of attachment in the presence of inflammation, based on clinical and radiographic examinations, has been established, the diagnosis of periodontitis is made. The diagnosis must then be qualified in order to prepare a treatment plan.

### Plaque scores

Accumulation of dental plaque at the gingival margin is the major aetiological factor in gingivitis and gives rise to the subgingival plaque associated with periodontitis. Levels of plaque on all or selected teeth should be recorded using a suitable index or scoring method (see Chapter 2).

Plaque scoring at various time intervals forms the basis for diagnosis, oral hygiene instruction, assessing response to instruction and for patient information and encouragement. Clinical probing and radiographic examination provide information about the presence of subgingival deposits, notably subgingival calculus, and usefully directs treatment.

### Local predisposing factors

Certain factors encourage plaque accumulation and some make plaque removal difficult by normal tooth cleaning methods. These include:

- Supra and subgingival calculus
- Carious cavities

- Subgingival restorations
- Overhanging restorations
- Poor approximal contact areas
- Fixed and removable appliances or prostheses

Perhaps surprisingly, mucogingival anomalies and tooth malpositions have little bearing on plaque accumulation and removal.

### Modifying factors of the gingival or periodontal response to plaque

Local or systemic conditions referred to in Chapter 7 should be identified from the history and examination of the patient. Special tests to determine predisposition or susceptibility to periodontal disease are rarely needed and the important factors usually arise from the medical history. However, where unusual symptoms or signs are apparent, particularly in gingival inflammation, that appear outwith the known medical history or local factors, haematological investigation must be considered.

It is worth noting that at present the use of microbiological methods to qualify the bacterial aetiology of periodontitis are of no value in the treatment planning of individual patients with chronic periodontitis and of little, if any, value to aggressive types of disease.

### Severity

It is essential to qualify the diagnosis of periodontitis for severity, particularly in respect of the patient's age. The following aspects should be examined to determine the severity of periodontitis:

- Gingival inflammation and associated recession or enlargement
- Loss of attachment
- Mobility
- Bone loss
- Tooth position
- Tooth vitality

*Gingival inflammation* may be demonstrated by bleeding on probing and the observation of gingival enlargement that may be local or general. Localised inflammation is most likely to be due to local predisposing factors such as poorly adapted crown margins.

*Gingival recession* may be local or general where again a differential diagnosis based on aetiology may be required. Gingival recession may lead to sensitivity

of dentine and poor aesthetics. These may need to be considered in the general treatment plan.

*Loss of attachment* is observed by using a graduated periodontal probe to measure pocket depth which in turn may provoke bleeding or exudation of pus. Pocket depths, indicating loss of attachment, are recorded in millimetres. Observation of bleeding in response to probing provides information on the distribution and severity of gingival pocket inflammation.

Multisite probing (6 per tooth) is often recommended but a considerable amount of information can be derived from mesial and distal probing and probing to the furcation areas of molar teeth.

*Mobility* is assessed using the handle of the probe alone or together with the handle of the dental mirror and typically graded on a 0 = none through to 3 = severe basis. Sophisticated instruments are available to measure mobility but their value to the assessment and follow-up of the individual patient is questionable. Vertical mobility is usually a poor prognostic sign and care must be taken in distinguishing pathological mobility resulting from bone loss and physiological mobility due to increased tooth loading, particularly as they may coexist.

*Bone loss* may be diagnosed from the probing depths and from *bitewings* or *periapical radiographs* (Chapter 2). However, full mouth periapical radiographs for diagnosis and follow-up of periodontal disease are now rarely required because the diagnostic yield is low without supplementing to any great extent the information that can be found by clinical examination.

Bone loss both in extent and type (horizontal or vertical) should be noted with particular reference to furcation defects; the latter being poor prognostic indicators to treatment success. The type of bony lesion will influence decisions concerning non-surgical and surgical periodontal treatment and the use of guided tissue regeneration and/or bone grafts.

*Tooth position* may indicate that drifting and/or overeruption has occurred. Particularly at anterior sites, aesthetic considerations may have major treatment planning implications, and decisions concerning orthodontic and restorative treatments have to be made.

Periodontal lesions may compromise *tooth vitality* and conversely endodontic lesions may create apparent periodontal or furcation lesions. Distinguishing an endodontic–periodontal lesion from a periodontal–endodontic lesion is important due to the poor treatment prognosis of the latter compared

to the relatively good treatment prognosis of the former. Clearly, both can coexist making definitive diagnosis difficult. Sinus formation may be important in the differential diagnosis of apical from periodontal infections since sinuses are more likely to be associated with apical disease.

Most assessments of disease severity must be correlated to *age* since this provides information concerning disease susceptibility and rate of disease progression, prognosis and therefore treatment planning.

A number of methods using chairside test kits have been used in the past to evaluate disease activity and to demonstrate the presence of certain periodontopathogens. Lack of sensitivity and specificity has largely resulted in discontinuation of their use in routine periodontal practice.

### Patient factors

Patient factors are of considerable importance to treatment planning since they can influence the disease itself and the ability and willingness of the individual patient to participate in the treatment plan. Firstly, there is a need to assess whether an individual can fulfil the long-term commitment to the prevention phase of management alone or with assistance from third parties. Secondly, it is important to determine whether an individual can receive the ideal treatment for the disease. Some of the answers to these complex questions can be determined easily from direct discussions with an individual and a consideration of their psychosocial and medical backgrounds. Other aspects of assessing their ability to participate in the management programme are difficult sometimes impossible to evaluate, particularly during initial appointments.

Patient factors that may be relevant to the preventive phase of management are numerous and at present many are poorly understood. At the extremes, why some individuals appear able to practise good plaque control and others not, often cannot be explained. It may be simply related to their apparent compliance and dexterity with oral hygiene practices that has been determined in retrospect, rather than predicted prospectively at the initial diagnostic and treatment planning visits.

Nevertheless, some factors that may contribute to difficulties with oral hygiene can be identified:

- Physical and/or mental handicap
- Chronic medical conditions particularly of painful nature may influence cooperation

- Social or occupational commitments may limit time available
- Social problems can affect ability and willingness

Patient factors that can influence the receipt of treatment are usually more obvious but potentially large in number and variable in their impact.

The age and general medical and psychological health of an individual are most important. As an example, in the aged it is possible to judge retrospectively the susceptibility to periodontal disease and plan treatment accordingly. In such circumstances treatment is likely to be conservative, even palliative. Conversely, in the young healthy adult, particularly with advanced periodontitis, treatment planning may have to be aggressive.

Specific aspects of the *medical history* can place individuals at risk from periodontal procedures, both non-surgical and surgical. These include:

- Previous endocarditis, congenital and acquired heart valve defects and cardiac valve replacement
- Bleeding diatheses and other acute haematological disorders
- Anticoagulant therapy
- Long-term steroid therapy

Medical disorders or conditions may influence the timing of periodontal procedures, for example:

- Pregnancy
- Coincident medical or surgical procedures

Concurrent pharmacotherapy may influence the periodontal state and therefore treatment decisions notably those associated with gingival hyperplasia.

Medical conditions or drug therapies can influence the decision to employ chemotherapy within the periodontal treatment plan. These include where the periodontal chemotherapy could induce:

- An adverse patient reaction due to allergy, for example penicillin or aspirin
- An adverse interaction with current medication, for example aspirin and coumarin anticoagulants
- An antagonism of an existing medical condition, for example aspirin and peptic ulceration
- Potential deleterious effects to the foetus during pregnancy, for example metronidazole

Medical and social problems can affect the patient's ability to attend for treatment particularly since periodontal treatment is often continuous and protracted with regular recalls. These problems could include

occupation, travel distance, availability of transport and finances.

### Treatment planning

Accepting that periodontal disease arises when suitable pathogens act on a susceptible host suggests three possible approaches to treatment:

- Removal of the pathogens
- Alteration of the host response
- Reduction or change of susceptibility

The mainstream approach to management of periodontal diseases has been and remains the removal of the subgingival pathogens and the prevention of recurrence through supragingival plaque control.

The host response can be altered to advantage by drugs such as non-steroidal anti-inflammatory drugs (NSAIDs). The role of NSAIDs in therapy is not established at present with clear concerns over benefit to risk ratio due to potential serious side effects. At present NSAIDs are of interest in researching pathogenesis of periodontal diseases. Daily use of low-dosage tetracycline (doxycycline hyclate) appears of interest for potential effects on host collagenase; the long-term additional benefit of this treatment remains to be established.

Susceptibility is poorly understood and therefore nothing can be done at present to change the susceptibility of most individuals with periodontitis. Specific aspects of the medical history that increase susceptibility, notably those influencing polymorph function, usually cannot be altered but have to be taken into account in treatment planning. Present knowledge indicates that patients with periodontitis should stop cigarette smoking. Improving diabetic control in Type I and Type II diabetics logically should decrease susceptibility but data are lacking to support this suggestion.

Based on the antipathogen approach to management, the following form the basic treatment plan for periodontitis:

- 1 Hygiene phase
  - Advice and instruction in supragingival plaque control
- 2 Therapeutic phase
  - Thorough debridement of the root surface
  - The use of surgery to improve access
  - Adjunctive use of antimicrobials
  - Recall and maintenance

Interestingly, this ‘modern’ treatment plan can be found almost in its entirety in periodontal textbooks from the beginning of the century. Before considering the specifics of the treatment plan applied to the average case of periodontitis, important factors concerning individual patients have to be considered since these may modify treatment planning to a lesser or greater degree. These include:

- Susceptibility factors influencing disease progression
- Predisposing factors that affect plaque accumulation and retention
- Severity factors that affect prognosis

*Susceptibility factors* include the modification of a smoking habit, diabetic control and the use of antimicrobials where polymorph function is compromised.

*Predisposing factors* that are outside patient control need to be removed or modified. These have been discussed earlier and frequently involve restorative procedures.

*Extractions* may have to be considered when:

- Periodontal therapy cannot or is unlikely to resolve the disease
- Aesthetics can only be improved by restorations
- Comfort and security problems can only be improved by restorations
- Coincident restoration problems exist making the tooth unsalvageable

Decisions concerning the above may have to be taken in consideration of the patient’s wishes, attitude, age and medical history.

Patient factors are of considerable relevance to treatment planning since they can influence needs and demands for treatment and affect the type and delivery of treatment. Some of the important patient factors that are identifiable from personal details, occupational, social and medical histories have already been mentioned. Most cannot be changed and therefore, when possible, the treatment plan has to be modified to accommodate them.

It is not unusual particularly where aesthetic considerations are important to the patient that collaboration with restorative and/or orthodontic colleagues is necessary. Based on these consultations, restorative and/or orthodontic procedures may be planned to improve aesthetics and function. It is essential to appreciate that such procedures should be consequent upon a successful outcome to periodontal treatment. There is evidence to suggest that restorative and more particularly orthodontic treatments which place increased

loading upon individual teeth can act as aggravating factors in the progress of active periodontal disease. In the presence of treated periodontal disease such effects appear irrelevant. Therefore, a sound basis for other treatments to the dentition must be a healthy periodontium.

## Hygiene phase

Advice and instruction in oral hygiene methods must be tailored to individual needs. There is no scientific basis for providing any particular type of advice and instruction and there is little evidence that any method or device is superior to others. It would seem reasonable that patients or, where indicated, a third caring party, need to understand the problem. Information on plaque, gingivitis and periodontitis should be provided and can include verbal and written information. The main aim is to achieve a level of supragingival plaque control compatible with gingival health. To achieve this, the clinician must identify individual factors which can affect compliance and dexterity with tooth cleaning habits.

Many individuals appear not to find interdental cleaning easy and do not follow advice. Some may have dexterity problems of varying magnitude and may require assistance. Certain sites appear difficult to clean with most people spending little or no time cleaning such sites; most notable are lingual and palatal areas.

## Oral hygiene procedures

In the absence of evidence for the superiority of any one method, recommendations should be based on individual needs and ability. Interdental cleaning is important in long-term management. Oral hygiene will involve:

- Toothbrushes
- Toothpastes
- Mouth rinses

### *Toothbrushes*

Tooth brushing with a toothpaste remains the primary method of oral hygiene in the developed world and the individual is the major variable in influencing the outcome of tooth cleaning. Twice daily brushing for 1–2 minutes appears optimal.

There is little evidence that variations in manual toothbrush design significantly influence oral hygiene and gingival health. However, it would seem reasonable to suggest that head sizes are not too large for the

specific individual and filaments are soft to medium with rounded ends.

Electric toothbrushes can be of benefit to handicapped individuals. Also there are some recent data to show that electric brushes with a rotary oscillation action provide some benefit compared with manual toothbrushes. The cost implications of electric toothbrushes have to be considered for each individual.

### *Toothpastes*

Toothpastes contain ingredients, such as detergents, that provide some plaque inhibitory effects but these are probably insufficient to benefit gingival health. Recent evidence is available that toothpastes containing chlorhexidine, stannous fluoride or triclosan (with either zinc citrate or polyvinyl methyl ether maleic acid) provide modest benefits to gingival health. However, chlorhexidine and stannous fluoride toothpaste have the potential to cause tooth staining due to interactions with dietary chromogens on the tooth surface.

### *Mouthrinses*

Mouthrinses containing a small number of agents, of which chlorhexidine is still considered the ‘gold standard’, have been shown to be effective adjuncts to tooth brushing with a toothpaste. However, as part of the long-term commitment to plaque control, the use of such rinses may be questioned on the basis of cost, benefit and local side effects.

For example, mouth rinsing twice daily with a proprietary product requires an approximate expenditure of four times that spent on toothbrushes and toothpaste.

The use of antiplaque agents notably chlorhexidine in the hygiene phase may be questioned. Chlorhexidine in the short-term provides little if any therapeutic action against established gingivitis and certainly established periodontitis, since subgingival deposits are relatively inaccessible to supragingivally delivered fluids. The considerable inhibitory properties of chlorhexidine against supragingival plaque make an assessment of the response to oral hygiene instruction almost impossible and may therefore be misleading.

The clinical responsibilities in the hygiene phase are to provide oral hygiene advice and instruction and to monitor response using plaque and/or gingivitis scoring. In addition, it may be necessary to remove or modify factors predisposing to plaque accumulation and retention. This includes scaling and



polishing of teeth to remove supragingival plaque and calculus and easily accessible subgingival deposits and the correction of faulty fixed or removable restorations.

### Therapy phase – mechanical

The therapy of chronic periodontitis is almost totally based on non-surgical and surgical mechanical debridement of the root surface. Indeed, the treatment of rapid-onset periodontal diseases with few exceptions always includes these mechanical methods.

Non-surgical and, more particularly, surgical procedures result in variable often unpredictable gingival recession. The choice of procedure must be made on the full understanding by the patient on the possible outcomes including the possibility of dentine hypersensitivity (see gingivectomy).

*Non-surgical* root surface debridement/scaling/planing techniques are the first line of treatment for all forms of periodontitis with the expectation of reductions in inflammation and probing depth, gains in attachment level and beneficial shifts in the subgingival bacteria. Procedures can be performed with hand instruments or ultrasonic scaling devices. Ultrasonic devices appear particularly efficient but lack tactile feedback and may be usefully combined with manual instrumentation. Local analgesia may be used as necessary, based on patient wishes and comfort.

*Surgical techniques* are used primarily to improve access and facilitate removal of subgingival deposits. In the uncomplicated treatment of periodontitis, flap procedures aimed at minimising loss of tissue should be the first choice. Where infrabony defects or furcations are present, surgical flap procedures can also be used to facilitate the insertion of bone infill materials. Gingivectomy eliminates pockets at the expense of gingival tissue and this can create aesthetic problems.

Flap and gingivectomy procedures may be used as part of the restorative therapy, for example crown lengthening.

### Guided tissue regeneration

The ultimate goal of periodontal treatment is to restore lost connective tissue attachment. The healing process following either surgical or non-surgical treatment involves the formation of a long junctional epithelial attachment along the root surface with-

out regeneration of the periodontal tissues. *Guided tissue regeneration* at present is the most promising method for restoring periodontal structures. The aims of this treatment are firstly to prevent apical migration of the epithelial attachment during the initial stages of healing and secondly to create a potential space under the surgical flap so as to facilitate regeneration of periodontal ligament along the root surface.

This space can be created by inserting an exclusionary barrier membrane under the flap and covering the root surface and adjacent bone. Various materials have been developed which may be resorbable or non-resorbable. Initially, most of the clinical evaluation was concerned with a non-resorbable expanded polytetrafluoroethylene (e-PTFE) material. Clinically impressive results, in terms of pocket depth reduction, gain in attachment and bone fill have been noted in Grade II furcation lesions and various infrabony defects, with less impressive results in Grade III furcations in maxillary molars.

More recently developed resorbable membranes have the advantage of not requiring a second operation for removal. These materials are based on lactide/glycolide copolymers or collagen. Studies have found the copolymers as effective as e-PTFE membranes in attachment gain and reduction in pocket depth. Bovine and human Type I collagen membrane sponges have been used in guided tissue regeneration with good results, but there have been no direct comparisons with other materials.

Other approaches to regeneration of lost periodontal ligament have included the use of growth factors and an enamel matrix derivative, which do not involve the use of a barrier membrane. These materials are simply coated onto the exposed root surface prior to suturing of the replaced surgical flap. At present it is too early to ascertain the long-term benefits of these biologically active materials, although initial studies appear promising.

### Therapy phase – chemoprevention and chemotherapy

Since periodontitis is associated with bacteria antimicrobial agents may be used as part of treatment. These may have a primarily preventive role or a primarily therapeutic role, and can be delivered locally or systemically.

Chemoprevention is usually directed against the potential adverse effects of plaque organisms locally

or systemically. Chlorhexidine mouthrinses, irrigation and sprays are the usual forms of local treatment. Indications for their use include:

- Reduction of contamination of the operator with oral organisms
- Reduction of bacteraemia in the at-risk individual as an adjunct to systemic antimicrobial prophylaxis (see Chapter 4)
- Control of supragingival plaque when mechanical cleaning may be compromised

Chemotherapy, either local or systemic, is usually used as an adjunct to mechanical surgical or non-surgical techniques.

*Local delivery* of antimicrobials subgingivally may be achieved by:

- Irrigation
- Slow release devices

This area of local delivery has been extensively reviewed and currently it is considered that local chemotherapy should not be used routinely. It is indicated where sites have not responded to mechanical debridement techniques. Irrigation with either a single agent or a variety has not been convincingly proven adjunctive to root planning.

The potential side effects of the development of bacterial resistance and overgrowth of opportunist organisms must also be considered.

Some antimicrobials in slow release devices have been shown adjunctive to scaling and root planning as measured by a reduction in pocketing and/or gains in attachment levels. These include tetracycline, minocycline, doxycycline and metronidazole. The value of chlorhexidine in slow release vehicles is still debated.

*Systemic delivery* is usually by the oral route and currently systemic antimicrobials have little or no place in the management of chronic periodontitis. They may be considered in the management of aggressive and refractory periodontitis. The use of systemic antimicrobials in individuals whose periodontal state is compromised by a medical condition, e.g. diabetes, while logical, is unproven. It would seem reasonable to delay the decision to determine if such an individual is refractory to conventional therapy.

Systemic antimicrobials that have attracted most research interest are metronidazole, tetracyclines and the combination of metronidazole and amoxycillin.

The decision to use systemic antimicrobials must be balanced against possible side effects, namely:

- Hypersensitivity (allergic) reaction
- Development of bacterial resistance
- Superinfection by opportunist organisms
- Toxic side effects of the particular antimicrobial
- Drug interaction with concomitant chemotherapy

### Mucogingival (perioplastic) surgical techniques

These have evolved over a number of years. They have been designed to:

- Remove fraenal attachments
- Deepen sulci
- Augment the width of attached gingivae
- Recontour gingiva and or replace missing papillae
- Cover exposed root surfaces (recession)

It is now appreciated that neither the mucogingival problem nor the treatment outcome to rectify the anomaly have any bearing on the prevention of recurrence or treatment of periodontitis. Mucogingival techniques, therefore, rarely feature in the treatment of the disease. Clearly, these procedures may provide aesthetic and/or functional benefits and are usually reserved for such indications. Examples include the coronally repositioned flap procedure to cover buccal recession and surgical crown lengthening to expose sound tooth structure.

### Maintenance phase

It has been established that whatever the outcome of treatment, long-term success is dependent on supragingival plaque control that is improved by the combination of clinical and personal hygiene programmes. Periodontitis is a chronic condition in which susceptibility does not change and therefore recurrence is always a possibility. There is therefore a need for recall, reassessment and re-motivation of patients. When necessary, clinical prophylaxis should be given. The timing of recall appears arbitrary and should be based on patient needs rather than applying the same regime to each patient.

Patients who are unable to maintain a satisfactory level of oral hygiene or who are not followed up, tend to show relapse over time. Conversely, patients practising over-zealous tooth brushing may cause gingival recession and those who are subjected to frequent and

repeated scaling of teeth, particularly at shallow sites, show iatrogenic loss of attachment.

To summarise, care and maintenance are essential but should not be over prescribed. The value of long-

term chemical plaque control for the susceptible periodontal patient who has been treated is not established.

#### **Periodontal Therapy – Summary**

The main aspect of pre- and post-treatment management or preparation for the periodontal patient is the achievement and maintenance of satisfactory supragingival plaque control. This is dependent on clinical and personal involvement in a disease for which susceptibility cannot be altered by means available at present. For the foreseeable future, 'once a periodontal patient always a periodontal patient'.

# Chapter 14

## Principles of Occlusal Management

The functional anatomy of the occlusion was described in Chapter 8. This chapter discusses the clinical techniques associated with the occlusion, particularly the use of articulators.

### Occlusal Analysis

Whilst the examination of the occlusion is part of the examination of every patient, the term ‘occlusal analysis’ implies a more detailed examination and this will be aided by articulated models.

An occlusal analysis is necessary for:

- Planning fixed prosthodontics
- Designing removable partial dentures
- Diagnosing cases of occlusal dysfunction

### Clinical examination of the occlusion

The following intraoral aspects are of particular interest:

- Missing or malposed teeth
- Cuspal height and cuspal inclines
- Centric occlusion (CO) – intercuspatation
- Effects of tooth loss – tilting, drifting, overeruption
- Tooth surfaces – wear facets, irregular surface loss, attrition, erosion and abrasion
- Curves of Spee and Monson, overbite, overjet, incisal inclination
- Restorations/prostheses – accuracy of fit, occlusal form and function
- Centric relation (CR) and the retruded arc of closure, pre-centric prematurities
- Extent and direction of mandibular displacement from CR to CO
- Tooth guidance in lateral and protrusive excursions and interferences

The examination will be completed, if appropriate, by the examination of the:

- Temporomandibular joints
- Muscles of mastication

### Detailed examination

This may be done alongside an articulation to confirm it, or as a clinical procedure only. The exercise requires 8- $\mu$ m metal foil (*shimstock*) and artery forceps, 40- $\mu$ m smudge proof articulating paper, red and blue, with reverse action tweezers.

#### Centric occlusion

The shimstock is used to check the existence of stable, contacting cusp/fossa relationships. The patient should be asked to close until the teeth are just touching, since variable compression of the periodontal ligaments can bring uneven or open sites into contact. This point is of considerable importance when fitting restorations since clenching can create apparent evenness of contacts.

Shimstock is placed between each area of likely contact, the patient closes, and the foil will either be held or pull out (Fig. 14.1). This can be noted and checked against the articulation later.

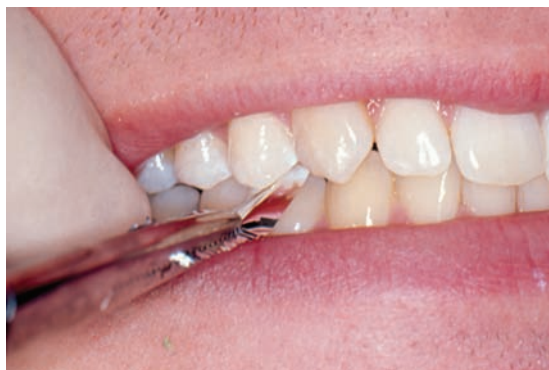Next, blue paper is used to mark CO contacts. The teeth should be dried and the patient asked to close the teeth together. A variety of markings are possible, from the classic tripod, to single fossa contacts (see Fig. 8.4).

#### Centric relation

Red paper is now used to mark the retruded contact position (RCP) and mandibular slide from CR to CO. The patient is manipulated onto the terminal hinge axis and closed into the RCP (Fig. 14.2). Then he closes of his own volition into CO.

This procedure will lead to:

- Double marking of centric stops, i.e. red superimposed on blue
- Red alone marking the RCP and slide(s) (see Fig. 8.5b)



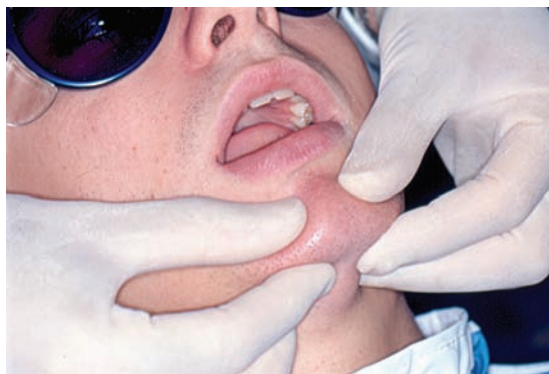**Fig. 14.1** Shimstock being used to check the centric contact between the upper and lower first premolars.

### **Lateral and protrusive excursions**

Examination of lateral and protrusive excursions should demonstrate either canine guidance or group function, and the length and height of the anterior guidance. This last characteristic is shown by the amount of posterior disclusion.

The most important aspect of the eccentric excursions is to look for interferences, i.e. tooth contacts that are interrupting smooth and even sliding contacts. These contacts may cause deviations in side-shift or protrusion. In group function, all buccal cusps on the working side should be in contact. If during the excursion, a pair of upper and lower cusps 'lift' the other cusps out of contact, this pair of cusps constitutes a *working side interference*.

Tooth contacts on the non-working side may interfere with condylar guidance and side-shift; these are *non-working interferences* (see Fig. 8.6d).



**Fig. 14.2** Manipulation onto the retruded arc of closure. The operator's fingers and thumbs exert upward and backward pressure to locate the condyles into their most superior, posterior position and 'rotate' the mandible.

### **Temporomandibular joints**

These may be examined for movement and clicks by palpation with the fingers overlying the joints or in the external auditory meatus. In addition, a stethoscope may be used to listen to joint sounds.

Clicking in the joint may not be revealed by simple movement of the mandible, since the disc position may change when food is between the teeth. It can be useful to ask the patient to chew on some hard wax and listen during the series of functional movements.

### **Muscles of mastication**

Extra-oral palpation of the temporalis origins overlying the parietal bones and the whole lateral aspect of the masseters is straightforward. Bi-manual palpation of the masseter is more reliable with one digit within the mouth and one external. This same method can be used for the mylohyoid and digastric.

Intraoral palpation of the medial pterygoid requires a finger to be placed in the fauces area and this can be unpleasant. The most difficult muscle to palpate is the lateral pterygoid. The first finger is placed around the posterior aspect of the tuberosity and upwards to the lateral aspect of the lateral pterygoid plate of the sphenoid bone. This is uncomfortable also.

The discomfort induced by palpation may persuade the patient to report tenderness which of course is misleading. The muscles that can be palpated with reliable results are the temporalis and masseters.

## **Articulation of Study Models**

### **Equipment**

The equipment available for reproducing the occlusion in the laboratory, for either the detailed examination of the occlusion or the construction of restorations, ranges from the primitive to the esoteric, from bare hands to microcomputers!

The overriding consideration in the choice of equipment is to use that which is appropriate to the job in hand, and that both the dentist and his technician really know and understand the principles of the instruments they use. A badly used articulator is often much, much worse than using no articulator at all.

Incorrect articulation will lead to restorations that will require considerable chairside time for fitting

whilst the occlusal surfaces are modified to suit the actual occlusion.

The very simple articulators, the average path and simple plane line, are too small to reproduce the relationship between the temporomandibular joint and the occlusal plane. For this reason they do not locate any hinge axis from the patient and may introduce errors if tooth apart occlusal records are used. The incisor angulation may be incorrect because of the free-hand orientation of the models and this may affect management of aesthetics. These instruments are little more than a convenient way of locating two models in a fixed position.

At the other end of the scale, the computerised, *fully adjustable articulator* will provide the nearest equivalent to the patient, with curved condylar guides, immediate and progressive side-shifts, exact intercondylar width and an exact reproduction of the hinge axis.

The most practical type of instrument is a *semi-adjustable articulator* and its associated *facebow*. There are several excellent types available and the choice depends to a large extent on personal preference. This book shows cases mounted on the Dentatus ARH and the Denar Mk IIA. The first is a good instrument for teaching the basic principles of occlusion and the latter is a light, simple instrument that is more suitable for fixed prosthodontics.

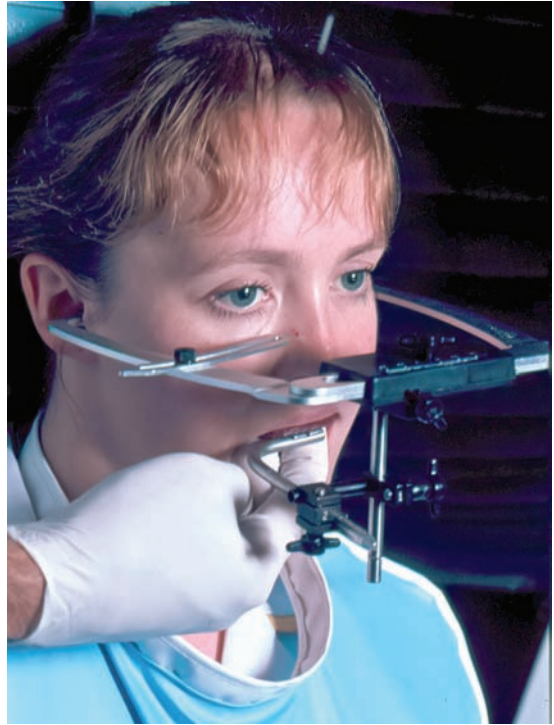In order to illustrate the design of facebows and articulators, the Denar Mk IIA and its associated Slidematic facebow will be described in detail.

### Facebow

The purpose of the facebow is to locate the maxillary teeth in three planes (superior–inferior, anterior–posterior and lateral) to the temporomandibular joint. Ideally, the articulator's hinge should be the terminal or *true hinge axis* of the joint. However, two pieces of equipment, a *hinge axis locator*, together with a *hinge axis transfer facebow* are required to do this accurately.

For simplicity of use, most facebows work in connection with an *arbitrary hinge axis*. A number of workers have determined the position of the true hinge axis for a group of subjects and correlated it with a surface anatomical landmark. Each worker has then derived an average position in order to dispense with true hinge axis location. These positions are usually claimed to be within 5 mm of the true hinge axis on all patients.

The most commonly used arbitrary hinge axis is a point 12 mm anterior to the posterior border of the



**Fig. 14.3** The Denar Slidematic earbow in place. The bow is self-centring and locates to the side of the nose for its vertical reference point. The registration fork is stabilised by the operator.

tragus along a line drawn from the superior border of the tragus to the outer canthus of the eye. This position would be transferred by a facebow to the condylar axis of the articulator.

However, it is easier to use an earbow that locates into the external auditory meatus, with the articulator having an earbow mounting site that is posterior to the articulator hinge. (Remember that the ear is posterior to the TMJ!) Alternatively, the design of the articulator and its mounting system takes account of this anatomy.

The Denar Slidematic facebow (Fig. 14.3) is a self-centring earbow that can also measure the intercondylar distance. The bow is located in the vertical plane by an arbitrary point on the side of the nose, 43 mm from the upper lateral incisor edge.

The registration fork should locate the upper model accurately but without engaging tooth undercut to avoid distortion of the wax. Three layers of base plate wax, softened and firmly sealed to the metal are sufficient, and a ZOE wash can be added for extra accuracy if required.

In taking the record, ensure that:

- 1 The ear lugs are firmly engaged on bone
- 2 The reference plane locator points to the nose point
- 3 The registration fork is accurately and evenly located on all the teeth and stabilised by the clinician during recording
- 4 All screws etc. are tightened firmly to avoid slippage during mounting

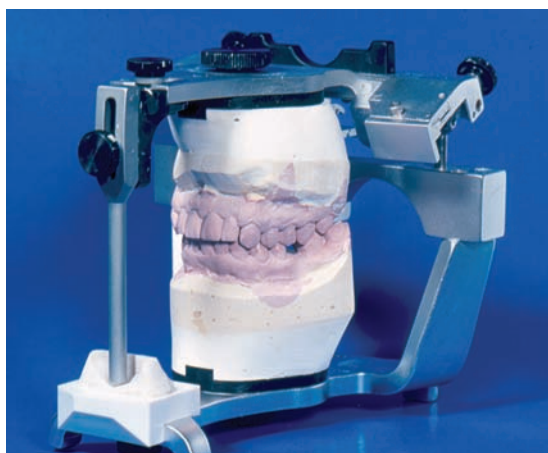The record is assembled on the articulator by means of an index system that avoids the need to send the whole earbow to the laboratory. It is useful to have the articulator at the chairside to check the earbow settings and discover spurious recordings whilst the patient is still available.

### Articulator

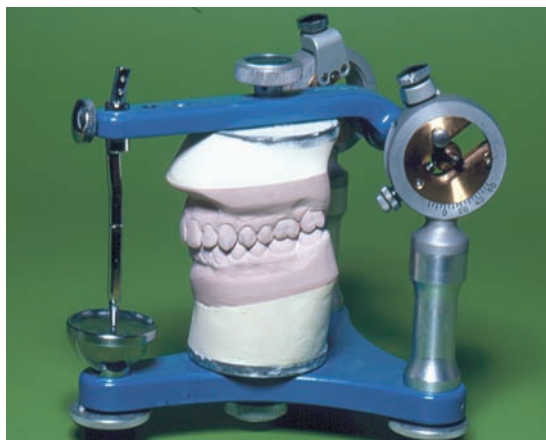The Denar Mk IIA (Fig. 14.4) is a simple, light 'Arcon'-type semi-adjustable articulator. The 'Arcon' classification (short for ARticulator-CONdyle) describes the fact that the condyles are attached to the lower member in comparison with the Dentatus ARH that is 'non-Arcon' having the condyles on the upper member (Fig. 14.5).

The Arcon design is more realistic anatomically, since in protrusion the condyles move forward with the mandible. In the non-Arcon, the condyles move backwards in protrusion. Some minor technical advantages are also claimed for the Arcon type.

The Denar can be set to vary the condylar angles, the progressive side-shift and the immediate side-shift.



**Fig. 14.4** The Denar MkIIA articulator. This is a light Arcon instrument, with adjustable condylar angles, progressive side-shift and immediate side-shift. The intercondylar distance is fixed.



**Fig. 14.5** The Dentatus ARH articulator. This is a non-Arcon instrument, with adjustable condylar angles and progressive side-shift. It has no provision for immediate side-shift.

The antero-posterior position of the condyles can be adjusted to provide separate identifiable positions for centric relation and CO. It has a fixed intercondylar distance. The incisal guide can be 'customised' to the anterior guidance (see later).

### Occlusal records

There are three types of static occlusal records, each for a different purpose. In addition, dynamic records can be used for certain articulators.

#### Centric relation record

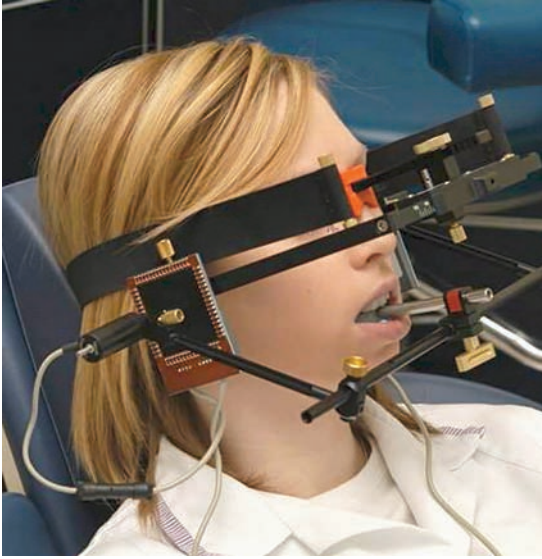This is a tooth-apart record, taken with the patient on the retruded arc of closure. It is used to carry out a pre-operative occlusal analysis where problems have been diagnosed with the existing CO. Alternatively it may be used for the construction of restorations when CO is lost, as in complete dentures.

#### Centric occlusion record

This is a tooth-together record of the position of maximum intercuspation. This position would be used for mounting pre-operative and master models when no change to the existing CO is proposed.

#### Lateral and protrusive check records

These are used to set the articulator condylar angles and the instruction manual of the articulator will specify those required for a particular instrument.



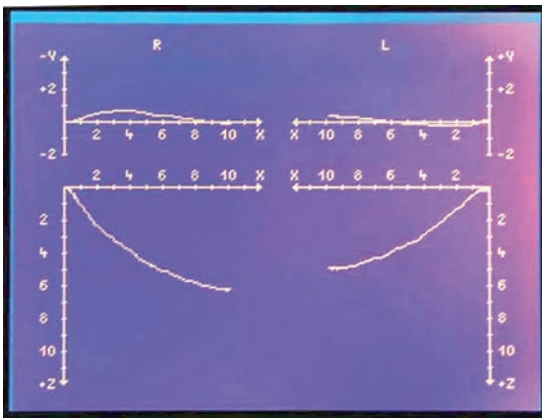
**Fig. 14.6** A kinematic facebow in use. Two styli are attached to the mandible and two sensor pads are fixed to the head alongside the area of the temporomandibular joints.

### Dynamic records

A detailed description of these is outside the scope of this book. Basically, these are usually tracings or micro-computer signals from specialised kinematic facebow systems (Figs. 14.6 and 14.7).

They can be used to:

- Assess the amount of immediate and progressive side-shift



**Fig. 14.7** The output from the facebow. The lower traces are the condylar paths and the upper traces are the lateral bodily movements. Settings for the articulator are computed from the traces.

- Assess the condylar inclination
- Trace the condylar path shape
- Trace the incisal guide
- Trace the chewing cycle
- Assess muscle activity and functional disturbances

### Recording media

The essential requirements are that the recording medium should:

- Not interfere with the path of closure of the mandible
- Record sufficient detail to permit accurate orientation of the models
- Be sufficiently rigid to stabilise the models during mounting on the articulator

The commonly used wax squash bite has the major disadvantage of interfering with the path of closure and also obscures the tooth position that is being recorded. Softer materials, such as alginate and impression rubbers, have been used to overcome this problem, but they give imprecise mounting positions for the models during articulation.

The best way of orientating the models for a *centric occlusion articulation* is to avoid the use of an interdental record altogether and place them into the position of 'best fit'. This position can be checked against the patient and marked on the models.

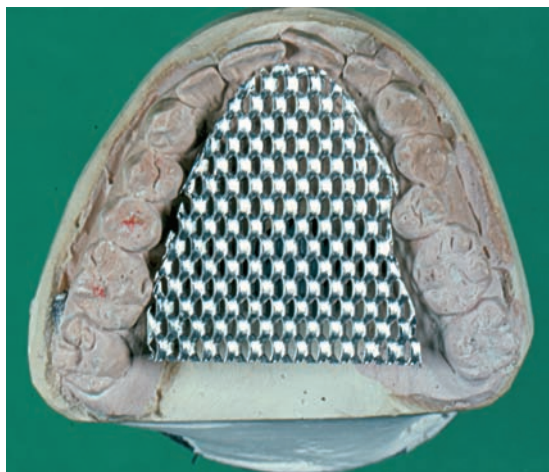
However, if CO is not reproducible by a position of best fit, a registration will be required. Islands of acrylic or a silicone registration polymer fulfil the requirements listed above. It is important not to use a 'horseshoe' of material as this interferes with seeing the teeth in contact. Figure 14.8 shows red acrylic islands on the teeth after registering CO.

There are several techniques for registering *centric relation*. The technique described here offers rigidity and the minimum interference with closure.



**Fig. 14.8** Registration of centric occlusion using acrylic islands.

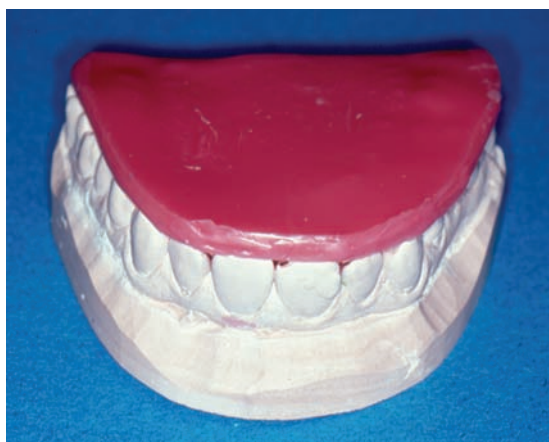



**Fig. 14.9** Occlusal record for centric relation. Aluminium mesh is cut to fit exactly to the palatal surfaces of the upper teeth. The mesh supports the wax wafer and prevents distortion.

The starting point is accurate study models, taken in an elastomer and cast with die stone occlusal surfaces.

The record consists of two thicknesses of very hard baseplate wax supporting by a metal mesh. The mesh is cut to fit exactly to the palatal surfaces of the upper teeth (Fig. 14.9) and the wax is trimmed to the buccal surfaces (Fig. 14.10). This ensures good vision of the tooth relationships.



**Fig. 14.10** Two thicknesses of hard wax have been added to sandwich the mesh. The wax is trimmed to the buccal surfaces so that the occlusal relationship can be seen during the registration.

Bi-manual manipulation of the mandible onto the terminal hinge axis or retruded arc of closure is now performed. The patient is asked to half open the mouth and relax. The operator's fingers and thumbs exert upwards and backwards pressure on the mandible to locate the condyles into the posterior, superior position in glenoid fossae (Fig. 14.2).

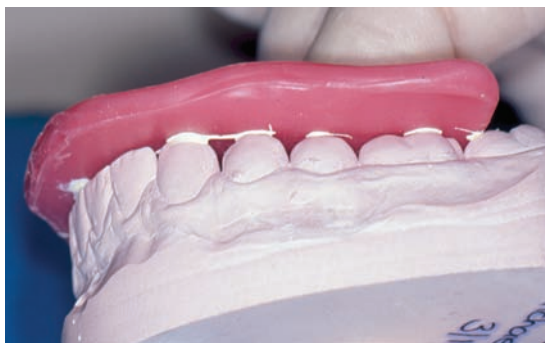The wax wafer is softened in hot water and placed on the upper arch and the mandible manipulated on the hinge axis so that the lower teeth indent the wax very lightly. The wafer is removed and chilled in cold water. This first stage creates a matrix to support the actual recording medium.

The detail of the tooth relationships can now be recorded using a zinc oxide–eugenol wash. The wash is 'dotted' into the tooth indents on both surfaces of the wax with just enough used to record the cusp tips only. Any more may record occlusal surface detail not included on the models and therefore prevent seating of the record.

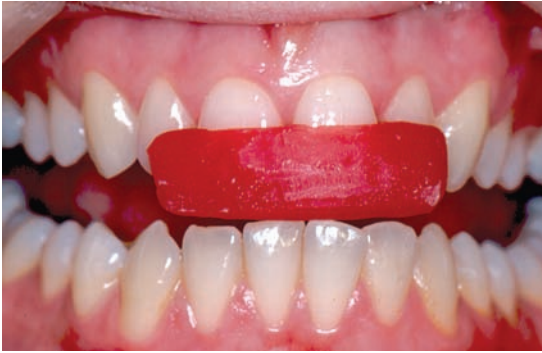The wafer is replaced in the mouth and the mandible manipulated again onto the terminal hinge axis and onto the record.

After the ZOE has set, the record is removed and carefully placed on each model in turn to check for accurate seating (Fig. 14.11). This checks the accuracy of both the record and the models.

To confirm the reproducibility of the record, two further wafers can be taken and the mounting done by a *split cast technique*. Here, the upper model is grooved and a separating medium applied. It is mounted to the facebow in the usual way, and the lower model plastered to the first record. When the plaster has set, the record is removed and the upper model separated from its mounting plaster leaving the



**Fig. 14.11** The completed record has the cusp tips reproduced in ZOE and should fit each model accurately.



**Fig. 14.12** An occlusal deprogrammer. This removes the memory of centric occlusion and, after removal, manipulation onto the retruded arc of closure should be easier.

locating points. The other two records are then used to orientate the upper model onto the mounted lower model and the articulator closed. If the records are identical, then the location grooves and points will meet exactly. Two matching out of three is an acceptable reproduction, given the difficulty that may be experienced in manipulating the mandible.

In the case of patients whose musculature resists the manipulation, a 'deprogrammer' may be needed to remove the short-term memory of CO. The appliance is made at the chairside from cold cure acrylic and forms a flat bite plane on the incisal edges (Fig. 14.12). The record is re-attempted after about 10 minutes, with the deprogrammer out.

The same wax wafer arrangement may be used for lateral and protrusive records for articulator settings in accordance with the manufacturer's directions.

### Confirmation of articulated mounting

The articulation should be compared with the patient. This will involve the use of articulating paper and shimstock and general observation of the tooth relationships created by articulator movements.

When the pre-centric record is removed, the articulator should reproduce the retruded arc of closure, with the RCP and then close into CO via sliding from the prematurities (Fig. 14.13). In CO, shimstock should be retained by centric stops on the articulator as it is in the mouth (Fig. 14.14). Wear facets should be observed in particular, to see that these approximate to each other on the models as they do clinically.

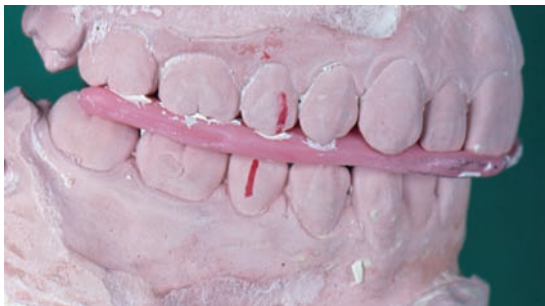Comparison of the articulating paper markings made clinically in CO, RCP and in eccentric excursions with those on the articulator should show good agreement. The adjustment of the antero-posterior position of the articulator condyles facilitates the closure directly into CO if a centric relation mounting has been done.

### Errors in articulation

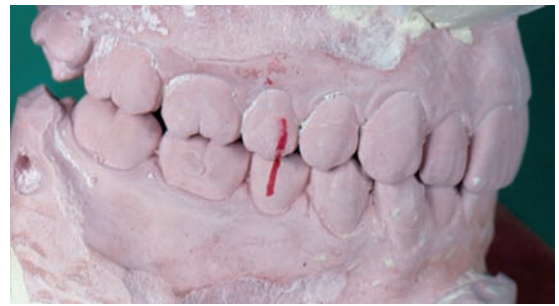These can occur as a result of the compromises made in articulator design and particularly as a result of using an arbitrary hinge axis. It may be possible to compensate for some errors by adjusting the condylar assemblies to bring appropriate teeth into contact, but gross inaccuracies will require remounting to a new occlusal record.

Possible sources of error in articulation are:

- Distortion of the impression
- Air blows on the occlusal surface
- Slippage of the facebow
- Use of the arbitrary hinge axis
- Expansion of the mounting plaster

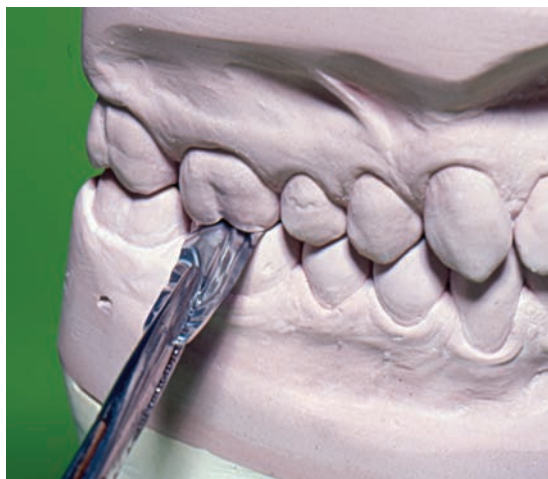

(a)



(b)

**Fig. 14.13** (a) Articulated models with pre-centric record in place. (b) The record has been removed and the articulator closed. There has been an upward and forward movement, as shown by the marks on the premolars, to reach centric occlusion.



**Fig. 14.14** The centric occlusion contacts on an articulator being checked with shimstock.

- Incorrect occlusal record
- Articulator design compromises
- Compression of the periodontium not reproduced
- Incorrect angles set

## Restoration of the Occlusion

### Conformative and re-organised approaches

As was discussed in Chapter 8, each individual adapts successfully to his occlusal irregularities, and will usually continue to adapt as teeth are lost or restored. However, there must clearly be a limit to the capacity of this adaptation and so the golden rule of occlusal restoration is not to create further problems.

This principle is enshrined in the '*conformative approach*' to occlusal restoration. Where CO and its associated lateral and protrusive movements are functioning satisfactorily, then no procedure must change this. No doctrinaire philosophies of the rights or wrongs of a particular occlusion should intrude on treatment. Each new restoration should blend harmoniously with the functional pattern already present, provided that is satisfactory.

The converse of this is the '*reorganised approach*'. Here changes are made to the existing occlusion following a diagnosis that there is some major occlusal problem present or, of course, when there is no CO.

An example of when the reorganised approach would be appropriate is the replacement of restorative

work that introduces occlusal interferences and/or deviations on mandibular closure that the patient has noticed, usually as discomfort. This type of case requires an articulation in centric relation to make the initial diagnosis followed by careful planning of the new occlusion using diagnostic waxing to develop appropriate tooth relationships.

### Occlusal stability

The maintenance of a stable CO position is important for occlusal harmony. This may be influenced by restorative work and the behaviour of materials.

### Intracoronal restorations

The natural cusp/fossa relationship, especially one that is based on tripods, is very difficult to reproduce by freehand carving. The result of inaccurate contacts, or no contacts at all, will be tooth movement to seek a stable position (Fig. 14.15).

In moderate to large restorations, the natural fossa should be replaced by a flat plateau (Fig. 14.16), which receives the supporting cusp of the opposing tooth. This provides good stability and also directs the occlusal loads axially. It is also easier to carve and adjust in comparison with anatomically shaped fossae.

However, the best restoration from the occlusal viewpoint is the small one. Absolutely minimal cutting of the occlusal surface will allow the occlusion to be maintained by enamel in its original state (see Figs. 10.7 and 10.8).

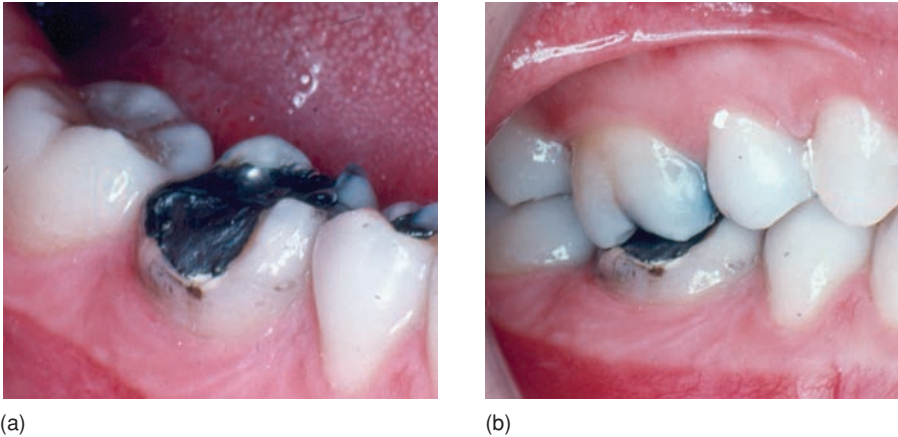
### Choice of materials

The choice of materials to restore occlusal surfaces is equally important. No wholly satisfactory material exists; all direct restorative materials deform under load (creep) or undergo surface loss (see Chapter 9) and, of the indirect materials, ceramic is the most difficult to use efficiently. Table 14.1 summarises factors that influence the choice between cast metal and ceramic for the restoration of occlusal surfaces in fixed prosthodontics.

The relationship of preparations to pulpal and tooth size will be discussed in Chapter 15.

A low anterior guidance leads to very little posterior disclusion in protrusion and lateral excursions and therefore the occlusal clearance required to accommodate ceramic may result in a very short preparation. A larger posterior disclusion will permit ceramic coverage.

The average technician is usually skilled in handling wax and will be able to make a functional surface in

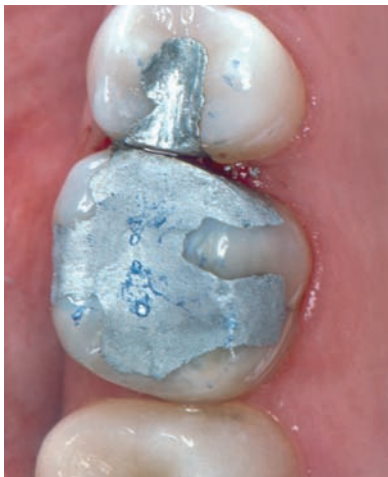

**Fig. 14.15** Occlusal stability. (a) Poorly carved amalgam restoration without buccal supporting cusps, (b) overeruption of the upper molar is the consequence. To correct this, the upper occlusal plane must be realigned by adjusting the displaced molar, or crowning it, followed by a veneer crown on the lower to restore the occlusion and maintain the new position.

metal very adequately. However, when firing ceramic it is much more difficult to achieve accurate contacts.

Perhaps the most important veto is provided by the last factor on the table. Marking, adjustment and repolishing of metal is much less time consuming clinically than the procedure for ceramic, which should include reglazing.

Unless aesthetics are of overriding importance, the better material for occlusal surfaces is cast metal (Fig. 14.17). For anterior crowns, two-thirds of the guidance should be in metal, allowing translucency at the incisal tips (Fig. 14.18).



**Fig. 14.16** Amalgam restoration with flat plateaux centric stops to provide accurate occlusal stability.

### Bridgework

It is essential that bridgework replaces all the functional contacts in CO. It used to be suggested that loads on the abutment teeth could be reduced by narrowing the occlusal table of the pontics. This is questionable, but more importantly such a pontic may not have correct centric contacts.

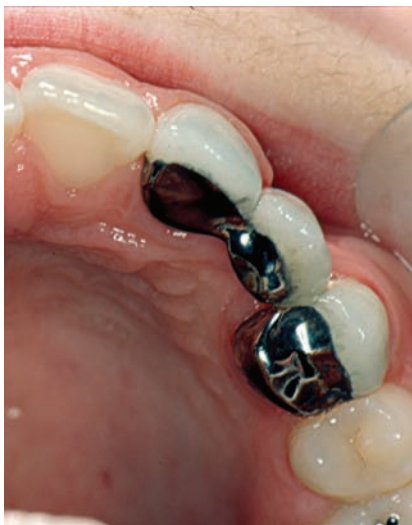Figure 14.19 shows a case where occlusal contacts were not provided, leading to considerable problems.

The patient was a 45-year-old man, who was complaining that the gap between the lower left lateral incisor and the canine was opening progressively (Fig. 14.19a). This, in fact was caused by overeruption of the canine, and the bridge pontic opposing this tooth (Fig. 14.19b) had no centric stop.

Orthodontic therapy was provided to realign the canine (Fig. 14.19c), and the upper bridge was remade with a positive fossa relationship with the repositioned tooth (Fig. 14.19d). This course of treatment took almost 2 years.

**Table 14.1** Factors involved in the selection of materials for occlusal surfaces

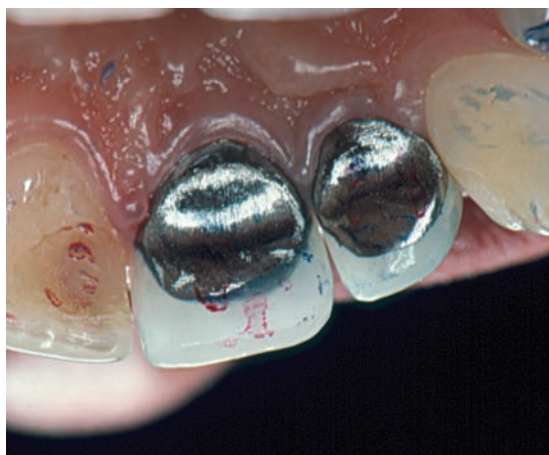Metal	Ceramic
Large pulps	Small pulps
Small teeth	Large teeth
Low anterior guidance	High anterior guidance
Average technical support	Excellent technical support
Simple clinical adjustment	Difficult clinical adjustment



**Fig. 14.17** Upper arch bridgework, with most of the functional surfaces reproduced in metal.

### Anterior guidance

The functional contours of upper anterior teeth are particularly important, and when making crowns or bridges for that region, the articulator must be 'customised' to reproduce conformative movement pathways. This is done at the diagnostic mounting stage and either an adjustable incisal guide can be set to the appropriate angles or, for better accuracy, a customised incisal table can be made (Fig. 14.20).



**Fig. 14.18** Two anterior crowns with two-thirds of the incisal guidance reproduced in metal. The incisal tips need translucency for aesthetics.

Cold curing acrylic is added to the incisal table, and whilst it is soft, the articulator is moved through the functional pathways dictated by the teeth. When hard, the articulator will reproduce these movements when, say, a series of crowns is being constructed.

A change in the anterior guidance may be indicated when a key functional tooth is being replaced.

This problem tends to be centred on the canine. If this tooth is lost in a canine-guided occlusion, then consideration must be given to changing the occlusal scheme to group function, so that the prosthetic replacement, whether bridge pontic or denture tooth, is not subjected to unfavourable forces. Figure 14.21 shows a bridge replacing a canine, in lateral excursion. The pontic receives all the lateral load and transmits rotational forces to the premolar. This latter tooth was mobile and painful. The bridge required replacement and a change in the functional pattern to group function so that the lateral forces could be shared with other posterior teeth.

### Occlusal Equilibration

#### Indications

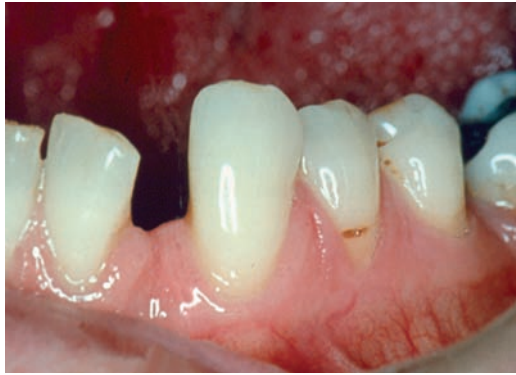
This procedure, sometimes referred to as 'selective grinding', involves the recontouring of tooth surfaces so that the occlusion conforms to certain norms. The indications are contentious and there is much disagreement on whether the procedure should be performed at all.

Various workers have proposed occlusal equilibration:

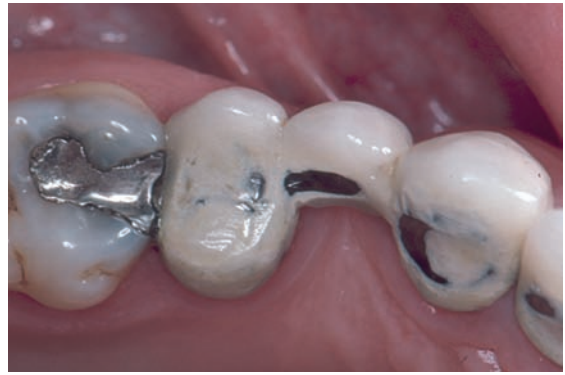
- To establish occlusal harmony as a preventive measure
- To treat temporomandibular dysfunction
- As part of periodontal therapy
- As pre-operative mouth preparation for crown and bridge work
- Following oral surgery

The doctrine 'equilibration for all' is not indicated by the available evidence that suggests that almost all people have occlusal interferences but only a small proportion are suffering from an occlusal related disorder (see Chapter 28). The use of equilibration for an established disorder is also considered later.

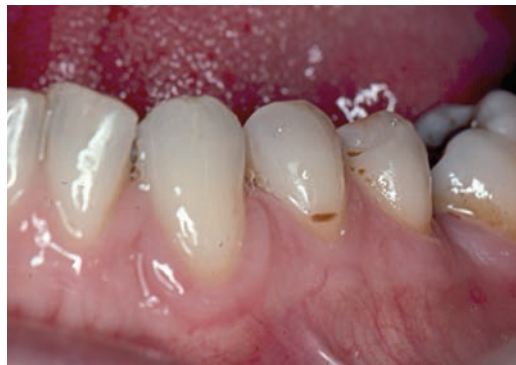The occlusal imbalance as a primary aetiological agent in periodontal disease is currently discredited.



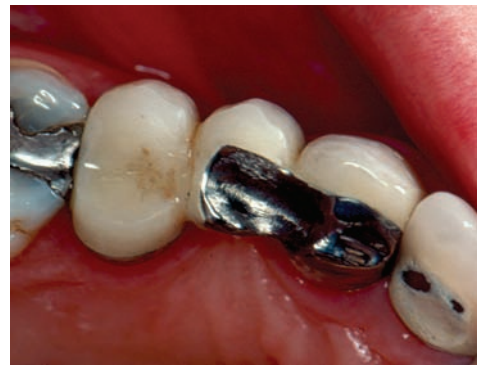(a)



(b)

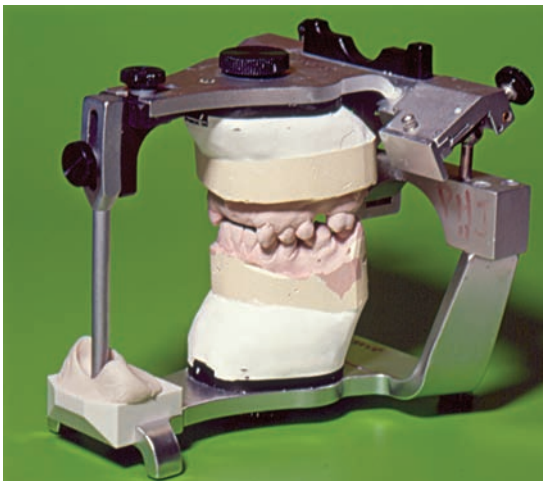


(c)

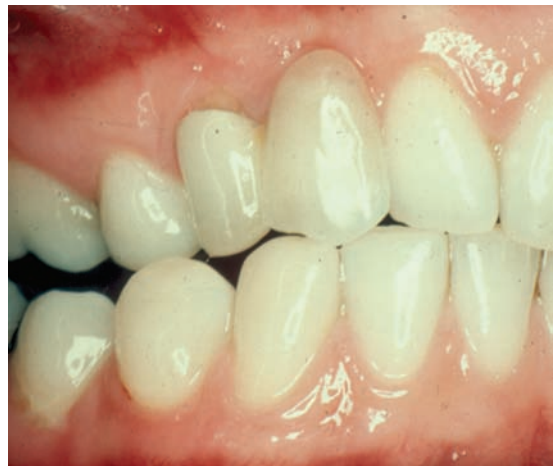

(d)

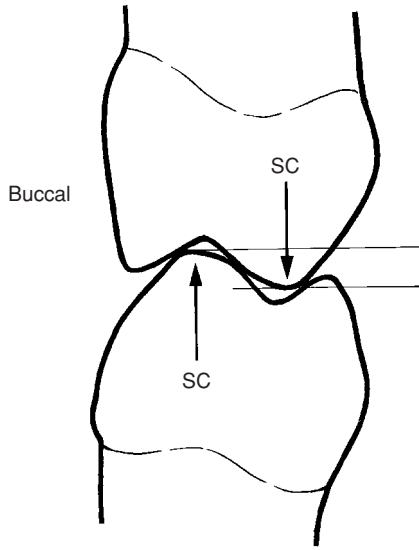
**Fig. 14.19** Loss of occlusal stability. The lower canine has overerupted (a) because there is no centric stop on the upper bridge pontic (b). The tooth was realigned orthodontically (c), and a new bridge made with a positive centric stop (d).



**Fig. 14.20** Customised incisal guidance table on a Denar Mk IIA.



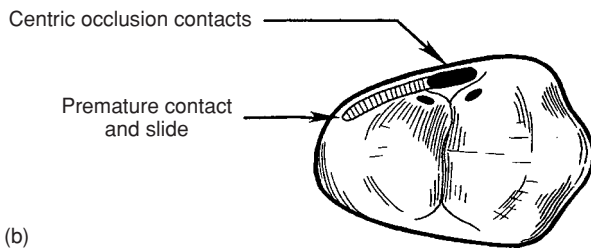
**Fig. 14.21** Cantilever bridge replacing 3 retained by 4 only. In lateral excursion, the occlusion is canine guided, and the pontic transmitted rotational forces to the premolar. The occlusal scheme should have been changed to group function to balance the forces on the bridge and the second premolar should have been included in the design.



(a)

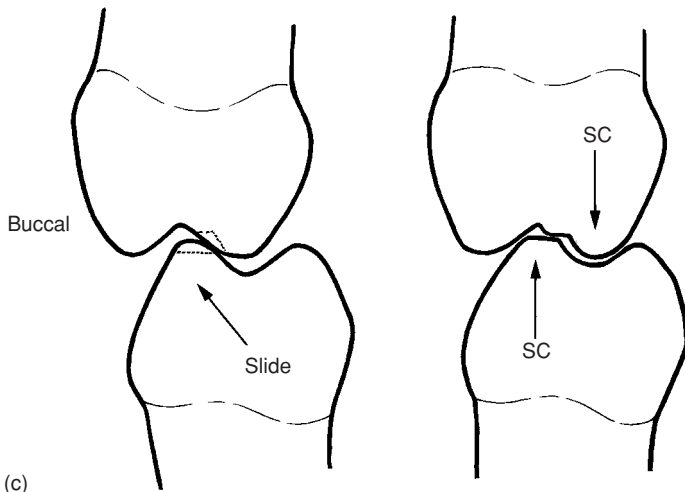
**Fig. 14.22** Principles of occlusal equilibration, assuming a correct and stable centric occlusion.

(a) Centric occlusion. The contacts between the pairs of centric stops and supporting cusps must be maintained for occlusal stability,



(b)

(b) Pre-centric prematurity on an upper premolar. Hollow the mesial slope of the palatal cusp, but do not touch the contacts where the two articulating paper colours will be superimposed from centric occlusion,



(c)

(c) Lateral slide from a pre-centric prematurity between the palatal cusp of the upper molar and the buccal cusp of the lower molar. The mandible moves to the right after this contact, into centric occlusion. Widen the fossa on the upper, but keep its contact level the same. Reduce the tip of the buccal cusp of the lower, maintaining the same buccal inclined plane contact, and creating a new plateau contact for stability to the palatal aspect,

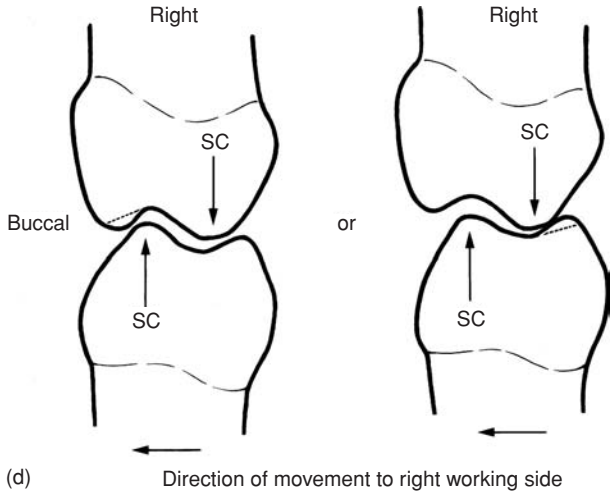
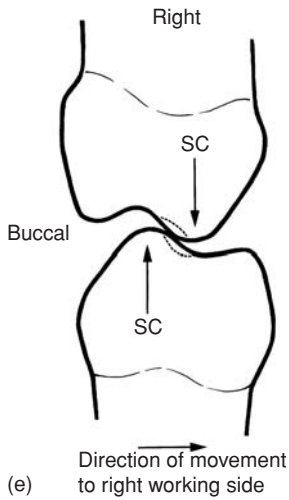
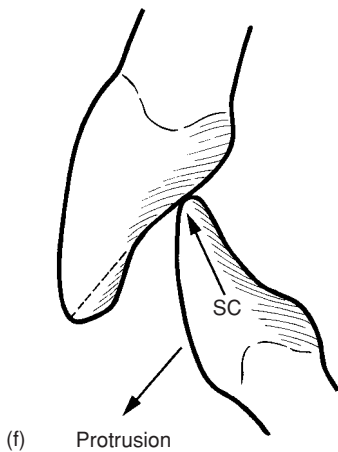


Fig. 14.22 (Continued)

(d) Working side interferences: grind non-supporting cusps, i.e. buccal upper, lingual lower, depending on the excursion. The interferences shown will tend to occur only in group function, since canine guidance tends to disclude all the posterior teeth. The adjustment will balance the excursion,



(e) Non-working interferences. Hollow the cusp slopes of interfering inclines, without removing cusp tips,



(f) Protrusive interference. Ideally, the lower incisors should have an even path and contacts with the uppers. The diagram shows the adjustment required if the lower incisor has an isolated path, discluding the others. The lower incisor tip must not be reduced – it would then be out of contact in centric, and would overerupt.



Work from Scandinavia has suggested that occlusal forces are regulated by a feedback mechanism that relates them to the amount of support available. There is evidence of secondary effects of occlusal irregularities once the primary lesion is established (see Chapter 7).

However, there is some evidence that limited equilibration is of value prior to crown and bridgework. The preparations will remove occlusal surface and in doing so may remove existing prematurities or interferences. This will change the tooth guidance and may also change the CO position. The practical result might be the loss of occlusal clearance when the restoration is tried in.

If the occlusal surface of the lower molar shown in Fig. 8.6d was reduced, then the condylar guidance would take over the progressive side-shift pathway and no crown could fit in between.

Finally, an excellent indication is following the reduction and healing of maxillofacial fractures or orthognathic surgery when there may be slight discrepancies in occlusal positions remaining.

### Technique

Equilibration must be approached with extreme care – the enamel cannot be put back! Further, the removal of apparently simple and localised prematurities can have the knock-on effect of creating more elsewhere.

Full mouth equilibration requires the application of an occlusal ‘philosophy’. There are essentially two:

- Freedom in centric
- CO coincident with centric relation

*Freedom in centric* has some sense attached to it, though little scientific support. The basic concept is to allow closure on multiple arcs of closure into a CO position that has a range of 1 mm or so both antero-posteriorly and bucco-lingually – a ‘long centric’.

The attainment of any position within long centric can then be achieved without the intrusion of premature contacts. The precise position of CO is therefore removed, but not occlusal stability. The neuromuscular control of mandibular closure therefore does not have to be so precise and therefore, it is argued, there will be less susceptibility to temporomandibular dysfunction.

In lateral movements, all teeth on the non-working side should be discluded, as should all palatal cusps on the working side. In protrusion, all the posterior teeth should disclude, and the lower anterior teeth should have even and balanced contact with the upper teeth.

The philosophy of CO being made coincident with CR involves the establishment of a precise position based on tripods. Much relies on which CR definition is applied; the posterior–superior position will be too far posterior for natural comfort and in contrast with freedom in centric, the mandibular positioning on closure will have to be very accurate. This approach seems to ignore the naturally occurring difference between the condylar positions in CO and CR.

The results of clinical studies of equilibration have been reported but many of these are retrospective and sometimes no more than anecdotal. There have been a few controlled studies and these are inconclusive.

In carrying out an equilibration to freedom in centric, the following rules should be applied:

- Do not reduce the height of any supporting cusps
- Fossae may be widened but must not be deepened
- Prematurities and interferences should be removed by hollowing cusp slopes
- Non-supporting cusps can be reduced in height to remove non-working interferences.

These rules are illustrated in the series of diagrams in Fig. 14.22.

### Occlusal Management – Summary

The overriding consideration is that most patients are able to tolerate many minor anatomical and technical ‘faults’ in tooth relationships and restorations. Dentists must avoid being dogmatic about occlusal theory and remember the old saw – ‘If it ain’t broke, don’t fix it!’

Restorations must be constructed to harmonise with and maintain existing tooth relationships where these are satisfactory.

Articulators are essential for the construction of fixed and removable prostheses and there is no substitute for hands-on training with this equipment.

Changes to an occlusion must be planned carefully with proper diagnostic procedures.

# Chapter 15

## Fixed Prosthodontics – Crowns

Intracoronar restorations will be generally satisfactory provided there is sufficient sound tooth tissue to support and retain them and to maintain the occlusion. On the other hand, weakened tooth tissue is vulnerable to fracture and should be protected. Further, large plastic restorations tend not to maintain the occlusion as well as cast metal or ceramic. These are the principal reasons for providing crowns.

### Treatment Planning

#### Indications for crowns

The indications for the provision of a crown are:

- Protection of weakened tooth tissue
- Maintenance of the occlusion
- Improving aesthetics

The potential disadvantages are:

- The need to remove further sound tooth tissue
- Plaque accumulation at the margins
- Risk of crown fracture or failure

The treatment of a large cavity in a posterior tooth, as discussed in Chapter 11, would in the first instance be restored by a pinned amalgam restoration. This might well give good service for some time, and it is certainly effective as a stabilisation measure. However, depending upon its size, there might be remaining enamel and dentine that has become undermined and therefore weakened and the amalgam might not maintain occlusal stability in the long term.

A large cavity in an anterior tooth might be restorable by a composite restoration but it is more likely that retention will be compromised by loss of tooth tissue and the aesthetics of a large composite might not be satisfactory.

It is likely that a better long-term result would be achieved in both of the cases described above if a crown was constructed.

Crowns may also be used to improve aesthetics and this is discussed in Chapter 16.

The decision to construct a crown depends not only on the individual tooth factors, as listed above, but on other general factors. These are:

- Patient motivation
- Oral hygiene status
- Periodontal condition
- The restorative state of the tooth
- The occlusion
- The provision of dentures

#### Patient motivation

As was stressed in Section I, patient motivation is essential, and any advanced operative work requires a commitment from both the patient and the dentist. The stabilisation phase of the treatment plan will give the dentist the opportunity to assess the patient's motivation, and indeed vice versa!

#### Oral hygiene and periodontal condition

As was discussed in Chapter 13, no matter how accurately made the crown, the junction between it and the tooth will promote plaque accumulation. If this extra plaque is superimposed on already established periodontal disease, this may make the condition worse. Ideally the periodontium should be stable and the patient's oral hygiene excellent.

#### Restorative state of the tooth

Examination of the tooth should ensure that the tooth is either vital or that adequate endodontic treatment has been carried out. A periapical assessment with radiographs must be made. If there is doubt about the prognosis of a tooth, it is better not to embark on a complex restoration until the doubt has been removed. Nothing is more frustrating or embarrassing to find the necessity for endodontics shortly after crown placement.

If the existing restoration has not been placed by the present dentist and is of dubious quality, it should be removed. This is really part of the management of the deep cavity since the dentine can be examined to ensure it is caries free and the periphery may be examined to ensure that there is an adequate base of sound tooth upon which to place a crown margin.

The remaining tooth can also be examined to decide on the techniques of core construction. An assessment of the tooth support likely to remain after crown preparation should be made so that weak undermined walls can be removed. This will influence the type and amount of additional retention to be provided for the core. It is usually best to plan for the worst and for the core to be well retained by an adequate number of pins. It is unwise to place too much reliance on a core that is retained principally by dentine adhesive.

The commonest reason for crown construction is the fracture of one or more cusps. The position of the fracture line may well determine not only the type of restoration but also the fate of the tooth as well. Subgingival fractures are difficult to treat since the deeper they are, the more inaccessible they are to instruments and impression materials. Gingival surgery is often necessary to expose the margin and assess restorability.

### The occlusion

The ability of an amalgam or composite to maintain occlusal stability will depend on the surface area of the restoration in contact with opposing supporting cusps and the accuracy with which the occlusal surface has been carved.

Once cusp or incisal tip loss has occurred, the prognosis for any direct restoration diminishes. While the restoration may not fail catastrophically, the effect of the oral environment on the physical properties of the material will result in slow degradation. The basis for this was discussed in Chapter 9; both amalgam and composite undergo creep, and the composite is vulnerable to surface deterioration. Occlusal loading leads to fatigue of both materials.

As a rule of thumb, one cusp can probably be restored reasonably with amalgam, but more than this and crowning should be considered. If an incisal edge is restored with composite then not only should the restoration itself be reviewed carefully, but also the opposing teeth in case surface loss is caused by the hard filler particles of the composite.

The tooth position relative to the adjacent and opposing teeth will influence the type of crown

preparation to be used. Imbrication and rotation will alter the design of the preparation and may limit the ability to position its margins satisfactorily. Tilting of the adjacent teeth may limit the path of insertion of the restoration and prevent crown construction unless modifications are made to the approximal surfaces of these teeth as well.

The inter-arch occlusal relationships should be studied prior to preparation. If there has been deterioration in these, there may be opposing cusps may be intruding beyond the planned occlusal plane and pre-operative equilibration of the area must be done (Chapter 14 and see Fig. 14.15).

### The provision of dentures

Partial denture abutments that are heavily restored may provide a better relationship with the denture if they are crowned. Appropriate contours for clasping and to receive occlusal rests can be incorporated in the crown, probably to greater advantage than trying to use the existing tooth. The *design of a partial denture* that will relate to a new crown must be completed before the crown is made (see Chapter 24).

### Principles of Preparation

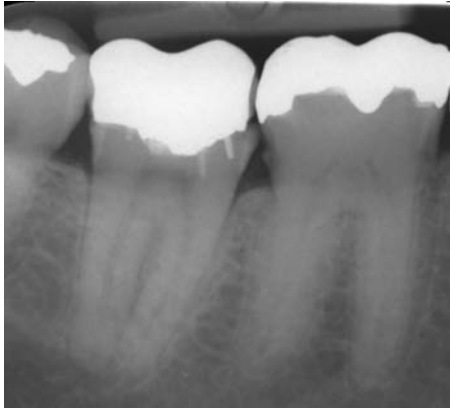The design of the preparation of any extracoronary restoration depends on planning the following using pre-operative study models:

- Path of insertion
- Stability of the restoration
- Aesthetics and the choice of material
- Margin position and type
- New occlusal relationships

#### Path of insertion

This is dictated by the approximal surfaces of the adjacent teeth mesio-distally and *not* by the long axis of the tooth to be prepared. Ignoring this may lead to an inability to seat the crown because its margin is obstructed by a tilted adjacent tooth or a poorly contoured approximal surface of an adjacent tooth (Fig. 15.1). The bucco-lingual path on the other hand is dictated by the tooth inclination (see below).

The path of insertion is also linked to the stability of the restoration. A long, single path provides the maximum retention (Fig. 15.2) and on tilted teeth, particularly lower molars, a lingually inclined path will provide the longest opposing walls.



**Fig. 15.1** Periapical radiograph showing a full crown on the lower second molar. The mesial margin of the crown is deficient because the distal surface of the lower first molar obstructs the path of insertion of the crown. The crown needs to be removed, the distal surface of the first molar recontoured and a new crown made with the correct path of insertion.

### Stability of the restoration

This is the resistance provided by the preparation to displacing forces. These will usually be occlusal in origin and will give rise to rotational moments. Whilst retention is often considered in relation to the path of insertion, it is unlikely that displacing forces in service will act in this direction.

Additional resistance to displacement will be provided by the cementing medium. Traditionally, crowns have been cemented by space occupying *luting agents*. These fill the gap between the tooth and the crown and assist retention by mechanical interlocking. There are inorganic cements with an adhesive component, polycarboxylate and glass ionomer cements, that have shown good success. Now there are well-established polymeric adhesive materials that are commonly used to cement ceramic veneers and resin-retained bridges (see Chapter 19) and may be used for crowns. If the adhesive materials were totally reliable, then the preparation geometry to be described below that creates resistance to displacement would be unnecessary. However, this is not the case and, further, if the crown required removal to deal with say, recurrent caries or fractured ceramic, this could be a very tedious and difficult process if the crown was well bonded to the underlying tooth.

### Near-parallelism

Stability is achieved firstly by the principle of opposing parallel walls that need to be based on the same

level – parallel walls not on the same base do not provide stability (Fig. 15.3).

The bucco-lingual inclination of the tooth to be prepared should be assessed so that the path of insertion creates the maximum amount of parallel and opposite walls (Fig. 15.4).

The preparation of exactly parallel walls is difficult, and near-parallelism, with an angle of convergence or taper of about 5° is more realistic and achievable. Any increase in taper above this figure leads to a dramatic reduction in stability.

The tapered rotary instruments used in the preparation are manufactured with this taper, and so all that is required is to select the path of insertion and cut the bulk of the preparation with the bur held rigidly in this axis. The temptation to angle the bur for apparently easier access, particularly palatally, must be resisted, as this will produce far too much taper.

Basic retention will be created by a cervical collar resembling a squashed cylinder that will occupy one-third to one-half of the crown height. The occlusal third of the buccal and lingual aspects will need to be curved, so that the overall reduction is even, and the final crown will not be bulbous (Fig. 15.5). Some teeth with short lingual walls will have less height bucco-lingually, and so attention must be paid to the approximal areas to create most of the retention.

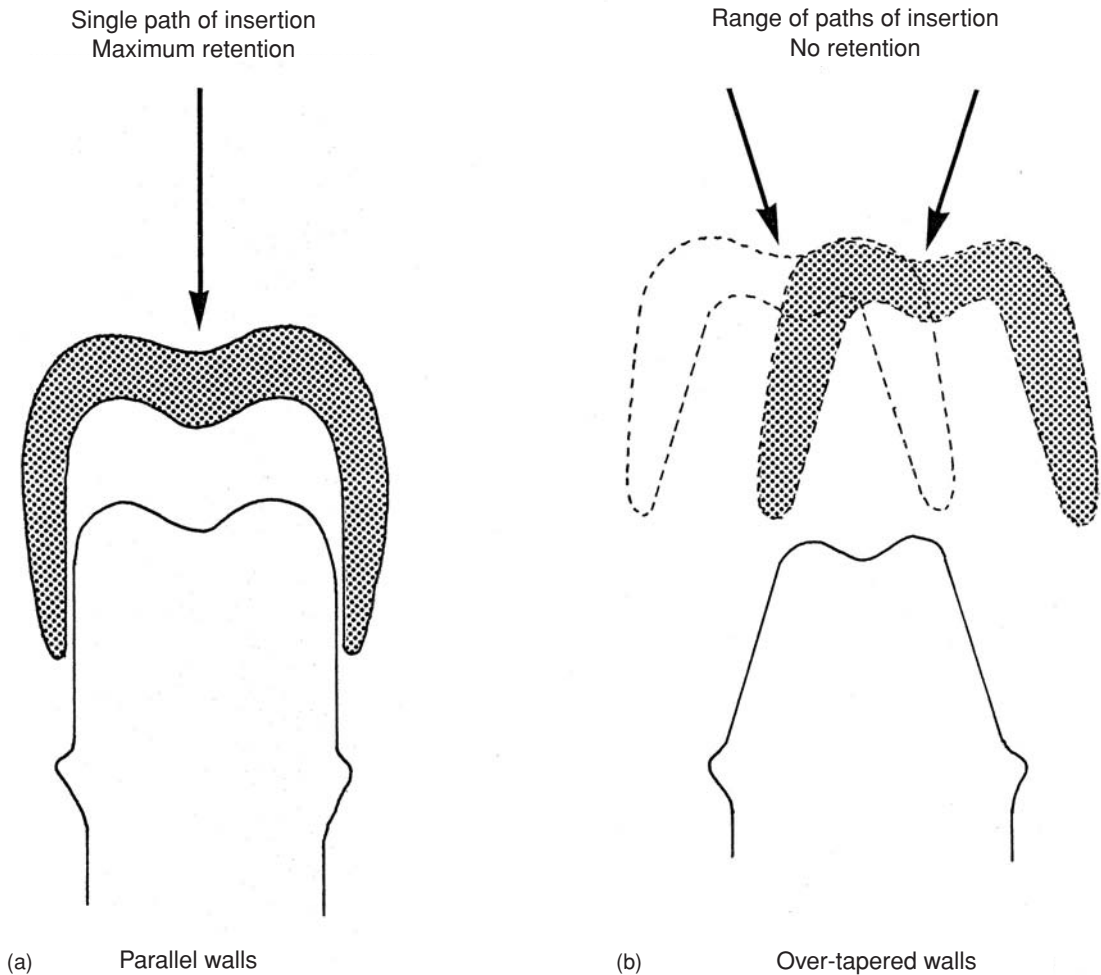
Cutting the approximal surface can be made difficult by a long and broad contact area. Upper molars are a particular problem in that the contact is frequently wide and can extend down to the enamel-dentine junction cervically.

### Crown height

A short clinical crown will increase the risk of failure by displacement since the path of insertion will be very short. Increasing the crown height may be achieved by gingival surgery – *crown lengthening* – but this can produce very unsatisfactory results. Care must be taken to ensure that gross irregularities do not occur in the level of the gingival margin as a result of the lengthening of a single short wall. There is also danger of the exposure of alveolar bone.

Gingival surgery is probably of most use in the distal segment of the lower arch, where frequently the distal crown height of the last standing tooth is very short; the removal of a wedge of tissue can increase the crown height significantly.

The stability of short preparations can be increased by the use of slots and grooves. These will usually



**Fig. 15.2** The geometry of paths of insertion. (a) A long single path provides the greatest stability for the restoration; (b) an overtapered preparation leads to a range of paths and the restoration will have poor resistance to displacement.

need to be placed in the buccal and lingual walls, though approximal grooves are useful where the lingual walls are short (Fig. 15.6).

If none of this is possible, then dentine pins incorporated in the casting or the use of dentine adhesives will be necessary.

### Occlusal reduction

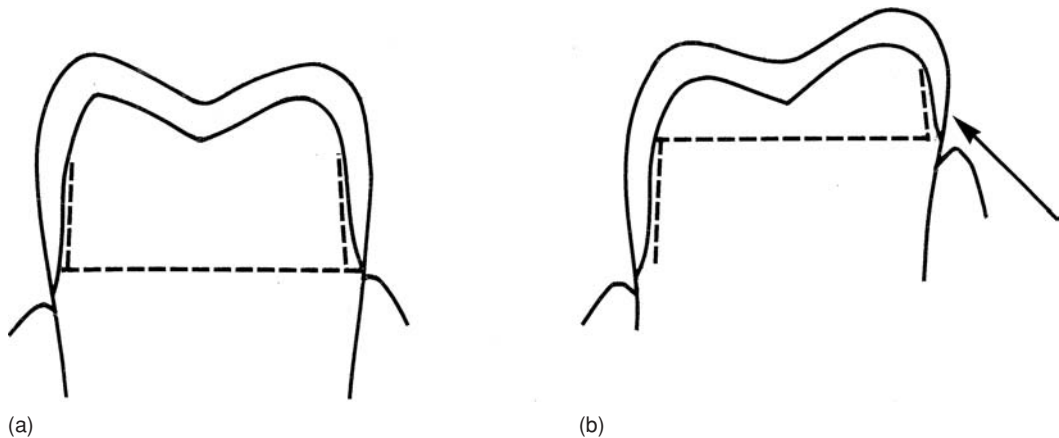
Stability is increased by a preparation with a large surface area and having an occlusal surface that follows the proposed cusp outline. A flat-topped preparation has less stability and also removes more tooth substance than is necessary.

### Margin position and type

The finishing margin of any crown is determined by the gingival contour, the restorative material to be used and the presence of any core.

Where aesthetics is not the primary consideration, the crown margin should be placed supragingivally to prevent plaque accumulation and subsequent gingival inflammation. The margin should therefore follow the sinuous outline of the gingival tissue, with no sharp changes of direction.

The margin should, however, extend beyond the junction of any core, so that it is sited on sound tooth. If the margin is not beyond the core, the



**Fig. 15.3** Stability in a full crown preparation. The parallel walls in preparation (a) are opposite each other on the same base, and provide excellent stability. The parallel walls in (b) are not on the same base, and the crown would be vulnerable to rotational forces.

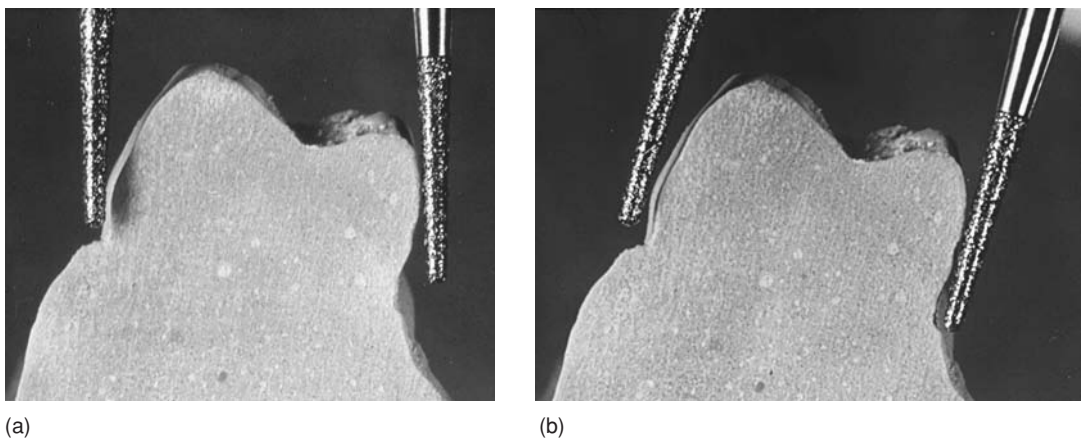
core/tooth/crown junction will be vulnerable to recurrent caries.

The profile of the finishing line is determined by the material from which the crown will be constructed. Ceramic must have a *shoulder* with a minimum width of 1 mm, otherwise the material will be at risk of fracture in thin section. Gold may be finished on a *chamfer* or a *bevelled shoulder*, the object being to achieve a 135° edge to the metal and to create a slip joint that can allow for slight casting shrinkage. This size of margin also allows the gold to be finished without running the risk of distortion.

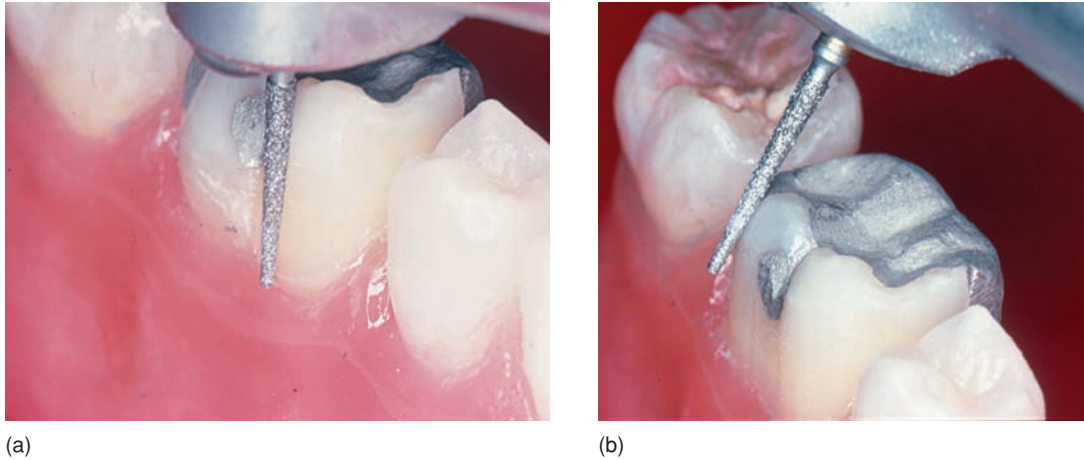
The bevelled shoulder is used for partial veneer crowns where the supporting cusps require overlay-

ing and the casting may be vulnerable to flexure. It may also be used for metal–ceramic crowns to provide margin strength for the sub-frame, and to provide a smoother enamel finish. The drawback to the bevelled shoulder is that it sacrifices considerable tooth substance.

The chamfer is the principal finishing line for the gold veneer crown (Fig. 15.7). It is conservative of tooth structure and provides clear definition of the extent of the preparation for both the clinician when reading his impression and the technician when waxing. It also provides a substantial bulk of metal close to the margin reducing the risk of flexure under load and the consequential rupture of the cement lute seal.



**Fig. 15.4** The choice of path of insertion in the bucco-lingual plane. (a) The path shown by the burs will not create opposite parallel sides; (b) angulation of the path creates longer walls that are parallel and opposite each other.



**Fig. 15.5** The bucco-occlusal reduction on a full veneer crown preparation. (a) The first stage to create a near-parallel collar in the cervical area for stability; (b) the remainder of the buccal wall must be reduced to conform with the contour of the tooth to avoid the final crown being overcontoured.

The *shoulderless* or knife-edge finishing line (Fig. 15.7) should not be used as its definition is poor and can lead to inadequate thickness of metal that may flex under load.

### New occlusal relationships

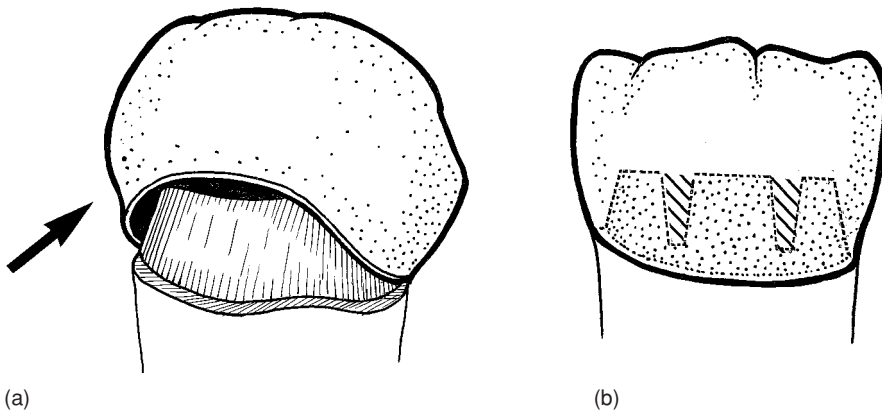
The new crown should harmonise with the existing occlusal relationships where they are satisfactory, but may be required to modify those that are not.

The occlusion should be examined pre-operatively for premature contacts and occlusal plane irregularities in the region of the proposed crown. If deterioration of the occlusal surface has occurred,

the opposing tooth may have overerupted. If this is not corrected, the new crown will continue the disharmony.

Crowns may also be used to correct rotations or aesthetic malalignments. The new crown position must be stable or the eventual result will be tooth movement and a worse problem subsequently (see also Chapters 16 and 19).

The occlusal clearance provided by the preparation must be sufficient to accommodate the chosen material (see later) and in load bearing areas there must be an adequate thickness to prevent fracture. The shape of the reduction should indicate the cusp positions to the technician.



**Fig. 15.6** (a) A short preparation is vulnerable to lateral displacing forces; (b) the incorporation of grooves increases the resistance to displacement.

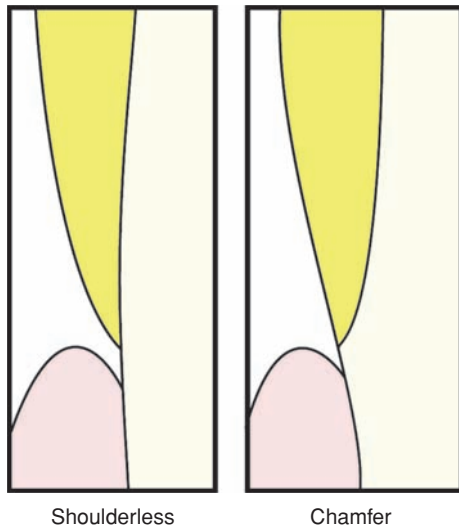


Fig. 15.7 Finishing line profiles for gold crowns.

### Choice of material

The choice is between:

- Gold
- Laboratory fired ceramic
- Milled ceramic
- Ceramic fused to metal (metal–ceramic)

### Gold

Gold is still regarded as the most satisfactory extra-coral restorative material. It has a hardness similar to enamel, does not undergo creep intraorally and may be cast accurately. The creation of the occlusal contour and axial surfaces is relatively straightforward by wax carving. It may be used in thin section and will allow the production of fine margins. It is not, however, regarded as a very aesthetic material.

There are a number of gold types with additions of other metals providing a variety of properties available for use in different parts of the mouth. The clinician should specify the type of gold required for each type of restoration.

The tooth reduction required to accommodate gold is approximately 1 mm throughout, and 1.5 mm, where possible, on the supporting cusps.

### Ceramic

Dental porcelain, or ceramic as it now termed, is regarded as the most aesthetic material used in the mouth but is brittle and is liable to fracture in thin

section. It is essential to have a minimum thickness of 0.8 mm at the margin and at least 1–1.5 mm incisally. Simple laboratory fired ceramic is not strong enough to be used alone for full crowns on posterior teeth or for bridgework. Its weakness is that cracks can originate from micropores on the fit surface, and that these can open catastrophically in tension or bending.

In view of the inherent weaknesses of basic dental ceramic, a number of methods for strengthening it have been developed and most seek to increase the strength and/or translucency of the core; ultimately, there is a desire to eliminate metal from aesthetic systems.

Strengthening methods are:

- Dispersion strengthening
- Glass infusion
- Crystallisation of glasses
- Metal sub-structure

### Dispersion strengthening

The introduction of ceramic crystals of high strength and elasticity into the basic ceramic matrix reinforces the system. The first such system involved the use of alumina crystals and the aluminous crown was introduced in the mid-1960s. This has a high alumina core that is very opaque onto which conventional enamel and dentine ceramics are fired. The improvement of physical properties achieved by this has not really been surpassed until very recently.

Other systems of dispersion strengthening are the inclusion of leucite crystals in either a conventionally fired material (Optec, Jeneric, Connecticut) or in a castable, heat processed form (Empress, Ivoclar, Liechtenstein). Magnesium–aluminium oxide crystals are incorporated in another castable ceramic, Alceram (Innotek, Colorado).

The disadvantage of the *castable ceramics* is that specialised equipment is required for production of the restoration. Their advantage is that they can be produced by the lost wax process and therefore contouring is easier.

### Glass infusion

This produces a denser stronger core by *slip casting*. In this technique a pure alumina slip cast coping is made on a special gypsum die and partially fired. After shaping by milling, the porous alumina is infused with a low fusing glass of matching thermal expansion that melts and diffuses through the porous alumina by capillary action. The result is a very dense and strong alumina composite. The commercial materials





**Fig. 15.8** The die scanning stylus for a milled ceramic crown. All changes of direction of the preparation surface should be rounded to allow smooth movement of the stylus.

are Procera (Nobel Biocare, Sweden) and In-Ceram (Vita, Germany).

A variation in finishing line is necessary for milled ceramic materials that require the die to be scanned mechanically by a stylus to reproduce the internal contours (Fig. 15.8). To allow free movement of the stylus the preparation geometry should include rounded angles. This means that the shoulder needs to blend with the axial wall of the preparation with a rounded line angle, not a sharp one (Fig. 15.9).

#### **Crystallisation of glasses**

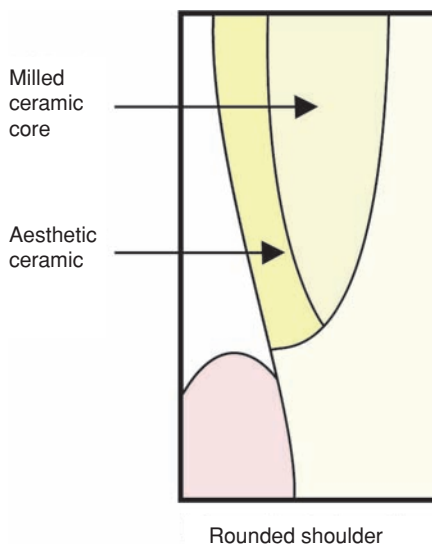
This is the strengthening technique found in another group of castable ceramics. It requires an initial firing process that produces a 'green' ceramic followed by a second firing that converts this material into a dense mass of interlocking crystals. Commercial materials are Dicor (Dentsply, Philadelphia) and Ceraparl (Kyocera, California) but these systems are now used less frequently.

#### **Metal sub-structure**

The use of a cast alloy sub-structure is the principal and most common method; it is discussed below.

#### **Clinical implications**

Whilst the newer systems are of considerable interest, they are as yet unproven clinically and some are not



**Fig. 15.9** Finishing line for a milled ceramic crown.

in general use because of the cost of the equipment. Perhaps the most important factor in the acceptance of new ceramics is whether they can be used in the multiple units of fixed bridgework. Most current materials have limited application in this field.

The principle of the preparation for an all-ceramic crown of any type is to provide dentine support for the ceramic throughout, particularly on the incisal and cingulum areas of anterior teeth. Adequate thickness of material is also essential.

Dental ceramic is harder than enamel and an unglazed surface will abrade tooth surface and frequently results in considerable wear to the opposing tooth (Fig. 15.10).

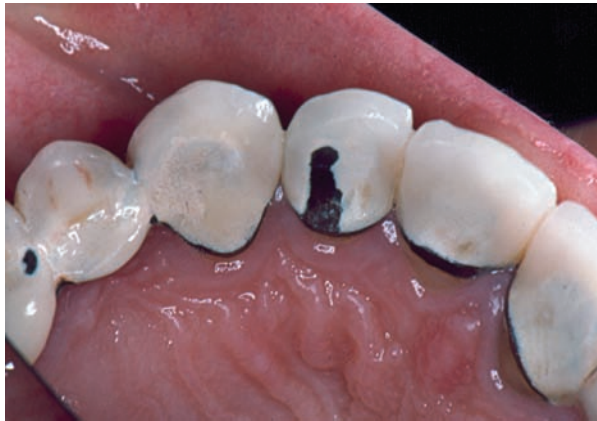#### **Metal-ceramic**

The most reliable and successful method for strengthening ceramics is the provision of a cast metal sub-frame to which the ceramic is bonded. This prevents the propagation of cracks from the ceramic inner surface and the combination provides good aesthetics and excellent strength. Its disadvantage is that it requires considerable tooth reduction to accommodate it.

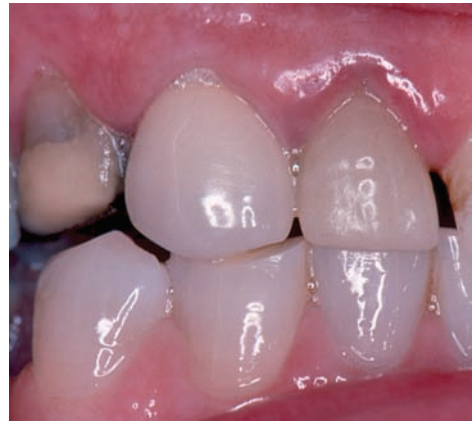#### **Ceramic bonding alloys**

The alloys intended for ceramic combination should have a:

- Sufficiently high melting point so that they do not deform during firing of the ceramic



(a)



(b)

**Fig. 15.10** Poorly glazed ceramic. (a) Crowns and a bridge with poorly constructed ceramic. Opaque ceramic is exposed to the occlusion and this is very abrasive, (b) Poorly glazed ceramic on the palatal aspect of  $\bar{3}$  has resulted in wear of the ( $\bar{3}$ ).

- Thermal coefficient compatible with ceramic to avoid fracture on cooling after firing
- Capacity to bond chemically with the ceramic

There are four main categories of alloy:

- Precious
- Semi-precious – high gold
- Semi-precious – low or no gold
- Non-precious

The melting points of these alloys are higher than those of gold alloys used for crowns and therefore need to be used in phosphate bonded investments rather than gypsum bonded.

Precious metal alloys contain small amounts of platinum and palladium that have been added to gold to raise the melting point. These exhibit good bonding characteristics, are relatively easy to cast, and finish to a high lustre. Their disadvantages are cost and their tendency to sag during firing of the ceramic, particularly when long span bridges are being made.

The semi-precious alloys have better sag resistance and consist principally of silver and palladium, with a variable amount of gold. The silver sometimes leads to ‘greening’ of the ceramic if the alloy has been overheated during casting and is visible at the metal–ceramic junction.

Both precious and semi-precious alloys have small traces of base metals (iron, indium, tin or zinc), which oxidise on firing to form a film that bonds chemically with the ceramic.

Non-precious, or base metal, bonding alloys are either nickel–chromium or cobalt–chromium. They are cheap, but more difficult to cast, and harder to finish. Their high modulus of elasticity gives them the highest sag resistance of all the bonding alloys. The nickel and the chromium oxidise on firing to form the oxide layer for bonding. However, this can be uncontrolled and was one of the major limitations of the early alloys.

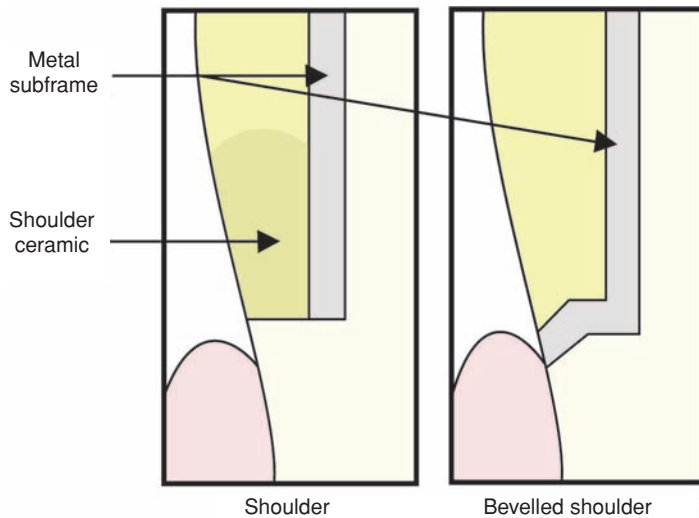
There are some reservations about the inclusion of nickel, which may induce a sensitivity reaction in susceptible patients.

The mechanism for bonding the ceramic depends on three factors:

- *Chemical* – during firing an oxide film is formed on the metal that bonds with the ceramic
- *Mechanical* – surface irregularities on the casting provide a key for interlocking with the ceramic
- *Compressive* – there is a slight mismatch between the thermal coefficients of expansion of the ceramic and the alloy. That of the ceramic is higher so that on cooling the ceramic shrinks very slightly more and grips the metal. A curved surface is necessary for this to happen effectively

### **Clinical implications**

The aesthetics of metal–ceramic restorations present particular problems and these are discussed in Chapter 16. As mentioned above, the clinical preparation requires considerable tooth substance removal to accommodate the metal and ceramic. This particularly



**Fig. 15.11** Finishing lines for metal–ceramic crowns. The metal subframe does not cover the shoulder and shoulder ceramic is used. The bevelled shoulder is designed to allow metal to extend to the external aspect of the crown.

applies to the occlusal aspect where 2-mm clearance is desirable if ceramic is to cover the occlusal surface. Other areas for which ceramic coverage is desired should have a 1.2-mm reduction, which should be removed evenly from the whole surface contour. This means that the final third of the preparation will curve markedly towards the occlusal aspect.

*Finishing lines.* As was mentioned above, ceramic requires a shoulder finishing line that allows sufficient bulk of material for strength. In metal–ceramic restorations it was usual to extend the metal subframe to the edge of the shoulder to support the ceramic and restrict its shrinkage. Various configurations were used and the bevelled shoulder is shown in Fig. 15.11. This creates a very accurate fit at the cervical margin but has the disadvantage that the collar of metal may be visible and spoil the aesthetics.

To obviate this problem, *shoulder ceramic* was invented. This invention is conventional ceramic that is mixed with wax and when this mixture is fired there is little shrinkage. This means that the ceramic remains adapted to the shoulder and the metal subframe is not required in that area (Fig. 15.11); this creates excellent aesthetics.

*Under-reduction of the preparation.* This is the main clinical fault associated with metal–ceramic crowns. Under-reduction of the buccal surface may lead to one of two problems:

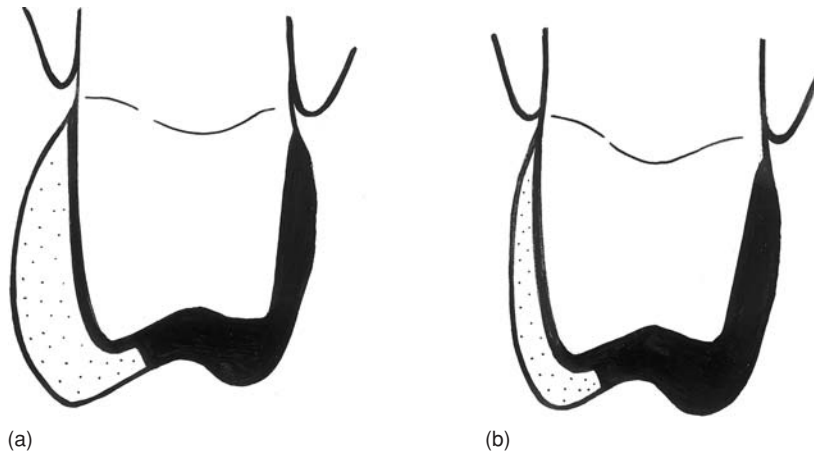
- 1 The technician overbuilds the crown to give adequate thickness of material for aesthetics. The crown is then grossly overbuilt (Fig. 15.12a)
- 2 The technician attempts to maintain the original tooth anatomy which leads to a thinning of the ceramic and metal, with poor aesthetics and the subsequent fracture of the porcelain occlusally (Fig. 15.12b)

In order to judge the amount of tooth tissue removed during the preparation and to ensure this removal is even and sufficient a *silicone index* may be used. A small local impression is taken of the tooth before preparation and cut through in the long axis of the tooth. This may then be positioned on the tooth at stages during the preparation to check the amount of reduction (Fig. 15.13).

*Occlusal considerations.* The choice of material for the functional surfaces must also be considered. Glazed porcelain is usually the patient's choice but it is difficult to produce the anatomical form accurately and adjust it intraorally. If not reglazed, it will damage the opposing tooth surface. As was discussed in Chapter 14, it may not be possible to provide enough clearance in the occlusion to accommodate ceramic. Metal is therefore preferred (see Figs. 14.17 and 14.18).

## Restoration of Root-Filled Teeth

By the time caries and/or trauma has destroyed coronal dentine and the endodontic access cavity has been



**Fig. 15.12** Incorrect preparation for metal–ceramic crowns and the consequences. (a) The crown is made bulbous to reproduce the correct shade; (b) the correct contour is reproduced, but this means that the ceramic is too thin.

cut, there will often be little dentine remaining to support a crown (Fig. 15.14). Should a crown therefore be required on a root filled tooth, some form of *post and core* will be needed to retain the crown and provide stability, with the post being fixed within the root canal.

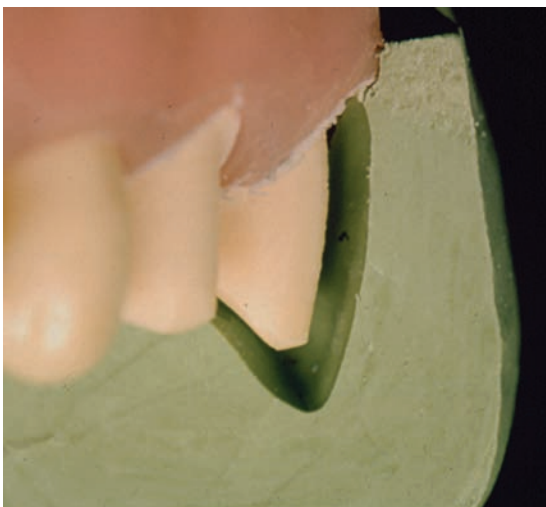The post crown has some limitations and risks. These relate to the morphology and size of the roots, and the danger of fracture of the root in the event of trauma to the crown.

Where the root is of variable shape and size and cannot be seen clearly by radiography, the post crown is a real hazard (Chapter 29). This is true of posterior

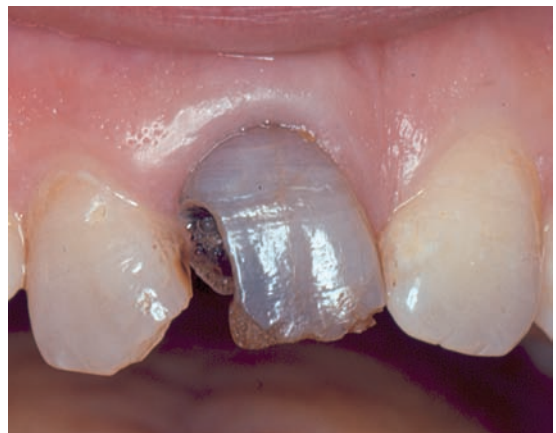teeth, particularly those which have sometimes one and sometimes two roots.

The two-rooted premolar may also have very narrow roots, quite unsuitable for receiving posts. Here it is safer to provide a pin retained amalgam core, rather than embark on two posts with a split core. If there is not enough dentine for the pins, then the root canals can be used for retention, but using small cemented preformed posts that only intrude by 3 or so millimetres into the canal.

A further variation is to construct an amalgam core without pins that is retained within the coronal region of the root canal(s) – the *Nayyar core*. This



**Fig. 15.13** Silicone index used to indicate the amount of tooth reduction to ensure sufficient tooth is removed.



**Fig. 15.14** A carious, non-vital tooth. After removal of the caries and the cutting of the endodontic access cavity, there will be little dentine left to retain a crown. The root canal must be used for retention.

type of post and core is very poor at resisting lateral forces and it is essential that at least 2 mm of coronal dentine is present above gingival level to be incorporated in the crown preparation to resist such forces.

In the anterior teeth, the post and core is the restoration of choice.

### Posts and cores

There is a huge range of post and core systems from which to choose. They may be classified into:

- Cast
- Prefabricated
- Hybrid

#### Cast post and core

Here the natural shape of the canal is utilised after the elimination of undercuts and irregularities to form a conical preparation. The post shape may either be recorded using the direct technique with inlay wax or a non-residual burnout pattern acrylic, or indirectly by taking an elastomeric impression. The core is waxed to the appropriate shape for the particular tooth and the system has the major advantage that it

is made to fit the tooth, rather than the tooth being prepared to fit the system.

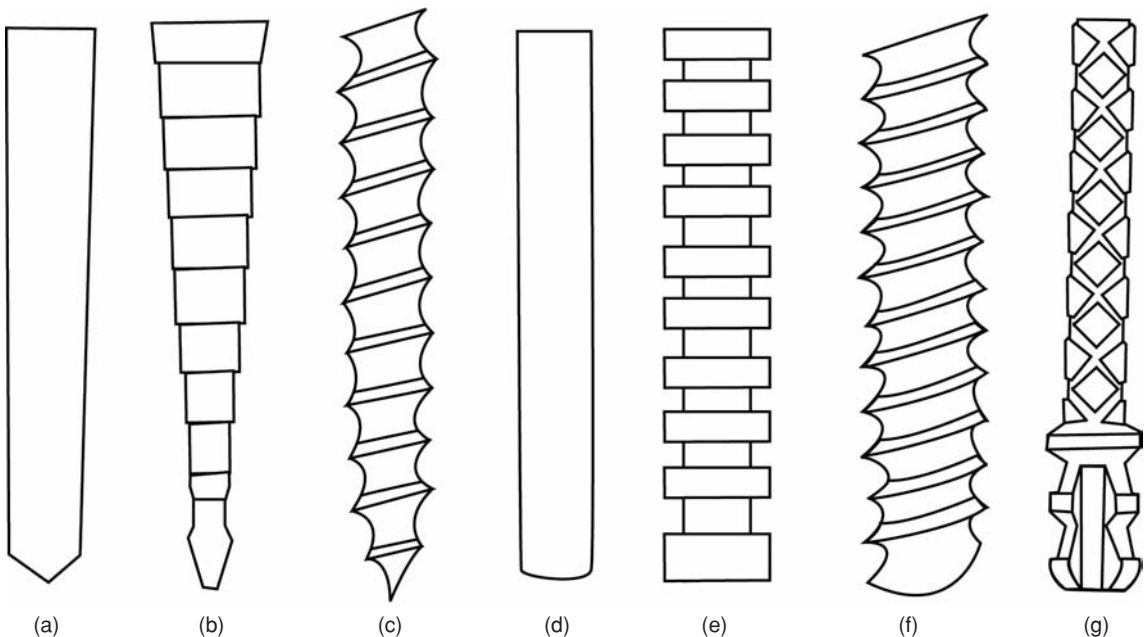
The major disadvantage of the cast post is that it is weaker than the equivalent diameter of a wrought post. Therefore, if fracture of the post is to be avoided, the diameter of the canal must be enlarged to ensure an adequate bulk of metal. This means that the technique sacrifices more tooth and weakens the root in comparison with the prefabricated systems.

The cast post is probably the technique of choice for large canals, for difficult alignment problems, and when a cast diaphragm is required to support the root, or make up subgingival deficiencies.

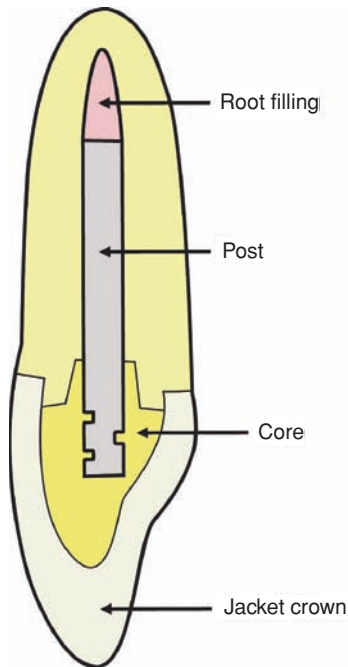
#### Prefabricated post and core

These posts are factory made in a range of sizes with a matching twist drill system to prepare the root canal to receive the post. The posts may be *parallel sided* or *tapered* and these in turn may be *smooth*, *serrated*, *threaded* or *vented* or various combinations of some of these (Fig. 15.15).

The choice of commercially available systems is immense and personal preference has a large part to play in selection. Of the various types, the tapered threaded post is the most dangerous, since its insertion can generate enough stress to split the root.



**Fig. 15.15** Variations in post configuration: (a) tapered; (b) tapered serrated; (c) tapered threaded; (d) parallel; (e) parallel serrated; (f) parallel threaded; (g) parallel vented.



**Fig. 15.16** The structure of a hybrid post crown.

The majority of non-threaded posts are made of stainless steel and are therefore strong in narrow diameters, whilst the threaded systems tend to be brass or mild steel. Other designs have utilised carbon fibre or composite polymers or titanium.

Parallel posts are effective in most teeth, but care must be taken with them in small roots, because the risk of perforation of the canal wall is high. Tapered posts are better in narrow canals. The vented posts have channels for the escape of excess cement and are therefore claimed to permit better seating.

Perhaps the biggest drawback of the basic prefabricated system is that the core position, size and shape is relatively fixed. Some modifications are possible, but are limited in extent. The biggest claimed advantage is that they remove one laboratory stage, and are therefore more economical.

### Hybrid – prefabricated post, cast core

This group has prefabricated posts where the core is custom made and cast onto the post. This combines the strength of the wrought post that can be semi-precious alloy, cobalt–chromium, steel or titanium, with the advantage of being able to shape the core exactly for the particular tooth.

Figure 15.16 shows the basis of the hybrid technique using a smooth parallel-sided post that fits

into a matched preparation. This post may be titanium, steel or, rarely, wrought gold. The core is cast gold, and extends into a countersink to reinforce the post and provide resistance to rotation. The shoulder, which receives the crown, is cut separately and may leave a collar of dentine that effectively lengthens the canal preparation. The collar must have sufficient bulk so that it does not fracture on the die.

Some systems provide plastic impression posts that can be used instead of the metal ones but these can create some problems. The narrower posts are flexible and will negotiate curves that the final post will not. The impression post can subsequently be used as part of the pattern for casting but then the disadvantages of the cast post mentioned above are reintroduced.

The core waxing may be done either in the mouth or in the laboratory.

### Other variations

Concerns about the presence of metal in the root canal such as possible discolouration and the transmission of impact forces directly to the root have led to non-metallic posts. These include posts made from polymer impregnated with carbon fibre, glass fibre, or glass particles. The principal advantage claimed for these posts is that they have moduli of elasticity similar to dentine and therefore it is suggested if the crown receives a blow, the post will absorb some of the force and not transmit it directly to the tooth causing root fracture. However, against this is the property that the post is flexible. Functional loads of the crown may then flex the post and the cement seal may be broken. There is no convincing outcome analysis that supports the use of these posts.

A further technique that has become popular with some, is the cementing of a prefabricated post after canal preparation and then building a composite core to the appropriate shape followed by the impression for the crown. This technique may be called an *anchor* system. Whilst this is a quick technique, the disadvantage is that the composite relies on mechanical interlocking with the post for its retention which may be unreliable.

### Canal preparation

Whatever system is used, there are a number of common features in the preparations. The following aspects are important:

- Root canal morphology
- Length

- Diameter
- Resistance to rotation
- Retention of coronal dentine
- Core characteristics

### Root canal morphology

Assessment of the root canal morphology is required before committing the tooth to a post preparation. It is essential to have an adequate apical seal and the root filling material should be removable from the coronal end of the canal. A full-length silver point is a considerable impediment, and should be replaced with gutta-percha if possible. If it cannot be removed, then a post will be impossible, and a pinned core will have to be considered.

The cross section of the canal and the presence of any curvature should be assessed. A very narrow canal may make preparation difficult and an excessive curvature may limit the extent of the post and reduce retention.

Remember also that the radiograph only shows curves mesially or distally, and not labially or palatally.

### Length

The length of the post is one of the most critical features. A short post is capable of exerting enough leverage to split the root when loaded transversely. It also determines in part its retention and the longer the post, the greater the load bearing area for dissipation of forces to the surrounding bone.

As a rule of thumb, the post should be as long as the crown it is expected to retain.

### Diameter

The diameter is determined by the anatomy of the canal, the amount of diseased tooth tissue removed and the type of metal used in the post and core construction. In order not to weaken the root, the post should not be more than one-third the total root width for the whole root length. This suggests superiority for the tapered post.

However, if the parallel post obeys the rule in the apical danger zone, it will be narrower coronally. This is how the addition of the custom core adapts the parallel post to fulfil ideal requirements, since the diameter is increased by the cast-on metal. The prefabricated core type does not do this.

The range of post diameters that are successful is 1.2–1.4 mm. Posts of a smaller diameter are vulnerable to bending in the occlusion and those that are

larger may jeopardise the root through perforation or splitting.

### Resistance to rotation

A cylindrical post will rotate under stress from the occlusion and may not locate accurately when tried in. Some prefabricated systems require the cutting of grooves or notches to provide resistance to rotation.

However, the natural shape of the root canal is oval and it seems a pity not to utilise this natural feature and to avoid the stress concentrations and weakness created by anti-rotational notches or other devices.

The canal can be simply enlarged coronally to follow the root contour smoothly and this area can be engaged by cast-on core.

### Retention of coronal dentine

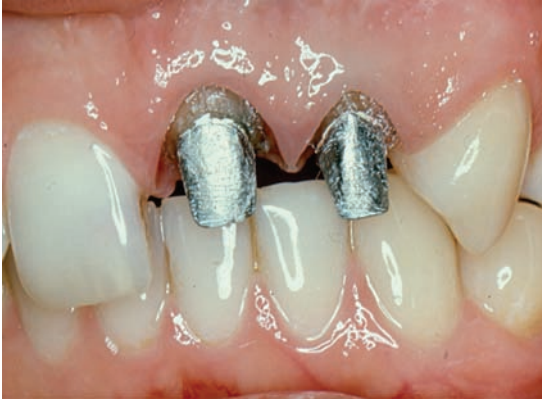It is desirable to keep some coronal dentine above the gingival level. This will effectively lengthen the post preparation but more importantly it will create a collar allowing the crown margin to be sited below the core/coronal dentine margin as seen in Fig. 15.16. This overlapping of the root dentine and core–dentine junction is referred to as a *ferrule*. This term comes from the thimble-like metal tip to a walking stick or umbrella end that is intended to stop the wood splitting.

Hence, in post crown designs, the ferrule has been proposed as a way of stopping the root splitting. There have been designs where the ferrule has been part of the post and core, perhaps as a diaphragm over the root face. However, the crown itself acts as the ferrule and there is no need to modify the post for this purpose.

Difficulty arises when there is not enough dentine to provide this collar and then the core tooth margin will be at the same level as the crown-tooth margin. This is not so advantageous in the distribution of stress away from the canal walls. Also with more stress being transmitted to the post, its mechanical properties become more important. The Nayyar core mentioned above will not succeed without a good-sized ferrule because amalgam is weak when subjected to shear forces. Also there is more risk of the non-metallic posts bending in such circumstances.

### Core characteristics

The core should provide retention and stability for the final restoration and should be similar to the shape of a conventional crown preparation (Fig. 15.17).



**Fig. 15.17** Two posts and cores in place, showing the basic core shape is similar to the ceramic jacket crown preparation, but is smaller. A collar of dentine is present as the base for the core and the ‘ferrule effect’.

It is possible to realign the position of the crown with the core, which allows derotation or uprighting relative to the root position. However, this option must be used with caution since there is frequently an interplay between the hard and soft tissues, and muscle pressure may well move the altered tooth producing a bizarre result.

The core can also be smaller than the vital tooth preparation since there is no pulp to worry about. This gives added bulk to the final crown, which is a considerable advantage for the strength of a ceramic crown, and helps the aesthetics of the metal–ceramic crown.

### Provisional Crowns

This aspect of advanced operative work is frequently neglected and little time is devoted to the construction of a good provisional crown.

The functions of a provisional crown are:

- Protection of cut dentine
- Maintenance of the occlusion
- Maintenance of approximal contacts
- Restoration of aesthetics
- Maintenance of gingival health

It is good practice to construct the provisional crown prior to the impression of the preparation, since this will allow proper estimation of the time remaining for this.

Provisional crowns may be *customised* or made from *prefabricated crown forms*.

### Customised crowns

An impression in a silicone putty is taken prior to the start of the preparation and put to one side. On completion of the preparation the putty impression is used to form a mould for a polymer-based material. There are currently a number of dimethacrylate polymers based on composite technology that are available for this application and these may be self-curing or light activated. They may pass through a rubbery phase during setting which is intended to assist removal of the mould and crown prior to full setting.

After the tooth has been prepared, the material is placed in the putty mould which is then replaced on the tooth. The mould must be located exactly as it was pre-operatively or else the provisional crown will be incorrect. At the rubbery stage the mould and crown is removed with care. It is very easy to tear the crown at this stage. On the other hand, leaving the crown to harden on the tooth may mean that the set material is locked into approximal undercuts and then it will have to be cut off; it cannot be left in place in this condition because it will be a plaque trap and allow leakage to the preparation.

When polymerisation has completed, the crown is trimmed accurately to the margins of the preparation and the occlusion, and polished. It should be cemented with a weak ZOE cement.

### Prefabricated crowns

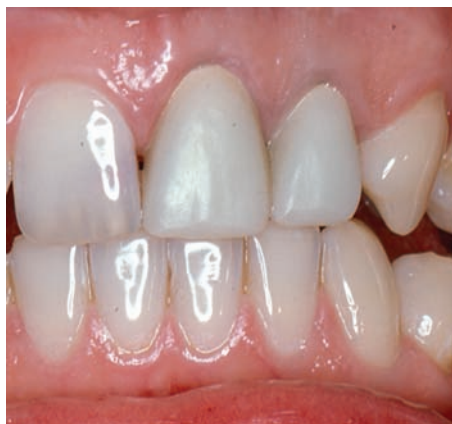Anterior crown forms can be tooth coloured, usually polycarbonate, or transparent cellulose acetate. They are available in a range of sizes for each tooth and the size should be chosen to conform to the mesio-distal width. They need to be cut carefully to the cervical margins and then based with a self-curing polymer (Fig. 15.18).

The range of sizes can be restrictive, if it fits it is usually good, but if it does not it can be terrible. It can be difficult to find one with the correct dimensions both bucco-lingually and mesio-distally.

Posteriorly, the best provisionals are anatomically shaped silver–tin crowns. These are also designed as burn-out patterns for crown waxing. They are soft and can be adapted easily to the occlusion and to the cervical margin.

They do not usually require basing with a polymer, but can be if the fit needs to be refined. Their disadvantage is that being made of a soft alloy, they have a limited life. They must also be protected from amalgamation if they are placed on a fresh amalgam core.





**Fig. 15.18** Provisional restorations. They have been made from transparent crown forms and self-curing acrylic, and provide correct aesthetics, occlusion and gingival contour.

## Shade and Impressions

These are considered in Chapters 16 and 17.

## Occlusal Registration

The construction of a single crown and often a pair of crowns will not require an articulation; hand held models will be satisfactory. However, a crown for a strategic tooth, such as the terminal abutment of a bounded saddle, will require articulation to obtain accurate occlusal contours. Occlusal records were discussed in Chapter 14 and in the absence of a reproducible position of best fit the technique of using an occlusal registration coping should be used. This technique is described in Chapter 21.

## Fitting a Crown to an Existing Denture

This can be a very difficult operation, particularly if a rest seat and two clasp arms are involved as well as the denture base. Clearly the counsel of perfection is to ensure that denture abutment teeth are sound and well restored before a denture is made. However, further caries and loss of tooth substance may happen after a crown has been in service for some time.

The registration of the denture position in relation to the crown preparation must be supplied to the technician. If there is sufficient clearance between the denture and the preparation then the impression can be

taken with the denture in place. The technician may cast the denture area immediately next to the crown preparation in acrylic to provide a durable index for guiding the waxing of the crown pattern.

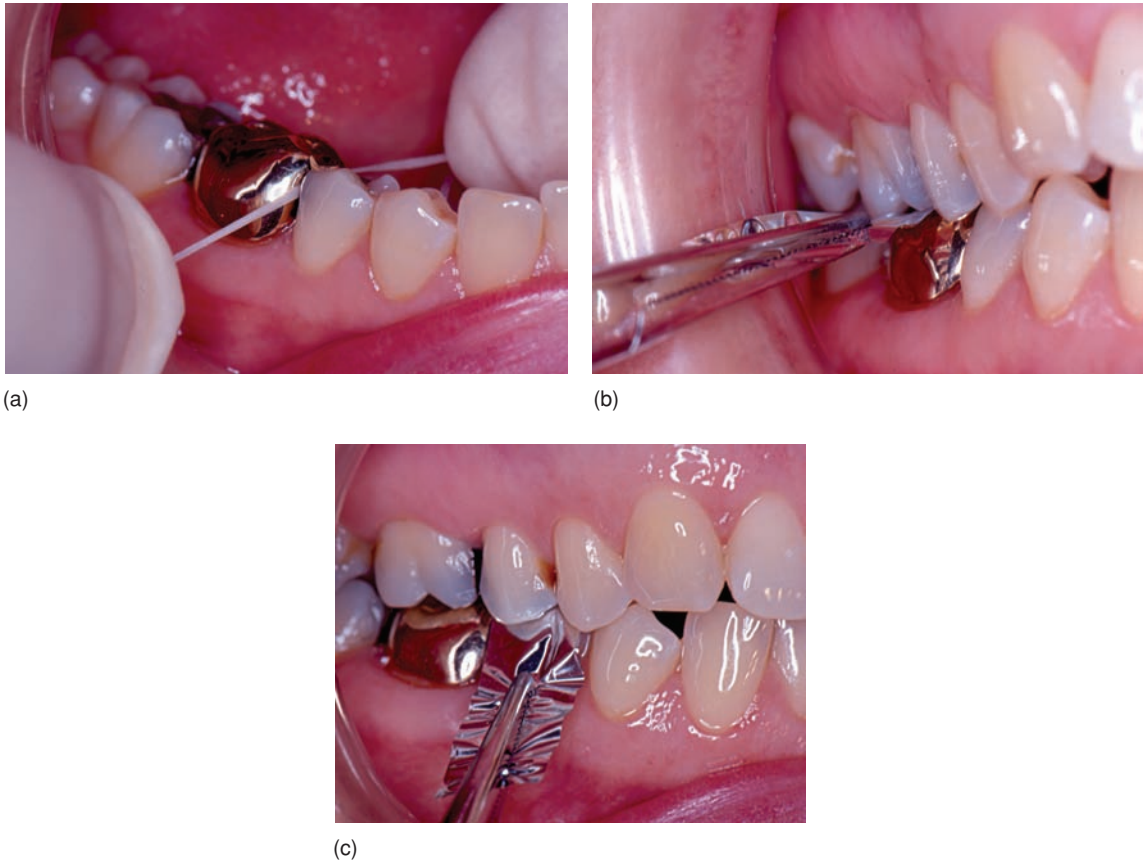
A more accurate method, but one requiring an additional visit, is to take an impression without the denture and ask the technician to construct an acrylic coping on the die. The coping will normally be made of a *pattern acrylic* that burns out of the investment with no residue.

Intraorally, the coping is tried on the preparation and the denture seated. Further pattern acrylic is then added to the coping to register the position of the denture components and the occlusion. The technician will use this as a guide for finalising the pattern that will be invested and cast.

## Try-in and Cementation

The sequence is:

- 1 Check the restoration on the model before the patient arrives ensuring that there are contacts with adjacent teeth and that the occlusion and shade (if ceramic) is correct. Examine the die and the adjacent teeth on the model for rub marks which may have introduced errors
- 2 Do not attempt cementation if the tooth displays any adverse symptoms. If the patient complains of discomfort, diagnose the cause and treat it before cementation
- 3 Remove the provisional and clean the preparation, ensuring that all cement is removed. If possible this should be done without local analgesic since this can prevent the patient assisting in the assessment of the occlusion
- 4 Try in the restoration. If it does not seat initially check the *contacts* with floss (Fig. 15.19a). If the restoration still does not seat, examine the fit surface for irregularities such as blebs of cast metal and grind any away
- 5 Once the crown has been seated, check the *marginal adaptation*. There should be a smooth transition from the tooth onto the crown. Check the shade in daylight
- 6 The *occlusal contacts* should be assessed. Premature contacts may be detected using articulating paper and shimstock (Figs. 15.19b,c). The type of articulating paper can affect the results since some are excessively thick and will not allow for differentiation of the high points and normal



**Fig. 15.19** Fitting a full crown. (a) The approximal contacts are checked with floss; (b) the occlusal relationship is checked with shimstock both on the crown itself and (c) at the cusp/fossa relationship mesial to the crown. Both contacts should hold shimstock.

occlusal stops. Fine articulating paper is preferable and it often advantageous for the occlusal surface of the restoration to have a matt finish in order to detect the minor prematurities that may be present

- 7 The occlusal contacts must be checked in all excursions. Heavy contacts must be eased but care should be taken that the surface is not over-reduced, since this will take the crown out of occlusion.
- 8 *Choice of cement.* Incorrect selection and manipulation of the cement will affect the life of a crown dramatically

There are two principal luting agents, zinc polycarboxylate and glass ionomer cements, and their properties were discussed in Chapter 9. The polycarboxylate is the more reliable since there is some concern

about the pulpal response to glass ionomers when used as luting materials.

The cement should be mixed to the manufacturer's specified powder/liquid ratio which should provide a consistency that will allow it to be displaced as the crown is seated and excess will flow away.

- 9 The prepared tooth should be isolated and dried. The fitting surface of the crown should be coated with cement, placed on and seated home. Considerable pressure should be applied to the seating crown initially to express the excess cement and pressure should be maintained until the cement has set. For a post crown, the canal should be cleaned and filled with cement prior to seating the post and crown together with the same mix
- 10 Once the cement has set, excess is fractured away from the margin and the approximal embrasures

cleared with floss. It is particularly important that the cement has fully set before removal of excess is attempted. This is especially so because glass ionomer and zinc polycarboxylate cements go through a rubbery phase on setting. If these are disturbed at this point the integrity of the marginal seal may be lost

- 11 After cementation, the occlusal relationship should be rechecked

## Review

The crown should be inspected again a week or so later, since natural occlusal function will have been re-established, and contacts may require further adjustment

Radiographic review should be carried out 6–12 months later and every 4 years or so, to check for symptomless development of apical pathology

### Fixed Prosthodontics – Crowns – Summary

Ensure that the crown is treatment planned in the context of the patient's requirements and the general condition of the mouth.

Important principles in the preparation of a crown are the choice of the path of insertion and features to ensure the stability of the final restoration.

There is a large range of materials available, particularly for the all-ceramic crown. The choice of material affects the preparation design, particularly the shape of the finishing line and the amount of tissue to be removed.

There are many post crown systems. The choice is to a large extent personal but the hybrid types offer the greatest range of application. Important characteristics in the post preparation are the length and diameter. Tooth tissue should be preserved where possible.

Accurately fitting provisional crowns maintain the relationships to adjacent teeth and the health of the dentition.

High standards of acceptance at the fitting stage will lead to long-lasting restorations.

# Chapter 16

## Colour and Aesthetics

Two of the recurring themes of this book are the requirements for durable tooth-coloured restorative materials and the need to achieve good aesthetics. This is a complex subject and is a mixture of art and science. Advances in both restorative polymers and ceramics have increased the range of techniques available under the broad heading of 'Cosmetic dentistry' and some of these have been described already.

This chapter will consider colour science and shade taking together with the causes and management of poor aesthetics of individual teeth. Section IV will consider the aesthetics of fixed bridgework and removable prosthodontics.

### Colour

A prerequisite of all aesthetic dentistry is accurate shade taking and matching, and, in respect of indirect restorations, good shade communication. The technician rarely sees the patient and is therefore relying on the dentist to describe the shade and its distribution. Perceived colour is highly affected by viewing conditions and it is essential that the shade is taken in the most favourable conditions in order to obtain an accurate result.

### Factors affecting perceived colour

Three factors are involved:

- Light source
- Eye response and colour perception
- Environment

#### Light source

Light is composed of different wavelengths that are dependent upon the source. Incandescent light, such as that provided by normal light bulbs, accentuates the yellow/red range in the spectrum, whilst fluorescent light accentuates the blue/green range; both affect colour vision.

Teeth exhibit *metamerism*, that is the property of changing colour in different lighting conditions. Daylight corrected fluorescent tubes and shade taking lights with a standard colour spectrum are commercially available and these can help, but they may give rise to more inaccuracies in comparison with good

natural daylight. The daylight for shade taking needs to be diffuse, north light, not direct southern sunlight. Teeth also change colour as they become dry; they must be kept wet during shade taking.

#### Eye response and colour perception

When concentrating on the colour of a tooth, the retinal cones of the eye will fatigue and sensitivity to colour will be reduced. To overcome this, decisions on shade should be made in steps of no more than 5 seconds. Looking at a pale blue surface, such as a napkin or piece of card, between evaluations of shade can help; this accentuates yellow/orange sensitivity, which is the dominant range of tooth colour. Prolonged viewing of a tooth results in a negative after-image that is the complimentary colour of the original surface viewed.

Colour perception is subjective and varies between people. In addition, colour blindness is quite common and obviously creates problems during shade taking. Using two people to take the shade, dentist and nurse, will even out such inaccuracies. A simple eye test is also useful to discover colour vision acuity.

#### Environment

Strongly coloured light reflected from furniture, clothing or the walls will influence shade taking, partly from the after-image mentioned above and partly from reflection. Ideally the surgery and its equipment should be of a neutral colour. Strong colours from make-up or clothing should be removed or masked.

## Components of colour

In order to communicate subtle variations in colour, it is important to understand the way that a specific colour is measured. Colours may be broken down into three components:

- Hue
- Chroma
- Value

### Hue (colour)

This is the description or name given to a colour or family of colours, e.g. blue, red, green, yellow. Dentine is the most important hue within a tooth.

### Chroma

This is the intensity or strength of a given hue. For example, if 10 drops of red dye are added to a glass of water it will become red, if 100 drops are added, the water will still be red, but of a more intense colour. The chroma will have changed but the hue will not. The chroma of dentine is as important as its hue.

### Value

This is the total reflectance or luminance, that is related to the brightness of a colour measured on a scale from black to white. For example, if red is the hue then pink or maroon can be made by changing the value without changing the original hue. The overlying enamel, being essentially colourless, is the principal determinant of value in a tooth, modifying the dentine hue to the observer. The brightness of a colour is probably the most easily perceived characteristic.

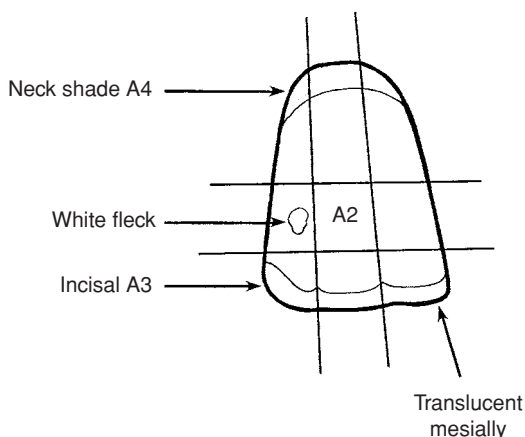
## Shade Guides

The most commonly used shade guide is the Vita-Lumin that allocates a letter for the hue, A, B, C, D, and a number, 1, 2, 3, 4, indicating the chroma. No provision is made for altering or indicating the value.

The arrangement of basic hues is:

- A1-4: browns
- B1-4: yellows
- C1-4: greys
- D2-4: reddish-greys

This means that the observer must make a decision about the combined hue/chroma in almost one step. Selection can therefore be difficult, especially for the novice, as there is a tendency to jump from one group to another, rather than follow a progressive pattern.



**Fig. 16.1** Sketch made at the chairside to provide instructions for the laboratory for shade reproduction.

If the shade tabs are arranged according to value (degrees of brightness), as in most denture tooth shade guides, selection may be more straightforward. The appropriate sequence is B1, A1, B2, D2, A2, C1, C2, D4, A3, D3, B3, A3.5, B4, C3, A4, C4.

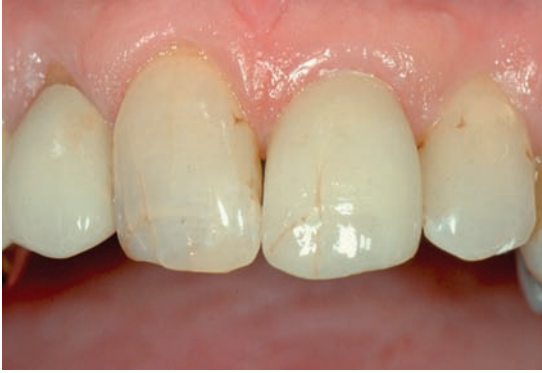The shade guide has other limitations. An all-ceramic crown will not be the same thickness as a shade tab, and, of course, light passes through an all-ceramic crown more readily than one of metal-ceramic.

The construction of the guide may be different from the layering that the ceramist may use. The shade tab has subtle in-built colours and nearly always a neck effect that most ceramists do not include. It is important to ask the ceramist how he uses his shades, and it may be necessary to remove the neck colour from the tab to match his system. Many laboratories use just core, dentine, enamel and an external stain and it would be useful to ask the laboratory to provide a customised guide of various thicknesses and colours.

### Informing the technician

Any time spent accurately obtaining the shade will be wasted unless the information is communicated clearly to the technician. When taking a shade it is essential to include a sketch diagram of the tooth or teeth marking clearly areas of decalcification, internal flecks, lamellae and so on (Fig. 16.1).

Work cards, or laboratory prescription forms, can be set out in many ways, but must include the following information:



**Fig. 16.2** Ceramic crown on I1 showing characterisation.

- Patient's name and sex
- Approximate age – the surface texture of teeth changes with age and the technician can reproduce this effect
- A drawing of the tooth showing the distribution of the various shades, and characterisation
- The dentine, enamel and cervical shades
- Amount of glaze – high, as guide or low
- Amount of translucency – high, as guide or low
- Type of restoration required
- Is a metalwork try-in stage required?
- Is a biscuit bake (unglazed) try-in stage required?
- Ceramic or metal occlusal surface?

If the information given to the technician is good and the accompanying impressions are accurate, then the standard of ceramic crown construction can be excellent (Fig. 16.2).

## Discoloured Teeth

Discolouration of the teeth may be due to intrinsic or extrinsic stains:

### *Extrinsic staining:*

- Plaque and calculus
- Mouth washes
- Diet
- Discoloured restorations
- Smoking

### *Intrinsic staining:*

- Caries
- Erosion
- Chemical ingestion, including fluoride and tetracycline
- Trauma

- Non-vitality and root filling
- Neonatal jaundice
- Genetic and developmental malformations

## Extrinsic staining

This is very common and patients may not appreciate the effects of tea, coffee, smoking, red wine and chlorhexidine mouth washes. The misinformed patient may resort to home-bleaching kits when all that is required is a scale and polish and instruction in oral hygiene.

The discolouration and microleakage associated with polymeric restorations has been discussed in Chapter 9. Corrosion products from amalgam diffuse into the surrounding dentine, causing a greyish-black stain.

## Intrinsic staining

Developmental disorders vary in intensity from case to case. Enamel hypoplasia may be seen as localised insignificant white spots or more extensive areas of poorly formed tissue that are very liable to take up extrinsic stains. Other more serious conditions, amelogenesis imperfecta and dentinogenesis imperfecta may lead to badly discoloured teeth; these are considered in Chapter 27.

Chemicals may be incorporated in the dentine and enamel during their formation. The most dramatic of these is tetracycline. Different effects are produced by different members of the tetracycline family, by the dosage and duration of treatment and the age of the patient at treatment. Effects range from mild grey bands to total blackness. It is surprising, in view of this problem being common knowledge, that tetracycline is still prescribed for children by the medical profession.

The dental profession, on the other hand, in its keenness to prevent caries has caused a somewhat similar problem with fluoride. Systemic fluoride supplements, perhaps with their dosage not monitored accurately by parents, coupled with ingestion by children of fluoride toothpaste, has led to a high incidence of fluorosis in the more dentally aware population. This may be seen as grey or white patches in the enamel.

Neonatal jaundice may lead to incorporation of the yellow pigment of bilirubin in the dentine.

Discolouration caused by caries was discussed in Chapter 10 and erosion will be discussed in Chapter 27.

Trauma, particularly that resulting in loss of vitality, may induce dentinal changes. Blood may pass from the pulp into the dentine and the breakdown products of haemoglobin will appear as black or brown stains. Non-vital dentine can lose its translucency, probably as a result of mineral deposition in response to the trauma, and become more yellow.

Root canal therapy may cause three staining problems. If all the pulp is not removed from the crown, particularly from the pulpal cornua, this will undergo breakdown and cause staining. The older silver containing root canal sealers have to be handled carefully so as not to leave residues in the access cavity, because these can stain the dentine. Finally, the access cavity of an anterior tooth should be sealed with a tooth coloured material and not amalgam; amalgam may interfere with the translucency of the crown, making it look darker.

### Management of discolouration

The remedies for *extrinsic stains* and discoloured restorations are straightforward – polishing of both or replacement of the restoration. A stained restoration may not be a functional failure but, if the patient is aware of it, it is an aesthetic failure. In respect of root canal access discolouration, remove the access seal, remove stained dentine within the coronal area and restore it with a lighter shade composite.

*Intrinsic stains* may be more difficult to treat. The possibilities, depending upon the cause and the severity, are:

- Microabrasion
- Bleaching

- Ceramic veneer
- Crown

### Microabrasion

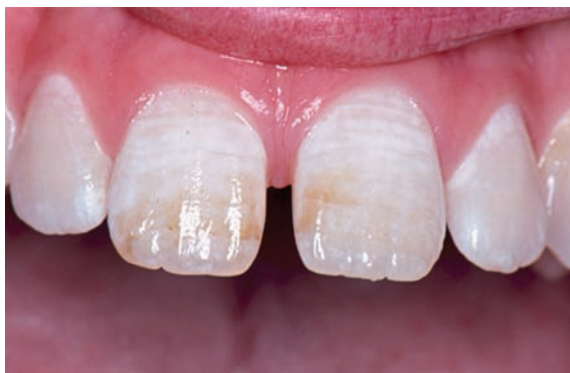Staining or a developmental problem that is fairly superficial in the enamel can be eliminated by removing the stained enamel. Here, 'fairly superficial' means to the depth of several hundred micrometres only. The removal must be carefully controlled and very conservative. It is important to maintain the overall enamel surface character.

This procedure may be done using a combination of abrasive and dilute acid. Commercial products are available that use hydrochloric acid together with abrasive impregnated wheels. An effective substitute is dry pumice mixed with phosphoric acid etching gel and applied by hand with a composite polishing rubber (Fig. 16.3).

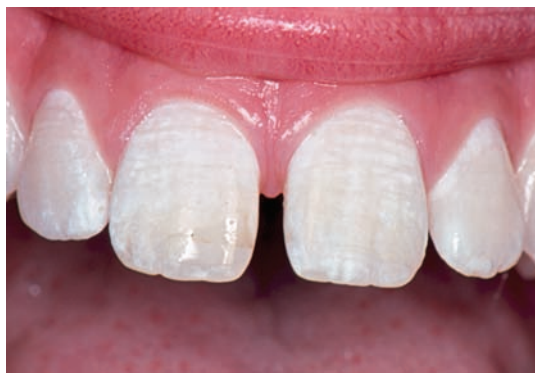The technique removes only superficial stains and must be abandoned if the stain turns out to be deeper than originally estimated.

### Bleaching

The intrinsic pigments of the stained dentine may be bleached by chemical action. The technique uses 35% hydrogen peroxide or similar agents such as urea peroxidase or carbamide peroxide. The technique is usually used on teeth that have discoloured after root canal therapy. The access cavity is reopened under rubber dam and a pledget of cotton wool soaked in the bleach inserted. The cotton wool is sealed in place for a week and 'refreshed' as necessary. Yellow stains respond better than brown or orange. However, the changes are not permanent and relapse is common.



(a)



(b)

**Fig. 16.3** Enamel hypoplasia that is superficial and amenable to microabrasion. (a) Before treatment; (b) after treatment.

External bleaching of vital teeth has become popular and has been provided by non-clinically qualified people. The intention is to change the colour of all the teeth making them to be whiter and brighter. To be effective the underlying dentine must be bleached but this will take time. Superficial stains may be bleached by home bleaching kits but these are limited to low concentrations of hydrogen peroxide so they are not as effective as treatment provided by the dentist where concentrations of up to 35% carbamide peroxide may be used. The risk of unqualified people providing such treatment or of patients deciding to treat themselves is that any underlying pathology such as a carious lesion may not be diagnosed. In the United Kingdom such treatment has been complicated by its being classed as cosmetic with a limit of 0.1% hydrogen peroxide being imposed on dental treatment.

### Ceramic veneers

These are effective for masking more substantial hypoplastic defects of enamel, intrinsic staining and mild malformations. They utilise a half-enamel thickness reduction of the labial surface and the acid etch technique to bond a thin layer of ceramic to the tooth. They are a valuable conservative alternative to ceramic crowns.

The cementing agents are the same as those are used to cement resin-retained bridges (see Chapter 19), ceramic and composite inlays. To complete the technique, 'opaquers' that are fluid composites can be used to mask strong underlying colours or modify the shade of the veneer. The mode of adhesion to the ceramic relies on etching or sand blasting and then coating the fit surface with a silane coupling agent.

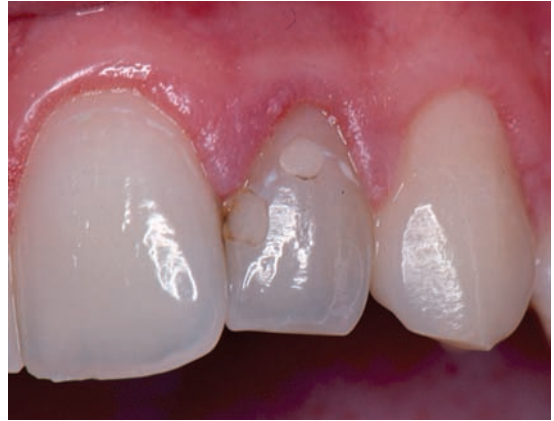Adhesion is much better to enamel than to dentine and the best results are obtained with either complete attachment to enamel or, where enamel has been lost, with at least 2 mm of enamel present around the periphery of the restoration. If too much dentine is present bonding will be unreliable and crowns will be a better alternative.

### Indications

If the stain or anomaly is deep within enamel or in dentine then the choice is between a veneer and a crown.

A suitable check list is:

- Is the discolouration severe enough to warrant treatment?
- Is there enough tooth tissue left to support a veneer?



**Fig. 16.4** Root filled and discoloured  $\bar{2}$  that requires a veneer.

- Is the discolouration minor enough to be masked by thin ceramic?
- Is there any occlusal restriction?

The first point is to consider whether the patient is being excessively conscious of a minor defect. Some people naturally have teeth of a slightly odd colour and these often fall into the shade guide range of C and D. A careful and sympathetic explanation of natural tooth colour and the disadvantages of operative treatment may dissuade such patients from sacrificing structurally normal enamel to correct a minor problem.

The second question is whether the tooth is too heavily restored to support a veneer. For example, a veneer preparation on a tooth with large mesial and distal restorations plus an endodontic access cavity might not be supported by much sound tissue.

Figure 16.4 shows an upper lateral incisor that had been traumatised and was root filled, and also has stained composite restorations. The dentine has been darkened in response to the trauma. It was unlikely that bleaching and replacement of the composites would provide lasting improvement. A veneer was therefore provided.

Very dark staining, such as that of tetracycline staining, may not be masked by veneers. Notwithstanding this, even opaque veneers can achieve a very acceptable change from gross staining that is often appreciated by patients. It is now less common to see such discolouration but mild staining with yellow, orange or brown bands is still seen (Fig. 16.5).



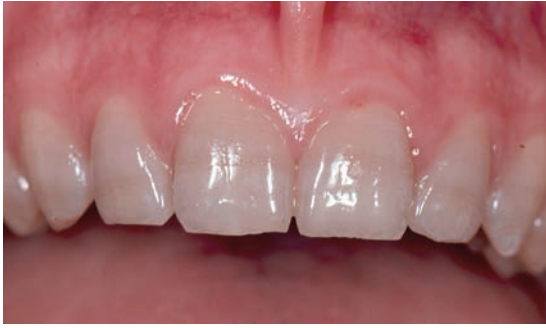

Fig. 16.5 Mild tetracycline staining.

Ceramic in thin section is very vulnerable to chipping. If there is parafunction or evidence of excessive tooth wear, veneers may fail.

### Preparation

The preparation (Fig. 16.6) involves the reduction of a one-half enamel thickness over the whole surface, which means that there is a variable thickness of enamel removal. The reduction is extended into the approximal embrasures but not through the contact area, and should remain on enamel.

Defects, such as acid erosion, should be made good with glass ionomer cement and the finishing margin should be a narrow shoulder or chamfer prepared at

the level of the free gingivae and not placed in the gingival crevice.

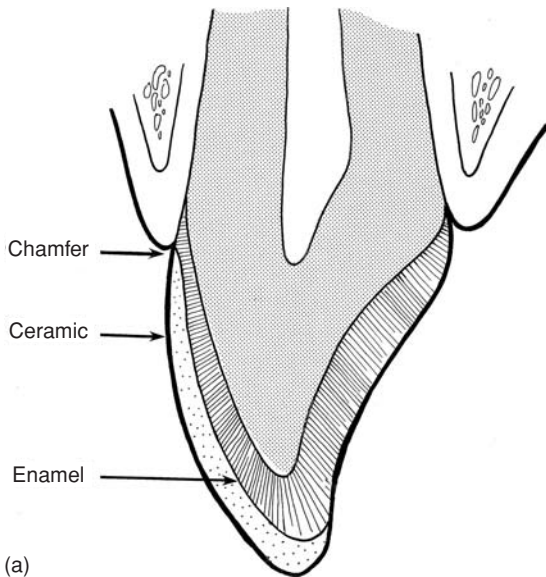
The incisal edge should be reduced, utilising a reverse bevel onto the palatal surface. The thickness of the incisal reduction should be at least 1 mm.

Provisional restorations may not be necessary and it is an advantage not to place these because their retention would be by adhesives which might interfere with the cementation of the final restoration. If the patient feels that the appearance of the preparations is unsightly, a composite layer or a polycarbonate veneer can be placed but this should only be tacked onto a limited area of prepared enamel.

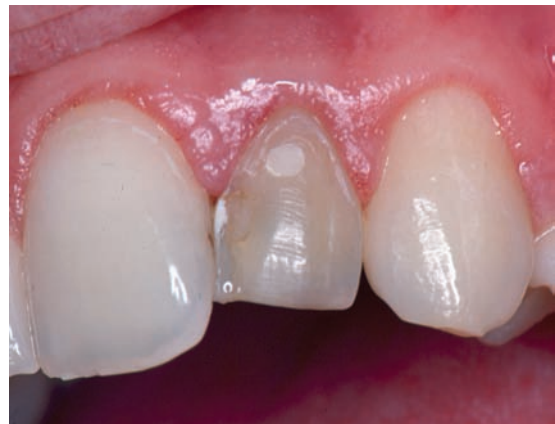### Laboratory stages

The impression is cast first in *divestment refractory stone*, i.e. stone that can be heated in the ceramic furnace without breaking up, and then in die stone. The veneer is built and fired on the divestment and adjusted finally on the die stone model. The ceramic that is used must be translucent so that the glass cores referred to in Chapter 15 cannot be used because they are opaque. Standard dentine and enamel ceramics or the newer leucite reinforced ceramics are satisfactory and their translucency enables minor colour correction to be achieved by varying the shade of the underlying cement.

After adjustment of the margins and the occlusion, the fit surface is treated. This is better done, if



(a)



(b)

Fig. 16.6 (a) Schematic diagram of the preparation for a ceramic veneer on a central incisor. Note the incisal reduction and the palatal reverse bevel, (b) Preparation on the tooth shown in Fig. 16.4. Note that the approximal contacts are maintained.

possible, after clinical try-in because contamination from the mouth may interfere with adhesion.

The techniques for preparation of the veneer fitting surface are:

- Etching
- Sand blasting

Etching is very technique sensitive. The glazed surface of the veneer is first protected with wax and the fitting surface etched with 30–40% hydrofluoric acid for no more than 3 minutes. The etched surface must be neutralised by placing it in a furnace at 600° C for 5 minutes, followed by ultrasonic cleaning in distilled water for 3 minutes after cooling.

Because of the dangers of hydrofluoric acid, substitutes are available, but the safest way is to avoid etching altogether and grit blast the surface instead with 40- $\mu$ m grit. This grit blasting may be done using a small unit in the dental practice.

#### **Try-in and cementation**

The tooth is cleaned with dry pumice and a slowly rotating brush to remove plaque and pellicle that might otherwise contaminate the veneer. The veneer is placed carefully onto the tooth and the margins and the occlusion checked. If necessary these may be adjusted by fine diamond points followed by a diamond polishing paste.

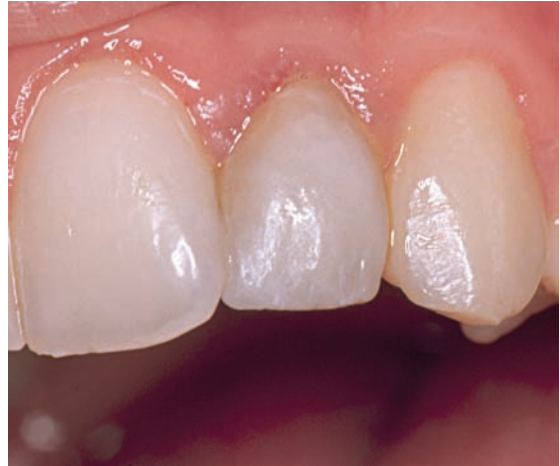The shade is observed in natural light in order to decide whether the ‘universal’ cement will be satisfactory or whether a lighter or darker shade is required.

The lightly filled composite cements or luting agents may be dual cured or light cured. Whilst the dual-cure type may provide better polymerisation if the activating light is attenuated by the veneer, their colour stability is poorer because there is an increased amine concentration for the self-cure system.

Depending upon the product, it will come with the basic shades grouped into whites, yellows, browns and perhaps greys. There will be a separate opaquing agent. There may either be individual syringes of each colour or a base colour and containers of add-in colours – *tinters*.

The base paste may be tried first without mixing in the activator. Additions may be made as desired to change the colour, keeping some on the mixing pad, until the effect under the veneer is correct. The underside of the veneer must be cleaned for each application – the reserve on the pad will become the final cement in due course.

When the correct effect has been obtained, rubber dam is applied, the underside of the veneer is cleaned



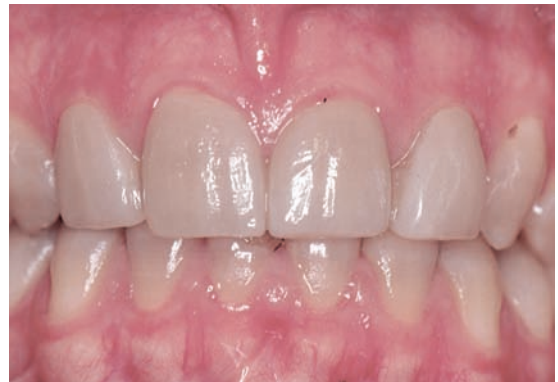**Fig. 16.7** Completed ceramic veneer on 12.

with isopropyl alcohol and, if this has not been done already, grit blasted. (Wax must be applied to the glazed surface first to protect it.) A silane coating is then applied to the veneer and air dried. The bonding resin comes next; this is air dispersed to prevent pooling. Then apply the luting cement and position the veneer.

‘Tack’ cure for 10 seconds with the activating light and check the orientation of the veneer. If this is correct, the cement can be fully cured by exposure to the light from several angles.

If the orientation is incorrect, the veneer can be removed gently and cleaned to repeat the cementation.

After curing, check and remove excess from the margins, check the occlusion both in centric occlusion and lateral and protrusive excursions and show the patient (Figs. 16.7 and 16.8).



**Fig. 16.8** Ceramic veneers on 11|12 masking the tetracycline staining shown in Fig. 16.5.

## Aesthetics

### Incorporation of colour and characterisation

Careful selection and use of colour can create illusions to apparently change the position or size of a crown. This can be used for a malaligned or poorly shaped tooth to give it the appearance of being wider or shorter than it really is. By lightening or darkening selected teeth in a full arch, the illusions of flatness or more rounded appearance can be created. Wide teeth can be apparently narrowed by the placement of shaders or stains mesially or distally that highlight the central area.

The contour and texture of a crown should mirror its neighbour, enabling the reflection of light to be equal to that of the natural tooth. A roughened labial surface should be left on the core of a crown so that light entering through the more translucent layers of ceramic will be reflected in different directions, adding vitality.

If the technician has been asked to make six anterior crowns with just the shade and the sex of the patient to guide him, he can make the crowns take on a definite masculine or feminine appearance by attention to detail and careful shaping. Labial surfaces may be made to look flat and therefore wider and more masculine, or, alternatively they can be rounded, smaller and feminine with greater vitality due to the reflected light from the curved surface coming at a variety of angles.

Artificial ageing can be achieved by creating flat worn incisal edges, loss of lamellae and thin enamel.

Colour may be imparted to a crown by the application of internal colourant ceramic effect powders. When building colour into the crown, the ceramist will remove unfired body ceramic almost to the opaque layer, hollowing and cutting an angle so as to achieve a blend and carefully introducing either gingival effect or dilute stain into the depression, and upon firing, the colour will show through the more translucent body ceramic. Traces of orange on the incisal edge, decalcifications and so on may all be incorporated in the same way.

Colour may also be included by cutting back a previously fired crown. A cut is made into the crown with a diamond disc, the selected colour applied, air-dried, and then overlaid and refired. Similarly, the blue effect sometimes present on mesial and distal corners can be obtained by grinding ceramic away to the desired depth and painting the prepared surface with a blue wash, overlaying with a clear ceramic and refiring.

The use of clear ceramic and inlaid colours is particularly effective, and imparts a very natural appearance. Surface staining is less effective and does not give the three-dimensional effect achieved with internal segmented building. It is also vulnerable to abrasion during intraoral service, thus losing its effects.

However, surface stain can be added quickly and easily, being mixed with a liquid binder and painted onto the fired crown before glazing and is therefore popular.

### Aesthetic problems

#### Dark line at gingival margin

This was common with earlier metal–ceramic systems but has now been eliminated by the use of shoulder ceramic (Chapter 15).

#### Core shine

This usually occurs in cases where insufficient labial reduction has taken place during clinical preparation. The technician, in an attempt to bring the crown into line with the adjacent teeth, exposes the underlying core by grinding or is forced to cover it by insufficient dentine build-up. This results in an area of the crown that looks lifeless. Opaque ceramic must be covered by at least 0.5 mm of dentine ceramic to diffuse the reflected light from the opaque. Doing this though in the underprepared tooth results in a bulbous overcontoured crown with poor aesthetics.

The correct treatment is to ensure that a minimum of 1.2 mm is removed from the labial surface during preparation to allow enough depth of ceramic to create a lifelike aesthetic restoration. The metal substructure needs to be a minimum of 0.3 mm thick, the opaque needs to be a minimum of 0.3 mm which leaves only 0.6 mm for the dentine and enamel ceramics to create an acceptable result.

#### Shadowed regions

Shadowing occurs in areas where there is an excessive amount of dentine ceramic or in areas where there is not an opaque backing. Typically, in bridges these occur interstitially or at the cervical margin of pontics. In order to compensate for these darker areas of lower chroma, ceramics that have an increased opacity and chroma have been developed – these are known as *opacious dentines*. The opacious dentines can either be blended with conventional dentine powders or be applied in layers.

These ceramics can help considerably to increase chroma and to diffuse reflected light, hence improving the aesthetic result.

### Conclusion

With the advent of these new ceramics and by using a layered build-up technique it is now possible for the ceramist to control the reflection and scattering of light in a similar manner to natural teeth. With the use of opacious dentines, control over value and chroma is possible and life-like aesthetic restorations are now far more easily achieved. However, when patients move from one type of light to another, changes in apparent shade are inevitable. The most dramatic of these is the sight of metal–ceramic crowns in television arc lights!

### Malformed or missing teeth

The most common problems are:

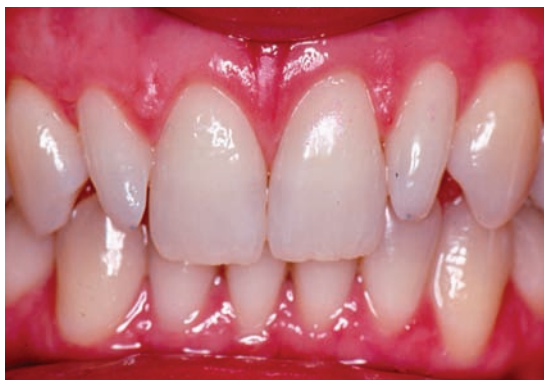- Peg-shaped upper lateral incisors
- Missing upper lateral incisors
- Central incisors lost through trauma

More extensive *hypodontia* and dental problems associated with *cleft palate* are considered in Chapter 20.

### Peg-shaped lateral incisors

The management options are:

- Persuade the patient that it is better to do nothing
- Reshape by veneers or crowns
- Extract and either open or close the space



(a)

### No treatment

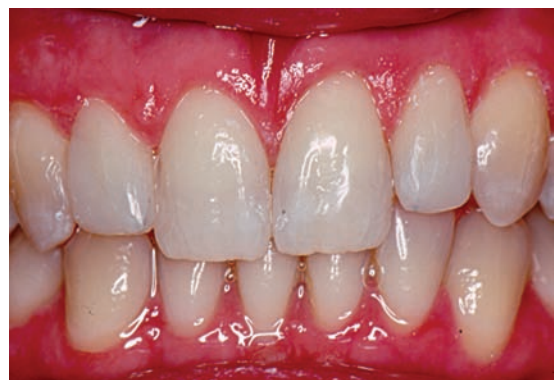Some individuals, particularly females, may become very concerned that their appearance is not 'conventional'. This was mentioned earlier in relation to shade. Slightly malformed teeth may not be noticed by the casual observer but are glaringly obvious to the patient who grimaces at herself close to the make-up mirror.

Minor discrepancies in tooth shape need to be put into perspective (tactfully) together with an explanation of the possibly deleterious effects of restorations and their need for periodic replacement. Often, patients will be reassured and elect to having nothing done.

### Reshaping

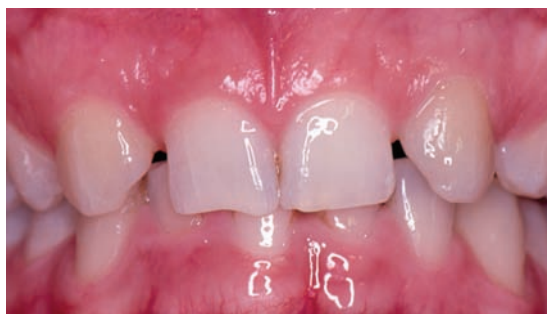The amount of natural tooth will have a bearing on the choice of treatment. Very small teeth will be impossible to prepare with sufficient remaining tissue to support a crown or a veneer. It is also problematic to increase the size of a tooth because this usually results in an unfavourable gingival contour.

Here the best solution will often be the use of acid etch retained composite to increase the incisal length and width of the tooth without encroaching on the gingival margin (Fig. 16.9). Some commercial products are supplied in a range of shades equivalent to the Vita shade guide together with opaque shades. This may mean a range of at least eighteen shades providing a comprehensive colour matching system. The possible disadvantage is that the material may need replacing in 5–6 years due to discolouration.

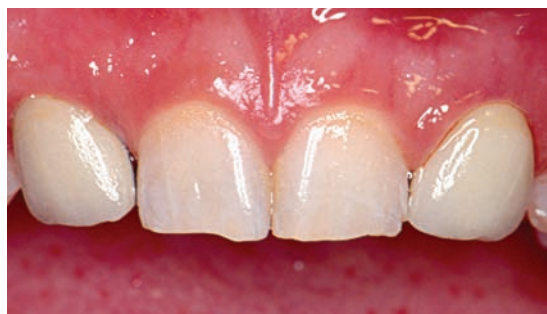

(b)

**Fig. 16.9** Peg-shaped lateral incisors. The appearance has been improved by the addition of acid-etch-retained composite. (a) Before treatment; (b) after treatment.



(a)



(b)

**Fig. 16.10** Prominent canines in the lateral incisor position that cannot be corrected effectively by veneering. Crowns are necessary to create less prominent teeth of the correct shape. (a) Before treatment; (b) after treatment.

Larger pegs can be veneered successfully to increase their size but again the gingival relationship will not be ideal and the patient will need to be taught careful flossing and brushing techniques.

#### Extraction

This would be the last resort and would be reserved for badly formed and displaced pegs. Orthodontics should be considered to either open or close the space. Space closure is probably more desirable since this avoids a prosthesis to replace the lateral incisor. However, the disadvantage is that the canine may be moved into a more prominent position and may require reshaping (see below).

#### Missing upper lateral incisors

Absent upper lateral incisors may result in retention of the deciduous canines and the eruption of the permanent canines into the lateral incisor position. Alternatively, the deciduous canines may be shed as normal and spacing results between the central incisors and the permanent canines.

The management options are:

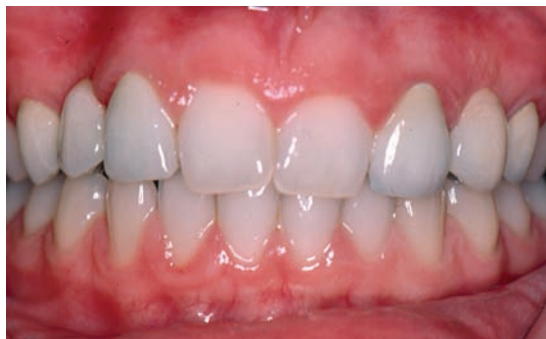- Reshaping the permanent canines to resemble lateral incisors
- Orthodontic treatment to retract the canines and bridges or implants to replace the lateral incisors
- Veneers/bridgework to correct the aesthetics without orthodontic treatment

#### Reshaping

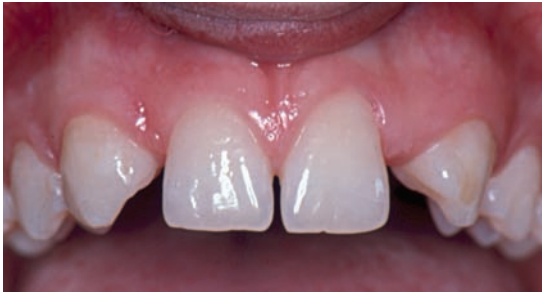This is the simplest option but carries with it the problem of making a large tooth look small. The incisal edge can be made square and level by either composite resin addition or ceramic veneer or in some cases, simply grinding the tooth.

This type of reshaping will remove the 'Dracula' appearance but will not change the bulk or prominence of the tooth which can be a problem if the canines are labially placed. Here to reduce the prominence of the tooth, a radical crown preparation is required to provide a flatter labial surface. Ideally, a post crown would provide the best appearance but elective devitalisation should not be prescribed without a strong indication. Even with a large labial reduction the ceramist will have considerable difficulty with shade control (Fig. 16.10).

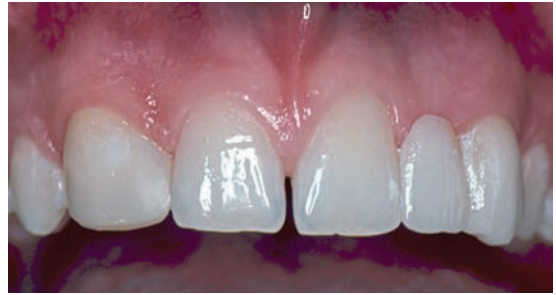The case shown in Fig. 16.11 had retained deciduous canines and the upper permanent canines had erupted into the lateral incisor position. The deciduous canines had to be extracted because of caries and root resorption. Two bridges were made to replace the missing teeth and the permanent canines were reshaped by crowns to resemble lateral incisors.



**Fig. 16.11** Missing upper lateral incisors with retained  $\underline{c|c}$  and the permanent canines in the lateral incisor position. The  $\underline{c|c}$  have been replaced with bridges and the  $\underline{3|3}$  have been converted to resemble lateral incisors by crowns. The underlying size of the canines restricts the reduction in width.



(a)



(b)

**Fig. 16.12** (a) Missing upper lateral incisors with uneven spacing; (b) the  $\overline{3|}$  has been recontoured with acid-etch-retained composite and the  $\underline{1|}$  has been replaced by a bridge retained by a ceramic veneer on  $\underline{13}$ .

Inevitably the size of the ‘new’ lateral incisors is dictated by the underlying canine teeth which cannot be prepared extensively to allow smaller crowns to be constructed.

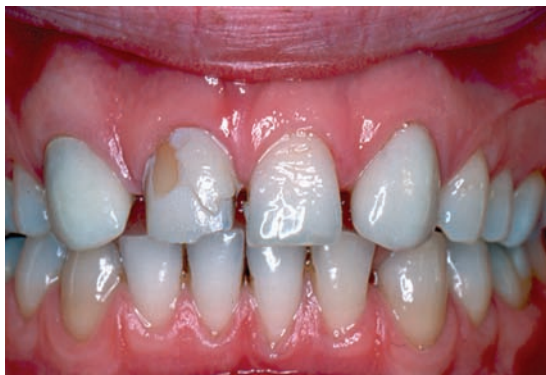### Orthodontics

In certain respects this is an ideal treatment because the canines will be moved bodily into their correct positions. Lateral incisors of the correct shape can then be made as bridge pontics, usually as resin-retained bridges (see Chapter 19). However, the disadvantages are that space will be needed for the canine retraction, usually by extraction of posterior teeth and fixed appliance therapy will be needed perhaps taking at least a year.

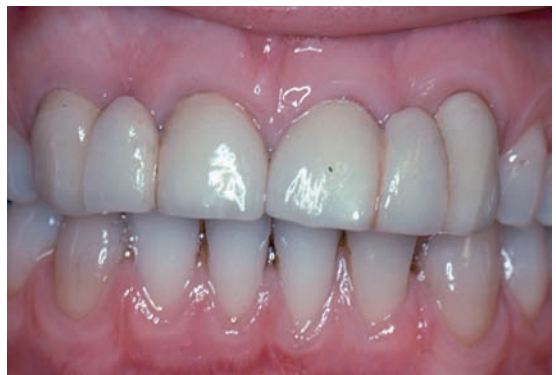### Veneers/bridges without orthodontics

This approach removes the need for prolonged treatment and the loss of more teeth. However, it will almost always be a compromise because of the limited space available for extra teeth. Figure 16.12 shows a case where there was enough space for a reasonable lateral incisor on the left side but the space available on the right is much smaller. The upper right canine was enlarged by means of acid etch retained composite whilst a veneer bridge (see Chapter 19) was made on the left.

Figure 16.13, on the other hand, shows a much more difficult case because the lateral incisor spaces are neither small enough to allow the enlargement of the canines nor big enough to allow full-sized lateral incisors to be made. The case was complicated



(a)



(b)

**Fig. 16.13** (a) Missing lateral incisors where there is restricted space for their replacement; (b) two three-unit fixed-fixed conventional bridges  $\overline{3-1|1-3}$  where the  $\underline{2|2}$  have been made to overlap the retainers to achieve extra width.

by the previous attempts to veneer the incisors and canines.

The lateral incisors have been made as wide as possible on two fixed prostheses by overlapping the central incisor and canine retainers. The preparation of the four teeth for crown retainers provided more flexibility in the final mesiodistal diameters of the new teeth.

### **Missing central incisors**

If the space has been maintained then these will fall under the treatment planning decisions discussed in Section IV. However, in a young patient it may be possible to move the adjacent lateral incisor into the space or, if the case has been neglected, the lateral incisor may drift forward. The conversion of the lateral incisor to look like a central incisor may be done by either a veneer or a crown. The disadvantage is the

gingival contour and its relationship where the larger crown or veneer joins the smaller root.

### **Malocclusion**

Whilst many malocclusions are corrected orthodontically in childhood, it is still common for adults to request the correction of crowding and other malocclusions. These patients often request rapid treatment and may not wish to wear orthodontic appliances. They usually expect their appearance to be corrected by crown and bridgework.

Notwithstanding their preferences, these patients need to be persuaded that orthodontic therapy will provide the better results in most cases. Irregular incisors are difficult to crown or veneer and such treatment results in teeth that have thick incisal edges and creates periodontal problems.

#### **Colour and Aesthetics – Summary**

Modern materials and techniques offer much scope for cosmetic dentistry. The artistic aspects of tooth colour and shape are more difficult to teach and come with experience.

Shade taking must be done in good natural light without the influence of strong colours.

Liaison with the technician must be good in respect of shade communication and reproduction.

Composite additions, ceramic veneers and bridgework each has its place in correcting aesthetics. Each is accompanied by its advantages and disadvantages and sometimes the treatment plan is a compromise between tooth conservation, the patient's aspirations and technical possibilities.

# Chapter 17

## Impression Materials and Techniques

The long chain of positive- and negative-dimensional pitfalls between completion of the preparation and the cementation of a cast restoration begins with the impression.

The choice of impression material, the management of the gingival tissues and the clinical technique all contribute to the accuracy of the final restoration.

An impression material should be:

- Accurate and dimensionally stable
- Easy to handle
- Pleasant tasting
- Compatible with blood and saliva
- Non-irritant and non-allergenic
- Tear resistant
- Compatible with model materials

The patient would like the material to taste pleasant and have a short setting time. Impression taking can be a messy procedure so the material should be easy to remove from tissues and clothes. It should not damage the oral tissues or the tooth and, very importantly, the material should not contain constituents likely to produce sensitivity reactions.

The operator's requirements are somewhat different. The material should be easy to mix with a working time that is long enough to allow it to be placed around a number of preparations before setting starts.

In order to reproduce the details of the preparation, it should flow well and have a low surface tension, so that it will wet the surfaces of the preparations. This is essential in order that the restoration will fit well and will not fail due to leakage or plaque accumulation.

Impression taking would be very easy if the materials were miscible with saliva and tissue fluid. Some of the more recently available materials are claimed to be hydrophilic, but currently the only material that is truly hydrophilic is the reversible hydrocolloid.

After removal from tooth undercuts the material must have a high elastic recovery to reproduce these areas and the rate of this recovery from deforma-

tion must be rapid (Chapter 9). Also, the material should not be excessively rigid. If it lacks elasticity, it may well be difficult to disengage from undercuts and could traumatise the soft tissues. A stiff material will also be difficult to remove from its model and stone dies may be damaged.

Perhaps the most significant properties for clinical success are dimensional accuracy and dimensional stability. All the elastomers set by a polymerisation reaction that results in shrinkage; this varies with the type of material. The result is a contraction towards the internal surface of the impression tray, assuming that the tray adhesive is strong enough to resist the forces.

With simple extra-coronal preparations this contraction does not present major problems since the die produced from the preparation will be slightly larger than the original preparation. Therefore, the restoration will seat on that preparation, but the width of the cement lute will be increased.

Greater problems exist with complex intracoronal features, such as slots and grooves. Here, the dimensional changes are much more complex and consequent variations result in either difficulty or failure of the restoration to seat completely.

The material should also have a high tear resistance, since once the impression has entered a gingival crevice, a thin area of material might well be damaged on removal.

### Impression Materials

A general classification of impression materials is given in Table 17.1. With the development of elastomers, the rigid materials, often used within a



copper ring, have fallen from grace almost completely, as have the techniques of direct wax pattern making in the mouth.

The irreversible hydrocolloids, the alginates, are excellent for preliminary impressions, but because of their dimensional instability, have no place as final impressions for crown and bridgework though they are satisfactory for partial and complete dentures. The reversible hydrocolloids, agar-agar, on the other hand, are excellent for the reproduction of detail and mix well with intraoral fluids. However, they require specialised equipment and must be cast immediately upon removal from the mouth.

The principal materials now used for fixed prosthodontics are the rubber-based *elastomers*. The currently available materials fall into three main groups:

- Silicones (polysiloxanes)
- Polyethers
- Polysulphides

The elastomers are generally available in one of four forms described as *putty*, *heavy bodied*, *regular* and *light bodied*, the basic difference between the four forms being the filler loading.

The silicone materials are divided into two separate subgroups:

- Condensation curing (Type I)
- Addition curing (Type II)

### Condensation silicones

Until the general acceptance of addition-cured materials, the condensation curing materials were very popular in general dental practice because of their clean handling and rapid set. They may come in all four consistencies, but the most popular are the putty and wash materials, the wash being light bodied. The active constituents are shown in Table 17.2.

The elastomer sets by a condensation polymerisation reaction with the formation of ethyl alcohol as a by-product. The alcohol subsequently evaporates causing further shrinkage over and above that of the polymerisation reaction. Shrinkage continues for several days with 0.5% occurring in the first 24 hours. This is significant if the technical laboratory is some distance from the practice. The greater setting contraction occurs in the light-bodied materials where the polymer is the largest component.

The light bodied material has the ability to reproduce the surface detail well, but has a relatively low

tear resistance and many of the materials are difficult to handle.

The setting reaction is temperature dependent with a marked reduction in both working and setting times in the presence of a relatively small increase in ambient temperature, particularly when the humidity is high. This can result in a material being manipulated at a time when it has already commenced its setting phase. This causes the development of setting stresses in the material that will be relieved after the removal of the impression. This, in turn, will lead to a restoration that, whilst fitting the die, will not seat satisfactorily in the mouth. Failures with these materials are more commonly associated with complex intracoronary preparations and bridgework.

### Addition silicones

These are now the most popular of the elastomers and their active constituents are shown in Table 17.2. The setting reaction here has no low-molecular-weight by-product which results in a material that shows little or no dimensional change. The shrinkage figures quoted are in the range of 0.05–0.07% at 24 hours.

However, a secondary reaction does take place if incomplete polymerisation has occurred, with the liberation of hydrogen gas. A number of the materials have finely divided palladium added that is supposed to absorb the hydrogen. Because of this, impressions should not be poured immediately, otherwise the liberation of hydrogen will result in a roughened die stone surface.

The material has low tear resistance and is prone to tear if engaged in deep undercuts or the gingival crevice; care is required on removal of the impression. It is also particularly temperature sensitive.

The other main disadvantage is that current tray adhesives are not very effective and this can result in the impression material pulling away from the tray in places. This is not necessarily always visible and consequently it is only when the restoration is tried in and does not fit that the problem is seen. It is essential to use the adhesive in conjunction with a perforated tray.

The addition silicones have poor wetting characteristics and are also hydrophobic; this may lead to poor reproduction of detail and may also make model pouring troublesome. Wetting agents have been developed for both intraoral and laboratory use to overcome this problem though some have limited effectiveness.

**Table 17.1** Types of indirect impression materials

Rigid	Elastomeric					
Composition	Hydrocolloids		Polysulphides	Polyethers	Silicones	
	Irreversible	Reversible			Type I	Type II
	Alginate	Agar-agar			Condensation cured	Addition cured

The excellent dimensional stability of addition silicones often results in very accurately fitting castings that may prove difficult to seat, and the master die should be treated with the appropriate die spacer (see later).

### Polyethers

These materials have a restricted but enthusiastic following and when used with care produce very satisfactory results. Their components are shown in Table 17.2. They are usually purchased as a two paste system of a regular consistency.

The original materials, whilst apparently being very dimensionally stable, were affected by humidity and showed variable unpredictable shrinkage when a diluent paste was added. Modifications in formulation have improved this, but at the expense of the handling properties.

Some cases of allergic reactions to the material causing a burning sensation in the tissues covered by the impression and, in severe cases, marked erythema have been reported. The reformulation has reduced this although some patients still comment on the burning sensation when the impression is being taken.

The tear resistance of the material is similar to that of the silicones but its stiffness is considerably higher. This stiffness can result in problems during removal

of the impression from the mouth which can also be impeded by the hydrophilic character of the material; it tends to 'stick' to the mucosa. It is advisable to have a double-spaced special tray so that there is more material to flex to facilitate the removal of the impression. If a stock tray is used, then this should have sufficient rigidity to prevent distortion during removal of the impression from the mouth.

The stiffness may also cause difficulty in the laboratory, since it is relatively easy to damage the dies on removal of the impression, particularly if they are narrow. Lower incisor crown preparations can be a particular problem.

The material is quite temperature sensitive and may set rapidly on a hot day. This may be critical since the working and setting times of these materials are the shortest of all the elastomers.

### Polysulphides

These are the oldest of the elastomers and in spite of their smell and dirty handling are still occasionally used because of their reliability and strength. However, they have, to a great extent, been displaced by the addition silicones.

The components are shown in Table 17.2. The material is usually used as a combination of heavy and light consistencies, with the heavy-bodied version

**Table 17.2** Components of elastomeric impression materials

Type	Base	Catalyst	Filler
Type I silicone	Dimethyl siloxane	Stannous octoate	Copper carbonate or silica 2–8 µm
Type II silicone	Dimethyl siloxane	Chloroplatinic acid	Silica
Polyether	Polyether – ethylene imine terminated	Dichlorobenzene sulphonate	Silica
Polysulphide	Polysulphide (Thiokol)	Lead dioxide Dibutyl phthalate	Titanium dioxide, silica or copper carbonate

being particularly difficult to mix. There is also a regular consistency material. It is the lead dioxide that makes the material unpleasant to use.

The setting reaction is condensation polymerisation with the formation of water as the by-product. Impressions should be kept in a sealed moist bag to reduce the shrinkage that would be caused by the evaporation of the water. There is a small setting contraction of between 0.13 and 0.25% at 24 hours, with little further shrinkage after this.

On the plus side, the material has a much higher tear resistance than the other three elastomers, but it does not show such good recovery from deformation. The working and setting times are the longest of all the elastomers and it appears to be the least sensitive to temperature changes.

## Impression Techniques

### Management of the gingival tissues

This and excellent control of saliva are the keys to successful impression taking.

The first requirement is that the tissues should be in good health and undamaged. Careless preparation, with abraded gingivae, will repay the operator with a poor impression. Poorly fitting provisional restorations will accumulate plaque and cause gingival enlargement and bleeding.

In the interests of periodontal health, crown margins should be at the level of the gingival margin and not be placed in the gingival crevice unless aesthetics will be improved by such location. Gingival margins should be recontoured if the preparation has to enter the crevice by more than 0.5 mm, perhaps where there is a deep core. Impression taking is made easy by supragingival margins.

If there are problems with bleeding tissues, the impression should be abandoned at that visit. Accurately fitting provisional restorations should be placed, perhaps cemented with a periodontal dressing material, and the impression taken on a subsequent visit when the gingivae have recovered.

### Gingival retraction

To provide clear definition of the finishing line, the gingival tissues must be displaced from the preparation and any exudate from the crevice controlled. There are several types of material that may be used for this.

Mechanical displacement using a variety of cord is probably the most popular. Cords come in two

forms, *braided* and *twisted*. The braided form is easier to place and may be supplied in several sizes. The twisted type has a tendency to become untwisted during placement. There are also elasticated rings that may be pushed over the preparation and into the crevice.

All the proprietary brands may be impregnated with agents to control oozing from the crevice; these may be vasoconstrictors or styptics. Epinephrine (adrenaline) hydrochloride is the most common of the first group, but must be avoided in certain patients who have either cardiovascular problems or are sensitive to it. Aluminium trichloride, alum, is a common styptic as is ferrous sulphate. As well as being impregnated in the cord, retraction solutions may be purchased separately. Care must be exercised in their use, since excess application can cause irreversible damage to the tissues, particularly gingival recession.

### Cord placement

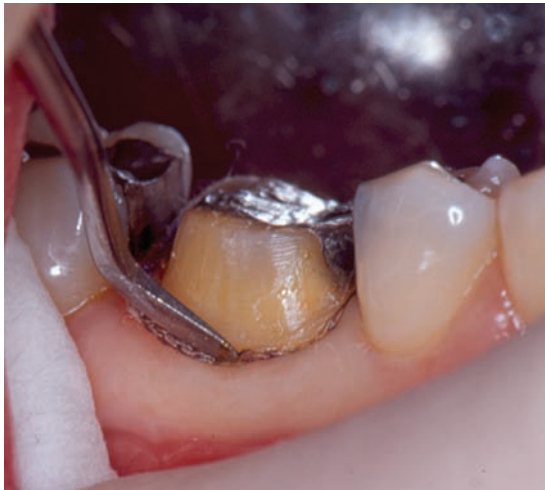Care must be taken in placement of the cord to avoid damage to the epithelial attachment. The teeth must be isolated by cotton wool rolls and a saliva ejector and blown dry. The cord is laid around the gingival margins of the prepared tooth. The width of the cord should match the depth of the crevice and, if necessary, a multi-stranded cord can be split into several thin strands. It is better, though, to have cords of different diameters available.

The cord is pressed gently into the gingival crevice using a small flat plastic instrument, keeping the cord between the blade and the tissue (Fig. 17.1). A local analgesic is often advisable as the procedure can be uncomfortable.

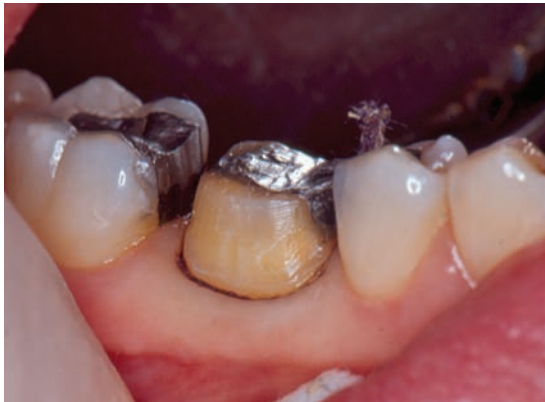The cord should not be left in place too long since permanent recession may be caused. About 5 minutes is necessary to provide optimum retraction, maintaining saliva control all the time.

If the cord does not obstruct the margins of the preparation, it can be left in place whilst the impression is taken. If this technique is used, it is most important to remember to remove the cord before the patient leaves the surgery! To remove the cord after the impression has been taken, it should be first moistened with water to avoid damaging the friable gingival tissue.

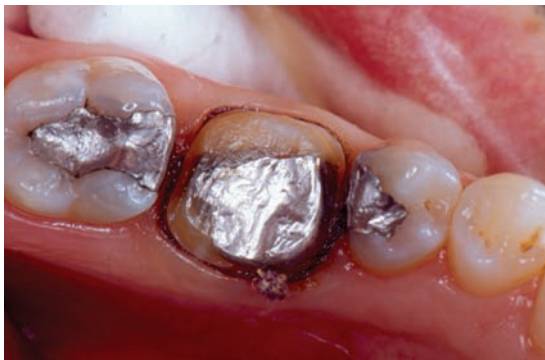It is more common, though, to remove the cord when the impression material is ready to syringe around the preparation. The cord must be removed very gently to prevent the initiation of bleeding or oozing. It is essential that the preparation site and



(a)



(b)



(c)

**Fig. 17.1** (a) Braided gingival retraction cord being inserted into a gingival crevice, (b) and (c) Insertion completed. Note the lack of gingival trauma following the preparation of the full crown.

the surrounding area are dry and free from contaminants prior to impression taking as any residue may affect the impression material and the detail of the impression.

It is sometimes possible to dispense with retraction and blow the light bodied material into the gingival crevice with compressed air. This is quite effective, but may result in a very thin section of rubber because of the lack of retraction, and this is liable to distort or tear.

### Electro-surgery

This technique involves the use of a high-frequency electric current that may be used to either coagulate bleeding tissues or fulgurate (spark drying by ionisation). When used carefully, it can produce a very clearly defined margin.

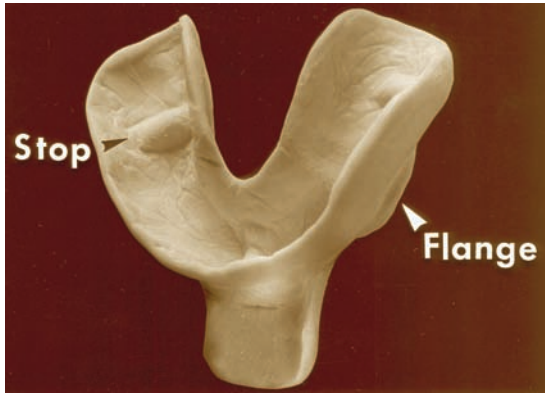
There is a risk, however, that the misuse of this technique will result in serious gingival tissue damage, particularly if the tissues are inflamed and oedematous at the time of surgery. Its main advantage is the haemostasis obtained.

### Special trays

The main advantage of a correctly made special tray is that it ensures a uniform thickness of the impression material thereby reducing risk of uneven distortion. The tray will also confine the material, assist in its adaptation to the teeth and prevent it escaping into the rest of the mouth. The thickness of the tray material can be controlled to give good rigidity thus avoiding flexing and distortion of the impression on removal from the mouth. This last characteristic is an important factor in the choice of stock/disposable trays.

Adequate spacing should be provided between the tray and the teeth to accommodate a reasonable volume of impression material and stops should be placed around the arch to ensure that the tray locates accurately onto the teeth. It should be extended to about 2 mm below the gingival margin of all teeth and should wrap around the end of the alveolar ridge to confine the material to the tray (Fig. 17.2).

The weak link may be the tray adhesive. Those used for the polysulphides are very good, but those provided for the addition silicones are poor and perforations should be incorporated in the tray to assist retention. Whichever type is used, it must be given adequate time to dry before the material is mixed; this may be as much as 15 minutes.



**Fig. 17.2** Special tray with posterior flanges to aid removal and occlusal stops to locate it on the teeth.

Full arch, rather than sectional, impressions are desirable for accuracy of occlusal contacts.

### Handling the materials

There are three main ways in which impression materials may be used:

- Putty and wash
- Regular/universal single mix
- Light- and heavy-bodied double mix

#### Putty and wash technique

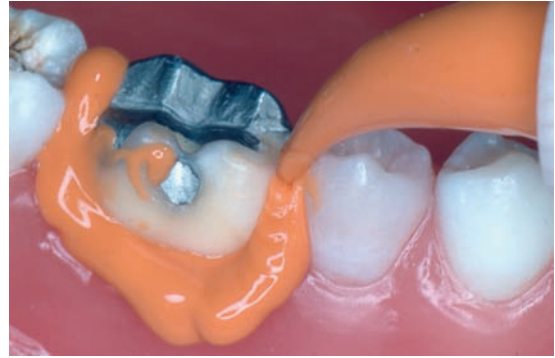
This technique uses a very stiff putty within a stock tray instead of a special tray, together with a fluid, light-bodied perfecting wash. Care is needed in tray selection because if pressure is used to seat the tray, some stock trays will distort. On removal of the tray, recovery of the distortion will distort the impression.

Condensation and addition silicones are the only successful materials that have been produced for this technique. The technique has the possible advantage that no special tray is required, but there are dangers of uneven shrinkage setting up stresses within the material. The later release of the stresses leads to dimensional inaccuracies.

Putty and wash materials may be used in one-stage or two-stage techniques.

#### One stage

Here, both the putty and wash materials are fluid at the same time. Following mixing, the wash is syringed



**Fig. 17.3** Syringing the light-bodied material around the gingival margin. Care must be taken to apply the material to the tooth surface so that air does not become trapped.

around the preparation, ensuring that the nozzle of the syringe remains within the exuding material to reduce the risk of air blows. Syringing should start at the distal margin of the preparation and brought forward (Fig. 17.3). It is necessary to cover the preparation and the occlusal surfaces of the other teeth with a thin film, the latter being recorded for occlusal registration.

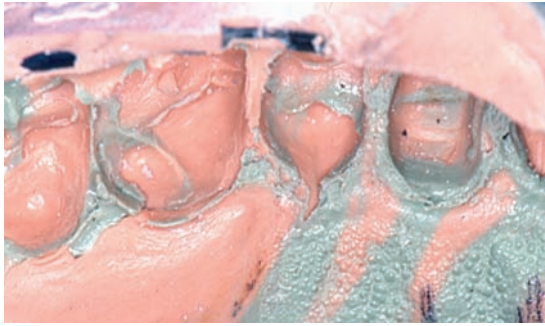
The putty is loaded into a rigid stock tray as soon as the syringe has been filled, and is inserted into the mouth immediately the wash is in place. All these materials are very rapid setting and working time is exceptionally short.

Considerable pressure will be required to seat the tray because of the stiffness of the putty. It is also important to insert the tray in the long axis of the preparations. An oblique seating direction will displace the putty away from the teeth and because of its high viscosity it will not flow back around the teeth resulting in *flow failure* (Fig. 17.4). The result is often called incorrectly *drag marks*, but 'drags' are caused by the withdrawal of a rigid impression material from an undercut or the early removal of an elastic material from an undercut before it is fully set.

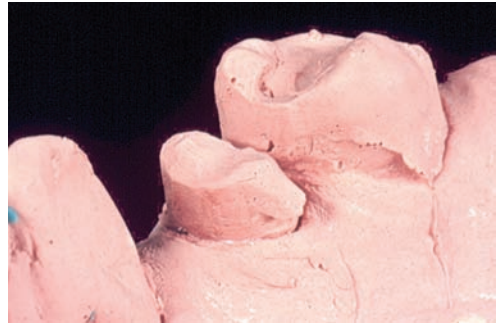The tray and impression material must be supported under moderate pressure until the materials have set since disturbances will result in distortion.

#### Two stage

This technique is not recommended. Here a putty 'tray' is prepared before the wash is mixed. The stock tray is first filled with the putty and seated home. A polyester sheet may be placed as a spacer on the sur-



(a)



(b)

**Fig. 17.4** (a) Flow failure on the palatal aspect of the upper second premolar. There is also failure of the light bodied material to merge with the putty. The light bodied was setting before the putty arrived, (b) Model showing the result of flow failure on the palatal aspects of the premolar and molar.

face of the putty before insertion or, alternatively, the tray may be rocked to provide the space necessary for the wash.

Once the putty has set it is removed, washed and dried and sluice ways cut in the buccal and lingual aspects in the areas adjacent to the preparation. Any material remaining approximately is also removed. These modifications allow escape of excess wash material in the second stage of the technique. The putty must be clean and dry and uncontaminated with saliva.

The perfecting wash is syringed around the preparation and all occlusal fissures to form a thin film over the area where fine detail is required. The putty 'tray' is then resealed and the wash and putty will unite chemically as the wash sets.

The results using this technique can be good but a number of problems may arise:

- Saliva interposed between the putty and the wash
- Build up of wash in certain parts of the occlusal section of the impression that results in an incorrect occlusal relationship. This usually follows inadequate sluice way preparation in the primary putty impression
- Displacement and distortion of the tray during its second seating. This can result in uneven distribution of the wash and, worse, distortion of the tray itself

### Special tray technique

The putty/wash techniques involve the production of a close fitting 'tray' in putty, but this is bulky and can

introduce errors with incorrect seating. A special tray reduces the volume of impression material used and is easier to handle.

### Two mix technique

The materials used are light and heavy bodied with the heavy bodied material acting as a support for the fine detail reproducing light-bodied material. The light bodied material is syringed around the preparation and onto the occlusal surfaces of the other teeth, and the heavy-bodied material is loaded into the special tray that is seated, again, in a direction parallel to the long axes of the teeth. The tray must be located accurately and held immobile until the material has set.

If the tray is not placed as soon as the light-bodied material has been syringed, there is a risk of saliva contamination between the materials and impression failure. Impressions of the lower molars are the most vulnerable, with the tongue often becoming interposed at the crucial stage.

This problem may be reduced by not introducing the light-bodied material until the heavy-bodied material is almost mixed. However, too much delay may mean handling the material beyond the point when it has commenced its setting phase.

Quite heavy pressure should be applied for about the first 15 seconds after insertion to ensure that the material flows and, at the same time, it is important to ensure that the stops on the fit surface of the special tray locate accurately on the surfaces of the teeth. Without the stops, the tray will come into contact with tooth surface over a large area, and even in the

area of the preparation, with a consequent failure of the impression.

### Single mix technique

The special tray technique may be used with materials of a single, regular, or medium, bodied consistency using the same mix in both the tray and the syringe. Whilst this can be successful, it is sometimes difficult to syringe the material because it is stiffer than the light bodied type, and the tray portion can flow rather freely because it is more fluid than the heavy bodied type. This technique is commonly used for impressions for partial dentures.

### Removal of the impression

It is always tempting to remove the impression as soon as the outer aspect of the material has set. This may have disastrous consequences since the light-bodied materials set at a slower rate than the heavy-bodied materials. This is especially the case with some addition silicone materials where there can be a difference of up to 1½ minutes between the setting times of the heavy- and light-bodied materials. Premature disturbance of the materials will result in the distortion of the impression and dragging of the material at the margins of the preparation.

The best indication that the material has set in the mouth is when the material has set on the mixing pad, and a timer may give additional guidance. Ambient temperature and humidity cause large deviations from the manufacturers' predicted behaviour, and it is better to leave the material in place for as long as possible.

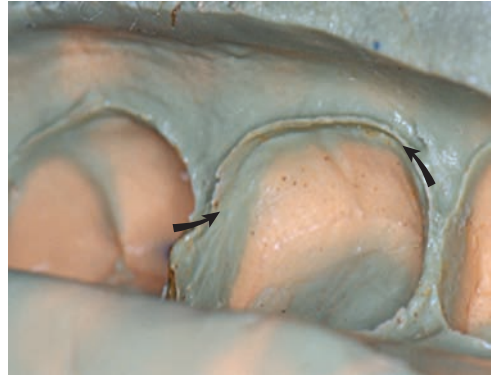
The impression should be removed without rocking or shaking. One sharp pull in the line of insertion of the preparations is the ideal. This is assisted by having flanges at the side of the special tray, rather than using the handle.

### Assessment of impressions

After removal, the impression should be thoroughly washed to remove all contaminants and then dried. Careful examination should be made in good light, using a hand lens or low-power microscope.

A clear outline of the finishing margin all round the preparation should be visible with a small extent of impression material beyond it (Fig. 17.5).

There should be no air blows on the margin but sometimes small air blows on the fit surface may be accepted. It is important to ensure that the material has not pulled away from the tray. This should be



**Fig. 17.5** An impression of a chamfer finishing line (arrowed). Clarity here is essential for the technician to be able to see where to finish the waxing. There should be registration of uncut tooth beyond the finishing line. The light-bodied material has merged properly with the putty.

apparent at the periphery of the impression where it is easy to see.

If there is any doubt about the accuracy of the impression, it may be possible to pour it immediately and examine the preparations. This may save time and money, but should be done in liaison with the technician, to ensure that the appropriate casting technique is used.

### Decontamination

The dentist has the responsibility for ensuring that impressions, models and other equipment passing to the laboratory are not contaminated with body fluids or bacteria from the patient. This is one of the principles of that should be enshrined in the dentist's *prevention of cross infection* policy.

Several agents have been recommended and some lead to dimensional changes in the impression material and others, such as glutaraldehyde, present risks to the dentist and his team.

Currently, the recommendation is for immersion of the impression, etc., in a 1% sodium hypochlorite solution for 20 minutes. Items coming from the laboratory also need decontamination. It should be remembered that it is chlorine from the sodium hypochlorite which is the disinfectant and this is used up quickly. This means that each impression should be immersed in a fresh solution of the disinfectant. It is desirable that the bagged impression be labelled with the date and time of disinfection and also the type of disinfectant used. This will reduce the risk of the

laboratory carrying out a similar procedure. The rationale for this is that prolonged exposure to disinfectants can have an adverse effect on the impression material. It is essential that once disinfection has been completed that the impression material is thoroughly washed since residue from the disinfectant can be deposited on the surface once the impression is dried. This in turn will affect the surface of the model which is poured.

## Model Construction

The laboratory should always be informed as to which type of impression material has been used so that the production of the working die may be done correctly. As mentioned earlier, addition-cured silicones may release hydrogen if cast too soon and this will affect the model surface. If metal-plated models are required, the process will be affected by the impression type. Both types of hydrocolloid material are adversely affected by water loss, and therefore must be cast as soon as possible or kept in a humidifier.

In order to improve the abrasion resistance of the model, stone die and plaster *hardeners* may be used. These are monomers in solution that are simply painted directly onto the die and surrounding areas. They harden, seal and waterproof the surface, and protect the definition of the margins without altering the dimensions of the die.

*Die relief* or *spacer* solutions can be used to increase the size of the die by a controlled amount. The claimed advantages are:

- Surface roughness is reduced, making pattern removal easier
- Space is created to accommodate the cement lute
- Adjustment can be made for dimensional problems in the investment (This applies to the ceramic bonding alloy investments.)
- The casting is larger in the case of a crown or smaller in the case of an inlay; therefore, it seats more easily clinically

The decision to use die spacers should be made jointly between the clinician and technician since the amount of relief required will have to match the dimensional changes of the impression material. A very accurate material, such as addition-cured silicone, ought to have die relief used on its models. With materials having higher shrinkages, such as condensation silicones, die relief would create a very loose restoration.

Two thicknesses are available, coloured gold or silver, and the application of four alternate coats increases the die by 25  $\mu\text{m}$ . The die spacer should not be used within 0.5 mm of the margins of the preparation.

## Dimensional changes associated with indirect restoration construction

Each stage in the construction of an indirect restoration is accompanied by dimensional changes, either expansion or contraction. Each of the changes must be controlled or counterbalanced such that when the restoration is fitted the interfacial gap between tooth and restoration is of the order of 25–50  $\mu\text{m}$ .

The stages and their dimensional changes are as follows:

- *Impression* – polymerisation shrinkage of elastomer
- *Casting model* – hygroscopic expansion of model plaster
- *Waxing* – expansion and contraction of the wax on heating and cooling
- *Investment* – hygroscopic expansion on setting and thermal expansion on heating in the furnace
- *Alloy* – expansion on heating, contraction on cooling
- *Ceramic* – contraction on firing

The major predicted and counterbalanced process is alloy casting. The alloy expands on heating and will contract after casting. Since the casting is done at a high temperature, the investment mould will have already expanded. The casting shrinks on cooling to what will be its final dimensions. Dimensional changes of the investment must balance the behaviour of the alloy and may be altered by:

- Hygroscopic expansion – mould placed in warm water on initial set
- Thermal expansion – gradual heating increases this
- Alteration of the powder/liquid ratio
- Lining (non-asbestos) of casting ring to permit free expansion

Alloy manufacturers recommend appropriate investments and how these should be treated to produce an accurate casting with their particular alloy.

If used correctly, die relief offers an opportunity to balance impression material changes with those that result finally from casting the alloy or firing the ceramic.



**Impression Materials – Summary**

The material of choice for one or two preparations is addition-cured silicone in a putty/wash technique. Polyethers are satisfactory as heavy/light bodied or regular bodied in a stock tray.

For multiple preparations, consider a special tray with a heavy-bodied/light-bodied technique.

Gingival management should involve supragingival margins wherever possible, no trauma during preparation and careful use of retraction cord and solution.

Complete moisture control is essential.

Syringe the light bodied material with the nozzle close to the preparation to avoid air inclusions

Insert the tray in the long axis of the preparations to avoid flow failure.

Remove with a single short, sharp tug and avoid rocking.

Check that the impression is free from airblows, flow failure (drag marks) and material discontinuities.

Decontaminate the impression before it leaves the surgery.

# Section IV

## Fixed and Removable Prosthodontics



## Chapter 18

# Diagnosis and Treatment Planning for Fixed and Removable Prosthodontics

Here we consider the possible consequences on the remaining dentition of the loss of teeth, whether to replace them or not and the general approach to the choice of a prosthetic replacement.

### Consequences of Tooth Loss

No matter how good our preventive programmes and conservation skills, teeth will still be lost as a result of caries, periodontal disease and traumatic injuries. The consequences of the loss of a tooth or several teeth will vary from patient to patient, but in general the following are possible:

- Tilting, drifting and rotation of adjacent teeth
- Overeruption of opposing teeth – loss of occlusal stability
- Increased plaque accumulation and periodontal disease
- Abnormal sites for carious lesions
- Damage to remaining teeth due to increased function – tooth wear
- Loss of masticatory efficiency
- Loss of aesthetics
- Speech problems
- Alveolar resorption
- Loss of support for soft tissues

The principal effects are summarised in Fig. 18.1.

### Loss of occlusal stability

The extent to which this may occur depends upon the original tooth relationships. The teeth around a single unit space may well have stable contacts such that no deterioration occurs (Fig. 18.2). In other cases, there may be slight changes in tooth position resulting in less than perfect relationships but not necessarily requiring restoration of the missing teeth (Fig. 18.3).

However, overeruption and drifting may be dramatic (Fig. 18.4). The changes in tooth positions may lead to abnormal functional relationships such as non-working interferences in protrusion and lateral

excursions, and pre-centric prematurities. Space for tooth replacement may be restricted.

### Loss of masticatory efficiency

Whilst the loss of a single tooth is unlikely to have any significant effect on mastication, the loss of two or more in the same quadrant would probably require the patient to modify his chewing pattern to maintain effective function. It is unlikely that this would be noticed and, even with many missing posterior teeth, the vast majority of patients will continue with a normal diet.

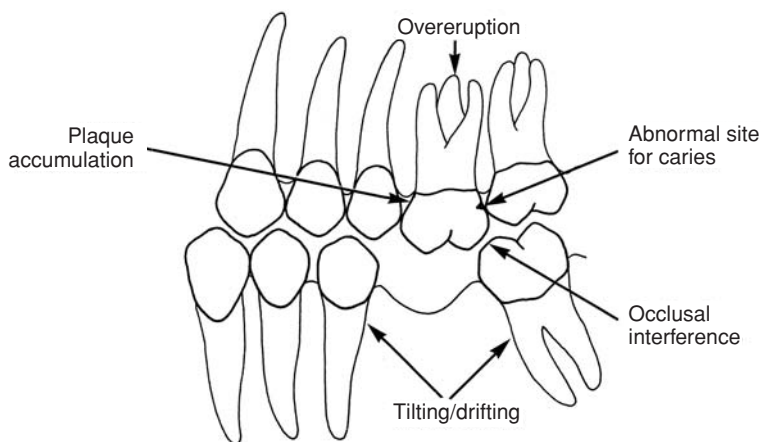
However, once a substantial amount of posterior support is lost, mastication will be transferred to the anterior teeth that have a narrow occlusal table making them unsuitable for grinding. The consequence will often be tooth wear or *tooth surface loss* (see Chapter 25). A typical case of anterior tooth surface loss following loss of posterior teeth is shown in Fig. 18.5.

### Increased plaque accumulation – caries and periodontal disease

The opening of contacts by tilting, drifting and rotation into an edentulous space may encourage food packing and plaque accumulation that in turn may initiate or increase the progress of periodontal inflammation. The same applies to the overerupted tooth where embrasures and contact relations are changed to an unfavourable relationship for natural plaque control.

Tilted teeth may be more vulnerable to periodontal breakdown due to unfavourable loading from the occlusion.

Caries too may be initiated by plaque accumulation in poorly accessible areas, but of course this disease



**Fig. 18.1** Schematic diagram of the consequences of tooth loss.

also requires a carbohydrate substrate. Therefore, the overall caries rate will be of importance in predicting the initiation of new carious lesions. In the event of new caries, because the contact area of an overerupted tooth will be resited to an area of thinner enamel, the tooth can be more vulnerable to carious spread.

These effects are not absolutely certain and other factors such as the patient's diet and plaque control effectiveness will be important. In a mouth with a low caries rate and good oral hygiene the effects of tilting, rotation and drifting may be minimal.

### Aesthetics, speech, alveolar resorption and soft tissue collapse

Losing a front tooth clearly affects aesthetics but a posterior tooth is not usually considered essential for

good looks. This of course varies according to the social perceptions of the patient's social group or occupation. Perhaps an actor or public speaker may be more concerned about the loss of a premolar or molar.

Speech may be affected, particularly in respect of anterior tooth loss. There may be lisping or spitting on speaking. However, these effects are not often found because of the general ability of the patient to adapt to such changes.

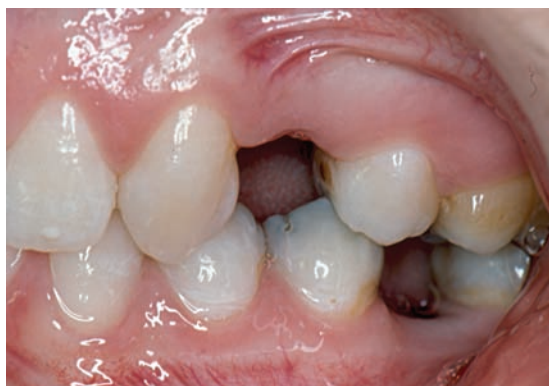Alveolar resorption is a natural consequence of tooth loss, there being no need for the bone if there is no tooth and periodontium to support. Both intra- and extraoral soft tissues may collapse or spread into the space. The tongue will spread laterally and the perioral soft tissues may collapse inwards. This latter effect may affect aesthetics considerably, particularly in middle age and after, when muscle tone is reduced.

### Effects of tooth loss – summary

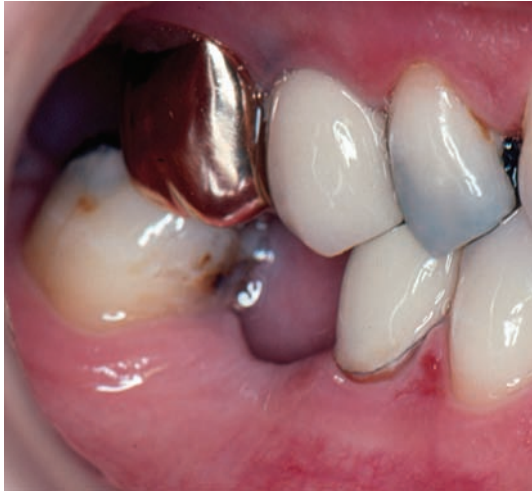As with many other biological processes the effects of tooth loss are often unpredictable. Although the list of possible problems is large, many patients do not exhibit any of these and in others the effects may be minimal. Clearly, the more teeth that are lost, the greater the possibility of problems. The most important are those that could induce further pathology and deterioration of the remaining dentition.

### The Replacement of Missing Teeth

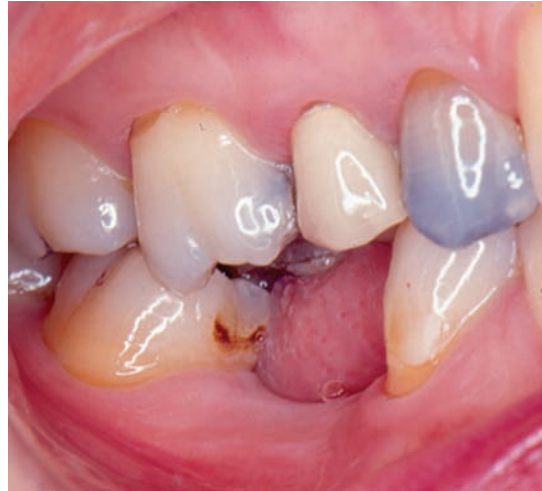This section must open with the statement that *not every missing tooth needs to be replaced*. This might



**Fig. 18.2** Edentulous spaces at  $\bar{4}$  and  $\bar{6}$  where tooth relationships have remained stable.



(a)



(b)

**Fig. 18.3** Slight deterioration of occlusal relationships around missing molars but not indicating tooth replacement.

come as a shock to a well-motivated patient who has invested much time and trouble in attending for prolonged but ultimately unsuccessful endodontic therapy, only to learn that the resulting space will remain unfilled!

Such a patient needs to be informed that all methods of replacing missing teeth carry with them the possibility of causing further damage to the dentition and other problems.

On the other hand, there are obviously several potential benefits to be gained from tooth replacement:

- Restored aesthetics
- Restored function
- Prevention of deterioration of the remaining dentition

Of these, the patient will be highly motivated to the restoration of aesthetics but might need some convincing as to the value of the other two, particularly the last. From the treatment planning viewpoint, the restoration of function and the maintenance of the remaining dentition will need to be balanced against the possible harm that may be induced by the provision of a prosthesis (see later).

Missing teeth may be replaced by:

#### *Fixed prostheses – bridgework*

which may be

- Resin retained (*adhesive*)
- Crown retained (*conventional*)
- Endosseous implant retained

#### *Removable prostheses – partial or complete dentures*

which may be

- Tooth borne
- Tissue borne
- Implant borne
- All three combined

The detailed indications, contraindications, design and construction aspects of the above will be considered in the subsequent chapters (Chapters 19–26) but the general aspects of each will be considered here.

### The choice of prosthesis

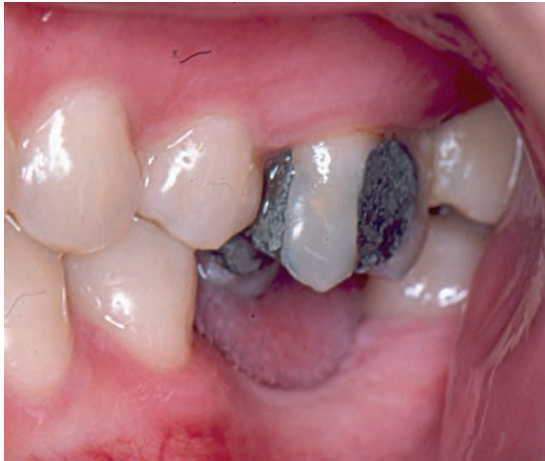Once the decision to replace a missing tooth or teeth has been made, many factors will be involved in choosing the appropriate prosthesis:

#### *General factors*

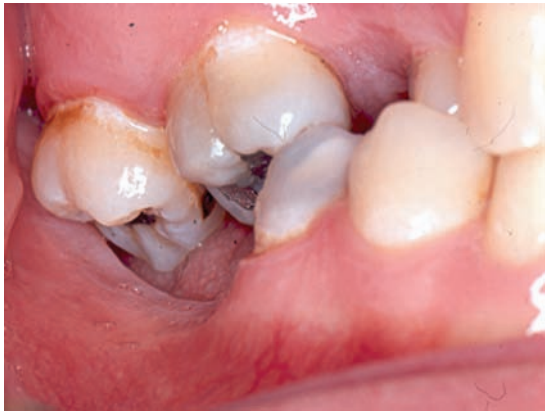- Patient aspirations and motivation
- Age and general health of the patient
- Ability and training of the dentist
- Ability and training of the technician
- Clinical and laboratory facilities available
- Economic factors

#### *Intraoral factors*

- Restorative condition of the dentition, in particular the abutment teeth
- Number of missing teeth and their location
- Tooth relationships – the occlusion
- Periodontal condition, caries and oral hygiene

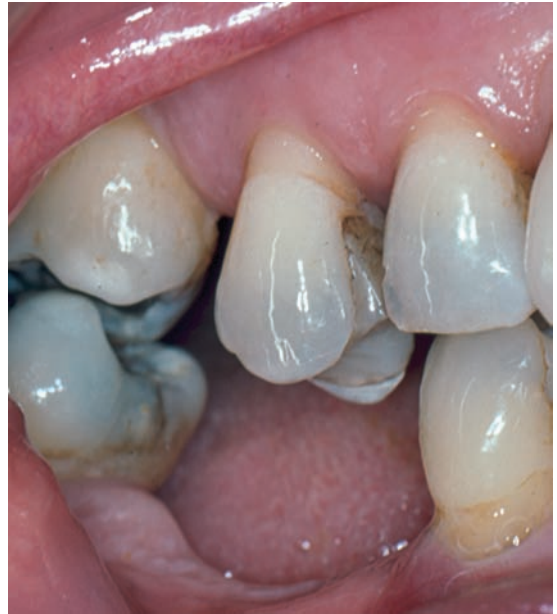

(a)

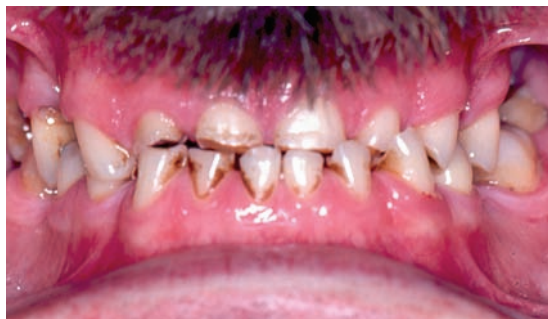

(c)

**Fig. 18.4** Edentulous spaces with associated deterioration of occlusal stability which has restricted the space for replacement of the missing teeth.



(b)



**Fig. 18.5** Loss of posterior support has resulted in anterior tooth surface loss due to changes in chewing pattern.

- The presence of an existing partial denture
- Alveolar bone volume and position

### General factors

#### The patient

The patient's prime position in the formulation of a treatment plan was discussed in Chapter 1 and these same principles apply here. A patient with low motivation, who is unable to attend regularly or who cannot for whatever reason be treated 'normally', should have a simple treatment plan. In the context of the choice of a prosthesis, this will usually mean a partial denture.

There should be no general upper age limit affecting the choice between a bridge and a partial denture but age may bring with it some restrictions that affect the delivery of dental care. The influence of the medical history in the drafting of a treatment plan and its delivery was discussed in Chapter 4.

Young patients will have immature dentitions with large pulps and unstable gingival margin position and will not usually be suitable for bridgework. Also, they may be involved in contact sports that again would contraindicate bridgework. Continuing growth contraindicates implants.

*The dentist, the technician and their facilities* – The construction of fixed prostheses requires excellent clinical and technical skills and appropriate facilities. Whilst some aspects of the construction of partial dentures require similar skills, in general this line of treatment is usually simpler and less demanding. It may also be that the consequences of a poorly constructed partial denture will be less harmful to the dentition than those of a poorly constructed bridge. At least the partial denture can be removed for cleaning and the tooth preparation for it is usually minimal.

*Economic factors* including state or private insurance schemes influence the delivery of advanced restorative care to a large degree. Endosseous implant retained prostheses are outside the scope of some schemes and are outside the financial resources of many patients. Fixed bridgework is also affected, though to a lesser extent, whilst partial dentures sometimes seem to be regarded as the bargain basement treatment; this attitude somewhat devalues the skills and techniques required for their proper construction.

### Intraoral factors

#### Restorative condition of the dentition, in particular the abutment teeth

The provision of any prosthesis should be against a background of a stable and well-restored dentition. The presence of active caries or periodontal disease ought to preclude the construction of a prosthesis that should wait until intraoral conditions are suitable. A prosthesis may aggravate a pre-existing condition and make things worse.

However, delaying the construction of a prosthesis may not always be possible, for example when the patient requires the restoration of aesthetics. In these circumstances it is necessary to make a prediction of the outcome of the pre-prosthetic periodontal and restorative therapy. If this prediction is guarded,

it would be acceptable to construct a simple intermediate partial denture whilst the mouth is being stabilised. If the dentist has more confidence in the outcome then provisional bridgework could be constructed pending stabilisation of the rest of the mouth.

The condition of the abutment teeth is a major consideration in the choice of prosthesis. Bridgework requires biologically and structurally sound teeth of good prognosis to support and retain it. Each tooth should have a healthy periodontium, even though this can be reduced through previous periodontal disease. The pulp should be unquestionably vital or the tooth should be properly root filled with no apical pathology. There should be enough sound dentine or enamel to support the chosen retainer.

Whilst the abutment teeth are also important in the support and retention of a partial denture, the alveolar ridge can often be used to supplement them. Their condition therefore will not be as critical as it is for bridgework.

Teeth alongside implant retained crowns or bridges should be sound and well restored.

#### The number of missing teeth and their location

In general, a single missing tooth is best replaced by means of a bridge, all other factors being equal. Even in the presence of moderate periodontal disease there is evidence to suggest that a bridge creates less unfavourable conditions for plaque control than does a partial denture. Single tooth restoration endosseous implants (Chapter 23) offer better success rates than a bridge and do not need the preparation of an abutment tooth. However, cost and a surgical operation may inhibit their use.

An edentulous space resulting from two missing adjacent teeth bounded by remaining teeth could be restored by bridgework, either attached to an implant or to the adjacent teeth. Where the space is of three or more teeth, the partial denture becomes the more reliable simple option with implants providing better results at higher cost. Here there may be insufficient adjacent teeth to support a bridge adequately or the technical difficulties in construction may limit the treatment plan.

Where the edentulous space is unbounded at one end, i.e. a free end saddle, the restorative options will be further limited, again if implants are not possible. A bridge may be used to restore one tooth as a distal cantilever design but to restore more will inevitably require a partial denture.



Several missing teeth, each in different areas of the dental arch, could be replaced by several independent bridges, but usually the most cost-effective and simple option is to make a partial denture.

### Tooth relationships, the occlusion

As will be discussed in Chapter 20, the design of a simple bridge involving two or more abutments requires that these teeth be aligned roughly parallel. The construction of a bridge on malaligned teeth is not impossible, but is more difficult technically. The greater the disruption to the normal tooth relationships, the more a partial denture is indicated. Irregularities of the occlusal plane will also compromise the design of a bridge and if these are difficult or impossible to correct then usually a partial denture is preferable.

### Periodontal condition, caries and oral hygiene

As was stated above, all prostheses should be placed into stable and pathology-free mouths. In the face of poor oral hygiene, all types of prosthesis are likely to fail. It is a matter of some clinical judgement as to whether intraoral conditions will deteriorate more where there is a dirty bridge compared to a dirty partial denture present. The counsel of perfection is to only place a prosthesis in a mouth that is properly maintained by both the patient and by the dentist and where active caries and periodontal disease have been eliminated.

In relation to implant retained prostheses, the presence of periodontal disease is a significant contraindication. There is considerable potential for periodontal infection to spread to the implant sites and cause problems.

### The presence of an existing partial denture

When a further tooth is lost in close association to an existing denture, the simplest approach is to add another artificial tooth to the denture. The mixing of a denture and bridgework in the same arch may lead the patient to dispense with the denture and to rely on the bridgework alone. This is true particularly of an anterior bridge combined with a partial denture replacing posterior teeth; having an anterior tooth on the denture is a great motivator to proper denture wearing.

### Alveolar bone volume and position

These will be affected by the extent of post-extraction resorption which may in large edentulous areas

continue for many years. The series of sectioned models (Fig. 18.6) shows the results of resorption in the upper incisor region. Resorption in this area and indeed the whole maxilla proceeds from the outer aspects of the alveolar ridge thus reducing its diameters. In contrast the resorption in the mandible proceeds from the inside and therefore the diameters of the lower arch increase. In an edentulous patient, this has implications for the construction of complete dentures (Chapter 26).

The lower model in Fig. 18.6 has little resorption and this represents favourable circumstances for the placement of a bridge pontic onto the alveolar ridge. This may be seen in Fig. 18.7 where a single tooth pontic is represented in its restorative position. The tooth inclination is good from an aesthetic viewpoint and, as will be seen in later chapters, the alveolar mucosa will mimic gingival tissue. A removable prosthetic replacement could also be made in this site and, because of the volume of bone, a labial flange would not be required and the artificial tooth or teeth would be *gum fitted*.

Clearly, the volume of bone seen in Fig. 18.7 would be favourable for the siting of implants.

The worst case shown in Fig. 18.8 has insufficient bone for implants and when an incisor or incisors are placed in the correct aesthetic and functional position there will be a large gap between the alveolar ridge and the teeth which can only be filled effectively by a denture base.

Where there is moderate resorption as in the middle model in Fig. 18.6, the replacement could be by a bridge, but there would be a need to make up the missing bone demonstrated in Fig. 18.9 by using pink ceramic. A denture base could also provide an effective replacement.

The angle of an implant placed into an area of reduced bone may also create unfavourable aesthetics. Figure 18.10 shows the moderately resorbed ridge with the outline of an implant placed in the maximum volume of bone. The *emergence angle* will mean that the abutment will need to be at an angle to the implant for the crown to be in a functional position and therefore the aesthetics will be poor. To create good aesthetics the implant will need to be further forward and angled palatally and this can only be done by ridge augmentation prior to implant placement (see Chapter 22).

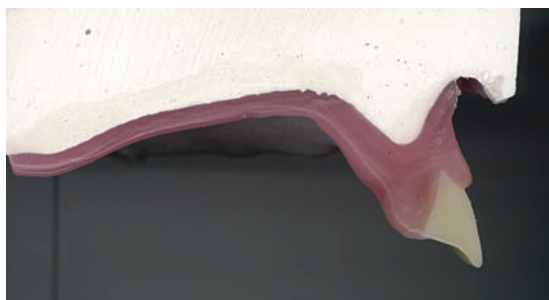This same principle applies to the siting of implants in other areas of alveolar resorption where vital structures such as nerves, blood vessels and the maxillary antrum would be vulnerable to damage.



**Fig. 18.6** Alveolar resorption. Sections of maxillary models showing the progression of alveolar resorption over several years from the lower model where there is little resorption, the middle model where there is moderate resorption and the upper model where there is much resorption.



**Fig. 18.7** Correct central incisor position on an alveolar ridge with minimal resorption.




**Fig. 18.8** Correct central incisor position on a grossly resorbed ridge. The resorbed bone is replaced by denture base.



**Fig. 18.9** Correct central incisor position on a moderately resorbed ridge. A bridge would need the resorbed bone to be replaced by pink ceramic. A denture base does this.

The functional and aesthetic siting of bridge pontics or implant retained crowns in areas of considerable resorption is difficult. The model in Fig. 18.11 shows an incisor that has its tip in the correct position. However, it has been angled to bring its neck into contact with the resorbed alveolus. Such an arrangement was made in the case shown in Fig. 18.12 that has a large anterior bridge. The angle of the incisors creates poor aesthetics and was presumably constructed in this way because the position of the tips was set by the lower incisor occlusion and the necks by the alveolus. Figure 18.13 shows the alveolus after the bridge was removed and the amount of resorption



**Fig. 18.10** The outline of an implant has been superimposed on the remaining bone in Fig. 18.9. The aesthetics would be poor if an implant retained crown was made in these circumstances.



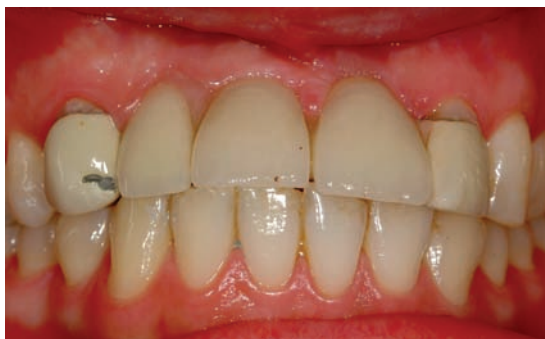**Fig. 18.11** Incorrect incisor position on a ridge with much resorption. The acute angulation leads to poor aesthetics.

can be seen. The management of this case is discussed in Chapter 21.

### Deleterious Effects of Dental Prostheses

There is no doubt that the placement of a prosthesis, whether this is fixed or removable, brings with it certain disadvantages. Principal amongst these is the possibility of causing further deterioration of the dentition. The possible deleterious effects are:

- Recurrent caries
- Loss of pulp vitality
- Tooth wear
- Periodontal disease



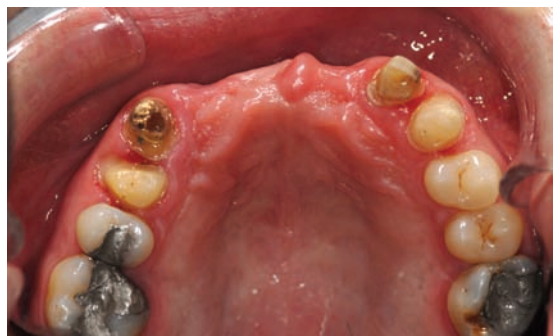**Fig. 18.12** Large anterior bridge with poor aesthetics caused by the incorrect incisor angulation.

- Soft tissue infection and damage
- Alveolar bone infection

These effects will vary in incidence and magnitude according to the type and design of the prosthesis. Their management will be discussed in Chapters 29 and 30.

### Fixed bridgework

The construction of a bridge requires tooth preparation to accommodate the retainers. In the case of resin-retained bridgework this preparation is minimal and this type of bridge is likely to have less untoward effects on the dentition. Where conventional bridges are made, the retainers are usually full crowns and here there is the potential for loss of vitality as a



**Fig. 18.13** Alveolar ridge with the bridge removed showing bone loss.

result of the trauma of the preparation. If the abutment tooth has already been carious and restored this potential is increased.

The retainer margins, no matter how well fitting, and the pontic/retainer embrasure spaces introduce plaque traps that require special oral hygiene measures to be performed by the patient. The consequences of plaque accumulation may be periodontal disease and, in the presence of a substrate, recurrent caries.

Damage to opposing teeth is possible if ceramic on the bridge is in functional contact with them. The ceramic is harder than enamel and, if poorly glazed or rough, will cause rapid tooth surface loss.

Bridge abutment teeth may transmit unfavourable twisting forces to the periodontium. If the periodontium is already inflamed these forces may accelerate periodontal breakdown. On the other hand, if the periodontium is healthy, it appears that supporting a bridge does not bring any untoward effects (see Chapter 20).

### Implant-retained prostheses

Damage to local vital structures (nerves, blood vessels, antrum) is possible during placement. The endosseous implant is also a potential entry point for bacteria and 'peri-implant' infection of the soft tissues and bone is possible (Chapter 23).

### Partial dentures

The contact areas of clasps and denture base to the surrounding teeth are sites for plaque accumulation and its consequences of caries and periodontal disease. Movement of the denture base, particularly tipping and rotation may accelerate periodontal breakdown in the presence of active periodontal disease.

Stagnation under a denture base may create conditions favourable to the establishment of infection by *Candida albicans* (thrush) leading to denture-induced stomatitis.

### Continuing care and replacement

All restorative work brings the requirements of continued maintenance and monitoring by the dentist and scrupulous oral hygiene by the patient.

Perhaps of even greater importance is the realisation that eventually repair and replacement will be necessary for most restorations. This does not reflect upon the standards of care but a realistic apprecia-

tion to be conveyed to the patient that nothing lasts forever. General wear and tear and changes in the oral cavity may lead to local or general failure of restorations.

All other things being equal, i.e. that no pre-existing problem, such as a questionable root filling, exists then the life expectancy for a bridge would be between 10 and 15 years and a removable partial denture perhaps 10 years. Even during that time minor problems such as the fracture of a component or even major repairs such as root canal therapy through a retainer may be necessary.

Because of their complexity of construction, implant retained prostheses require even more intense maintenance. Failure of joints and superstructure components is possible as well as the basic failure of the implant itself.

A very positive commitment to continuing care in relation to any prosthesis is required by both the patient and the dentist. Effective oral hygiene and attendance for regular review is the patient's role in this.

### Shortened dental arch

Bearing in mind the above description of the deleterious effects of dental prostheses, a philosophy of non-replacement of lost posterior teeth has evolved, known as the *shortened dental arch*. Whilst this concept could be applied to any missing molar teeth, it has come to refer to dentitions that have no teeth distal to the second premolars in all four quadrants, i.e. all the molar teeth have been lost and deliberately not replaced. This arrangement has also been termed a *premolar dental arch* or a *premolarised occlusion* (Fig. 18.14).

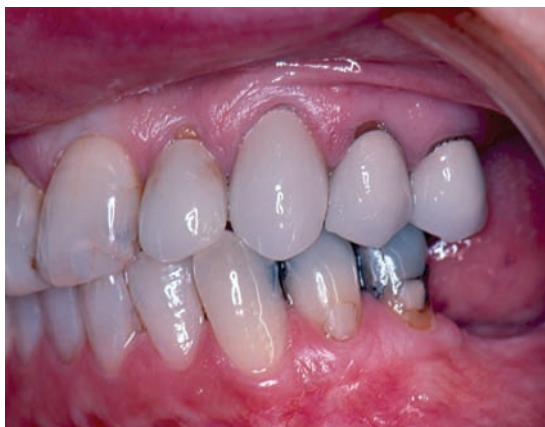

Fig. 18.14 A case with shortened dental arches.

There is clinical evidence to support the concept in that patients have been observed to function adequately with such a reduced occlusal table and the possible deleterious effects of a prosthesis on the premolar teeth, in particular tipping and periodontal problems, are prevented.

Loss of occlusal stability of the premolars due to distal drifting and wear has been shown to be small and the poorer aesthetics of missing molars has not been considered a problem.

The concept may also be applied if the premolar arch is not intact, particularly if the second premolars are missing. These teeth may be replaced, all other factors being equal, by distally cantilevered units attached to the remaining teeth or endosseous implants. The biomechanics of this type of arrangement must be considered. It is suggested that the distally cantilevered unit is restricted to one premolar only to reduce tipping forces and if several teeth are involved in the prosthesis that it is constructed from gold alloy and acrylic resin to allow flexure.

#### **Treatment Planning for Prosthodontics – Summary**

The loss of natural teeth may result in the deterioration of the remaining dentition and affect the patient adversely.

The provision of a prosthesis will restore aesthetics and function as well as playing a part in maintaining the dentition.

The prosthesis, however, may cause deterioration in its own right and the decision to restore the edentulous space must take into account both the advantages and the disadvantages of the treatment.

The choice of prosthesis is based on a complete assessment of both the patient and the intraoral conditions and many factors must be considered with the condition of the mouth itself being of principal concern.

The active cooperation of the patient in both the provision of the prosthesis and its subsequent maintenance is of paramount importance to its success.

# Chapter 19

## Fixed Prosthodontics: Resin-Retained Bridgework

The next five chapters consider fixed prosthodontics. In this chapter there are the basic definitions for bridgework. The history, design, treatment planning and techniques of resin-retained or adhesive bridgework are described together with the materials involved in their construction.

### General Definitions for Bridgework

A bridge, also referred to as a *fixed prosthesis* or a *fixed partial denture*, is a false tooth, or teeth, permanently attached to natural teeth or to endosseous implants. The false tooth, the *pontic*, is joined by *connectors* to *retainers* that are cemented to the *abutment teeth*. The retainers may be either wings – (*resin-retained* or *adhesive bridgework*) or inlays or crowns – (*conventional bridgework*) (Fig. 19.1).

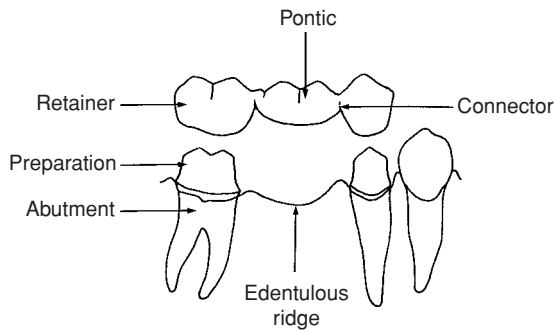


Fig. 19.1 The components of a bridge.

The pontic may be fixed to the retainer by a *rigid connector*, or it may have a movable joint (*non-rigid connector*). Bridges may be classified according to the type of connectors either side of the pontic, as either *fixed-fixed* or *fixed-movable*.

In addition, the pontic may only have one connector and be free at the other end – this is a *cantilever bridge*. If the pontic is some distance away from the retainer, and the connector is a metal bar, this is a *spring cantilever bridge*.

Bridges are also referred to by the total number of retainers and pontics, for example – a *five-unit bridge*.

### Resin-Retained Bridgework

#### History

The concept of the resin-retained bridge (RRB) is that metal ‘wings’ are retained by the acid-etch technique to enamel surfaces adjacent to the edentulous space. The wings are part of a metal sub-frame that also supports a resin or ceramic tooth. The use of metal and resin in this way was first reported by Rochette (1973) who described a perforated metal periodontal splint that was adapted to retain a false tooth. Metalwork covered the whole of the lingual enamel surface and retention to the cementing composite was achieved through small holes in the metal. Other workers developed alternative ways of obtaining macromechanical retention to the metal but these and the Rochette system have now been superseded.

In the late 1970s, Livaditis and Thompson at the University of Maryland developed an electro-etching procedure for non-precious ceramic bonding alloys to provide a microporous surface that a micromechanical interlock with the cement. This gave rise to the ‘Maryland’ bridge that had the advantages over the Rochette type of thinner wings and no perforations. Electroetching, however, was a demanding technique and two other techniques, acid etching and grit blasting, were developed. Grit blasting was the most simple and reliable and the other two have been largely superseded. This has not stopped the incorrect use of the term ‘Maryland bridge’ for all RRBs.

Further improvements in longevity have been obtained by the development of specific affinity cements and by metal primer systems that increase the bonding of the cement to the metal.

## Design

The original bridges and splints were made with no tooth preparation, but now considerable enamel preparation is required to promote long-term success; the technique is also referred to as *minimal preparation bridgework*. The objectives of the preparation are to create features that will enhance the stability of the bridge and, to as great extent as possible, to accommodate the casting within the original tooth contour. Other aspects of RRBs have evolved empirically with clinical experience. Perhaps the most interesting of these has been the reduction in the number of wings used; most single tooth RRBs will now be retained by a single wing to a single abutment. This is the result of an appreciation of the twisting forces applied during function that translate to peel forces across the adhesive. Stress on one side of a two-wing bridge will be transmitted across the structure and the second abutment will be moved in its socket. Stress therefore concentrates in the adhesive layer under one wing.

Clinical experience showed that two wing RRBs often failed by debonding of one wing. The problem would be managed by removing the debonded wing intraorally to leave a single-wing bridge. These single-wing bridges were surprisingly successful and this led to the current design concepts.

This observation of the biomechanics of this bridge system has implications for the design of conventional bridgework (see Chapter 20).

## Tooth preparation

The objectives of tooth preparation are to:

- Accommodate the metal within the original contour of the tooth
- Provide occlusal clearance if necessary
- Direct stress away from the adhesive
- Provide as great a surface area of enamel for bonding as possible
- Achieve clear finishing lines

To achieve this it is necessary to:

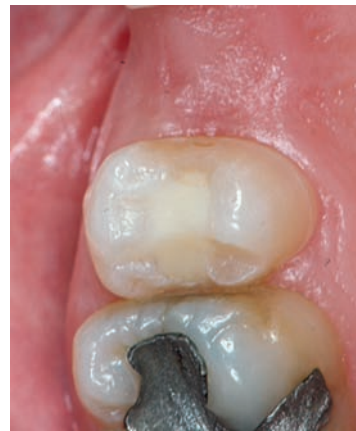- Identify a single path of insertion
- Remove the bulosity from as wide an area of enamel as possible without exposing dentine – half enamel thickness preparation
- Extend the preparation to as much of the buccal and lingual surfaces as possible to create ‘wrap-around’



**Fig. 19.2** Resin-retained bridge preparation on a premolar. The bulosity is removed, a light chamfer finishing line established and a wrap-around created. An occlusal rest seat is cut in the mesial marginal ridge.


- Avoid the incisal one-third of anterior teeth to maintain translucency
- Incorporate rest seats, slots and grooves as appropriate, to increase stability and accurate location of the casting for cementation

The posterior tooth preparation is shown on a premolar (Fig. 19.2). A rest seat is cut in the marginal ridge and in some teeth the occlusal morphology may allow an additional rest. These rests must be at least 1 mm deep to be effective (Fig. 19.3).



**Fig. 19.3** RRB preparation on an upper premolar. Note the second rest seat and the fade out of the preparation buccally, creating a chamfer in that area.



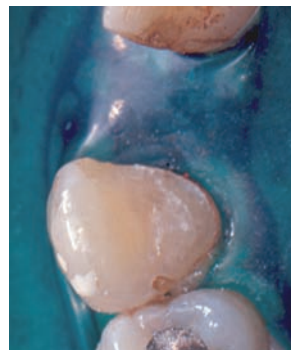


**Fig. 19.4** RRB preparation on an incisor. This includes a palatal wrap-around, cingulum rest and cingulum reduction to clear the occlusion. The yellow lines indicates sites for retention grooves.

The typical anterior tooth preparation, which is shown on an incisor (Fig. 19.4), requires clearance from the occlusion to enable correct reproduction of the anterior guidance, an internal cingulum rest for location and stress bearing, approximal reduction in the path of insertion and a supragingival chamfer finishing line palatally. If the cingulum area is small, slots or grooves should be cut to enhance stability (Fig. 19.5).

There is a danger of producing greyness of incisal edges if the metalwork extends too far incisally. For this reason, the preparation should be confined to the cervical two-thirds of the crown. Care should be taken also to avoid bringing the approximal reduction into the line of sight and a 'fade out' of the reduction should be done to maintain enamel in the labial region.

Provisional replacement of the missing tooth by a bridge is not possible and a removable partial den-



**Fig. 19.5** RRB preparation on an upper canine. Grooves have been incorporated in the preparation to increase stability.

ture is used. The occlusal clearance created by the preparation can be maintained by attaching composite to the tip of the opposing teeth. An alternative technique that some favour is to fit a bridge that is high in the occlusion and allow tooth movement to accommodate the imbalance. Care must be taken if this approach is favoured that inclined plane forces are not created that may procline the abutment tooth.

### Treatment planning

Table 19.1 summarises the indications and contraindications for resin-retained bridgework.

### The occlusion

The RRB is useful for short spans and where unfavourable tipping forces are not present. Potential displacing forces from the occlusion are difficult to predict but patients with a clenching or grinding habit or an edge-to-edge incisor relationship may create unfavourable conditions. A further occlusal problem may be variations in the level of the occlusal plane caused by tilting or overeruption into the edentulous space. It is preferable to correct this before making the bridge as the irregularity may be another source of unfavourable displacing forces.

**Table 19.1** Indications and advantages for resin-retained bridgework

Indications	Contraindications	Advantages	Disadvantages
Short spans (one or two teeth)	Long spans	Technically simple	Metal visible through tooth
Sound enamel available	Heavily restored teeth	Cheaper than conventional bridgework	Debonding problems
Favourable occlusion	Multiple upper anterior teeth		

### The abutment teeth

These should have sound and well-supported enamel. Whilst small restorations are acceptable, more extensive cavities are likely to have weakened cusps. If there is any doubt about the integrity of the chosen abutment, then the existing restoration(s) should be removed and the enamel inspected. Ideally, the abutment tooth restoration should be composite or glass ionomer cement because of the better bonding of the adhesives to these materials (see later). However, small sound amalgam restorations are acceptable.

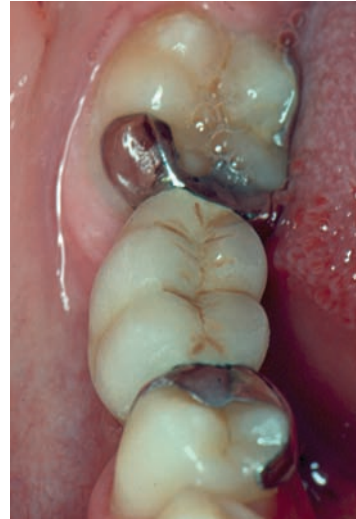The precise choice of abutment is somewhat empirical but as a general rule the more posterior tooth of a bounded space is more suitable. The rationale for this is that the more posterior the tooth usually the larger and the less visible it is. The exception is the upper lateral incisor and this tooth should be avoided as the sole abutment because of its small crown and reduced root support.

The amount of etchable surface and potential wrap around varies from tooth to tooth because of variation in size and position. The size is of particular significance in the lower arch, where the lingual surfaces of the anterior teeth are relatively small, and in the posterior region, where the lingual crown height is often low. Similarly, very severely tilted or rotated teeth might be difficult to use as abutments. All incisor and canine teeth have short palatal or lingual walls and here slots or grooves are useful to increase stability.

### Bridge span

While it is possible to replace more than one tooth with an adhesive bridge, more failures appear to occur with multiple replacements. The use of more than one abutment on either side of the space is also rather risky since the differential stresses are applied to bonds of varying areas, and debonding is likely. A single molar should be regarded as two tooth 'elements' and two wings, one at each end are usually prescribed for retention (Fig. 19.6). A novel design splitting the molar pontic into two offers the advantage of two single wing bridges (Fig. 19.7).

The upper central incisor may be replaced by a single wing cantilever from the other central incisor or as a cantilever from two wings on the upper lateral incisor and canine. In this latter design it is important to incorporate slots, grooves and rests in the preparations to increase stability.



**Fig. 19.6** RRB replacing a lower molar using two wings.

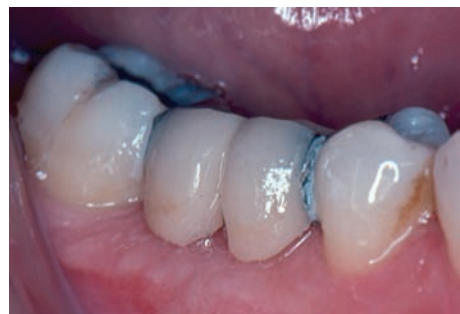### Design variations

The introduction and development of adhesive techniques has led to many variations in design as dentists attempt to establish the limits of the techniques.

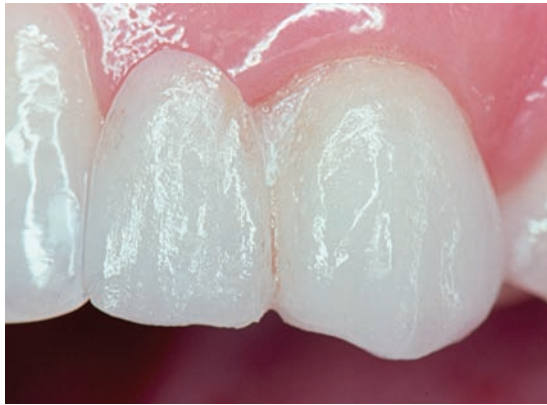For example, a buccal wing could be used if enamel is better there and the aesthetics are acceptable. The bridge could be constructed completely in ceramic, with the wing being a veneer preparation (Fig. 19.8). This is useful if the adjacent tooth is to be veneered anyway.

Spacing is difficult to reproduce but connectors can be constructed to lie below the space, out of sight. However, the stresses on the wings may be increased by this design.

Hybrid designs have been used that combine a conventional crown on one side of the pontic with a



**Fig. 19.7** An alternative design for the replacement of a molar. The molar is replaced by two half-tooth pontics, each attached by a single wing to the abutments.



**Fig. 19.8** Ceramic veneer retained bridge replacing [2] cantilevered from [3].

bonded wing on the other but with the experience of the success of single wing cantilevers; these designs have little value and complicate treatment. The same applies to designs that incorporate joints within a hybrid structure; these are not needed.

### Immediate RRBs

This type of bridge can be very successful as an immediate replacement for an extracted tooth. The abutment is prepared and the bridge constructed before the extraction. The tooth to be extracted is removed from the model and the model relieved to allow the pontic to be placed superficially in the socket. After extraction, bleeding may be controlled if necessary by placing cellulose mesh in the socket prior to placing the rubber dam.

The only problem of this technique is that alveolar resorption may change the relationship of the pontic to the alveolar ridge. If the patient's lip line is low, the gap may not be noticed. However, if the patient notices food collecting in the gap, a new ceramic facing can be made for the pontic. This technique is described in Chapter 29.

### Cementation

Cementation must be carried out in a dry field and the application of rubber dam is essential, particularly in the lower arch because of the potential for contamination of the etched tooth and the fit surface of the metalwork (Fig. 19.9).

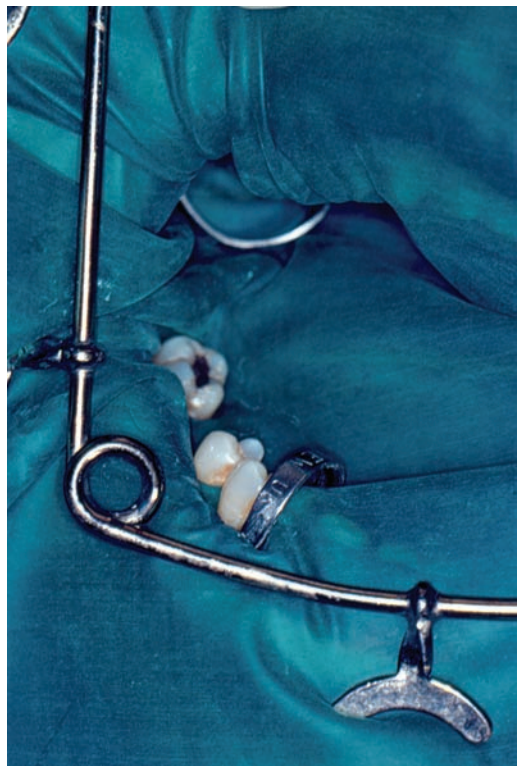
Before the dam is placed, the following must be checked:

- The shade
- The seating of the metalwork
- The occlusion (if possible)

These cannot be checked with the dam on.

The *cementing sequence* is as follows:

- 1 Try in and check margins and the occlusion. If the casting is not stable, the occlusion cannot be checked easily until after cementation
- 2 Place the rubber dam
- 3 Prophylaxis of the abutment teeth using a slurry of pumice and water. Non-oil-based prophylaxis pastes may be used but they may contain fluoride. This will reduce the effectiveness of the etching
- 4 Grit-blast the bridge wing or, if there is no access to a grit-blaster, clean the bridge wing with absolute alcohol or a proprietary cleaning agent
- 5 Prime the metal, if required
- 6 Acid etch the area of the tooth preparations



**Fig. 19.9** Rubber dam applied for the cementation of the RRBs shown in Fig. 19.7. It is important that the dam is slack over the alveolar ridge so that it is not under tension when the bridge is placed.

- 7 Mix and place the cement on the bridge and seat home
- 8 Remove excess prior to setting and place oxygen barrier, if required
- 9 Remove the dam, clean the margins and adjust the occlusion
- 10 Check that the embrasures are clear for oral hygiene measures

## Dental materials aspects

### Metal subframe and pontic

The choice of metal alloy relates particularly to the method of adhesion of the retaining wings. The electro-etched (Maryland) system is particularly affected by the alloy composition and the principal alloy used in this technique was a nickel–chromium–beryllium ceramic bonding alloy. Non-beryllium alloys did not electroetch well. However, the beryllium content of such alloys represents a health hazard on inhalation of the grinding dust and these are therefore not recommended.

The more universal use of grit blasting has led to the use of cobalt chromium ceramic bonding alloys. Nickel-containing alloys should be avoided because of the risk of allergy.

The cobalt chromium alloys are harder, denser and more difficult to cast than the semi-precious alloys described in Chapter 15 and also more time consuming to adjust and finish clinically. The higher melting point requires the use of a phosphate-bonded investment and the wax pattern for the bridge is usually made on a divestment model similar to those used for ceramic veneers. The accuracy of fit of the casting can be less than that achieved with crowns and the technician may often need to spend considerable time adjusting the casting to achieve a good fit to the master model.

However, in spite of this the alloys have the advantage of being strong in thin section and therefore the retaining wings can be thinner – of the order of 0.3–0.4 mm. They also form an oxide layer on their surface which is utilised for bonding (see below).

Pontics may be made from ceramic or polymers. Ceramic is the most durable with oven-processed composites being a second choice.

### Adhesive cements

There are two basic types:

- Fine particle composite luting cements
- Dual affinity polymer cements

These are mostly two-component autopolymerising systems but there are also some ‘dual-cure’ materials available that are initiated by visible light but also have a slow autopolymerising component. This means that polymerisation will take place even when the curing light does not reach the full thickness of the material. Care must be taken however as the autopolymerising process is slower. The setting process may be disturbed if occlusal adjustment is undertaken too soon after the initial ‘tack’ setting with the light.

The formulation of the first group is based on restorative composites with very much less filler of smaller particle size diluted with lower molecular weight monomers. This results in a material with a higher polymerisation shrinkage. They rely on micromechanical interlocking to both the etched enamel and to the metal wing for their retention.

The second group has a similar basic formulation but also has a chemical agent present to aid adhesion, particularly to the metal. The individual materials are based on 4-methacryloxyethyl trimellitic acid anhydride (4-meta), 4-meta with methyl methacrylate, 4-meta with bis-GMA or the halogenated phosphate ester of bis-GMA. Some of these have shown very high bond strengths to enamel and apparently offer advantages over the purely mechanical retention of the other types of cement. Their chemical bonding to the metal is dependent on there being a metal oxide layer present.

The setting reaction of some cements is inhibited by oxygen and air must be excluded from the bridge margins to permit polymerisation. Vaseline is effective and similar compounds are supplied with the materials.

### Metal surface conditioning

The success of resin-retained bridgework depends to a great extent on the adhesive bond between the metal, cement and tooth. Therefore, an understanding of the various methods for conditioning the metal fit surface is crucial.

The electroetching technique creates a surface that enables the polymeric cement to make a micromechanical interlock with it. Surface contamination with water, saliva or organic debris will prevent the interlocks from forming, which explains the care that must be taken with the bridge once it has been etched. The electroetched surface does not allow the chemical affinity cements to use this aspect of their formulation.

Grit blasting of a cobalt chromium ceramic bonding alloy with 40–50 µm aluminium oxide grit creates

a surface disruption of the metal that allows similar micromechanical interlocking but also leaves a well-bonded oxide-rich layer. The dual affinity cements react with this oxide layer to enhance their adhesion.

Semi-precious ceramic bonding alloys on the other hand do not form this oxide layer on grit blasting and to obtain the reactive oxide surface they must be tin plated and then be heated in a ceramic furnace to oxidise the tin.

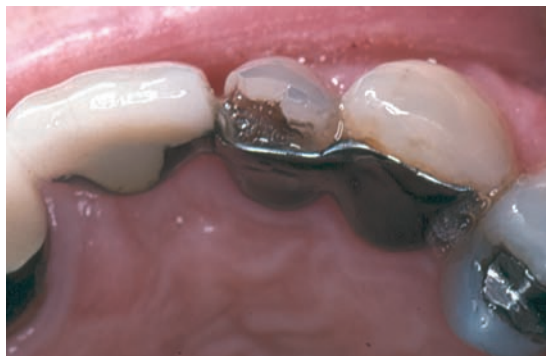A further treatment method is the deposition of silicon and silane compounds onto the metal surface. This requires special equipment but bonding is only moderately improved and the coating is also easily contaminated.

### Debonding

The catastrophic failure of RRBs by sudden debonding is the major drawback of the technique. It is now more dramatic with the use of single wings being more common. A two-wing bridge might fail on one wing first allowing the patient a little warning of impending disaster. One way of providing reassurance is to supply the patient with an emergency stand-by partial denture.

Debonding may occur either almost immediately after placement or much later.

The immediate type occurs in the first 48 hours after cementation and the debond is likely to be caused



**Fig. 19.10** Single-wing debond in a two-wing bridge. Extensive caries has resulted.

by contamination during cementation and failure at the tooth-adhesive interface.

The later failures can occur at either of the two interfaces but, increasingly, evidence of failure within the cements has been found. This is presumed to be the result of fatigue.

Debonding appears to be more common in cases where multiple abutments have been used.

When partial debonding occurs, it is essential that the bridge is removed and re-cemented, otherwise there is a high risk of recurrent caries under the loose wing (Fig. 19.10). Alternatively, the loose wing can be cut off and the bridge thereby converted to a cantilever type.

#### Resin-Retained Bridgework – Summary

The development of the technique and materials has proceeded rapidly. It is now the treatment of choice for single tooth replacement. Unfavourable occlusal factors and heavily restored abutment teeth may contraindicate the technique.

Minimal tooth preparation is required to enhance mechanical stability. Retention is achieved through a dual-affinity polymer-based luting cement via the acid-etch technique to enamel and grit-blasting to the bridge alloy. Base-metal-bonding alloys are preferred.

Patients should be warned of the possibility of catastrophic failure and perhaps supplied with an emergency partial denture to have in reserve.

## Chapter 20

# Fixed Prosthodontics: Conventional Bridgework – Design and Planning

Here we consider the replacement of teeth by crown-retained conventional bridgework. The principles underlying the choice of design and treatment plan are described. Of particular importance are the condition of the abutment teeth and their periodontal support. The problems of hypodontia, changes in appearance and cleft palate are discussed.

### Introduction

The more routine use of adhesive bridgework of various designs and its long-term success has led to considerable reduction in the indications for bridgework retained by inlays and crowns. In sound mouths, the resin-retained bridge is now the treatment of choice for a single tooth, with or crown-retained conventional bridges being used for cases where the abutment teeth cannot support an adhesively retained wing. Further changes in the provision of crown-retained bridges have been brought about by the use of implant supported crowns and bridges.

### Design Considerations

There is very little scientific evidence to support many of the principles of conventional bridgework. These principles have evolved empirically through clinical experience and some documentation of failures. Experience in the biomechanics of resin-retained bridgework has called into question some of the previously accepted tenets of conventional bridgework.

The design of conventional bridgework depends upon:

- Biological factors
- Mechanical factors
- Aesthetic factors

### Biological factors

The longevity of conventional bridgework depends firstly on the biological integrity and prognosis of each of the abutment teeth chosen in the provisional design. The crown must be caries free and the pulp

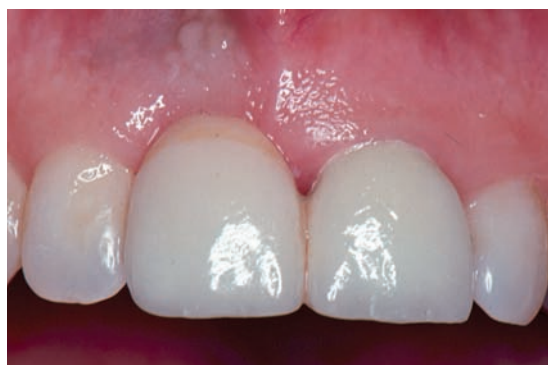must either be healthy or be replaced by a sound root filling with no apical pathology. The periodontium must also be healthy and well maintained.

Teeth that have suffered previous periodontal breakdown are not excluded from being abutments, but the disease must have been stabilised and the plaque control maintained at a high level.

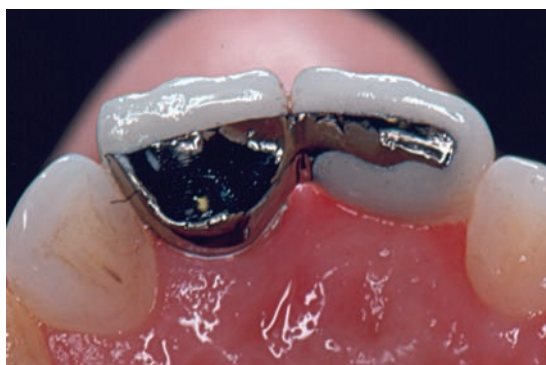The number of abutments required to support the proposed pontics is often a matter of opinion. Ante proposed that the combined surface area of the periodontium of the abutment teeth should be equal to or greater than that of the teeth to be replaced. This seems to assume that the abutments will be subjected to greater loading, possibly up to one and a half times more.

However, work from Scandinavia, where extensive bridges were provided for periodontally dubious teeth, together with clinical experience, suggests that Ante was being over-cautious and that occlusal loading is reduced by a bio-feedback mechanism to a level appropriate to the support available. This concept is also supported by experience with resin-retained bridgework where the single-wing cantilever design has been found to be successful. For the case shown in Fig. 20.1, the 'older' conventional bridge design would almost certainly have involved two abutments.

Rather than looking at the axial occlusal loads on abutments, it seems more important to consider the possible leverage and torque that may be applied. This will arise during function and parafunction in lateral excursions and protrusion, and the assessment of the occlusion is crucial in bridge design. For example, in a canine-guided occlusion, lateral stresses on other teeth are small, and perhaps this is more favourable when they are used for abutments.



(a)



(b)

**Fig. 20.1** Single retainer cantilever bridge replacing 1|. This design would not have been used prior to the experience with single-wing resin-retained bridges.

This is not to say that a large number of pontics can be supported by a few abutments, because the retention of the bridge is also important. Rather that bridges made with less than the traditionally ideal level of support can be clinically successful.

The *periodontal surface area* of the abutment teeth is clearly important, though. The upper canine and the upper first molar have the largest areas making them ideal for bridge support, whilst at the other end of the scale, the upper lateral incisor has a very small root and is often unsuitable as a terminal abutment. Pragmatically, then, it would seem sensible to adopt designs that utilise the teeth with the largest periodontal surface areas available in the particular circumstances.

### Mechanical factors

Each abutment tooth must also be structurally sound. It must either have dentine of sufficient quality and quantity to allow the preparation of a retentive crown, or, in the absence of such sound tissue, be capable of being restored, depending upon its position, by a pinned core or a post and core.

Each preparation should provide excellent mechanical retention, achieved by near-parallelism of walls (Chapter 15). In a multi-abutment bridge each of the preparations must individually provide proper stability. If, for example, a short preparation is included, this will be a site for stress concentration and subsequent cementation failure.

The most retentive retainer is a full crown with the partial veneer crown being a close second. For simplicity of preparation and reliability of fit, the full

crown has become the most used retainer. The use of inlays as bridge retainers has died out – mainly because a tooth that is suitable for an inlay would also be suitable for a resin-retained wing and therefore the conventional bridge would be contraindicated. Partial veneer crowns leave the buccal surface uncut and can therefore be aesthetically better and are more conservative of tooth tissue. However, the preparation is more technically demanding.

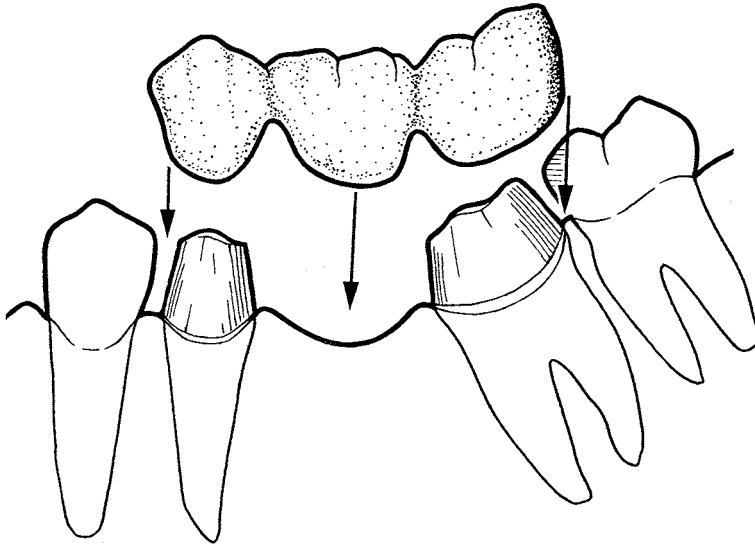
### Parallel preparations

The abutment preparations for a fixed–fixed bridge must be parallel. The bridge will eventually be inserted in one piece and this will not be possible if each preparation has a different path of insertion, caused usually by abutment tooth tilting. This aspect of each case must be assessed using a model surveyor. The problem of non-parallel alignment of abutment teeth may be solved by:

- Pre-operative orthodontics
- Compromises in preparation angulation
- Assembly joints
- Telescopic retainers or copings

*Orthodontics* may be used to upright the malaligned tooth or teeth. However, this may not always be practical due to the length of time required or the reluctance of the patient to undergo the treatment that usually requires fixed appliances.

*Preparation angulation* may be changed from the ideal for each abutment to a compromise in keeping with that required for the bridge design. However, such alterations may result in:



**Fig. 20.2** Tilted teeth – the problem of a fixed–fixed bridge. The seating of the bridge is prevented by the mesial aspect of the last molar, even though the preparations have been cut with a common path of insertion. Also, the retention of the prepared molar is reduced by the angulation.

- Loss of retention of individual retainers
- Inability to seat the bridge

Figure 20.2 shows this diagrammatically. It is possible to cut parallel preparations on tilted teeth but adjacent teeth may prevent the bridge from being inserted. Also, changing the path of insertion may reduce the preparation height and the extent of preparation walls that are parallel to each other thus reducing the retention.

### Assembly joints

To overcome this loss of retention, the paths of insertion of each retainer can be made in the long axis of each abutment crown and the bridge assembled in the mouth at cementation by means of a joint in one of the connectors parallel to the path of insertion of the other element of the bridge (Fig. 20.3). The dovetail slot may either be milled in the casting or be a preformed precision retainer (Fig. 20.4).

### Non-rigid connectors/movable joints

In addition to permitting the assembly of individual elements of bridges, joints have been used for many years as *non-rigid connectors*, also referred to as *movable joints*. The concept is that even when a bridge may be made fixed–fixed from the angulation of the abutments, empirical biomechanical considerations suggest that one retainer may either take more stress than another or that one is less retentive than another.

The design factor of *stress breaking* has been applied to these circumstances.

Stress analysis suggests that this concept is flawed. The type of joint shown in Figs. 20.3 and 20.4 is capable of very little freedom of movement. Loading in the long axis of the joint might allow some independent movement of the bridge elements but, of course, most masticatory movement would cause lateral and shear forces on the bridge. In the face of these forces the joint would, in effect, be a rigid connector and not break stresses at all.

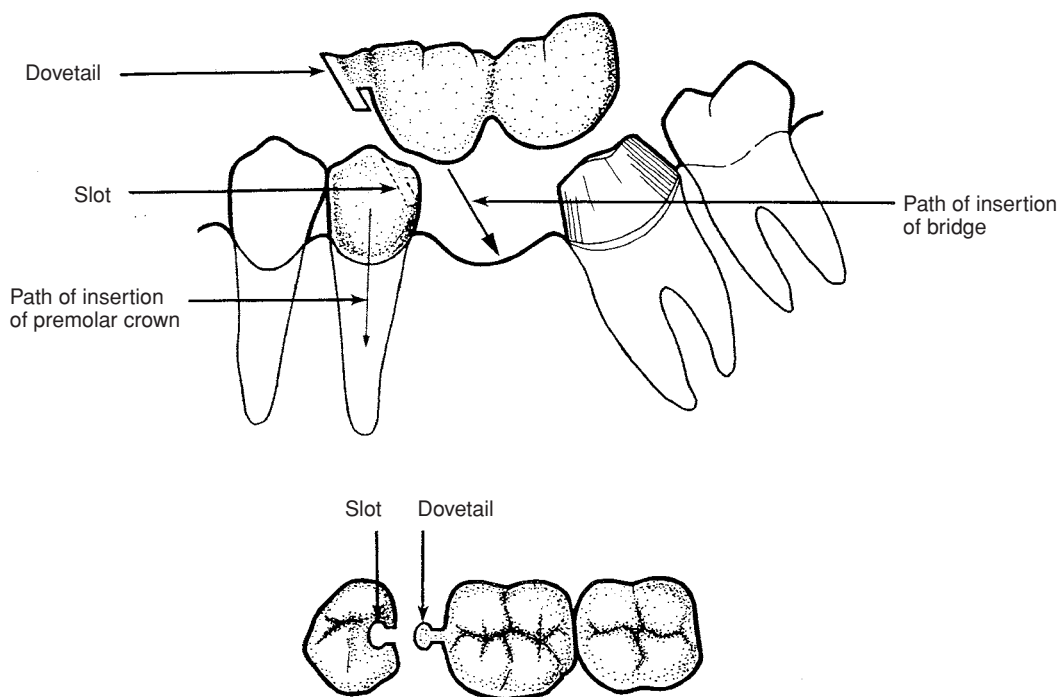
This concept is a very good example of scientifically unsubstantiated clinical opinion.

### Telescopic crowns or copings

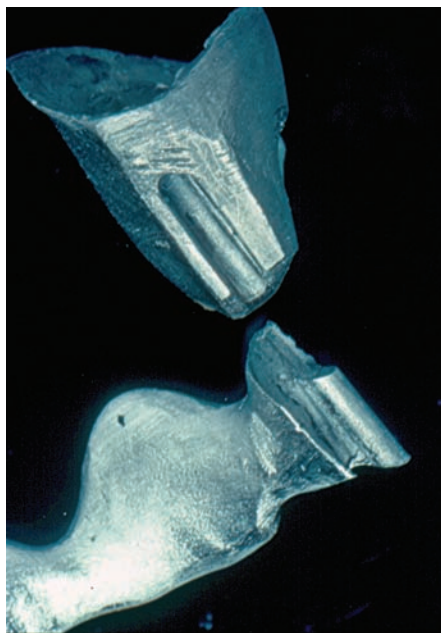
An alternative way of overcoming discrepancies in paths of insertion is to use telescopic crowns based on metal copings (Fig. 20.5). Each abutment is prepared to receive a casting in whatever path of insertion is appropriate for that abutment. Each casting or *coping* has its outer aspect shaped to the common path of insertion for the bridge and slots/grooves may be incorporated to increase retention.

This structural system, whilst solving the angulation problem, also has the advantage that the individual abutments are capable of being treated separately in the event of failure. Very often the overlying bridge is cemented with a temporary cement that allows easy removal of the bridge if problems arise.





**Fig. 20.3** Tilted teeth – the assembly joint. Each abutment has its preparation cut in its long axis. The crown on the premolar has a dovetail-shaped slot cut in its distal aspect (the preparation must be reduced to accommodate it) and the pontic has the dovetail-shaped piece to fit the slot. The line of the dovetail is the path of insertion of the molar preparation.



**Fig. 20.4** A precision retainer that can be used as an assembly joint.

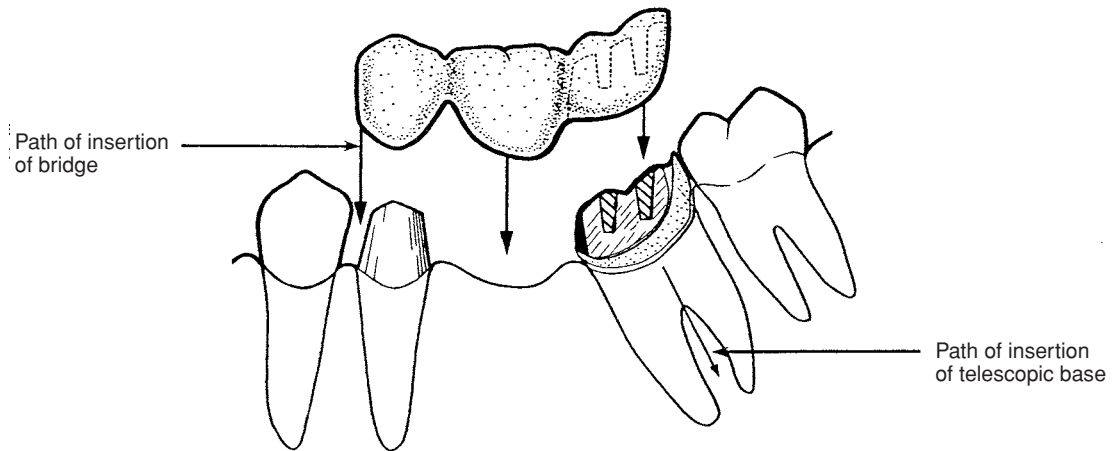
### Aesthetic factors

This may well be one of the major reasons for providing bridgework and a decision must be made about which teeth should have tooth-coloured components and which can remain all metal. The all-metal retainer utilises a minimal preparation and is technically less demanding than an aesthetic one.

The aesthetic component has to have space in the preparation to accommodate it and requires higher technical skills for its construction, particularly if it is to function in the occlusion.

Aesthetic materials tend to be applied directly to a metal sub-frame and may be ceramics or polymer-based composites. Pre-formed cemented facings are no longer used.

The newer castable and milled ceramics described in Chapter 15 may also be used for all-ceramic bridgework. However, the brittleness of ceramic means that the connectors in such bridges need to be substantial. Such connectors may impinge on the gingival tissue to achieve the required cervico-occlusal dimension. Also, caution should be exercised when considering



**Fig. 20.5** Tilted teeth – the telescopic crown. The preparations are in the long axis of each tooth. A gold coping is made for the molar, which is milled to receive a partial veneer crown with slots and grooves. The path of insertion of the bridge is then aligned with the premolar preparation.

all-ceramic cantilever bridges; these may end with the pontic breaking away.

When metal–ceramics are used, wherever possible, and with the agreement of the patient, the occlusal surfaces should be reproduced in metal (Chapter 14).

If the purpose of the bridge is to alter the aesthetics, then this must be carefully planned at the diagnostic stage (see later).

## Pontic Design

Pontics may require a functional component and well as an aesthetic one.

For its functional aspects, the pontic should provide occlusal stability by the inclusion of centric stops and supporting cusps as appropriate. Its participation in the new occlusal scheme should be decided (see later) and it should not create any interferences.

Pontic function could be fulfilled by a flat ‘plate’ of metal and the *wash-through* or *sanitary* pontics are useful from the periodontal viewpoint, in that the tissues around the pontic are readily accessible for cleaning. However, their use is usually confined to the molar region and is now rare because of their aesthetic limitations.

The majority of pontics will need to be aesthetic and this will mean the inclusion of a tooth coloured facing in conjunction with the metal functional surface. The aesthetic component will need to reproduce the embrasure spaces and contact the soft tissue of the alveolar ridge. This tissue contact must be

firm, but not intrusive, to reduce plaque accumulation under the pontic. Contact should be confined to the buccal or labial aspect of the ridge, with the remainder accessible to the tongue for natural cleansing (Fig. 20.6).

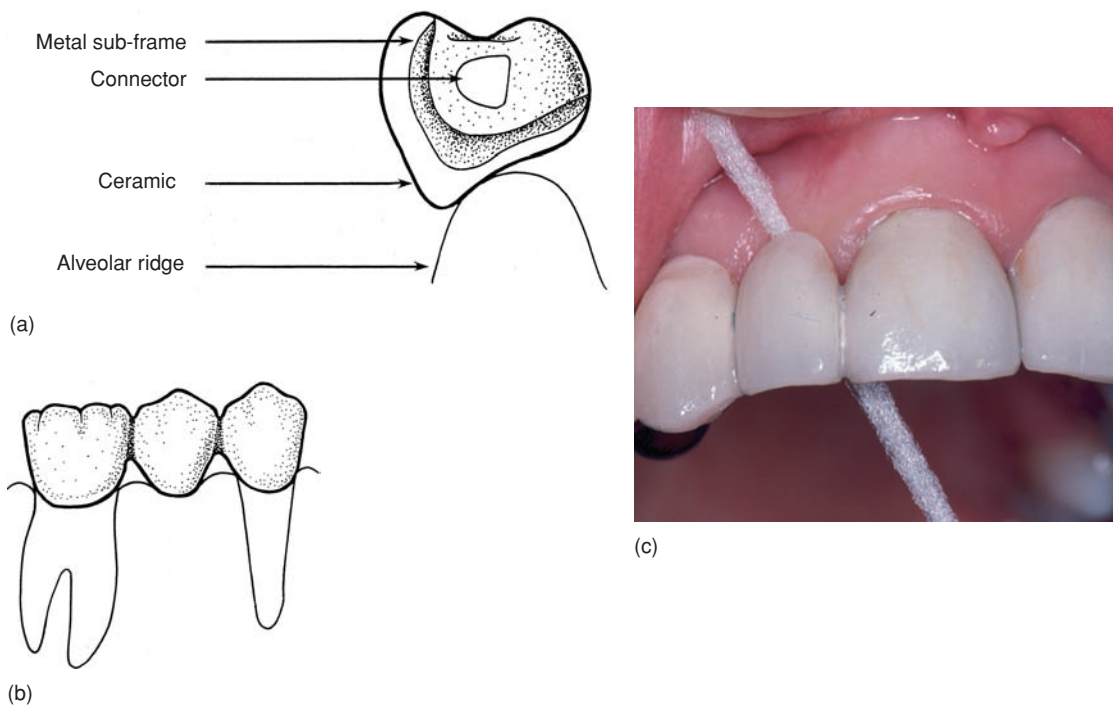
Special oral hygiene techniques are required to maintain the undersurface of the pontics and connectors in a plaque free condition, and the most useful aid is superfloss (Fig. 20.6c).

If alveolar resorption has been extensive, the pontics will not have an aesthetic relationship with the alveolar ridge (Fig. 20.7). The patient shown in Fig. 20.7 had difficulty with speech because air escaped through the teeth as well as having food particles collecting in the gaps. The bridge required re-making with the incorporation of pink ceramic at the necks of the pontics to ‘seal’ them to the alveolar ridge.

## Pre-Operative Considerations for Conventional Bridgework

### The patient

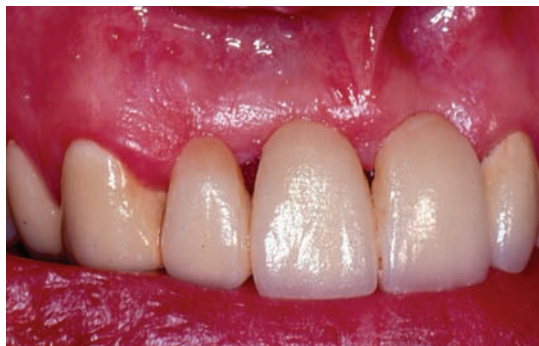The patient must be well motivated and clearly informed of his responsibilities in maintaining the proposed restoration and understand the sequence of appointments and what is to be achieved at each. He must be capable of maintaining good plaque control and any caries, periodontal disease and poor restorations must have been stabilised.



**Fig. 20.6** Features of bridge pontics. (a) The ridge contact of a premolar pontic. Ceramic covers the soft tissue, (b) The embrasure spaces are made wide enough to allow cleaning, (c) Superfloss being used to clean the embrasures and fitting surface of an anterior pontic.

### The occlusion

A pre-operative occlusal analysis should have been performed (Chapter 14) and consideration given to possible tooth movement in order to achieve more favourable tooth relationships.

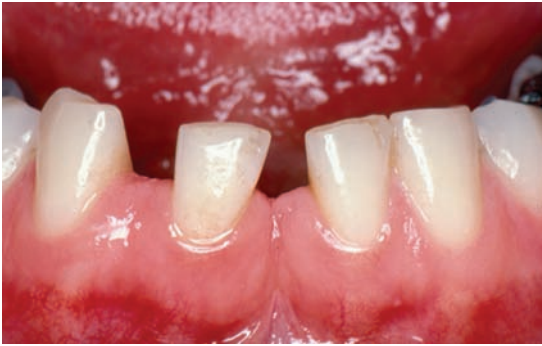

**Fig. 20.7** A bridge replacing 21| where there is considerable alveolar resorption. The spaces between the pontics are unaesthetic, collect food debris and interfere with speech. The bridge needs to be remade with pink ceramic blocking the spaces.

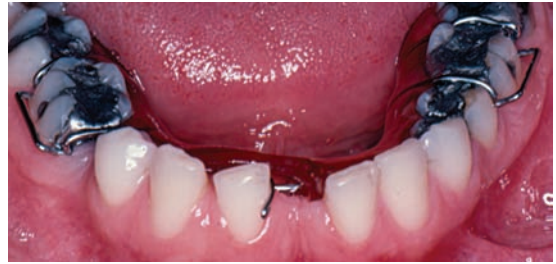Orthodontics has an important role to play in mouth preparation where there are malposed teeth or uneven spacing, particularly anteriorly. Uneven spacing is illustrated in Fig. 20.8. The two spaces have been ‘collected’ into the correct place for a single pontic.

Equilibration of pre-centric prematurities is desirable on those teeth that are destined for preparation. If a prematurity is removed by the preparation without knowledge of its relationship, the occlusal pattern can be changed leading to loss of occlusal clearance of the preparation (Chapter 14).

The pattern and strength of occlusal function in lateral and protrusive excursions is of great importance in anterior bridgework. For example, an upper lateral incisor can be replaced as a cantilever bridge from the canine in favourable cases. But this design should not be used if the pontic will receive lateral stresses from the lower incisors in lateral excursions. This would result in unfavourable rotational forces being applied to the canine. In these circumstances, the bridge should either have positive canine guidance, thereby discluding the lateral incisor pontic, or



(a)



(b)

**Fig. 20.8** Pre-bridge orthodontics. (a) The uneven spacing caused by the loss of one central incisor would make bridgework difficult; (b) the lateral incisor has been retracted by a simple appliance and the single tooth space can now be restored with a cantilever bridge.

involve the central incisor as well in a fixed–fixed design (Fig. 20.9).

### Abutment tooth assessment

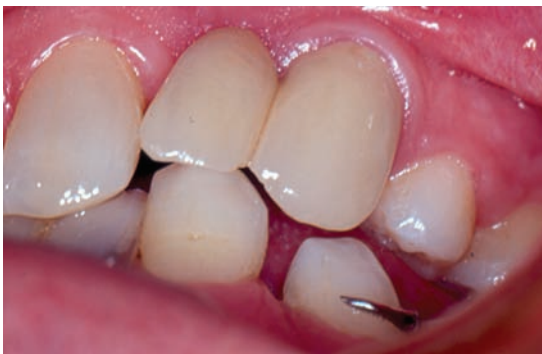The biological integrity of all the teeth must be clear from the start. Those teeth to be included in the bridge should not have pulps of dubious vitality nor have any root fillings of questionable prognosis.

Loss of periodontal support does not in itself preclude the use of particular teeth as retainers, but the disease must be controlled and stable. This will involve a thorough periodontal assessment and associated therapy. If the patient has worn a partial denture before bridgework was contemplated, there

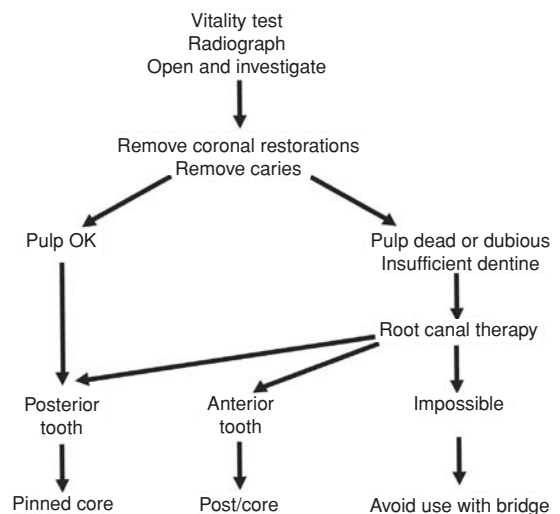
may be gingival complications if the denture was tissue borne. This has been discussed in Chapter 13.

These points, then, imply that a very thorough examination of the mouth aided by vitality tests and radiographs (Chapter 2) is essential prior to the prescription of bridgework.

Teeth that are provisionally designated for retainers should have any restorations of unknown origin or quality removed, and the remaining tooth examined to determine its physical and biological state (Fig. 20.10). Even if the restoration's natural history is well known, it must be assessed for its possible durability under a retainer when prepared. A simple



**Fig. 20.9** The 2 has been replaced as a cantilever bridge from the 3. In left lateral excursion, the pontic takes all the load and transmits this as rotational forces to the canine, which was painful. The bridge should have been made to maintain canine guidance.



**Fig. 20.10** The treatment of potential abutment teeth.

example is the replacement of a non-pinned amalgam by a pinned core because the tooth substance providing the retention of the former might well be removed during preparation.

## Aesthetics

The provision of good aesthetics is clearly an important goal for both the patient and the continuing reputation of the clinician!

The basic design outline will detail those areas to be tooth coloured and those to be constructed in metal. The patient should be aware of and approve such recommendations. Now further consideration must be given to the particular characteristics of tooth colour and position. The technician must be involved at this stage so that he can give advice about any shade matching problems that might dictate a change in design or might require special techniques.

If the existing tooth shape and position is satisfactory for appearance and function, then this must be copied exactly. This original template may be in the form of a denture or a semi-permanent resin-retained bridge. However, if a change in aesthetics is proposed, then this needs to be clearly defined at the planning stage.

Small changes, such as the closure of a diastema, can be easily accomplished, but major changes, such as reduction of overjet, are far more complicated. This may involve elective devitalisation of teeth outside the proposed arch line, together with post and cores, and, worse still, the positioning of retainers or pontics in zones where tongue activity may make them unstable.

This type of major cosmetic change should only be attempted when the patient's objectives and motivation are clearly established, and the clinician is clear in his own mind that these can be satisfied. Additional abutments will need to be included in the design to withstand the unfavourable muscle forces.

The management of aesthetics is discussed in more detail in Chapters 21 and 23.

A word of warning – dentists and plastic surgeons are prone to the attention of perfection seeking individuals. If the patient appears to be making unreasonable or strange demands, the dentist should be suspicious. It is better to refuse to provide treatment, tactfully.

## Basic Bridge Designs

Much (if not all) bridge design is empirical, based on the accumulated, acquired wisdom of clinical

experience, or simple personal prejudice! As has already been stated, very little objective work has been carried out on the biomechanics of the subject and it is doubtful as to how much in the way of physical laws would be appropriate in an area that is so dependent on biological status and response. It is a truism to say that every case is different.

A few basic guidelines can be advanced, such as:

- Keep designs as simple as possible  
For example, if two upper incisors are being replaced, make two three-unit bridges, rather than one six unit
- Use canine or molar teeth as abutments wherever possible
- Avoid upper lateral incisors as strategic abutments

The experience with resin-retained bridgework discussed earlier has led to the use of fewer abutments for crown-retained bridges and single crown-retained single pontics are used to replace incisors, canines and premolars.

However, the upper lateral incisor must be avoided as a single abutment; its root is not sufficiently substantial. If a central incisor cannot be retained by the other central, then it is necessary to involve the canine and construct a three-unit bridge.

Perhaps the principal limiting factor in crown-retained bridgework is the condition of the potential abutments. Longevity studies show that posts and cores are the worst retainers and of course the quality of the root filling is yet another problem. Dubious pulps should be avoided.

As will be discussed in Chapters 22 and 23, the use of implants removes the uncertainty of using teeth of dubious quality to support expensive restorations. The days of extensive crown-retained bridges are numbered!

## Precision Retainers

Simply, these are connectors that retain dentures without the use of externally visible clasps. The denture may be a complete denture or a partial, unilateral or bilateral. The unilateral partial denture is sometimes called a *removable bridge*. This is considered to have an advantage over a conventional bridge in that it is partly tissue borne, and therefore larger spans can be contemplated. Again, this is an empirical decision.

*Precision retainers* consist of two precisely interlocking parts, a male and a female, one of which is soldered into the retaining crown and the other which is

processed into the denture. The part fitting the retaining crown may be intra or extracoronal. The intracoronal type requires a more extensive tooth preparation to accommodate it within the crown profile.

There are many designs, most named after their inventors. Some include internal springs and stress breaking devices, and others fix the denture permanently by means of minute screws. They were developed in the late nineteenth century when many dentists believed that all prostheses needed to be removed for cleaning and fixed bridgework was decried for this reason.

Precision retainers are expensive and technically demanding to use, but do have advantages in a few particular cases. Where there has been extensive alveolar loss, denture base material is often necessary to make up the deficiency and this can be retained by adjacent teeth without an extensive denture base and clasps. Larger partial dentures may be aesthetically more pleasing without clasps, but teeth having the precision retainers on them must be splinted for support to other teeth, thus making the overall treatment plan complicated, costly and technically demanding.

The use of precision retainers in complete dentures is discussed in Chapter 26.

## Special Problems

### Cleft palate

With modern orthodontic and plastic surgical management of the cleft palate, the cases with massive

crown work to retain obturators are a thing of the past. The cases treated by modern techniques, though, may require crowning of teeth which are malaligned in the cleft, or bridges to replace missing teeth in the cleft area, particularly the lateral incisor.

Bridgework design must be modified so that the bridge is not fixed on either side of the cleft. This applies equally to resin-retained bridges and conventional bridges. The cleft may only be stabilised by fibrous tissue, and movement between the maxilla and premaxilla is possible. The forces generated by such movement will be easily sufficient to debond a resin-retained bridge of a fixed–fixed design, and cantilever types will be more reliable.

### Hypodontia

Congenitally absent teeth can present considerable restorative problems. The common occurrence of missing upper lateral incisors and retained deciduous canines was discussed in Chapter 16.

Cases with several missing teeth are usually associated with considerable drifting of the other teeth and these usually have small crowns. These cases must be treatment planned with the orthodontist to discuss tooth movement into more favourable positions to support bridgework. If each missing tooth can have a natural tooth on each side, and these natural teeth have reasonably sized crowns, then bridgework will be possible. Larger spaces coupled with small crowns would be treated ideally by using implants but usually commits the patient to partial dentures.

### Design of Conventional Bridgework – Summary

Much of bridge design is empirical.

The important considerations are choosing abutment teeth that are biologically and structurally sound and have healthy periodontiums.

Full assessment of the occlusion and tooth alignment using a diagnostic mounting is essential.

Full crown retainers of gold or ceramic fused to metal are the simplest and most reliable retainers.

Malaligned teeth may be incorporated in bridgework after re-alignment by pre-operative orthodontics or by using assembly joints or copings.

# Chapter 21

## Fixed Prosthodontics: Conventional Bridgework – Clinical Procedures

The decision to construct a bridge has been made and its design decided. The abutment teeth are stable with appropriate foundations in place. This chapter discusses the clinical, practical stages in bridge construction.

The sequence of clinical stages in constructing a bridge is:

- 1 Pre-operative diagnostic mounting and model surveying
- 2 Register shade and plan provisional bridge
- 3 Preparations
- 4 Working impression
- 5 Occlusal registration
- 6 Try-in and trial cementation
- 7 Permanent cementation
- 8 Review and recall

### Pre-Operative Diagnostic Mounting

The original diagnostic mounting may be adequate for this stage, but, if any teeth have been equilibrated, or major changes in tooth contours have been made by cores, then new impressions should be taken and a new mounting made.

The mounting should be in centric occlusion unless this position cannot be defined accurately. In this case centric relation will be used (see Chapter 14).

The occlusal registration for a centric occlusion mounting should be without an inter-occlusal record if at all possible. The orientation of the models to the position of best fit, together with checking this position against the patient, marking it and mounting should be satisfactory for most patients.

If missing teeth prevent the accurate orientation of the models, then occlusal rims will be necessary, but these should be adjusted carefully to ensure that centric occlusion is being recorded, and not a position influenced by the presence of the rims in the occlusion.

If there are enough teeth, but the position is imprecise, two 'islands' of registration material, one in each quadrant of the lower arch, will provide the minimum

interference with closure, and will locate the models accurately for mounting with tooth to tooth contact.

The incisal table should be customised to the protrusive and lateral excursions (Chapter 14).

The mounting will provide a record of centric occlusion before it is destroyed by tooth preparation, and will be the basis for the provisional bridge. Accurate surveying to decide the path of insertion will be done and a duplicate mounting will allow trial preparations to be carried out as a rehearsal to predict problems of angulation and paralleling.

### Shade and Provisional Bridge

The shade and tooth characteristics should be recorded at the planning stage, particularly before teeth are cut.

The provisional bridge must also be planned before the teeth are cut. Its functions are:

- Protection of cut dentine
- Maintenance of the occlusion
- Maintenance of gingival health
- Restoration of aesthetics
- Maintenance of abutment position and in some cases
- Diagnosis of changes to the occlusion and/or aesthetics

The provisional bridge may be made at the *chair-side* after the preparations have been completed or in the *laboratory* either before or after the preparation stage. The majority will be polymeric, but spans of more than four units will need a metal sub-frame and polymer facings for durability. The provisional may be in use for as long as six weeks and therefore needs to be constructed carefully.

Chairside construction of provisionals is appropriate for short spans of uncomplicated bridgework. These may only be in place for a matter of a couple of weeks, and for this relatively short period, the inferior aesthetics and lower strength are not usually a problem.

### Chairside construction technique

The pre-operative model is used as a template with the shape of the pontics and retainers being provided either from the diagnostic waxing or from the addition of denture teeth to the model. The areas of the buccal and palatal surfaces that will have minimal reduction should be overcontoured by adding wax so that eventually this will be reproduced in the provisional as thicker walls. Without this, the overlying polymer would be too thin for adequate strength.

An impression is made of the area of the bridge in silicone putty. Only a sectional impression is required, but this must extend by at least one tooth either side of the abutment teeth so that the impression, or mould as it is to become, can be stabilised in the mouth. A refinement of the technique is to use a vacuum formed polymer sheet that is moulded to the pre-operative model or diagnostic waxing.

At the chairside, following the completion of the preparations, the seating of the mould is checked for accuracy, gingival retraction cord placed to protect the gingival tissues, a smear of petroleum jelly applied to the dentine surfaces and a self-curing polymer, preferably one designed for provisional bridges, mixed and syringed around the necks of the prepared teeth and into the mould. The filled mould is seated onto the teeth, located correctly and left in place until the initial set of the polymer has occurred. The mould is then removed together with the new bridge and its excess. The excess is trimmed carefully back to the preparation margins and the pontic gingival margins rounded. The embrasures, particularly at the cervical margins, must be cleared carefully.

The bridge is replaced onto the teeth, and the marginal adaptation checked. The occlusion is then corrected using abrasive points following identification of inaccuracies with shimstock and articulating paper. Additions can be made easily to the polymer as necessary (Fig. 21.1a).

### Laboratory construction technique

The all-polymer bridge can be made by flasking the waxed trial preparations model, perhaps having

incorporated denture tooth facings as appropriate, and processing in the same way as a denture. At the chairside, the fit of the bridge is likely to be inaccurate because the free-hand cutting of the teeth is unlikely to match the free-hand cutting of the model. The bridge will therefore need to be relined in polymer on the preparations to achieve accuracy (Figs. 21.1b,d).

The metal-based bridge, whether cast in silver, student's alloy or even bonding alloy, requires exactly the same technique as that required for the final restoration. It needs to be made from an impression of the finished preparations as quickly as possible, with an all-polymer bridge made at the chairside as a very temporary intermediate restoration (Fig. 21.1c).

If the provisional has been used to verify a new occlusal scheme and has been adjusted for this or for tooth shape and position, an impression of the arch including the bridge must be taken and remounted to the existing mounted opposing model. The incisal table should then be re-customised.

### Preparations

Whilst each abutment will be prepared in accordance with the basic principles discussed in Chapter 15, the major consideration in most bridgework is achieving a single path of insertion for the bridge.

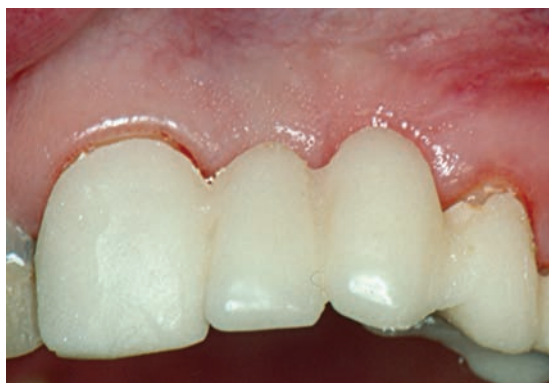The desired path of insertion should be decided from the diagnostic mounting using a model surveyor and the path should be marked on the model abutments. If an assembly joint is to be used with different paths for each abutment, these paths can again be marked on the model.

In short span bridges, with two or three abutments, the path can usually be transferred to the mouth by eye, with extreme care being taken to keep the burs in this single path whilst cutting.

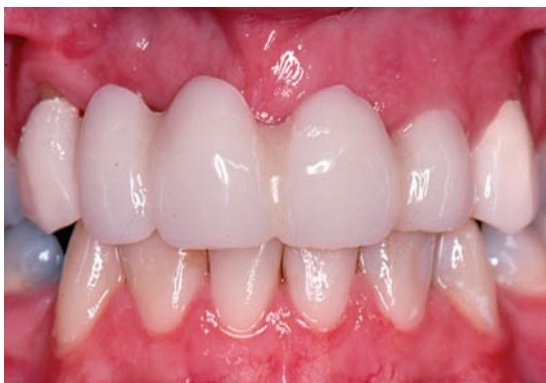For longer spans and multiple abutments, some additional help will be necessary. Proprietary parallelometers can be purchased, the simplest being a pair of parallel pins on an extending arm.

This may not be sufficient for cross-arch work and some reference device can be made for the particular patient in the laboratory. A flat sheet of 4-mm acrylic sheet is trimmed to fit the arch to be prepared, and modified with cold curing acrylic to locate to the occlusal surfaces accurately. It should extend laterally beyond the buccal surfaces of the abutment teeth by about 2 mm.

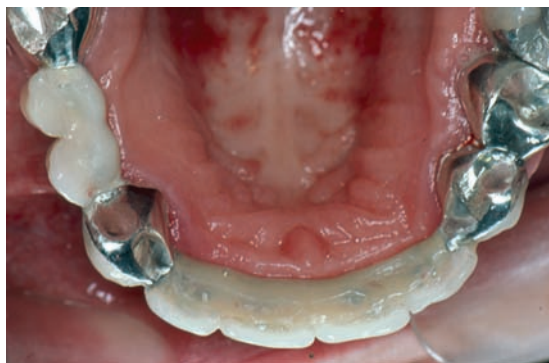



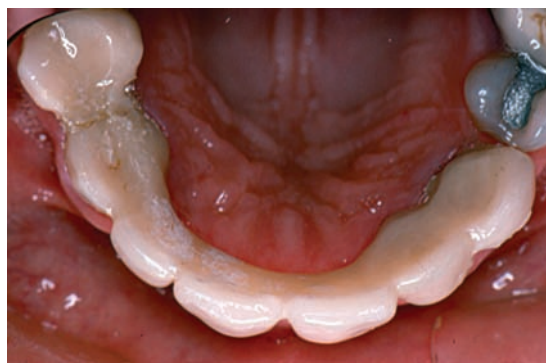(a)



(b)



(c)



(d)

**Fig. 21.1** Provisional bridges. (a) Polymeric, chairside made type. This has very bland aesthetics and has to be overcontoured for strength. It is satisfactory for short spans, or for a few days whilst a more accurate provisional is made, (b) and (d) All polymer, laboratory constructed type. The labial aspects are made from denture tooth facings and the remainder is made from a waxing and hydroflask-cured acrylic. This is suitable for trying new occlusal schemes and changes in aesthetics. If it is made from trial preparations on the diagnostic mounting, the retainers will need rebasing in the mouth with the addition of cold curing acrylic. Laboratory-cured composite is also satisfactory, (c) Cast silver/polymer type. This is necessary for long spans. The incisors are denture tooth facings, retained to the metal by hydroflasked acrylic. The occlusion and aesthetics can be checked accurately on this type of provisional.


The model is mounted on a surveyor whose surveyor rod is aligned with the chosen path of insertion. The acrylic sheet is placed on the model and holes are drilled by a surveyor-mounted handpiece to locate pins at the side of each abutment. The pins can be screwed in, or glued by cyanoacrylate cement. This device will locate in the mouth to indicate the desired paths for each abutment.

Additional help can be provided during the tooth preparation by cutting the teeth roughly and then taking an alginate impression. This is cast in plaster mixed with hot water for a rapid set, and the resulting model checked with a surveyor for accuracy of paral-

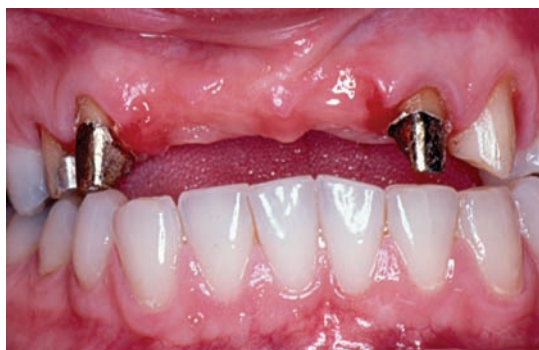leling whilst the patient remains in the chair and then has the preparations defined finally afterwards.

The presence of posts and cores in the design can be used to aid paralleling. Preparation for the posts is the first stage and an impression is taken of the post holes. The cores can then be waxed parallel to the predicted path of insertion (Fig. 21.2a), and when cemented, provide a very accurate guide for the preparation of the other abutments (Fig. 21.2b).

Modification to the basic design of abutment preparations is also necessary in the connector region. Tooth removal should be increased here to provide additional strength in the subsequent casting. Where



(a)



(b)

**Fig. 21.2** (a) Waxing the cores for an anterior bridge. The model has been mounted on a surveyor to align the cores precisely with the chosen path of insertion, (b) The cores cemented. The bridge is to replace 21|1 from 43|23, and the preparations have been completed using the cores as alignment guides. Note the shape of the vital tooth preparations giving good retention and the contour allowing correct thickness of ceramic. Note also the lack of gingival trauma after preparation.

precision retainers or other non-rigid connectors are to be used, box preparations will usually be necessary to accommodate them.

## Impression and Shade

These have been dealt with in Chapters 16 and 17.

## Occlusal Registration

Centric occlusion is required, with clear tooth to tooth contacts. If a position of ‘best fit’ is still present, in spite of occlusal reductions, this should be used without an inter-occlusal record; reproduction of the position from the pre-operative mounting will be possible.

If centric occlusion has been lost by the tooth preparation, then the most accurate method of registration is by *registration copings*. These are shells of acrylic or metal that fit the prepared teeth accurately and onto which cold curing acrylic is added to register the tooth relationships (Fig. 21.3). The coping can be made on the master die and used to check that the preparation margins have been accurately reproduced. Metal, such as cast silver, is better than polymer for this purpose if the margins are really questionable.

Alternatively, copings can be made intraorally on lubricated preparations by free-hand application of polymer and the occlusion registered at the same time. Clearly, these cannot be used to check margins.

The master model, when completed, is mounted to the untouched opposing arch of the pre-operative mounting. A further face-bow registration is therefore not necessary.

Articulator angles will have been determined from the diagnostic mounting and can be set again for the master models. However, when constructing crowns and bridges, it is common to use condylar angles that are slightly lower than average. This has the effect of making cusp heights lower, cusp slopes shallower and fossae more open. Therefore, the likelihood of introducing occlusal interferences unwittingly is much reduced.

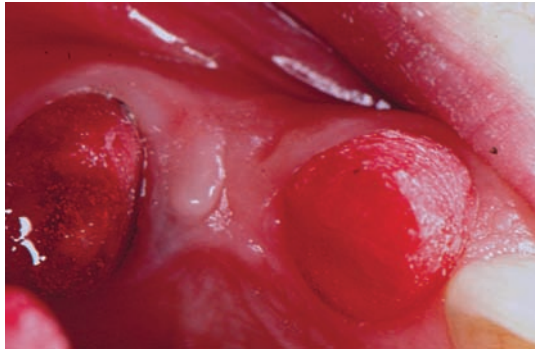Upon completion of the impression and registration, the provisional bridge should be cemented with a weak ZOE cement, or a proprietary temporary cement.

## Try-in

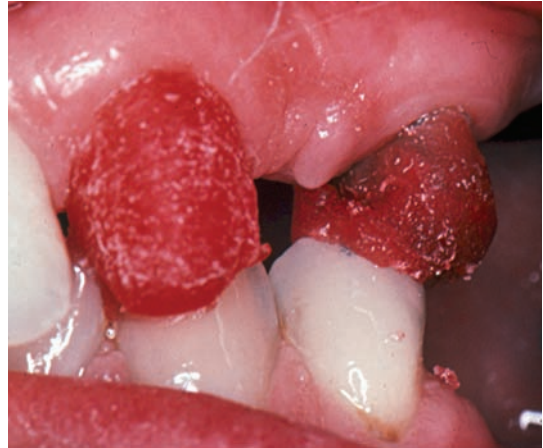This is possibly the most critical stage, wherein the established errors are either seen and accepted, or completely missed. It depends on the level of perfection and perception of both the dentist and the technician as to what passes and what is rejected. Only the obvious needs stating – the larger the errors, the less the chances of success for the restoration.

## Metal sub-frame

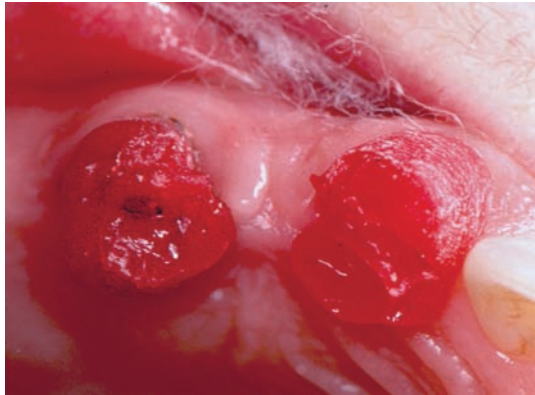
The try-in of the metal sub-frame before the addition of ceramic has several advantages:



(a)



(b)



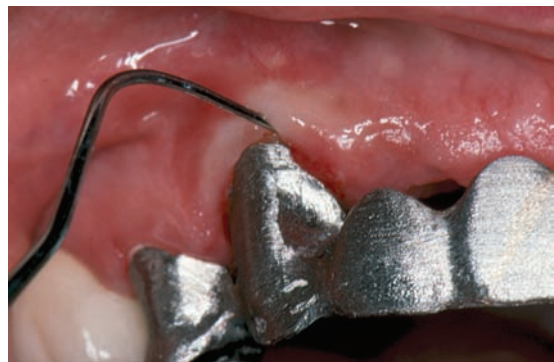(c)

**Fig. 21.3** Laboratory-made copings of pattern acrylic for occlusal registration. (a) Occlusal view; (b) buccal view in occlusion; (c) occlusal view of registration imprints.

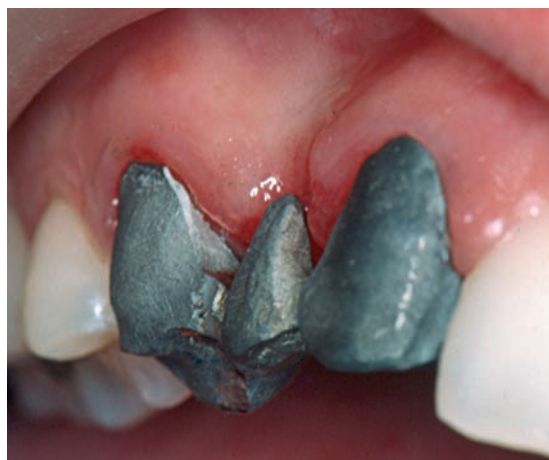- The accuracy of the casting can be checked. If there are errors, then the time and cost of adding the ceramic to a deficient base are avoided
- The localisation between abutments can be checked and changed if necessary without jeopardising the ceramic by resoldering
- The occlusion can be checked and adjusted without damaging the ceramic glaze

For short spans, where the dentist and technician are confident in the impression, then a metalwork try-in could be omitted. For longer spans there should always be one (Fig. 21.4). Now that the use of shoulder ceramics is routine, the metal sub-frame does not need to extend to the outer edge of the shoulder. However, for the purposes of a metal try-in the technician should extend the metal to the outer edge of the shoulder so that the fit can be checked. This excess metal will be cut back before the ceramic is added.

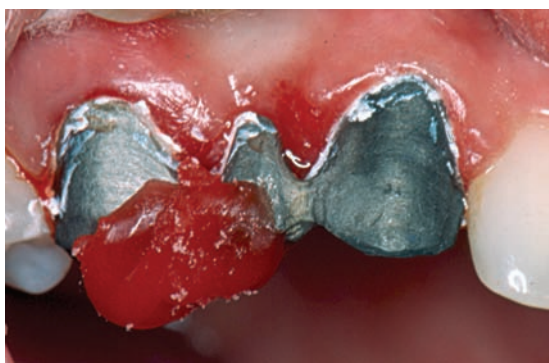Where one retainer fits and the other(s) does not seat fully, there can be a localisation error. The bridge



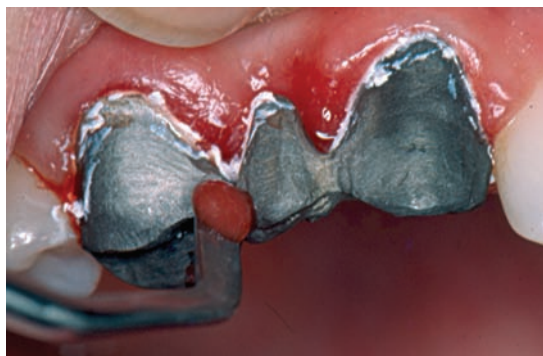**Fig. 21.4** A metalwork try-in showing the examination of the margins.



(a)



(c)



(b)

**Fig. 21.5** Relocalisation of a metal sub-frame. (a) The try-in did not seat on the premolar. The bridge has been sectioned between the pontic and the premolar retainer, and now seats correctly. (b) A zinc oxide–vaseline paste has been applied to the fitting surfaces to stabilise the bridge during application of the fluid acrylic. (c) The acrylic must be extensive to make sure that there is no movement upon removal of the bridge and during its journey to the laboratory.

should be sectioned carefully into individual pieces with one connector being maintained to hold each pontic. Each retainer should be tried on its abutment individually (Fig. 21.5a). If each seats accurately, the new arrangement should be fixed by the addition of cold curing pattern acrylic in the mouth.

To stabilise the retainers for this procedure, a small amount of non-setting paste, e.g. zinc oxide in Vaseline, should be applied to the retainers' fit surface (Fig. 21.5b). A non-residue, burn-out pattern polymer is then carefully applied to the sectioned joint to stabilise it rigidly (Fig. 21.5c). The relocalised bridge is then removed, cleaned and returned to the laboratory for soldering.

Failure of a sectioned retainer to seat requires a new impression after the preparation has been inspected carefully for undercuts. These may have created an impression fault not seen on the die.

If the dentist is at some distance from his laboratory, relocalisation may be impractical and it is then more common for a complete new impression to be taken.

### Final bridge

The bridge should be examined carefully with the teeth dried and isolated, and where possible, a pack in place to prevent loss of the bridge into the pharynx. The following must be checked:

- Marginal adaptation of retainers
- Retention and stability
- Integrity of contact areas with adjacent uncut teeth
- Adaptation of the pontics to the soft tissues
- Occlusal relationships in centric occlusion, centric relation and excursions
- Aesthetics – colour, shape and tooth position
- Speech
- Patient approval

### Marginal adaptation

A probe should traverse all the margins smoothly from tooth to retainer without catching. Positive edges can be trimmed back, but negative edges are a deficiency and the retainer must be modified or remade. If the master die does not reproduce the defective margins, then a new impression of the problem abutment is needed. The new die can be relocated alongside the satisfactory dies in a new model and the new retainer soldered into the new restoration.

If the margin was reproduced on the original die, then ceramic could be added to the retainer. Soldering, though, to build out a deficient metal margin is not usually acceptable.

If a retainer is not seating onto the abutment margin, then the following should be checked:

- Fit surface of preparation – temporary cement remaining
- Fit surface of retainer – ceramic present, casting excess from airflow in investment
- Contact areas – tight, preventing seating
- Movement of abutments under provisional bridge
- Localisation of retainers – one seats and the other(s) lifts off

The first four are fairly easy to overcome. Careful inspection will reveal extraneous material and use of floss will demonstrate tight contacts.

Small tooth movements may have occurred whilst the provisional bridge was in place. This may be due to occlusal forces or due to slight displacement by the temporary cement. Not every bridge seats home exactly at the first attempt, and small discrepancies can be overcome by ‘stressing’ the periodontal ligament by alternate loading and releasing.

Cotton wool rolls or a tongue spatula may be placed on the occlusal surface of the bridge, and by

alternate clenching and relaxing, the patient can induce minor movements of the abutments. This works only for small seating problems.

### Retention and stability

The bridge should not be dependent on its cement lute for retention. Looseness may be caused by over-tapered preparations or poor adaptation of castings. The fit of the individual dies on their retainers should be checked and if these are loose, the bridge should be remade. If the dies are tight, then an impression fault is possible; the impression will need to be retaken after checking the parallelism of the preparations.

The bridge should not rock when pressure is applied to each retainer and if it does there is likely to be a casting error on an individual retainer or seating problems referred to earlier.

### Contact areas

Check these with floss. A correct contact allows floss to ‘click’ through on pressure. Slack contacts will require the addition of solder or more ceramic to correct them. Tight contacts should be eased and repolished.

### Adaptation of pontics

The pontic should touch the underlying soft tissue lightly on insertion of the bridge. The neck of the pontic should blend smoothly with the alveolar ridge to promote natural cleaning during function.

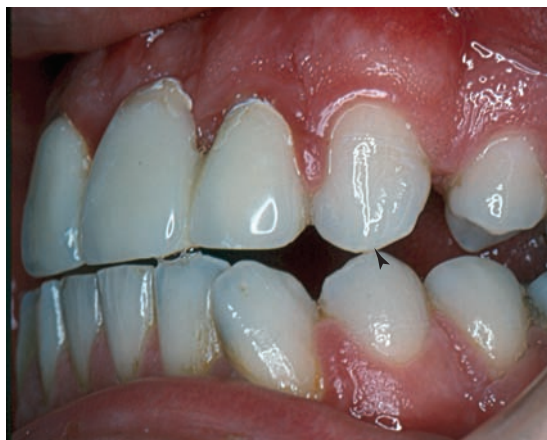### Occlusal relationships

Occlusal stability should be checked by marking each new cusp/fossa relationship with articulating paper and checking that each holds shimstock on light closure. The natural cusp/fossa relationships should also be checked with shimstock to ensure that the bridge is not preventing even occlusion elsewhere.

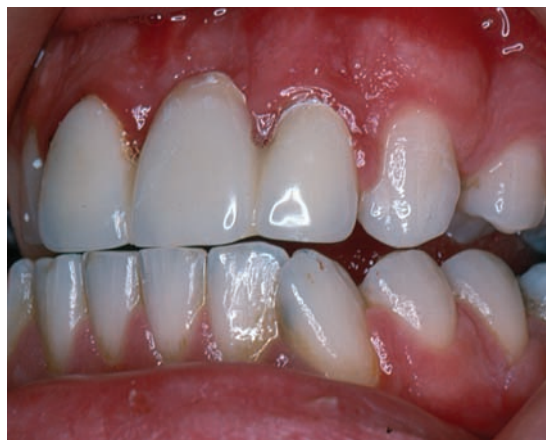Check mandibular closure on the retruded arc of closure to centric relation to ensure that the bridge is not introducing new pre-centric premature contacts.

Adjust cusp slopes or fossa width but not supporting cusp height, as the removal of the cusp tip will also remove occlusal stability.

Check lateral and protrusive excursions for freedom of movement and for the presence of non-working interferences. If the bridge is reproducing canine guidance, this must be steep enough to disclude the non-working side. If interferences are introduced, the bridge must be modified, rather than equilibrating other teeth. Similarly, incisal length should provide



(a)



(b)

**Fig. 21.6** (a) A non-working interference in protrusion (arrowed). The patient has a provisional bridge at 21|1. In protrusion the incisal edges are not in contact because of the interaction between 13 and 14. The choice is either to lengthen the incisors to disclude the interference or to equilibrate. (b) In this case, the appearance was satisfactory and therefore the interference was equilibrated.

enough depth of incisal guidance to disclude the posterior teeth (Fig. 21.6).

### Aesthetics

The patient should be the final arbiter of the appearance. Aesthetics were discussed in Chapter 16.

### Speech

A standard passage of prose to be read by the patient can be used, but it is better for natural speech to be the deciding factor. This means a period of trial cementation.

### Trial Cementation

Once a bridge is cemented permanently, the modifications that can be done subsequently are very limited. Therefore, it is better to fit the bridge with a weak temporary cement and allow the patient to try it for about 4 weeks for speech and function, and for the other members of the family to approve the appearance.

The patient must be warned, though, of the weakness of the cement, and to return immediately if there are any symptoms. This will usually mean cement failure in a retainer.

### Permanent Cementation

The patient's opinion and experience are discussed after the trial cementation, and the occlusal relationships rechecked. Modifications to tooth shape, colour and size are possible by refiring the ceramic. This may mean the refitting of the provisional bridge, whilst the permanent one is away in the laboratory.

If further modifications are made or the patient has any reservations, another period of trial cementation is indicated.

Only when all are satisfied should the bridge be cemented permanently. After the cement has set, check the marginal adaptation again and clean excess cement from the embrasures and from under the pontics.

Teach the patient the appropriate oral hygiene procedures (Chapter 20).

### Review and Recall

Finally, check the bridge again a week or two after cementation and make sure the patient is performing the oral hygiene required and that there are no problems with this. The bridge should be examined again 6 months later and the apical condition of all the abutments reviewed radiographically at 1 year after fitting. Further radiographs should be taken

routinely every 4 years or so. Silent pulp death and apical infection of abutment teeth are possible.

## Anterior Bridgework

This presents the dual problems of combining aesthetics with function. It is an important part of bridge-work, since the cosmetic aspect is a strong motivating factor for the patient. This, coupled with the desire to be rid of the intrusion of a partial denture, provides a demand which can only be satisfied by the highest clinical and technical standards. The ability to make good anterior bridgework is a good practice builder; the converse is also true.

The patient will either have a partial denture or an intermediate bridge and there are two possible lines of treatment. The existing prosthetic teeth may be satisfactory from the aesthetic and functional viewpoint, in which case they should be copied exactly in combination with the new retainers.

On the other hand, one or both aspects may be unsatisfactory and this will necessitate more in the way of diagnosis and planning and a longer stage with the provisional bridge.

## Replacement of existing aesthetics and function

Where the patient is to have a denture or bridge replaced that has *satisfactory* aesthetics and function, the sequence following stabilisation is:

- 1 Diagnostic mounting and examination of the occlusion with old prosthesis included
- 2 Customise the incisal guidance table of the articulator
- 3 Provisional bridge, tooth preparations
- 4 Provisional bridge approval
- 5 Final bridge – trial cementation and permanent cementation

## Changing aesthetics and/or function

Where the existing teeth and/or function are *unsatisfactory*, the sequence is:

- 1 Diagnostic mounting and examination of the occlusion
- 2 Diagnostic waxing to establish new aesthetics and/or function
- 3 Customise incisal guidance table to diagnostic waxing

- 4 Preparations and impression, chairside provisional
- 5 Construct provisional bridge on master model to diagnostic waxing
- 6 Check function and aesthetics of provisional, modify if necessary
- 7 Approval of provisional
- 8 If modifications have been made, impression of provisional in situ
- 9 Articulate model of approved provisional, re-customise incisal guide
- 10 Mount master model, construct final bridge
- 11 Trial cementation
- 12 Permanent cementation

## Improving poor aesthetics

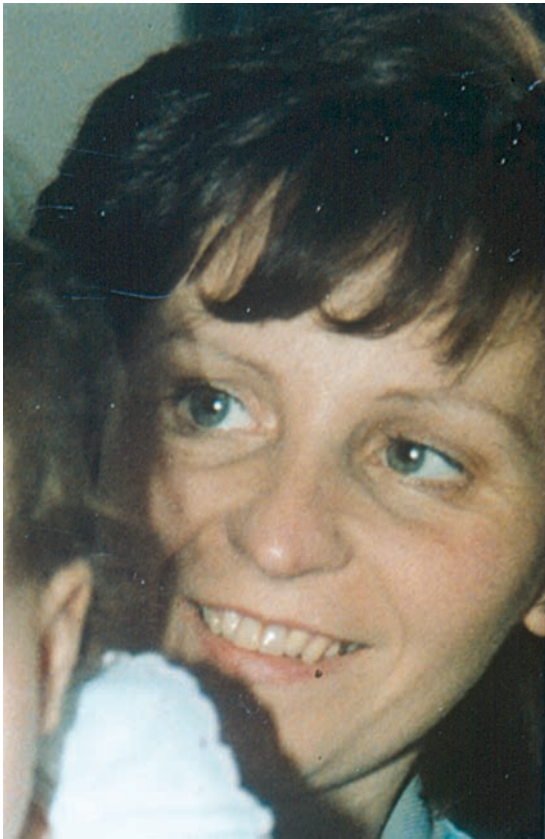The re-establishment of original aesthetics when these have been changed by a poor bridge or partial denture will be greatly helped by old photographs of the patient. Figure 21.7a shows a case where the upper central incisors were originally replaced by a partial denture following trauma. Some years later, the patient's general dental practitioner offered her a bridge instead of the denture.

The bridge design was a six-unit fixed–fixed bridge from the upper lateral incisors and canines. The bridge was fitted, apparently without the patient's agreement, and this is shown in Figs. 21.7b,c. The patient was unhappy with the appearance and if this is compared with the old photograph reproduced in Fig. 21.7a, it can be seen that the incisor angulation has been changed. The shade was also incorrect; the new bridge was Vita A1 in comparison with the shade of the adjacent teeth that was C2.

The sequence for the management of the case was that described earlier for changing aesthetics and function. Following the visit for the diagnostic mounting, the old bridge was removed by cutting each retainer with a serrated tungsten carbide bur (Jet Beaver). The underlying preparations were inspected and checked for vitality and were found to be satisfactory. An impression was taken and a 'temporary' provisional bridge made at the chairside.

With the aid of the old photograph a provisional bridge was made in the laboratory on the master model. It was fitted at the next visit with temporary cement. The patient wore this for 4 weeks and returned with the approval of her family and herself.

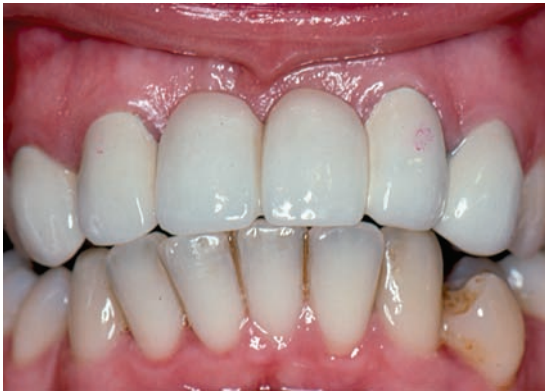An impression was taken of the provisional bridge in place and the model from this provided the guide for the technician for the tooth shape and position.



(a)



(b)



(c)

**Fig. 21.7** Unsatisfactory replacement of a partial denture by bridgework 1. (a) The patient seen in a family photograph with a partial denture replacing  $\overline{111}$ , (b) and (c) The first bridge showing poor contour and shade.





(a)

**Fig. 21.8** Replacement of the bridge shown in Fig. 21.7.

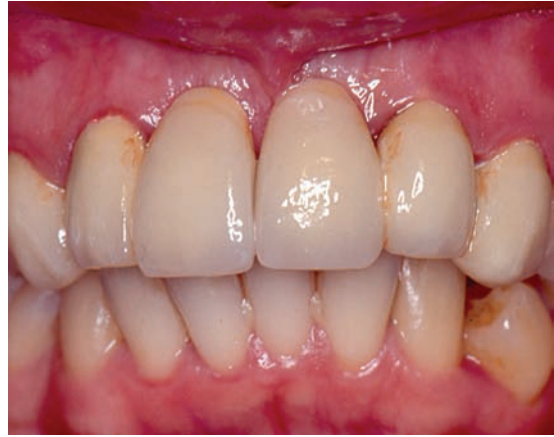The bridge design was changed for simplicity from a single six-unit bridge to two three-unit cantilever bridges. The trial cementation was uneventful and the bridges were cemented permanently 4 weeks later (Fig. 21.8).

### Alveolar resorption

The case described above has the pontics touching the edentulous ridge directly and, because there has been little resorption, the mucosa appears as natural gingival tissue in the pontic embrasures.

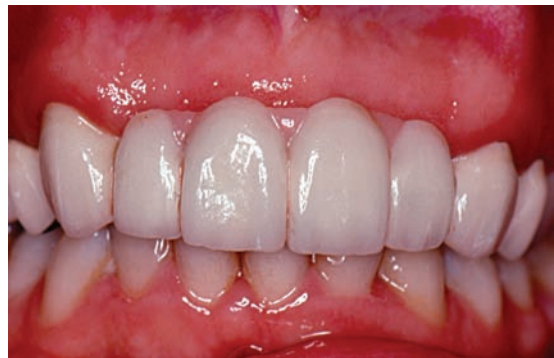Where there is more resorption, as was seen in the case shown in Fig. 20.7, the embrasures need to be filled with pink ceramic to eliminate the dark spaces seen between the pontics (Fig. 21.9).

The case shown in Figs. 18.12 and 18.13 illustrated the problem of aligning the incisors in relation to more alveolar resorption. The angulation of the incisors with their tips in the correct place and the necks against the resorbed alveolus leads to poor

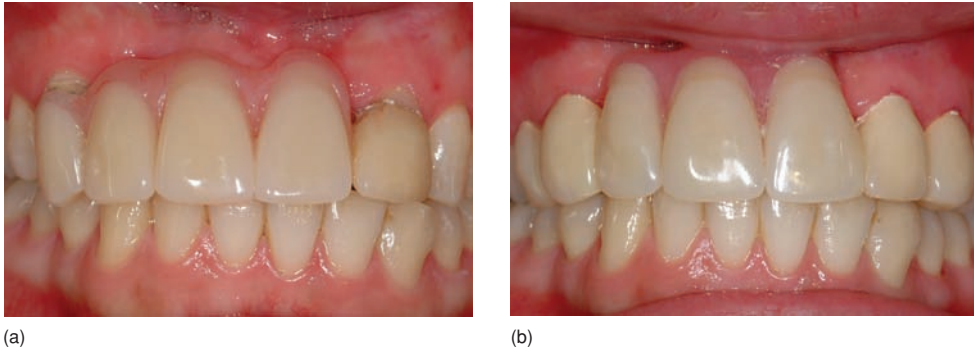


(b)

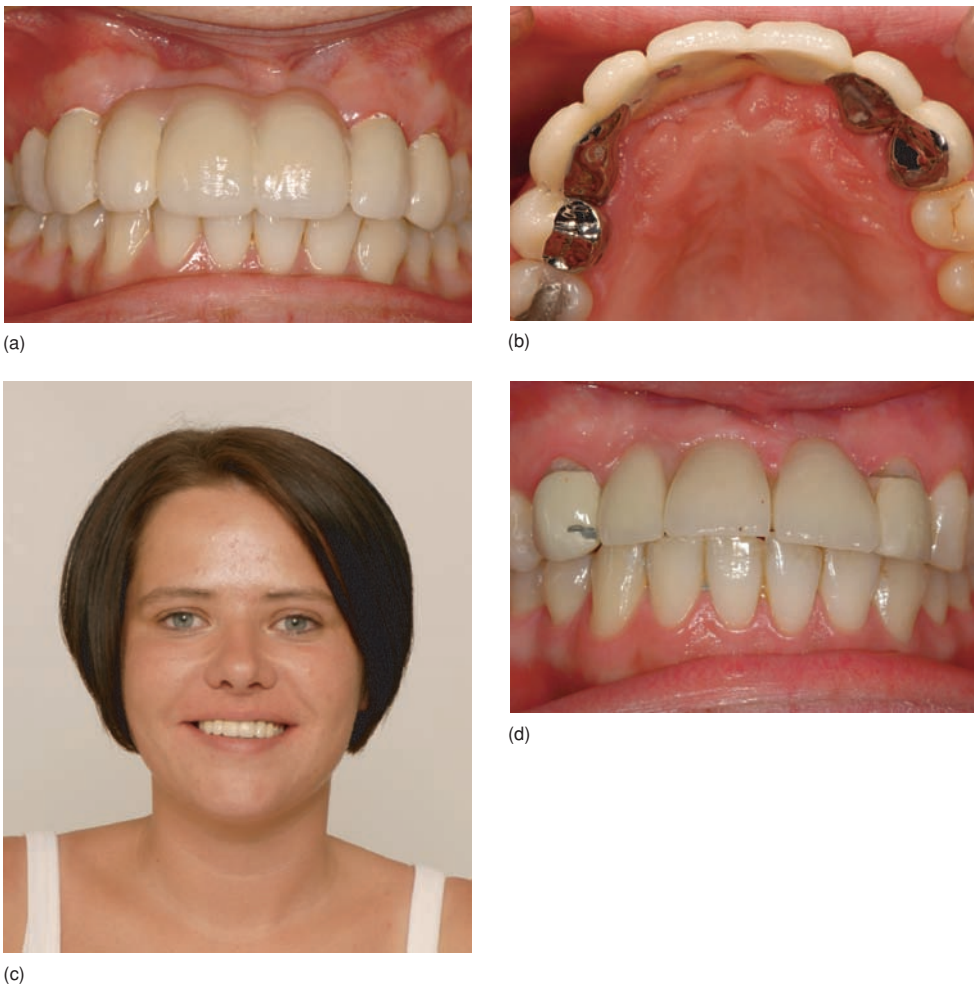aesthetics. This case had a diagnostic articulation and pre-operative periapical radiographs. The old bridge was removed in one piece and the condition of the abutments (vitality, coronal dentine) checked.



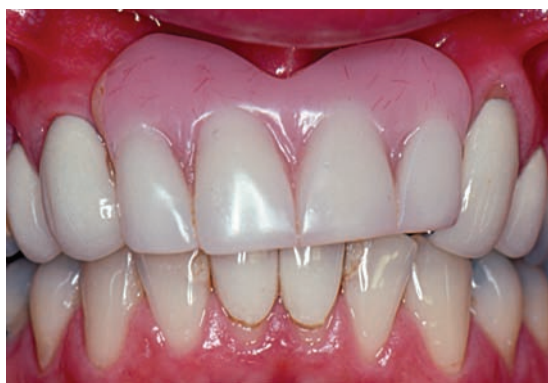**Fig. 21.9** Bridge replacing the upper incisors. Pink ceramic has been incorporated in the embrasures to hide minor alveolar resorption.



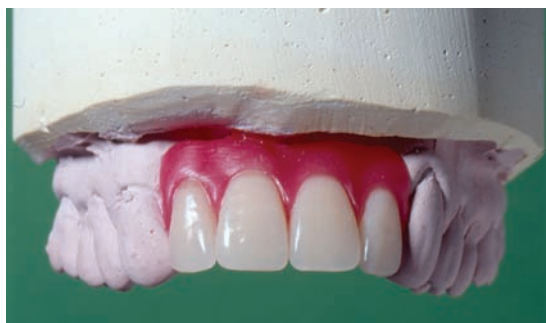**Fig. 21.10** Replacement of the bridge shown in Fig. 18.12. (a) A provisional denture has been made to establish the correct tooth position; (b) the tooth position incorporated in an acrylic provisional bridge.



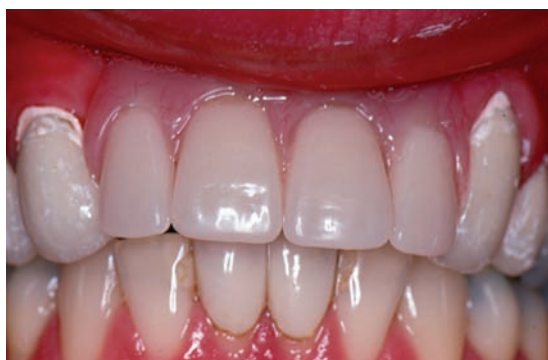**Fig. 21.11** (a) Labial view of the permanent bridge at the trial cementation stage, showing pink ceramic replacing lost bone, (b) Palatal view showing the line of the arch and its relationship to the incisive papilla, (c) The patient, (d) The old bridge shown again for comparison.



(a)



(b)



(c)

**Fig. 21.12** (a) This case has extensive alveolar resorption and  $\underline{21|12}$  have been restored by a precision retained denture which is very worn; (b) wax-up of a provisional denture to establish the correct tooth position, (c) Provisional denture in place. The crowns on  $\underline{43|34}$  have been removed, the preparations inspected and the crowns replaced with periodontal dressing to promote resolution of gingival inflammation.

The next stage was to establish the correct position for the incisors. This is most easily done using a provisional partial denture. An impression was taken after removal of the bridge and the old bridge replaced with temporary cement. At the next visit, the wax-based provisional denture was tried in and the tooth position checked. This can be changed easily if necessary and it is possible to replace the tooth mould if the size and shape is wrong.

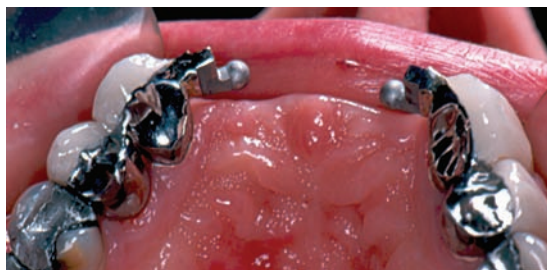The processed denture was fitted at the next visit (Fig. 21.10a), and the old bridge was sectioned to provide temporary crowns for the abutments. The upper right canine, which was non-vital, was left as a root with an overdenture tooth; this allowed more flexibility in the position of the teeth. Three weeks later, the patient agreed to the new tooth position and the denture was replaced by a provisional bridge with the shape copied from the denture (Fig. 21.10b).

The upper right canine was prepared for a post and core.

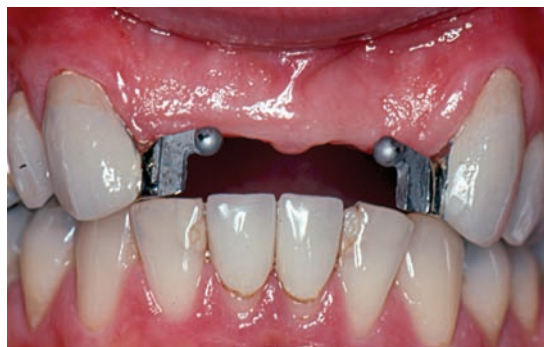When the bridge was approved by the patient, a model of it was mounted on the articulator and the incisal guide customised. To customise the incisal guide, cold curing acrylic was placed on the incisal table, and whilst soft, the incisal pin was moved in it with the tooth to tooth contacts being maintained in protrusion and lateral excursions. When hard, the table reproduced the movement paths that were guided by the provisional bridge contours (see Chapter 14).

The permanent bridge was then constructed through the stages of post/core cementation, impression, metal try-in, trial cementation and permanent cementation (Fig. 21.11).

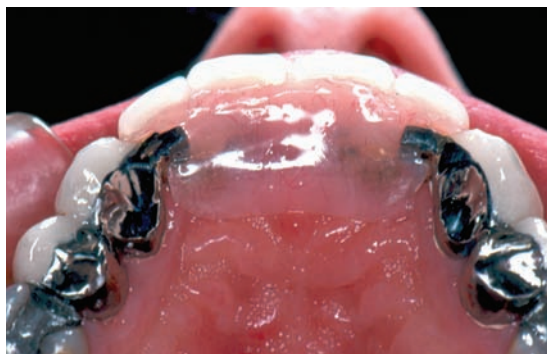If there is even more resorption then the use of simple pontics will be difficult. Then it would be



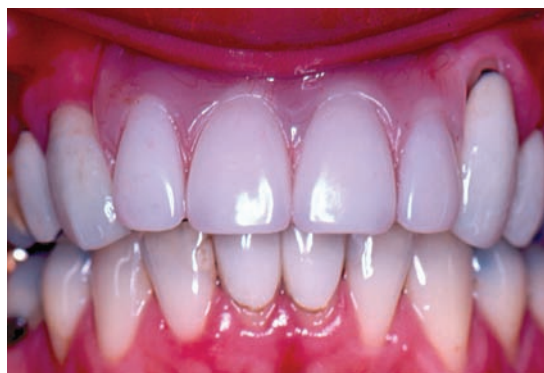(a)



(b)



(c)



(d)

**Fig. 21.13** (a) and (b) New soldered crowns with Mini-Dalbo precision retainers. Note the extent of the alveolar resorption, (c) and (d) The removable bridge in place.

better to use a denture base to make up the tissue loss and this can be incorporated in a precision retained removable bridge, rather than use a partial denture base.

The original denture (Fig. 21.12a) was worn and the tooth position was not correct. The new tooth

position was established by a provisional denture (Figs. 21.12b,c). The retainers on the upper canines and first premolars were replaced as soldered units with Mini-Dalbo precision retainers attached. The final denture, or removable bridge, is shown in Fig. 21.13.

#### Clinical Procedures for Conventional Bridgework – Summary

Detailed planning on an accurate diagnostic mounting is essential.

Planning will involve choice of the path of insertion, retainer and pontic design.

A provisional bridge will be needed to stabilise the abutments and restore aesthetics and function.

Retentive preparations parallel to the path of insertion will provide stability for the final bridge.

Use occlusal registration copings for accuracy of articulating the master model.

The try-in stage will reveal deficiencies in the fit and occlusion of the retainers and pontics.

Aesthetics must be approved by the patient; always use a trial cementation phase.

Always choose bridge designs that are simple.

# Chapter 22

## Fixed Prosthodontics: Basic Principles of Implants

Intraosseous implants are now well established for the support and retention of crowns, bridges and removable dentures.

This chapter describes the basic principles associated with their use.

### Historical Background

In 1941, Gustav Dahl introduced the *sub-periosteal implant*. This was designed for the treatment of patients with edentulous mandibles and consisted of a metal frame of vitallium (cobalt chromium molybdenum) fitted on the surface of the bone of the mandible below the periosteum. The technique involved surgical exposure of the bony ridge followed by an impression of it. The vitallium framework was made on a plaster model and was placed in the patient at a second surgical procedure. Such subperiosteal implants proved to have moderate success.

The first commercially available intraosseous implants were called *blade implants*, which were blade-shaped and generally made of steel. Initial cuts were made in the bone and the blades were tapped in with a mallet. These blade implants were designed more for single tooth replacement or short-span bridgework rather than denture support. Again they were moderately successful and there are many still in function today.

Professor P. I. Brånemark is regarded as the father of modern dental implantology. Whilst undertaking microscopic studies of vital rabbit femurs, he discovered a unique bond between titanium viewing chambers and the bone. He described this bond as *osseointegration*, which he defined as 'a direct structural and functional connection between ordered living bone and the surface of a load-carrying implant'.

Brånemark and co-workers undertook a 15-year study between 1965 and 1980 in which they treated edentulous patients using machined titanium implants with high levels of success. The reported suc-

cess rates of the implants were as high as 81% in the maxilla and 91% in the mandible over this 15-year period.

### Terminology

#### Implant

The implant is the intraosseous portion of the whole device. It can also be termed a *fixture*. Impressions taken of the implant head are called *fixture-level* or *implant-level* impressions.

#### Abutment

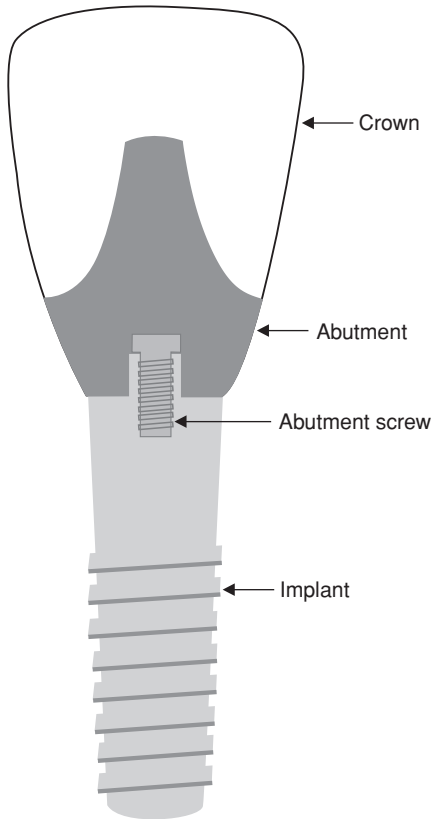
The abutment is the transmucosal portion that connects the implant to the restoration, e.g. a crown, or a bridge. Abutments are available in a choice of materials of which the most common are titanium, zirconium, gold and alumina. The combination of the implant fixture and a separate abutment can be described as a two-piece implant.

#### Osseointegration

The process by which bone is formed against the implant after its surgical insertion. At this stage the implant is often covered by mucosa.

#### Healing abutment

This is placed on the implant head following exposure of the implant after osseointegration or at the time of implant placement. It allows healing of the gingivae around the implant prior to provision of the implant restoration.



**Fig. 22.1** External connection type implant.

### Platform

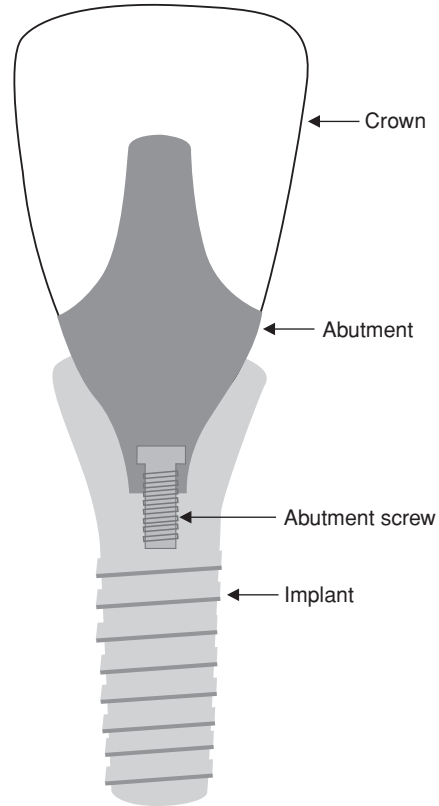
The platform is the head of the implant to which abutments are connected. Implants are available in different diameters (*platform size*) termed narrow, regular and wide platform sizes. The different-sized implants are used at different sites in the mouth. For example, narrow platform implants are used for replacing missing lateral incisors, whilst wide platform implants are used to replace missing molars.

### Platform switching

The use of an abutment that is narrower than the size of the platform. Platform switching can avoid vertical bone loss at the connection between the implant and the abutment.

### Connection

The junction between the abutment and implant fixture. Implants can have external or internal connection with the abutment.



**Fig. 22.2** Internal connection platform switching type implant.

### External connection

The abutment sits on the implant platform. It is connected to the implant by an *abutment screw*. Figure 22.1 shows a typical external connection implant.

### Internal connection

The abutment fits within the structure of the implant and again is generally screwed to the implant with an abutment screw. Figure 22.2 shows a typical internal connection implant with a platform switching type abutment.

### Screw-retained prosthesis

The implant prosthesis is screwed onto the abutment by a *bridge screw* or directly onto the implant head. The main advantage of a screw-retained prosthesis is its retrievability. It is simple to unscrew the implant prostheses to gain access to the implants.

## Cement-retained prosthesis

The crown is retained onto the abutment by means of luting cement as in conventional crown and bridge-work. Cement-retained prostheses are more difficult to remove for access to the implants but they generally offer better aesthetics.

## One-piece implant

In a one-piece implant the implant fixture and abutment are joined. There is no connection between them. The crown fits directly to the implant.

## Implant Materials

The most common materials for dental implants are:

- Commercially pure titanium
- Titanium alloy (Ti<sub>6</sub>Al<sub>4</sub>V)
- Zirconium

Commonly commercially pure titanium is the material of choice for implants as it has a predictable interaction with biological tissue. The metal is highly reactive and oxidises passively almost immediately when in contact with air or tissue fluids. This is of particular benefit when used as an implant since it reduces the risk of corrosion. Any damage to the surface of commercially pure titanium structures is immediately protected by an oxide layer about 12 Å thick.

The other physical attributes which make titanium popular is that it has a low density, just under half that of stainless steel, but high strength. It therefore has a high strength to weight ratio. It has a modulus of elasticity about half that of stainless steel alloys, making it more elastic. However, the modulus is about five times that of bone.

Titanium is regarded as highly biocompatible though there is still some release of titanium ions into tissue where tissue fluid and blood act as an electrolyte. Raised levels of titanium have been identified around implants and systemically in major organs. The amounts observed do not appear to be sufficient to produce an untoward reaction on current evidence.

The biological response to titanium is affected significantly by the surface character of the implant. It is suggested that contamination of the implant surface may have an adverse effect on the survival of the implant. Recent attempts have been made to modify implant surfaces to enhance the performance. These treatments include plasma spraying or coating the

surface with a film of calcium phosphate ceramic. This is designed to encourage bone growth and enhance osseointegration. These 'bioactive' implants offer potential for better bone integration but the success is determined by the durability of the bond between the coating and the substructure.

Titanium and its alloy with aluminium and vanadium is stronger than commercially pure titanium and is easier to machine. However, it is reported to promote a less favourable tissue reaction. More recently zirconium implants have become commercially available. Like titanium, zirconium is biocompatible and its main advantage is its colour. It is white rather than grey, which means that it may offer a more satisfactory aesthetic outcome.

## Implant Placement Techniques

### Standard drilling sequence

Different implant manufacturers recommend different drilling protocols. In general, preparation of the osteotomy site starts with a small round bur or a sharp straight drill of 2 mm diameter with drill speeds varying between 800 and 2000 rpm. The drills are cooled with cold saline irrigation, which can be delivered internally to the drills or from an external source. Overheating the drills will cause excessive damage to the bone. The osteotomy preparation continues with gradually increasing diameter drills and during drilling the planned direction of the implant can be checked by the use of a direction indicator. The final drill is generally 0.5–1.0 mm narrower than the diameter of the implant. The hole in the bone can be threaded by use of a screw tap at 50 rpm following which the implant is screwed in at speeds of between 25 and 50 rpm with a machine driver or by hand. The maximum torque developed during placement should not exceed 45 N/cm<sup>2</sup> otherwise excessive damage may occur to the bone. The drills used to prepare the implant site are usually up to 1.5 mm longer than the actual implant. This needs to be taken into account during the planning of implant surgery as, for example a good margin of error needs to be allowed above the inferior dental nerve.

### Osteotomes/site formers

Some implant systems require the use of osteotomes or site formers to prepare the socket for implant placement. Osteotomes are solid hand instruments with a concave end that come in a range of diameters. The

smallest diameter osteotome is used first and then ones with gradually increasing diameters until the site has been prepared to match the chosen implant. They are slower than twist drills in the creation of the implant site.

Osteotomes can also be used in soft (type IV) bone (see later) to compact the bone around the implant site.

## Principles of Osseointegration

Following the drilling of the bone and placement of the implant a number of events occur within the bone. Both procedures cause damage to the bone up to a few millimetres beyond the extension of the implant which can be limited by the use of cooled irrigation, drilling at slow speeds, the use of sharp drills and the use of a torque controller whilst placing the implant.

A cascade of wound healing events is triggered by this bone damage. On placement of an implant, there is not full contact between the bone and the implant and several gaps will exist around the implant surface. Bone healing has to occur in these gaps but also in the damaged pre-existing bone adjacent to the implant. Not all bone sites have the same wound healing potential and consequently the healing process occurs at different rates at different sites.

### Healing process in the gaps (de novo bone formation)

The sequence is:

- 1 Bleeding occurs after drilling. The gaps between the implant and bone fill with blood
- 2 Wound healing factors are released from the blood (*Angiogenesis*)
- 3 Under the influence of the wound healing factors, osteoprogenitor cells migrate into the blood clot
- 4 Osteocytes differentiate into osteoblasts
- 5 Osteoblasts form woven bone
- 6 Woven bone compacts to form lamellar bone
- 7 Remodelling occurs with the creation of new osteons

### Healing process in pre-existing bone

Despite good surgical technique up to 1 mm of bone adjacent to the implant undergoes necrosis and microcracks are found in the bone up to 3–4 mm beyond this area of microdamage.

Healing in this bone occurs by the following process:

- 1 Activation of osteoclastic cutter cones
- 2 Resorption of the damaged bone by osteoclasts
- 3 Formation of osteoblasts/new bone deposition by osteoblasts

On studying the interface between implants and bone at the light microscope level there appears to be direct bone–implant contact (BIC). The bone does not contact the implant around the whole surface but varies from approximately 30% on initial implantation to 50–70% following successful osseointegration.

## Implant Failure

Implant failures can occur early or late. Early failures are classified as those occurring before the first year of loading (placement of the restoration) and late failures are those occurring after the first year of loading.

### Early failure

This is a failure to achieve osseointegration. The cause is multifactorial and is thought to include:

- Placement technique
- Micromotion of the implant caused by early loading
- Level of experience of the operator
- Use of antibiotics and antimicrobials
- The cause of tooth loss
- The timing of implant placement
- Patient-related factors

### Placement technique

The use of blunt drills and inadequate cooling of the drills can lead to overheating of the bone. The use of osteotomes in dense bone can be associated with increased bone resorption around an implant.

### Micromotion of the implant caused by early loading

Excessive movement of an implant during the healing process can lead to fibrous repair and soft tissue encapsulation of the implant.

### The level of experience of the operator

Statistically, inexperienced implant surgeons will experience more failures than experienced surgeons. This is probably related to treatment-planning factors and case selection.



### Use of antibiotics and antimicrobials

There is some weak evidence that the use of pre-operative antibiotics is associated with a lower failure rate of implants than not using them or using post-operative antibiotics alone.

### The cause of tooth loss

Placement of implants at sites of teeth that have been lost through periodontal disease can be associated with a higher failure rate. Placement of implants in patients with untreated periodontal disease is associated with a higher failure rate and is a contra-indication to treatment.

### The timing of implant placement

There is some weak evidence that immediate placement of implants can be associated with a higher failure rate than implants that are placed later.

### Patient-related factors

Systemic and local factors can affect the early failure rates of implants. These include smoking, poorly controlled diabetes mellitus, radiotherapy and bisphosphonate medication for the treatment of osteoporosis (see Chapter 23).

### Late failure

This is a failure to maintain osseointegration. The bone at the implant interface is dynamic and is constantly remodelled. Fatigue microdamage occurs at the interface triggering this remodelling process. If the microdamage is in excess of the repair process then bone loss will occur.

Causes are:

- Overloading
- Peri-implantitis (see Chapter 23)

Overload may be caused by occlusal forces, insufficient implants for the planned restoration or para-functional habits.

## Implant Stability

### Primary stability

Primary stability of an implant is the stability that is created during the surgical placement of the implant. It is purely a frictional force created between the implant and bone. An implant is more likely to be successful if good primary stability has been achieved. Primary stability can be recorded by

*resonance frequency analysis* (RFA). This will give an *implant stability quotient* (ISQ). The torque (N/cm<sup>2</sup>) that is achieved during implant placement will also give an indication of the primary stability.

Primary stability is influenced by:

- Implant shape
- Implant surface topography
- Bone quality
- Bone quantity

### Secondary stability

Secondary stability occurs following the bone healing process as bone is deposited around the implant during healing and is influenced by:

- Implant material
- Implant shape
- Implant surface topography
- Implant surface chemistry
- Bone quality

## Timing of Implant Surgery

The original concept of implant surgery as described by Brånemark was that a cover screw was placed on implants and the mucosa was sutured over them allowing the implants to heal undisturbed for up to 6 months in the maxilla and 3 months in the mandible. After this period of osseointegration the implants were exposed into the mouth and healing abutments placed. This is called a *two-stage procedure*.

It is now common to undertake a *one-stage procedure*. This involves the placement of a healing abutment at the time of implant placement (first-stage surgery) thus allowing the mucosa to heal at the same time as osseointegration. The advantages are a reduction in healing time, as mucosal and osseous healing can occur concurrently, and only one surgical procedure is required. Following modifications to implant surfaces, there has been a reduction in the healing time of implants. Traditionally, implants were left to heal for 6 months in the maxilla and 3 months in the mandible. It is now more common to leave implants 2–3 months in the maxilla and 6–8 weeks in the mandible.

### Immediate placement

Sometimes it is possible to place an implant directly into an extraction socket. This is termed *immediate*

*placement.* One of the reported advantages of immediate placement is that the healing potential of the implant site is at its greatest immediately after extraction of the tooth. There is a suggestion that the bone and gingival profile of the implant site will be preserved by immediate placement. There is also a reduction in treatment time as only one surgical procedure is required. The disadvantage is that there can be a risk of transmission of infection to the implant at the time of surgery. This risk depends on the cause of loss of the tooth and is greatest in patients with multiple causes of tooth loss, e.g. periodontal disease, fractured roots and caries. Some studies report higher failure rates of implants placed immediately into extraction sockets.

### Delayed placement

Delayed implant placement generally refers to placement 6–8 weeks after extraction of a tooth. The advantages of this include utilising the early wound healing potential of an extraction socket. There should also be resolution of any acute infection present and there will be an increase in soft tissue volume allowing primary closure of the site if a two-stage procedure is required, e.g. following bone grafting/guided bone regeneration or treatment in aesthetic areas.

Disadvantages are that multiple surgical procedures are required, treatment times are longer and there will be some resorption of the buccal bone following removal of the tooth. Delayed placement requires surgical access to the site by raising a flap and this can be associated with up to 1 mm of resorption of bone. In areas where aesthetics are important, this may lead to a poor appearance.

### Late placement

Late placement refers to at least 3-month elapsing after removal of a tooth and the placement of an implant. Advantages include complete resolution of infection prior to placement and it is technically easier to undertake the procedure. The main disadvantage is that resorption of the bone will have occurred. Late placement generally occurs if patients have delayed requesting treatment. The main indication for late placement is if immediate or delayed placement may risk damage to a nearby vital structure, e.g. above the inferior dental canal or if it is felt that primary stability will not be achieved at immediate or delayed placement, e.g. upper molars and premolars in close proximity to the maxillary antrum.

The resorption of bone associated with late placement can be overcome by *site preservation*. Socket volume preservation is undertaken by guided bone regeneration at the time of tooth extraction. Following bone healing the implant placement can be undertaken without the need to raise a flap thereby avoiding unnecessary bone resorption.

### Immediate loading/Immediate function

Placement of a temporary restoration on an implant within 24 hours of implant placement is termed immediate loading and can be considered only if implants achieve a high primary stability at the time of placement.

The advantage of immediate loading is the immediate provision of fixed temporary restorations. However, some studies report higher failure rates of implants that are immediately loaded when compared to delayed loading.

### Anatomical Considerations

Before undertaking dental implant surgery it is essential to have a good understanding of the three-dimensional surgical anatomy of the maxilla and mandible because there are a number of vital structures that can complicate treatment. To gain detailed knowledge of the surgical anatomy of the maxilla and mandible readers should consult an anatomy textbook.

### Vital structures of relevance to dental implant surgery

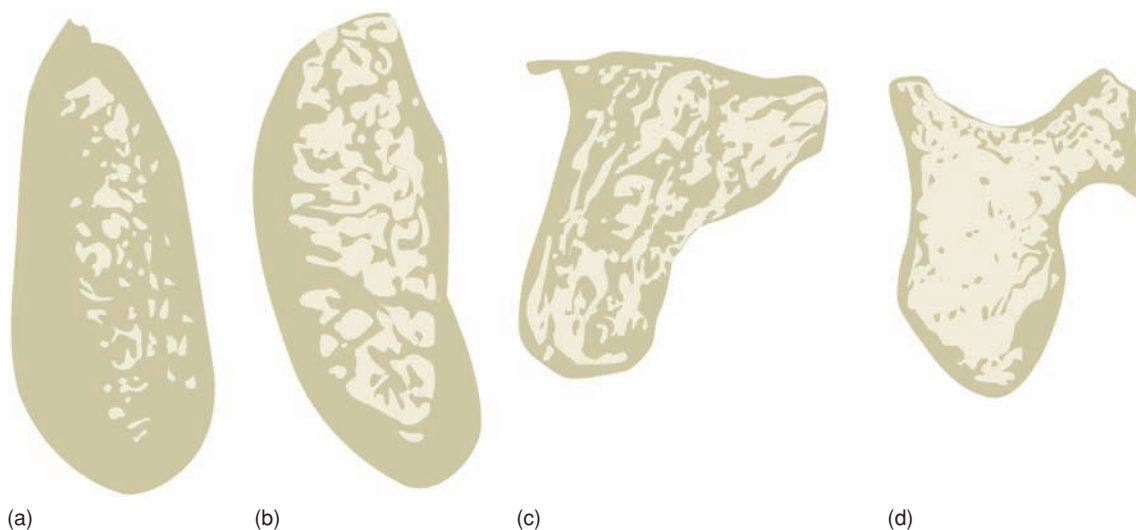#### Maxilla

Nasopalatine nerve/incisive canal  
Floor of nose  
Maxillary antrum

#### Mandible

Inferior dental nerve  
Mental nerve  
Lingual concavity/floor of mouth

When planning implant surgery 2–3 mm of clearance needs to be allowed above the inferior dental nerve. A clearance of 5 mm is usually allowed in front of the mental nerve to allow for the anterior loop of this nerve.



**Fig. 22.3** Classification of bone quality. (a) Type I – Predominantly cortical type bone. (b) Type II – Dense cancellous/thick cortical plate. (c) Type III – Dense cancellous/thin cortical plate. (d) Type IV – Porous cancellous/thin cortical plate.

### Bone quality

The success rates of implants can be site-dependent and failures in the maxilla have been reported as being three times higher than the failure rate in the mandible. Implants in posterior regions of the jaw also have a higher failure rate than implants in anterior regions.

This is related to the density and quality of the bone. Lekholm and Zarb introduced a bone quality index in 1985 (Fig. 22.3).

- Type I – Predominantly cortical type bone
- Type II – Dense cancellous/thick cortical plate
- Type III – Dense cancellous/thin cortical plate
- Type IV – Porous cancellous/thin cortical plate

Type IV bone is most commonly found in the posterior maxilla. The failure rate of machined implants in type IV bone has been reported as high as 35%.

Success rates in poor-quality bone have been improved by the use of rough surface implants, tapered implants, osteotomes and the under-preparation of osteotomy sites to improve the frictional fit of implants.

### Bone quantity

Following the extraction of teeth there is residual ridge remodelling. This resorption occurs most rapidly within the first 6 months after tooth

extraction but can continue for life and generally occurs horizontally from the buccal aspect.

Resorption at potential implant sites can have two implications for implant surgery. First, the bone ridge can be too thin to accommodate an implant and second the aesthetic outcome of the implant restoration can be compromised.

Several bone quantity indices are available.

- 1 The Lekholm and Zarb classification which is more relevant to edentulous jaws:
  - A – Unresorbed alveolar bone
  - B – Some resorption of alveolar bone
  - C – Complete resorption of alveolar bone
  - D – Some resorption of basal bone
  - E – Extreme resorption of basal bone
- 2 The Seibert classification is generally more useful for partially dentate patients:
  - Class I – Horizontal resorption
  - Class II – Vertical resorption
  - Class III – Combined horizontal and vertical resorption

Bone grafting can be undertaken to increase bone volume to allow implant placement but also to improve the aesthetic outcome of the final implant restoration. Bone grafting is much more predictable for horizontal (class I) resorption cases than vertical and combined cases (class II and class III).

## Pattern of residual ridge remodelling

In edentulous patients the pattern of resorption in the maxilla is in a horizontal and vertical direction with bone being lost from the buccal aspect of the alveolar ridge. In the mandible the residual ridge remodelling is generally in a vertical direction only, with mandibular basal bone being more resistant to resorption than maxillary bone. As a result there is a tendency towards a class III skeletal relationship in edentulous patients. This can have an impact in providing fixed restorations in patients with severe resorption.

## Radiographic assessment of bone volume/relationship of vital structures

To assess the bone volume and the proximity of vital structures, good clinical examination and plain panoramic and intraoral radiographs are sufficient for the vast majority of patients. If the inferior dental nerve is not clearly identifiable on pan-oral radiographs (OPT) or if any doubt exists then it is advisable to obtain cross-sectional imaging such as cross-sectional tomograms, cone beam CT or MRI scans.

## Bone – Implant Interface

When an implant is placed in bone a number of events occur at the implant surface. Titanium readily forms an oxide layer when exposed to air and on implantation the oxide layer is 2–6 nm thick. This increases two to three times during healing. Proteins are adsorbed onto the surface of the implant that mediate bone healing and there is also a change of the chemical composition of the oxide layer with incorporation of calcium phosphate and calcium sulphate salts.

Any disruption of the bone–implant interface during healing will lead to fibrous repair and soft tissue encapsulation. This will lead to failure of the implant.

## Nature of bone–implant interface

There is no direct contact between bone and the surface of the implant seen when studied using electron microscopy. There is an afibrillar interfacial zone.

- 1 The initial layer is similar to cement lines found around teeth. Its dimensions are 15–20 Å. It contains non-collagenous bone matrix proteins
  - a Osteopontin (OPN)
  - b Bone sialoprotein (BSP)

Both OPN and BSP have arg-gly-asp (RGD) as their terminal amino acid sequence. This is thought to play a role in cell adhesion and the binding of mineral.

- 2 A lamina limitans layer is found adjacent to the afibrillar interfacial zone. Osteoblasts, osteoid and mineralised matrix is observed at the lamina limitans. Bone is therefore deposited adjacent to this layer

## Modifications to implant surfaces to improve bone–implant contact

The initial Brånemark implant system was of machined titanium with a smooth surface. Over time many modifications have been made to improve the bone healing potential of implant systems and most of these modifications have been made to the initial 0.1–1.0 nm of the implant surface, which is termed the *primary interaction zone*.

Modifications include:

- *Physicochemical methods*
  - Increasing the surface energy
  - Creating a surface charge
  - Changing the surface composition, e.g. by the use of hydroxyapatite coating
- *Morphological methods*
  - Changing the implant shape, e.g. tapered implants
  - Increasing the surface roughness, e.g. sand blasting, acid etching and titanium blasting (TiOblast)
  - Changing the surface topography, e.g. double-thread design

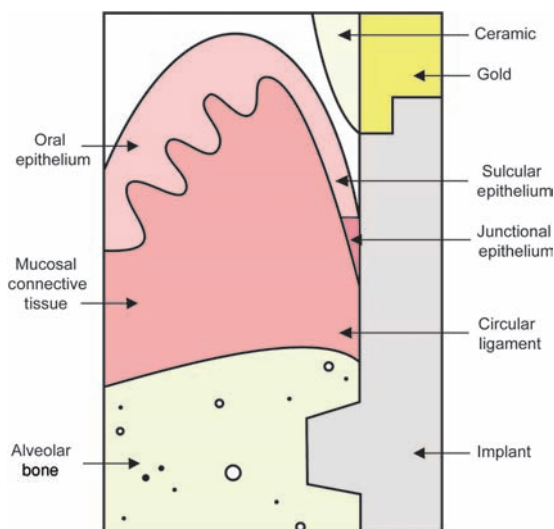
Research has also been aimed at biomechanical methods to improve implant healing. This has included the use of growth factors such as bone morphogenetic protein (BMP).

## Implant–Mucosal Interface

The implant–mucosal interface (IMI) consists of two principal layers, epithelium and underlying connective tissue and has many similarities to the tooth–mucosal interface (Fig. 22.4).

## Epithelial layer

Three levels of epithelium have been identified.



**Fig. 22.4** Schematic diagram of the implant–mucosal interface.

- *Oral epithelium* – This is keratinised epithelium that terminates at the crest of the gingival margin
- *Sulcular epithelium* – This is a 5- to 15-cell-thick layer of non-keratinised epithelium
- *Junctional epithelium* (aJE) – This is a 2- to 5-cell-thick layer of non-keratinised epithelium characterised by the presence of desmosomes between cells and hemidesmosomes between junctional epithelium cells and the surface of the implant/abutment.

### Connective tissue layer

The main difference between IMI and the tooth–mucosal interface is the lack of periodontal cementum around implants. As a result there is no direct attachment between connective tissue fibres and periodontal cement. Connective tissue fibres are found to run parallel to the implant surface. This is termed the *circular ligament*.

Connective tissue fibres consist of predominantly type I collagen with some type III and type IV collagen. The connective tissue layer is between 0.75 and 2 mm thick.

The vascular topography of the IMI also differs from the tooth–mucosal interface as the blood vessels are exclusively derived from periosteum as there is no periodontal vasculature.

### Differences between the tooth–mucosal interface and the implant–mucosal interface

- Lack of periodontal cementum around implants
- No direct attachment between connective tissue fibres and periodontal cementum around implants
- Direction of connective tissue fibres. The connective tissue directly around implants runs parallel to the surface of the implant/abutment, the circular ligament
- Vascular topography. The vasculature of the tooth–mucosal interface is derived from both periodontium and periosteum. The vasculature of the implant–mucosal interface is solely derived from the periosteum.

## Chapter 23

# Fixed Prosthodontics: Clinical Aspects of Implants

Implants can be used to support an individual crown, as abutments for bridgework (both partial- and full-arch bridgework cases) or to help retain dentures (either partial or complete dentures).

The techniques are complex and this chapter provides a simple description of these together with some clinical examples.

### Indications for the Use of Implants

The indications for replacing lost teeth and the general treatment options were discussed in Chapter 18. There is no single treatment option that is right to the exclusion of the others, simply an appropriate treatment in the particular circumstances of an individual patient.

Implants offer some advantages over other treatment and these include:

- The ability to reproduce spacing between the teeth
- No abutment tooth preparation is required
- The condition of the adjacent teeth is not critical to the success of the implant
- Bone and soft tissue volume is preserved

There are, however, some disadvantages of implant treatment which include:

- Surgical procedures are required
- Implant treatment may take several months
- Complications of treatment (both surgical and restorative)
- Cost

Most implant treatment, including hard and soft tissue augmentation procedures, is possible using local analgesic. Oral or intravenous sedation can be provided for nervous patients or for prolonged procedures.

### Contra-Indications to Implant Treatment

Dental implant surgery is essentially a routine minor oral surgery procedure and the same contra-

indications and pre-operative precautions apply to it as to any other type of elective minor oral surgery.

In addition to this there are some contra-indications and precautions that are specific to dental implant surgery.

### Medical contra-indications to elective minor oral surgery

- Unstable angina pectoris
- Recent myocardial infarction (elective surgery should be avoided for 6 months)
- Decompensated congestive heart failure
- Hypertension
  - Systolic blood pressure greater than 180 mm Hg
  - Diastolic blood pressure greater than 110 mm Hg
- Severe aortic stenosis

### Medical precautions

- Antibiotic prophylaxis protocols for infective endocarditis apply as for routine minor oral surgery
- Anti-coagulant therapy. It is generally not necessary to discontinue anti-coagulant therapy before surgery. Local haemostatic measures including tranexamic acid mouthwash, gelatin sponge, resorbable cellulose mesh and sutures are usually sufficient to control post-surgical bleeding
- Steroid cover. The same indications and steroid cover regimes apply as for routine oral surgery

- Insulin-dependent diabetes mellitus. The same precautions for minor oral surgery apply to implant surgery

If any doubt exists, the patient's general medical practitioner should be consulted prior to treatment.

### Contra-indications to implant treatment

Contra-indications to implant treatment can either be for local or systemic reasons. Relative contra-indications to treatment are conditions that are associated with higher failure rates of implants but do not necessarily preclude such treatment as long as the risks are understood by the patient.

### Systemic contra-indications

- Unfinished cranial growth with tooth eruption. Implant surgery prior to completion of growth can lead to infraocclusion of implant restorations and an unaesthetic appearance
- Alcohol and/or drug abuse
- Active chemotherapy
- Unrealistic patient expectations

### Systemic relative contra-indications

- Diabetes mellitus
- Smoking. Smoking probably does not affect the initial rate of integration of implants. It is however associated with increased coronal bone loss around implants and an increased risk of peri-implantitis particularly in the maxilla
- Syndromal hypodontia
- Age. Some studies show an increased failure rate in the over 60s age group, whilst other studies report no difference
- Osteoporosis (particularly with bisphosphonate treatment)

### Local contra-indications

- Head and neck radiotherapy. Failure rates of up to 30% have been reported in patients who have had radiotherapy. The failure rate is thought to be dose related, with the greatest failure found in patients receiving radiation dosage of greater than 50 Gy
- Acute infectious disease
- Pathological conditions in the maxilla or mandible
- Poor oral hygiene

- Untreated periodontal disease
- Insufficient restorative or surgical space for the implant

### Local relative contra-indications

- Poor bone quality
- Poor bone volume or severe bone resorption
- Para-functional habits

Whilst it is possible to find case reports of implants being successfully used in patients with most chronic illnesses, common sense should be exercised when deciding which patients are suitable for implant treatment.

## Implants and Aesthetics

It is clear from long-term clinical studies that there can be confidence in the success and durability of osseointegration. Attention has now moved from simply achieving an implant that stays in bone retaining a restoration successfully to improving the aesthetics of these restorations. Aesthetics is determined not only by the position and angulation of the implant in relation to the desired restoration position but also by the surrounding soft tissue and its supporting bone.

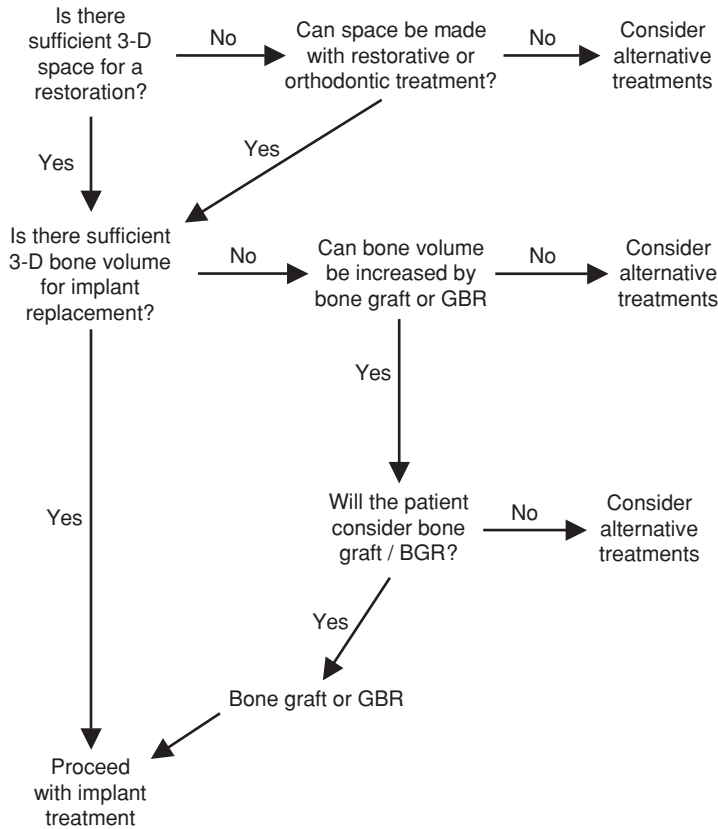
It is no longer acceptable to place implants in any available bone with total disregard for the appearance that will be created by their position. The principles discussed in Chapter 21 in relation to anterior tooth-supported bridgework apply equally to implant supported restorations. Similar techniques may be employed to decide on tooth position such as diagnostic waxing and provisional dentures. The two flow charts, Figs. 23.1 and 23.2, summarise the guidelines discussed below.

### Assessment of the anterior edentulous site

The following factors are important:

- Lip line
- Space available for the restoration
- Functional relationships
- Adjacent teeth
- Soft tissue phenotype
- Gingival line
- Muco-gingival line
- Interdental papillae

### Implants in non-aesthetic areas



**Fig. 23.1** Flow chart showing considerations for implants in non-aesthetic areas.

- Emergence profile of the implant
- Bone contour

#### Lip line

The lip line is generally classified as low, medium or high. In patients with a low lip line only the incisal third of the crown is visible during normal function. In patients with a high lip line the margin between teeth and gingiva is visible during normal function. The lip line influences how demanding the aesthetics will be. Patients with a low lip line are more likely to accept an aesthetic compromise than patients with high lip line, simply because they will show less of the restoration.

#### Space available for the restoration

The implant restoration needs to be in harmony with the adjacent teeth and will be compromised if there is

not enough space available for it. Consideration may need to be given to changing the dimensions of the edentulous space by either orthodontic or restorative treatment.

#### Functional relationships

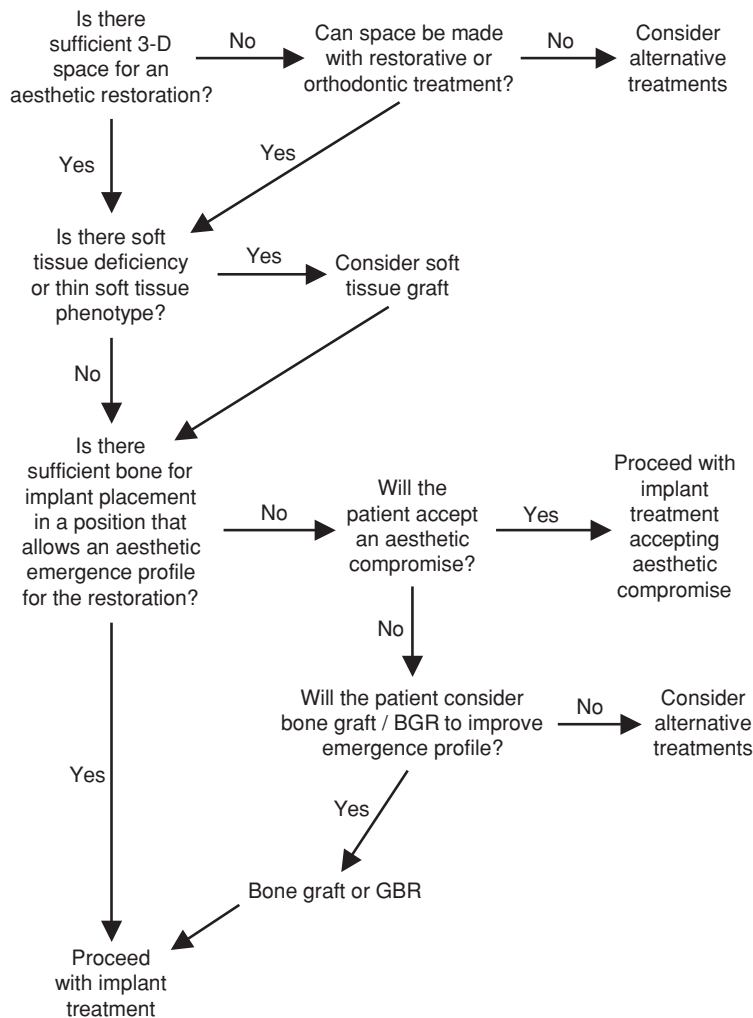
The occlusal relationships need to be defined including occlusal contacts in centric occlusion, the inter-arch relationship, the occlusal vertical dimension and the role that the planned restoration will have in mandibular guidance.

#### Adjacent teeth

The state of the neighbouring teeth is important so that the implant is considered in the context of the local conditions. It is clearly not good to place an implant alongside teeth of poor prognosis or where they may restrict the achievement of good aesthetics.



### Implants in aesthetic areas



**Fig. 23.2** Flow chart showing considerations for implants in aesthetic areas.

There can also be bacterial contamination of implants from adjacent periapical or periodontal pathology. The following aspects of the adjacent teeth need to be assessed:

- Position and angulation
- Structural integrity and condition
- Periodontal and endodontic status
- Crown-to-root ratio
- Root inclination in relation to the vertical plane
- Presence of spacing

### Soft tissue phenotype

The soft tissue phenotype is classified as either thick (approximately 85% of the population) or thin (approximately 15% of the population). A thin soft tissue phenotype is more prone to post surgical recession. A titanium abutment may also show through the thin soft tissues.

### Gingival line

The course of the gingival line of the implant restoration should be in harmony with the adjacent teeth or restorations.

### Muco-gingival line

The level of the keratinised mucosa at the implant site should be in harmony with the adjacent teeth.

### Interdental papillae

The interdental papillae of the restoration need to be in harmony with the adjacent teeth. The papilla levels have been classified by Palacci as follows:

- Class I – intact or slightly reduced papilla
- Class II – limited loss of papilla
- Class III – severe loss of papilla
- Class IV – absence of papilla

Alternative treatments may be necessary with type III or IV papillae or accept an aesthetic compromise.

The level of the soft tissues is dependent on the underlying bone level. If the contact point between restorations is vertically 5 mm or less from the level of the interdental bone then there is a 97% chance of retaining a full dental papilla. If the position of the contact point is 6 mm from the crest of the interdental bone then the chance of retaining a full papilla falls to 56% and at 7 mm the chance of a full papilla is 27%. Raising a full thickness flap can be associated with up to 1 mm of gingival recession. This can obviously have an impact on the aesthetic outcome. Careful consideration needs to be given to flap design. Papilla relieving incisions involve raising a flap but a 1- to 2-mm cuff at the papilla should be left intact and such incisions are recommended in aesthetic regions.

With single tooth implants, as long as the bone levels are good around the adjacent teeth then there is a very good chance of retaining a full interdental papilla.

However, adjacent implants may create a problem. In healed alveolar ridges, there is a pre-existing vertical deficiency of hard and soft tissue. The average mucosal thickness around implants is 3–3.5 mm. This represents a soft tissue deficiency of approximately 2 mm. There is a high risk of interdental papilla loss between adjacent implants.

The restoration of multiple missing teeth in anterior areas using bridgework rather than individual crowns often results in better aesthetics. Placing several implants adjacent to each other often leads to a poor aesthetic result (Fig. 23.3).

### Emergence profile

This term refers to the angle and position of the implant restoration in relation to the contours of

the alveolar ridge. The emergence profile of the implant should be the same as the emergence profile of the adjacent teeth. The development of a harmonious emergence profile is dependent on correct three-dimensional positioning of the implant. Bone resorption may lead to an implant being placed more palatally and at a more acute angle than the root it is replacing. The consequence will be that a large angle will be created between the crown and the implant with poor aesthetics.

It is often necessary to consider bone grafting or guided bone regeneration (GBR) to improve the bone contour allowing a better emergence profile.

### Bone contour

The bone contour apical to the implant restoration should be in harmony with the adjacent bone contour. It is often necessary to consider bone grafting, GBR or connective tissue grafts to improve the bone contour. It is often better to preserve bone and soft tissue volume at the time of tooth extraction (socket preservation) rather than having to deal with post-extraction resorption.

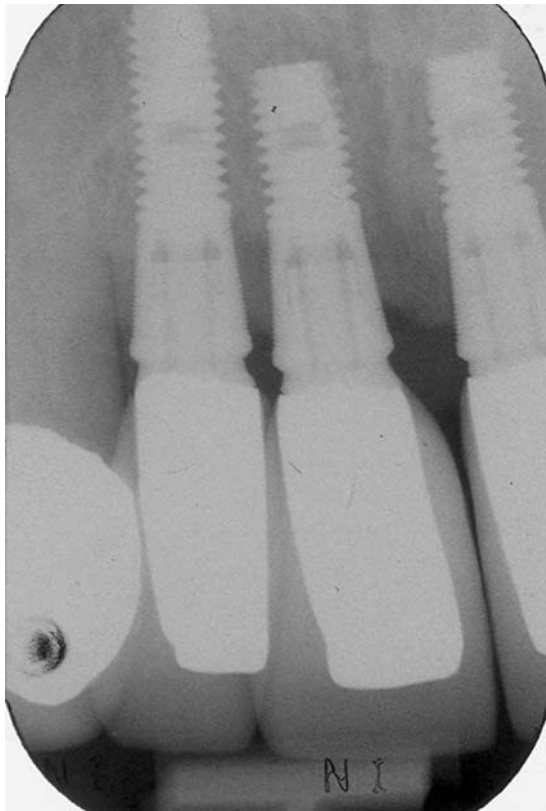
### Implant position

The three-dimensional position of the implant can influence dramatically the aesthetic outcome of the implant restoration. The ideal position is to have the buccal aspect of the implant head 2–3 mm palatal or lingual to the emergence point of the crown at the gingival margin and 2–3 mm apical to the vertical emergence point of the implant restoration.

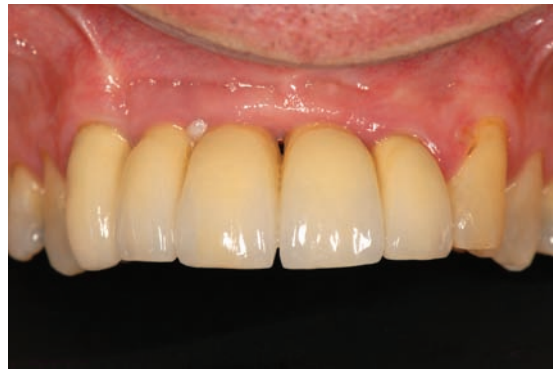The ideal implant position depends on a number of factors which include the use of internal or external connection implants, one piece implants, the size discrepancy between the implant diameter and the size of the implant crown, the buccolingual position of the implant and the soft tissue phenotype.

### Antero-posterior position

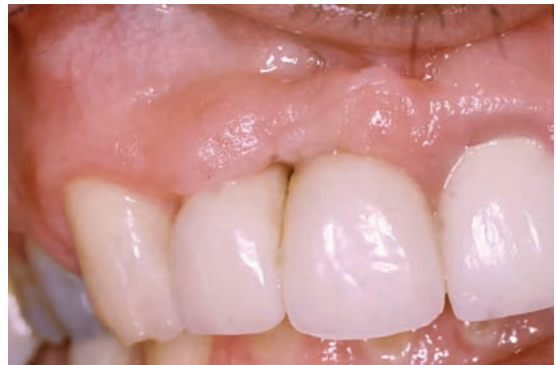Implants that are more buccally placed than the ideal will create the risk of the abutment of being seen through the soft tissue or loss of buccal bone causing soft tissue recession and exposure of the implant or abutment (Fig. 23.4). Buccal inclination of an implant can also lead to a loss of the buccal tissues leading to a long clinical crown or exposure of the abutment (Fig. 23.5).



(a)

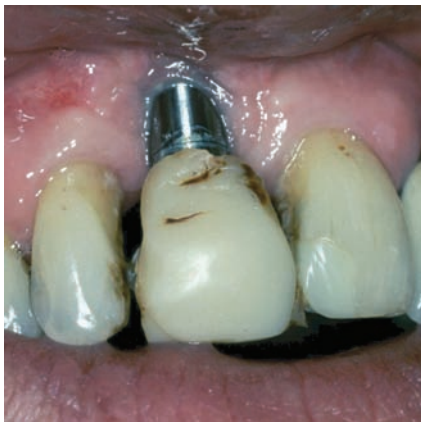

(b)

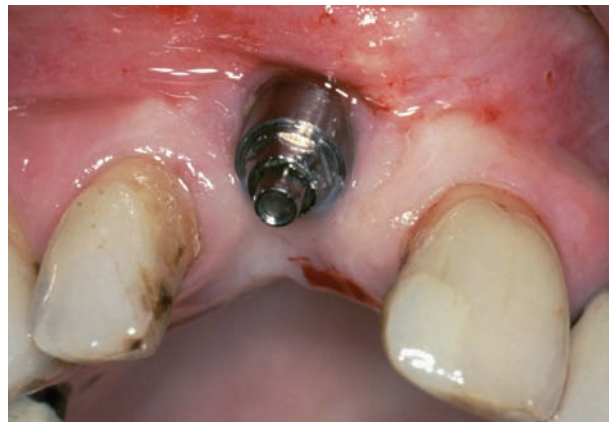


(c)

**Fig. 23.3** (a) Implants supporting  $\overline{21|2}$  that are too close together; (b) the result is loss of interdental papilla and poor aesthetics; (c) another case with poor gingival contour.

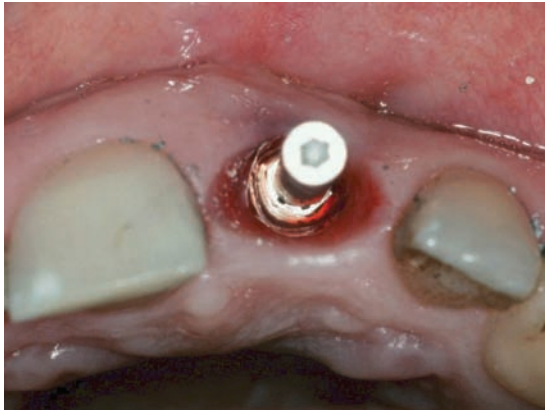


(a)

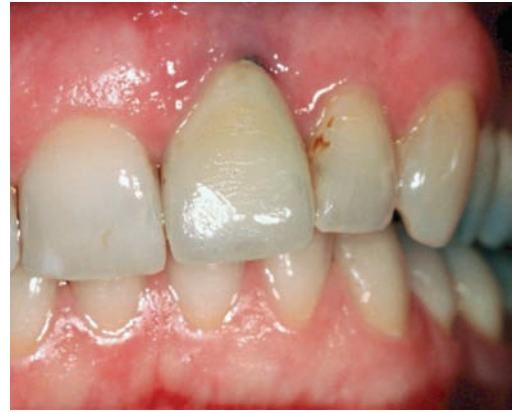

(b)

**Fig. 23.4** Implant placed too far buccally resulting in loss of buccal plate and exposure of the abutment.



(a)



(b)

**Fig. 23.5** Implant with buccal angulation resulting in loss of buccal plate and soft tissue recession.

### Mesio-distal position

Implants should be placed at least 1.5–2 mm from adjacent teeth and there should be at least 3 mm between adjacent implants. Following exposure of the implant into the oral environment, there is establishment of the epithelial and connective tissue interface with the implant. This soft tissue interface is called the *biological width* and is approximately 1.5 mm. If an implant is within 1.5–2 mm of an adjacent tooth, there can be a vertical loss of bone, as the biological width establishes, leading to loss of the papilla between the implant and tooth.

### Vertical position

Implants that are placed too superficially do not allow sufficient vertical space to allow the development of an aesthetic emergence profile. Implants that are placed too deeply allow the establishment of a peri-implant pocket, which is a risk factor for peri-implantitis.

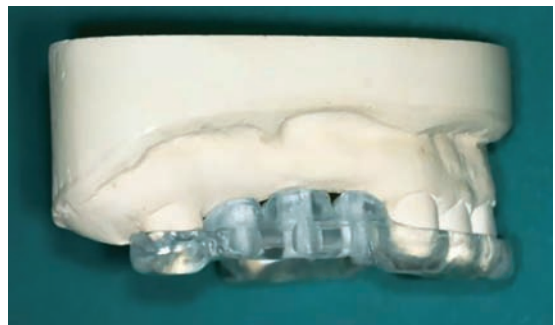### Surgical stent

In order to transfer the diagnostic information during surgery, the diagnostic waxing or provisional denture tooth position can be replicated as an acrylic *surgical stent*. The use of this during drilling the implant sites will allow correct spacing of implants and can be used to assess the vertical position of implants in relation to the implant restoration (Fig. 23.6).

### Linking Implants to Natural Teeth

Natural teeth and implants behave differently when loaded by the occlusion and differential movement is possible in both vertical and horizontal planes. On application of a force of 0.1 N, teeth will show displacement of between 50 and 200  $\mu\text{m}$ . This is as a result of compression of the periodontal ligament. Implants will displace by less than 10  $\mu\text{m}$  when subjected to the same 0.1 N force. This can have a number of implications on implant treatment.

When patients occlude their teeth firmly there will be some intrusion of the natural teeth. This is important in determining the occlusal scheme of implant restorations. An implant restoration should be slightly out of occlusal contact in centric occlusion but should be in occlusal contact on tight clenching



**Fig. 23.6** Surgical stent to align drills in correct unit spacing and angulation of final restoration.

(following slight intrusion of the adjacent teeth). Implant restorations should be able to just hold shim-stock on tight clenching. Over time there may be gradual intrusion of natural teeth adjacent to implant restorations. Implants that have the correct occlusal scheme on insertion of the restoration may develop interferences as a result of movement of the adjacent teeth. As a result the occlusion needs to be checked intermittently on any patient with a combination of natural teeth and implant restorations.

There is a further risk caused by the differential movement of teeth and implants linked by bridge-work. Unless the implants are absolutely rigid and act as a splint keeping the teeth immobile, the teeth will be depressed into their sockets by loading thus flexing the bridge structure. On recovery, stress will be induced in the cement lute risking de-cementation and possibly caries of the abutment teeth.

In general, linking teeth to implants should be avoided if possible though it can be acceptable in some circumstances. In these cases, rigid connectors are recommended.

Circumstances where linking teeth to implants may be acceptable are as follows:

- Close proximity of vital structures. Implant placement may damage vital structures
- Gross bone resorption. Implant treatment would require bone grafting prior to placement. In these cases if the patient is unwilling to have grafting undertaken then linking implants to teeth may avoid grafting
- Highly aesthetic regions. In patients with missing upper central and lateral incisor teeth placement of two implants can lead to an aesthetic compromise. The options in these cases can be either to place on implant at the upper central incisor position and place a fixed–fixed bridge using the canine as an abutment or accept a cantilever bridge from the one implant.

## Tissue Augmentation Procedures

Augmentation procedures are frequently necessary as part of implant treatment. This can include hard tissue augmentation (bone graft or GBR) or soft tissue augmentation.

### Bone augmentation

The indications for bone augmentation are either to correct bone volume deficiency or for an improve-

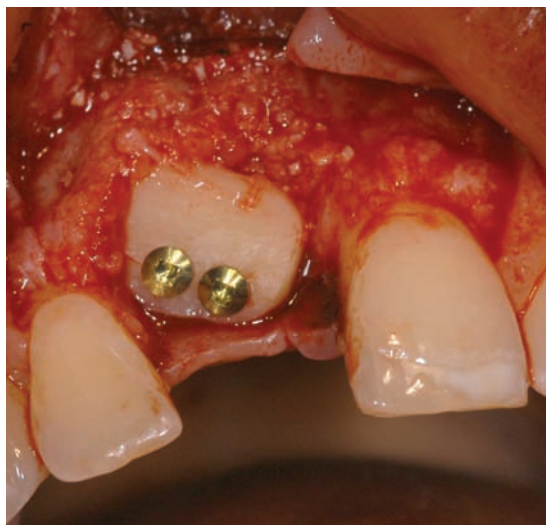

Fig. 23.7 Ramus bone graft at 1| position.

ment of the aesthetic outcome of the implant restoration (Fig. 23.7). Bone grafting is most predictable in a horizontal direction (class I horizontal ridge defects).

Donor sites for bone grafting can be either intraoral or extraoral. The most common extraoral donor site is the anterior iliac crest. Intraoral bone donor sites include the mandibular symphysis, mandibular ramus and maxillary tuberosity.

Intraoral donor sites offer many advantages over extraoral:

- Treatment is possible using local analgesic with sedation if necessary
- Intraoral bone is intramembranous bone whilst extraoral is endochondral. Intramembranous bone gains quicker re-vascularisation and is more resistant to resorption
- There is less donor site morbidity

Intraoral bone grafts can be supplemented by the addition of bone graft substitutes. These can have the benefit of lessening the degree of post-operative resorption. The only limitation of intraoral bone is the volume of graft that can be harvested. For large volume deficiencies extraoral bone grafting is required.

Common augmentation procedures include cortico-cancellous block grafts to broaden the ridge width and maxillary sinus augmentation.

## Guided bone regeneration

GBR involves the use of a cell-occlusive barrier membrane. The membrane prevents epithelial down-growth into a bone defect or socket. Following a tooth extraction or creation of an osseous defect, a membrane is placed over it. This allows the coagulum to heal and reorganise as bone tissue without the in-growth of epithelium. GBR is usually coupled with the use of a filler material.

Common filler materials in GBR

- Autogenous bone
- Allogenic bone
- Xenogenic materials
  - Bovine bone
  - Corals
  - Algae
- Synthetic materials
  - Tri-calcium phosphate
  - Calcium sulphate
  - Hydroxyapatite
  - Bio-active glass

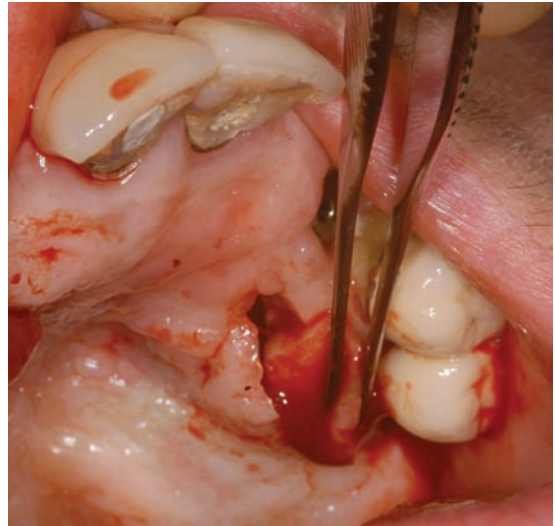
## Soft tissue augmentation

Soft tissue grafts can be harvested from the palate. They can be of split thickness (connective tissue graft), full thickness (free gingival grafts) or a combination of the two. Indications for soft tissue grafting include patients with thin mucosal phenotype, soft tissue deficiency or a deficiency of keratinised mucosa at an implant site (Fig. 23.8).

## Complications of Implants

### Complications of implant surgery

- Bleeding. This can be intraosseous bleeding or perforation of the lingual plate leading to bleeding from floor of mouth
- Nerve damage. The nerves that can be damaged are the inferior dental nerve, incisive nerve, mental nerve and nasopalatine nerve
- Damage to the roots of adjacent teeth
- Infection of the implant
- Haematoma formation. This can occur under the chin following mandibular implant placement
- Wound dehiscence
- Perforation of the mucosa
- Mobility of the implant (poor primary stability)



**Fig. 23.8** Harvest of split thickness connective tissue graft from palate.

## Peri-implantitis

Peri-implantitis is a destructive inflammatory process affecting the hard and soft tissues around an osseointegrated implant in function, resulting in loss of supporting bone leading to the formation of a peri-implant pocket. It generally causes a saucer-shaped loss of bone superficially with the apical portion of the implant often remaining osseointegrated so that no mobility is discernible (Fig. 23.9).

### Clinical signs of peri-implantitis

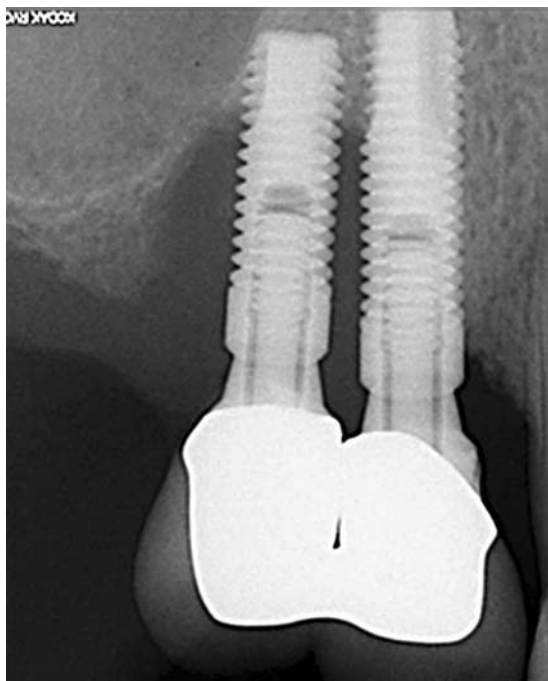
- Bleeding on gentle probing
- Suppuration from peri-implant pocket
- Swelling and erythema of overlying soft tissues (not always present)
- Mobility of implant

Pain is not typically a feature of peri-implantitis.

### Microbiology of failing implants

The bacteria associated with peri-implant disease are generally the same bacteria that are associated with chronic adult periodontal disease and these are:

- *Actinobacillus actinomycetemcomitans*
- *Prevotella intermedia*
- *Porphyromonas gingivalis*
- *Fusobacterium species*
- *Non-pigmented bacteroides species*



**Fig. 23.9** Implants at 54| showing 'saucerisation' bone loss associated with peri-implantitis.

### Risk factors for peri-implantitis

- Periodontal disease
- Implant depth
- Surface roughness of the transmucosal portion of implant
- Poor oral hygiene and plaque retention
- Foreign-body reaction in the peri-implant pocket
- Smoking

Bacteria commonly move from periodontal pockets to implant sites so untreated periodontal disease is a contra-indication to implant placement. Conversely, implants placed immediately into extraction sockets of teeth lost through periodontal disease carry an increased risk of peri-implantitis as do implants placed deeper than 4–5 mm subgingivally.

Bacterial colonisation of abutments begins at surface irregularities and therefore rough surfaces are more prone to biofilm formation and adhesion of bacteria. To avoid damaging the surface of the implant abutment, carbon fibre or plastic hand scalers are recommended for scaling implants.

Subgingival misfit of implant components offers an ideal environment for the formation and retention of

plaque and similarly poor oral hygiene is a high risk factor for marginal bone loss and peri-implantitis.

Extrusion of cement into a peri-implant pocket is commonly associated with an acute peri-implantitis that usually resolves after removal of the cement remnants.

Smoking is also associated with marginal bone loss and peri-implantitis.

### Treatment of peri-implantitis

Management of peri-implantitis includes the following measures:

- Oral hygiene instruction
- Subgingival curettage of the implant
- Topical antimicrobial agents
- Systemic antibiotics
- Surgical treatment for mechanical debridement of the implant surface and elimination of residual pocketing.
- GBR around the implant surface, although the long-term results of this are uncertain

### Restorative complications

- Implant fracture
- Fracture of components/prosthesis
- Speech complications due to tooth position and gaps between the teeth
- Lip trapping above fixed maxillary prostheses
- Prosthetic complications caused by poor implant positioning
- Late implant failure

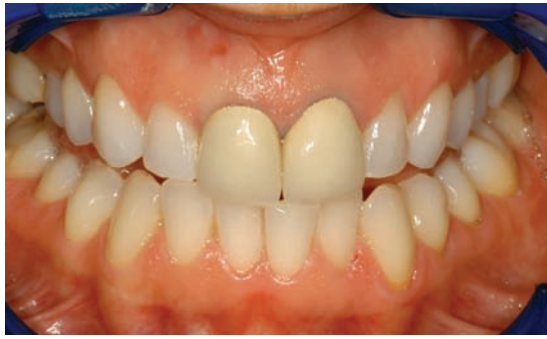### Clinical Review

The following aspects need to be reviewed annually:

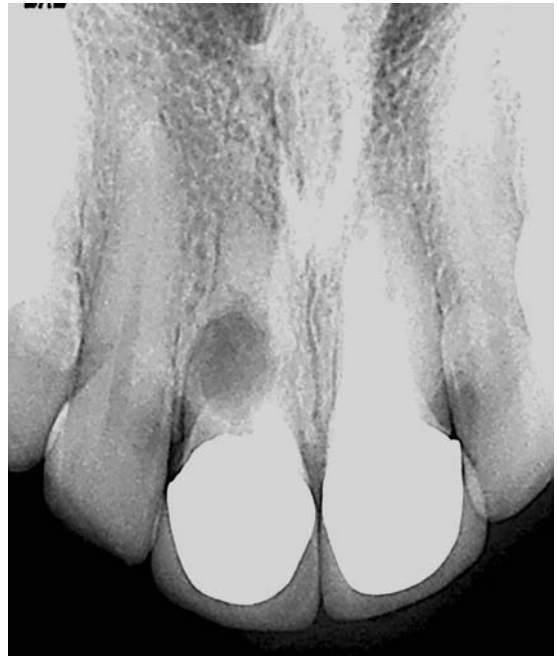- Implant stability
- Osseointegration and bone contour and volume by radiography
- Surrounding tissues – gingivae and mucosa

Particular attention should be paid to the following that will cause concern:

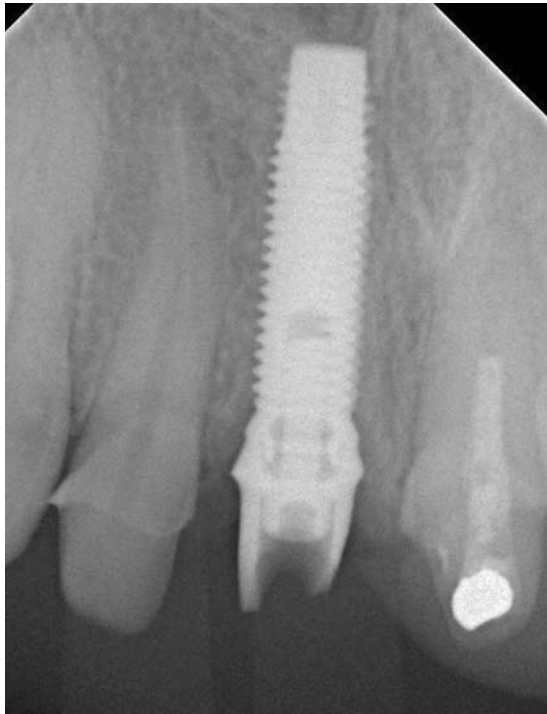- Clinical signs of infection around the implant, e.g. presence of pus
- Pain or sensitivity
- Mobility of the implant
- Radiographic evidence of bone loss (saucerisation)
- A dull sound at percussion



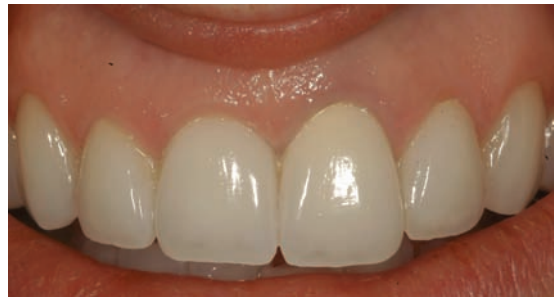(a)



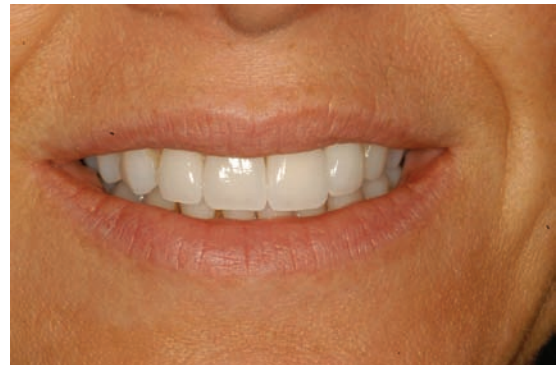(b)



(c)



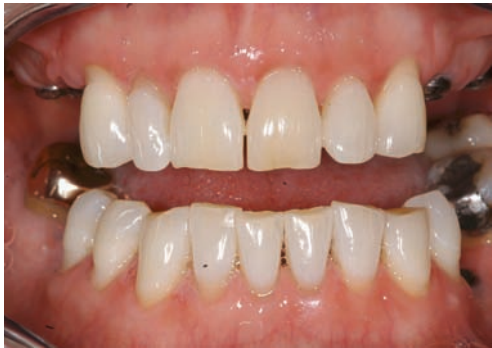(d)



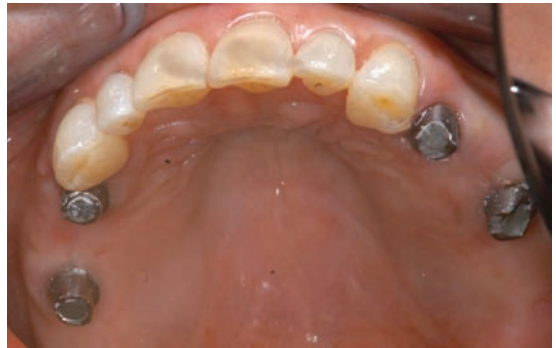(e)

**Fig. 23.10** (a) Patient with metal–ceramic crowns  $\underline{1|1}$  with poor shade match; (b) pre-operative radiograph showing internal resorption  $\underline{1|}$ ; (c) post-operative radiograph showing implant at  $\underline{1|}$ ; (d) post-operative appearance showing milled ceramic crowns  $\underline{1|1}$  and ceramic veneers  $\underline{2|2}$ ; (e) harmonious smile.

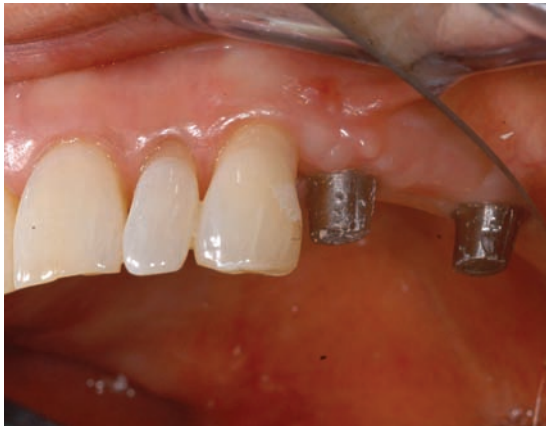



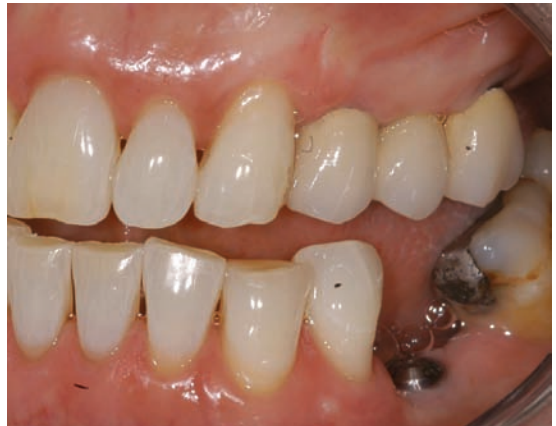(a)



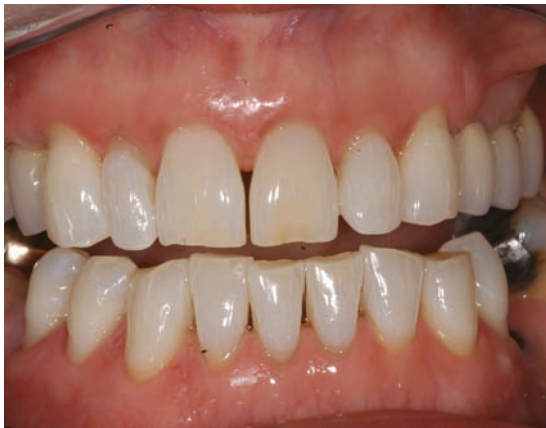(b)



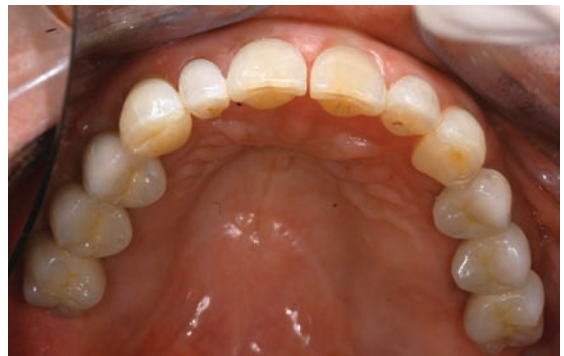(c)



(d)

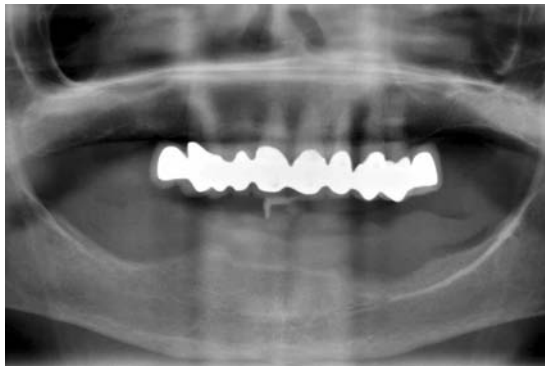

(e)

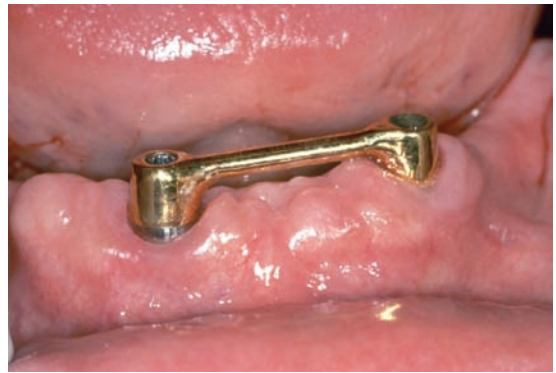

(f)

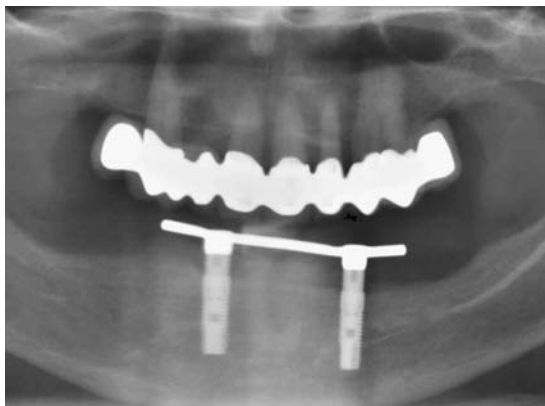
**Fig. 23.11** (a) A patient with bilateral maxillary free-end saddles; (b) occlusal view showing titanium abutments at 46|46 ; (c) titanium abutments at |46 ; (d) implant metal–ceramic bridgework |4 – 6; (e) completed bridgework with harmonious smile; (f) occlusal view of completed bridgework.



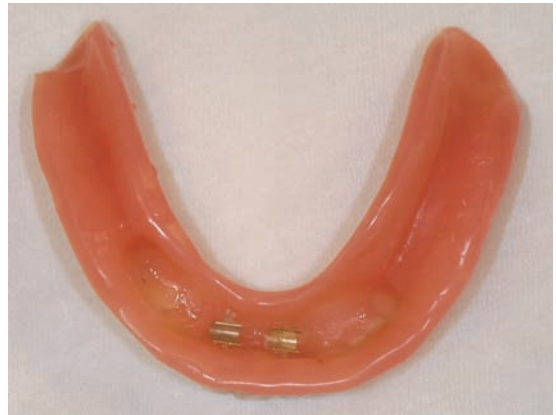(a)



(b)



(c)



(d)

**Fig. 23.12** A patient who had experienced difficulty managing a lower complete denture. (a) Pre-treatment OPT of edentulous mandible; (b) gold bar supported by two mandibular implants; (c) post-treatment OPT showing two mandibular implants and gold bar; (d) fitting surface of overdenture showing gold clips.

### General conclusions from clinical implant survival studies

Studies of single tooth implants show consistently high levels of success with individual centre reports of over 98% at 5 years, 96% at 8 years and 97.4% at 10 years.

The long-term survival rates of implants used to support partial bridgework though are not as consistently high as single tooth implant cases. The cumulative survival rate of maxillary implants was 90.2% and of mandibular implants was 93.7% at 10 years in one study. The survival rate for implant treatment in partially edentulous jaws followed up for 20 years in clinical function was 91% in another study.

A meta-analysis of long-term results of bridgework supported by a combination of teeth and implants

were not as favourable as wholly implant-supported cases. The 5-year survival rates of the implants were 90.1% and 10-year survival rates were 82.1% but the survival rates of the bridgework were found to be worse. At 5 years, 94.1% of the bridges were still in function but at 10 years this figure had dropped to 77.8%.

Studies of full arch bridgework cases show that implant survival rates are not as consistently high as for single tooth cases. Quoted cumulative survival rates are very similar as for partial bridgework cases and are of the order of 85–90%.

On the other hand, the survival rates of implants supporting mandibular overdentures are consistently high, probably amongst the highest achievable implant success rates, though the success rate in the maxilla is not as high.

## Clinical Cases

### Single tooth replacement

The patient shown in Fig. 23.10 suffered trauma to the upper incisors and in picture (a) has metal-ceramic crowns on the upper central incisors with poor shade match. The radiograph of the upper right central incisor (b) shows internal resorption. The upper right central incisor was extracted and an acrylic temporary bridge was provided supported by the upper left central incisor. Six weeks later a Brånemark Mk IV TiU regular platform implant was placed to replace it (c). The root filling of the upper left central incisor, although imperfect, has been present for over 10 years; the tooth is asymptomatic and there is no evidence of pathology and therefore interfering with the root filling is not indicated. A titanium ceramic abutment and ceramic crowns with milled ceramic cores were placed after 3 months on the central incisors and ceramic veneers placed on the lateral incisors.

The result is a very harmonious smile and the implant has been present for over 5 years.

### Bridgework case

The patient shown in Fig. 23.11a had bilateral free-end saddles in the maxilla. Brånemark Mk IV TiU regular platform implants were placed to replace the upper first premolars and first molars and these are shown at the healing stage in Fig. 23.11b. Pro-cera titanium abutments were placed 3 months later (Fig. 23.11c) followed by gold-ceramic bridgework (Figs. 23.11d–g).

### Overdenture case

Implants may be used to stabilise a complete denture and can be particularly useful if a patient is having difficulty in managing a non-retentive denture. Figure 23.12 shows such a case. Two Astra-Tech implants were placed and abutments placed 6 weeks later (Fig. 23.12c). A gold bar was attached to the abutments and gold clips in the denture were retained by this (Figs. 23.12d–e).

### Papers Used in the Summary of Cumulative Success Rates

- Henry PJ *et al.* (1996) Osseointegrated implants for single-tooth replacement: a prospective 5-year multicentre study. *Int J Oral Maxillofac Implants* 11:450–455.
- Bianc G *et al.* (2000) Osseointegrated implant for single-tooth replacement: a retrospective multicentre study on routine use in private practice. *Clin Implant Dent Relat Res* 2(3):152–158.
- Priest G (1999) Single-tooth implants and their role in preserving remaining teeth: a 10-year survival study. *Int J Oral Maxillofac Implants* 14:181–188.
- Lekholm U *et al.* (1999) Survival of the Branemark implant in partially edentulous jaws: a 10-year prospective multicentre study. *Int J Oral Maxillofac Implants* 14:639–645.
- Lekholm U (2006) Outcome of oral implant treatment in partially edentulous jaws followed 20 years in clinical function. *Clin Implant Dent Relat Res* 8:178–186.
- Jemt T, Johansson J (2006) Implant treatment in the edentulous maxillae. A 15-year follow-up study on 76 consecutive patients provided with fixed prostheses. *Clin Implant Dent Relat Res* 8:61–69.
- Adell R *et al.* (1981) A 15-year study of osseointegrated implants in the treatment of the edentulous jaw. *Int J Oral Surg* 10:387–416.
- Schwartz-Arad D *et al.* (2005) A long-term study of implants supporting overdentures as a model for implant success. *J Periodontol* 76:1431–1435.

## Chapter 24

# Removable Prosthodontics: Partial Dentures – Design

This chapter considers the first stages in the provision of partial dentures and the principles of their design. A step-by-step development of the design should be used to create the components for support and retention. Clinical experience and a detailed knowledge of the materials available will produce rational designs.

### Diagnosis and Treatment Planning

Supplying a partial denture to a patient is usually the last phase of a course of restorative treatment. The decision to make a partial denture will have been made following a thorough history and examination and discussion with the patient.

The dental history should include details of previous denture wearing experience (if any) such as:

- Do you wear a partial denture?
- If so, do you find it satisfactory?
- How long have you worn it?
- If unsatisfactory, what are the complaints?

If the patient has never had a partial denture then it is helpful to ascertain if they would like one and if so, why. These questions will help to clarify patient motivation and help in the decisions firstly, whether to provide a denture and, secondly, the type of denture that should be provided.

The examination of the mouth and oral tissues should include the condition, location and number of remaining teeth, condition of the soft tissues, the nature of the saddle areas, i.e. the height, width and consistency of the residual ridges and an assessment of the oral hygiene. The denture(s) should be inspected for fit, retention and stability, occlusal relationship, wear and cleanliness.

When all the information has been gathered and considered, a diagnosis can be reached and a treatment plan formulated. The plan will include a provisional partial denture design in order that other dental treatment can be completed appropriately and the mouth prepared to receive the partial denture.

The design, therefore, must be decided before embarking on other restorative procedures since it may

affect the type and material of the other restorations to be placed. This will optimise the function of the denture and maintain the health of the mouth. Further information and investigation is necessary in order to consider the design of the appliance this includes:

- Analysis of the occlusion
- Radiographs
- Model surveying

*Study models* serve a number of uses of which the most important are:

- Examination of the occlusion
- Model surveying – analysis of path of insertion and withdrawal, location of undercuts
- Trial preparation of the teeth
- Construction of special trays
- Communicating with the patient and the laboratory technician

### Examination of the occlusion

Although the occlusion can be assessed initially during an intraoral examination, the use of models permits a more detailed inspection and it is, of course, also possible to view the teeth from the lingual aspect. This enables tooth contact to be examined more easily to determine whether sufficient space exists for components of the partial denture design, e.g. occlusal rests. In many cases sufficient information can be gained by examining hand held models. However, this only reproduces the occlusion in a static state and therefore, for a more detailed analysis of occlusal function and articulation (movements of the mandible into and out of the position of maximum intercuspation), it is necessary to mount the models on a semi-adjustable articulator (Chapter 14).

## Model surveying

Model surveying is performed in order to determine the *path of insertion* and removal of the denture and to locate undercuts on the dento-alveolar tissues suitable for its retention.

## Trial preparation of the teeth

The earlier analysis of the occlusion and the model surveying might reveal the necessity for modification of the teeth either to improve or eliminate occlusal interferences or to alter the shape of the crown of the tooth, e.g. reduction of the height of contour on the proximal surface of the molar or premolar to produce a *guiding plane* parallel to the path of insertion in order to gain a more intimate contact between prosthesis and tooth. Such modifications can be rehearsed on the model before being performed in the mouth.

## Construction of special trays

Special trays are essential for subsequent impression procedures to ensure accuracy and reproduction of detail and, where appropriate, proper tissue moulding of the borders.

## Communication

Study models provide an excellent aid when discussing or explaining treatment to the patient and are an essential part of the prescription to the technician. An outline of the partial denture design can be drawn on the model to give a three-dimensional appreciation in those cases where a drawing on paper could be open to misinterpretation.

## Partial Denture Design

Designing the denture is a clinical responsibility since the dentist is the only person with all the information concerning the condition of the mouth and teeth. Liaison with the dental technician is perfectly appropriate and the technician may have suggestions to make from his point of view. However, the denture remains the dentist's overall responsibility.

Partial dentures should be designed using basic principles in a logical step-by-step sequence. Before detail of the design is considered four guidelines should be borne in mind:

- Simplicity
- Support from the teeth
- Relief of the gingival tissues
- Rigidity of the connectors

## Simplicity

A partial denture is more likely to be tolerated by the patient if the design is kept as simple as possible. Components should only be added for good reason and to serve a definite function. For example, the smallest number of clasps should be used compatible with retention and stability.

## Support from the teeth

In the lower arch, with its reduced mucosal area available for support, it is especially important to take advantage of the remaining natural teeth for support.

## Relief of the gingival tissues

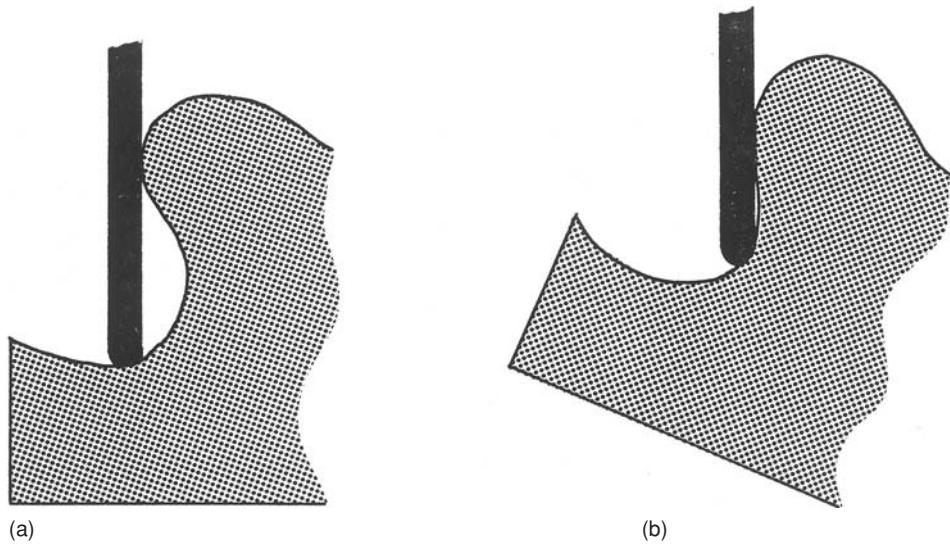
Plaque is more likely to accumulate around teeth that are covered by a denture and the problem is greatly magnified in patients with poor oral hygiene. Where gingival coverage is unavoidable, the impression surface of the denture should be closely adapted to the underlying soft tissue so that this does not grow to fill the potential space.

## Rigidity of the connectors

A thin flexible connector can easily be distorted during function or if gripped too firmly whilst cleaning.

## Design Stages

Provided a step-by-step sequence is followed no important components will be omitted and the design will be functional and satisfy the necessary criteria for clinical success. Several choices are usually available when designing and this means that it is possible to produce several different designs for the same patient. The final selection is based on many factors including knowledge of the clinical condition of the mouth, shape and length of the edentulous saddles, the patient's motivation and previous dental experience, availability of technical support and the overall costs of the treatment to the patient.



**Fig. 24.1** Surveying an alveolar ridge: (a) The survey rod illustrates a path of insertion that is at right angles to the occlusal plane; the denture base would not enter the tissue undercut; (b) the surveyor is tilted to provide a path of insertion that allows the denture base direct access to the tissue undercut. In view of the likely displacing forces in function, this undercut area will now provide direct and possibly indirect retention.

### Path of insertion/withdrawal

The *path of insertion/withdrawal* can be defined as the path followed by the denture from its first contact with the supporting tissues until it is fully seated. In effect this relates to the direction in which the patient will insert and remove the denture. There may be a single path or multiple paths of insertion and it may or may not coincide with the path of displacement, i.e. the direction in which the denture tends to be displaced in function (assumed for the purposes of design to be at right angles to the occlusal plane).

The path of insertion must allow the individual saddle areas to be seated but in addition, varying the path may improve the ability to engage tooth undercuts with clasps (see later). It is therefore necessary to consider three areas of the proposed denture at this stage:

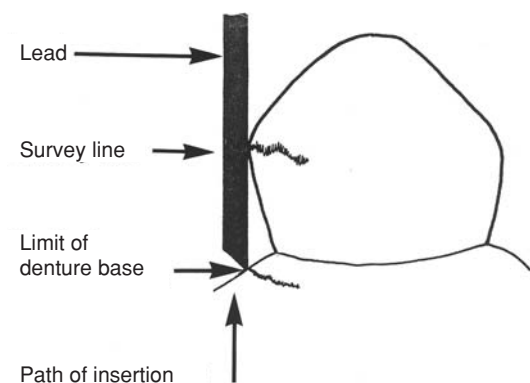
- Alveolar bone undercut
- Undercut caused by the approximal surfaces of abutment teeth overhanging the saddles
- Buccal and lingual tooth undercut in relation to clasping

The path of insertion is chosen whilst surveying the model. Surveying is usually undertaken with the occlusal plane horizontal but a tilt may allow hard or soft tissue undercuts to be engaged and therefore

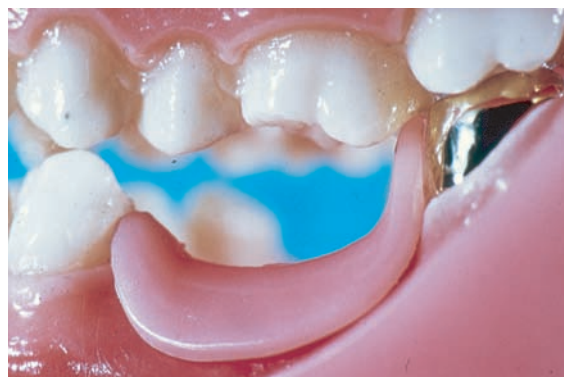improve the fit of the denture to the tissues. An example of this would be when upper anterior teeth are missing and there is a labial bony undercut present. Tilting a model with the heel down may permit more efficient utilisation of the labial undercut (Fig. 24.1), always assuming that this does not compromise the insertion of the denture in other areas.

Many partial dentures have multiple saddles and the final path insertion of the denture is likely to be a compromise between the ideal paths for each individual saddle together with the clasping sites. The approximal surfaces of abutment teeth may overhang the edentulous space and influence the path of insertion adversely (Fig. 24.2a). Here consideration should be given to modifying the approximal surface by grinding to produce *guiding planes* or, in severe cases of tilting, the provision of a restoration with the correct contour (Fig. 24.2b). If undercuts remain in the approximal aspects, these will be blocked out on the master model to prevent the denture base from engaging them during processing and later at the fitting stage.

Having obtained the desired tilt, the path of insertion should be recorded on the model. This can be done either by ‘tripoding’ (marking the model at three widely spaced points with the analysing rod fixed at the same vertical height) or by making vertical marks on the side of the base of the model in the anterior



(a)



(b)

**Fig. 24.2** Approximal undercut: (a) The survey line on an edentulous ridge showing an area of the tooth that could not be contacted by the denture base. This is a potential site for plaque accumulation, (b) Modification to the approximal surface will eliminate this undercut. In cases of tilting, a crown may be constructed to create a favourable relationship.

and posterior regions. Recording the path of insertion allows the model to be reorientated to the same position during later stages.

Once the path of insertion has been chosen it is necessary to:

- Outline the saddles
- Define the support
- Provide direct retention
- Consider the provision of indirect retention
- Join the components with connectors

An integral and important component of these stages is the choice of materials.

### Denture base materials

Partial dentures may be constructed from polymethyl methacrylate (acrylic) alone or, more commonly, in association with cast metal and/or wrought metal. The common alloys that may be used are cobalt–chromium, stainless steel and wrought and cast gold. Acrylic or ceramic may be used for the teeth.

### Saddles

Polymethyl methacrylate is universally used for replacing alveolar bone. Its ease of use and general physical properties are well suited to this. The only question mark over its use relates to the possibility of residual monomer within the material causing tissue reaction. This applies to both partial and complete dentures and is discussed in Chapter 30.

### Clasps and connectors

Whilst acrylic is cheap and simple to use, it is not an ideal material for partial denture connectors. It needs to be at least 2 mm thick for strength and therefore can be intrusive, particularly on the palate. Its plaque retaining ability is higher than the metal alloys and therefore its potential to initiate or aggravate periodontal disease is large.

Clasps and connectors should therefore be constructed from metal and the choice will relate to the proposed design. Cobalt–chromium alloys are almost universally used for connectors whilst clasp materials are chosen according to the undercut that they are to engage.

It is generally accepted that a cobalt–chromium clasp should only engage 0.25 mm of undercut because this material has a high elastic modulus and will deform or fracture if a deeper undercut is engaged. Cast gold has a modulus of elasticity of approximately half that of cobalt–chromium and can, therefore, engage greater undercut (0.5 mm) and a wrought structure, in the form of gold or stainless steel wire, has a lower modulus and good recovery and can be used in deeper undercuts (up to 0.75 mm).

### Teeth

Acrylic denture teeth have the advantages of being easy to adjust, chemical bonding to an acrylic denture base and cheapness. They have the disadvantages of having low wear resistance and the potential for becoming discoloured. Ceramic teeth, on the other hand, are more durable, retain their colour and are therefore more aesthetic in the long term. Their

disadvantages are that they are more time consuming to adjust, both clinically and in the laboratory, and mechanical retention to the denture base must be provided.

### The edentulous saddles

A classification of the edentulous saddles allows dentists and technicians to use a simple ‘shorthand’ description when referring to a particular case. The Kennedy classification is probably the most widely accepted:

- Class I bilateral edentulous areas (of any length) which lies posterior to the remaining teeth
- Class II a single edentulous area (of any length) which lies posterior to the remaining teeth
- Class III a single edentulous area (of any length) bounded by one or more teeth anteriorly and posteriorly
- Class IV a single edentulous area (of any length) which lies anteriorly to the remaining teeth

An early decision is required on which (if any) missing teeth need to be replaced. Guiding factors will include aesthetics, function, stability of the occlusion and wear of remaining teeth. The outline of the saddle(s) of the teeth to be replaced should be drawn on the design sheet.

### Support

Support for the saddles can be provided by:

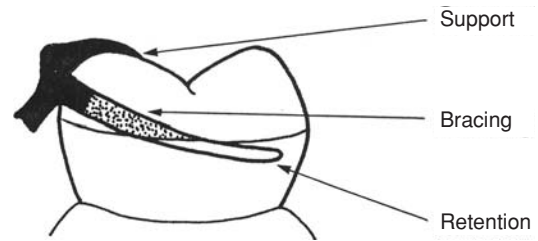
- Teeth
- Mucosa
- Teeth and mucosa in combination

As a general guide, permanent mucosa borne dentures with no tooth support should be avoided in the mandible because of the danger of overloading limited support area.

A tooth borne design is only possible when the saddles are bounded by natural teeth, i.e. in Kennedy Classes III and IV. In these cases the load is transferred to the natural teeth through extensions of the partial denture positioned on appropriate areas of the teeth and named accordingly:

- Occlusal rests – molars and premolars
- Cingulum rests – upper canines and incisors
- Incisal rests – lower canines and incisors

In Kennedy Classes I and II, the support is provided by both teeth and mucosa. In these cases the saddle



**Fig. 24.3** The component parts of a clasp unit. The reciprocating arm will be on the opposite side of the tooth.

should cover as large an area as possible to distribute the load widely.

### Direct retention

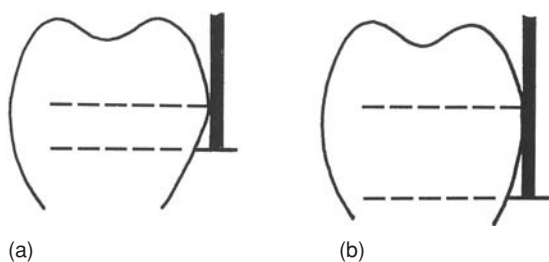
A *clasp*, or direct retainer, is the component that resists dislodgement of the partial denture along the path of withdrawal. It is a flexible metal arm that engages the undercut region on a natural tooth and forms part of a clasp unit, i.e.:

- Retentive arm
- Reciprocating arm
- Occlusal rest

The reciprocating arm is used as a bracing component to prevent displacement of a tooth by a direct retainer in its active phase, i.e. when it is being inserted or withdrawn over the survey line. The retentive arm should always be used in combination with a rest to ensure a proper and constant position. The portion of the clasp arm above the survey line is thicker and provides bracing against lateral movement whilst the portion below the survey line must flex to engage the undercut after insertion (Fig. 24.3).

The teeth chosen as potential retaining sites are examined with the analysing rod on the model surveyor and suitable undercuts and the survey lines marked with a lead marker. *Undercut gauges* can then be used to measure the depths of undercuts available in order to define the position of the retentive portion of the clasp arms in relation to the choice of material (see above). Three gauges are used, one for cobalt-chromium, one for cast gold and one for wrought gold. If the tooth surface is bulbous the clasp arm will be closer to the survey line whilst if it is shallow, the clasp will be more distant, i.e. the clasp arm is engaging a ‘standard’ degree of undercut for the chosen material (Fig. 24.4). On the other hand, if a retentive arm is placed in excessive undercut either the arm will





**Fig. 24.4** An undercut gauge determines the position of the retentive part of a clasp arm within the tooth undercut: (a) The arm will be nearer the survey line on a bulbous tooth; (b) the arm will be more gingivally placed on a less bulbous tooth.

be permanently deformed and no longer functional or it will fracture.

Although there are numerous designs of clasps, many linked with the names of their original protagonists, there are only two basic types (Fig. 24.5):

- Occlusally approaching – those which approach the undercut from the occlusal surface – *supra-bulge clasps*
- Gingivally approaching – those which approach the undercut from the gingival surface – *infra-bulge clasps*

The type of clasp used will be determined by:

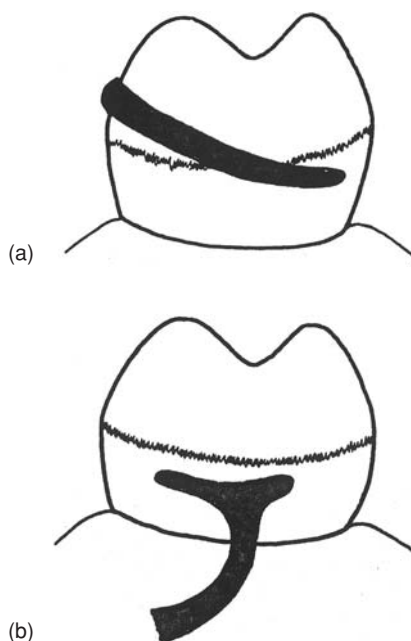
- The depth of undercut
- Position of the survey line
- Prosthetic considerations

The depth of undercut that can be utilised has been discussed previously in relation to the choice of materials.

The position of the survey line will have an important influence on the choice of clasp type. There are broadly four types of survey line (Fig. 24.6).

- Steep oblique
- Shallow oblique
- Occlusal third
- Gingival third

As was mentioned earlier, the survey line can be varied by changing the path of insertion. Whilst this can be superficially attractive in terms of the retentive arm, it must not be forgotten that the reciprocating arm and the denture base must also be capable of being inserted. For example, the low survey line may not allow the placement of a clasp arm. It could be ‘raised’ by the tilting of the model towards this side to



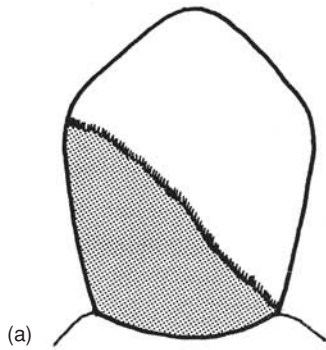
**Fig. 24.5** The two basic types of clasp: (a) Occlusally approaching. This may engage undercut directly from the marginal ridge or from the opposite marginal ridge as an encircling clasp, (b) Gingivally approaching. This is able to engage a low undercut and also reduces tipping forces on the tooth if the denture base moves into the alveolar tissues.

produce a higher line. However, the result of this would perhaps be to reduce undercut on the opposite side and also prevent seating of the denture base.

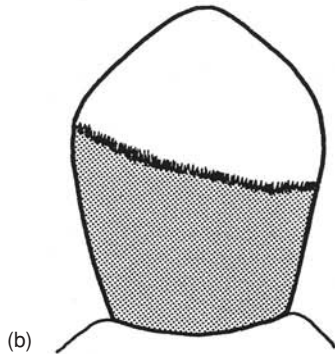
The low survey line may be engaged by a *gingivally approaching clasp* (Fig. 24.5). This has the advantage that the arm is longer and more flexible and, because of its position, is often less visible and therefore aesthetically more acceptable to the patient. However, because of its length and relationship to the gingiva it is more likely to cause food stagnation around the neck of the tooth.

If the survey line is very close to the gingival margin then there will not be space for the clasp arm. Here the contour of the tooth could be increased by a restoration, perhaps simply an acid etch retained composite supplement.

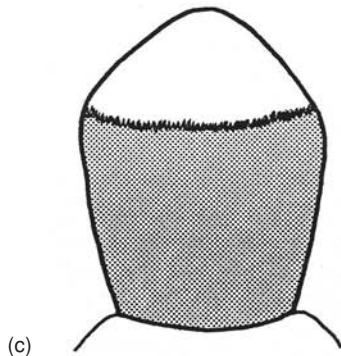
The design of restorations that are needed for abutment teeth should include consideration of providing retentive contours, shoulders and ledges for clasps and denture bases and rest seats within the overall contour (Fig. 24.7). This is why it is so important to decide upon the denture design before embarking upon restorations.



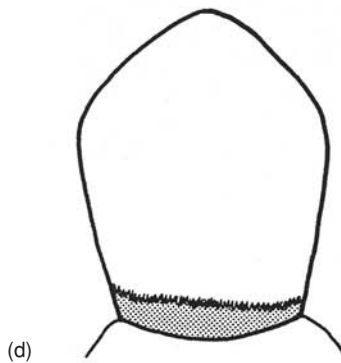
**Fig. 24.6** The four basic survey lines with the undercut areas shaded:  
 (a) Steep oblique. This is the most favourable line for an occlusally approaching clasp with the distance from the marginal ridge to the line permitting a good bracing component for the clasp arm,



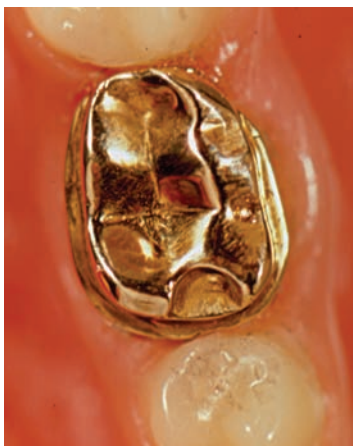(b) Shallow oblique. This allows less bracing but greater retention,



(c) Occlusal third. This is an unfavourable line for an occlusally approaching clasp because there will be little or no bracing action. A wrought clasp is better suited to this line so that the arm lies lower on the tooth. Alternatively the line is ideal for a gingivally approaching clasp,



(d) Gingival third. This is an unfavourable line with little or no undercut available. The tooth contour could be changed by a buccal restoration that increases the bulbosity.



**Fig. 24.7** A full crown denture abutment with a rest seat and clasp ledges. The clasps will be constructed within the normal tooth contours rather than adding bulbosity to the tooth.

### Indirect retention

Indirect retention is retention obtained by the extension of the partial denture base to provide the fulcrum of a Class II lever. The retainer(s) providing direct retention lie(s) between the fulcrum and that part of the denture which is subject to the displacing force. In practice, indirect retainers assist clasps in resisting displacement of the partial denture in function by providing resistance to rotational dislodging forces. The main need is with tooth/mucosa borne (free-end saddle) partial dentures especially in the maxilla because of the constant additional effect of gravity tending to dislodge the saddles.

Indirect retention can be provided by, for example, an extension of the major connector on the palate, additional rests on the natural teeth and the use of a lingual plate instead of a lingual bar connector in the mandible.

### Connectors

As the term suggests connectors join the component parts of the partial denture and are the final stage in the design sequence. They can be classified as either *minor* or *major* connectors. The role of minor connectors is to link the rests and clasps to the major connector or denture base. They should be strong enough to withstand heavy occlusal loads and usually be positioned to lie in embrasures in order to be unobtrusive.

Major connectors join the saddles and should be rigid so that the partial denture transfers forces to all the supporting structures on both sides of the arch and therefore functions as a single unit. The major connector should, ideally, lie at least 3 mm from the gingival margin in order to maintain the health of the tissues.

In the mandible the major connectors can be classified into five categories:

- Lingual bar
- Sublingual bar
- Lingual plate
- Dental bar
- Buccal bar

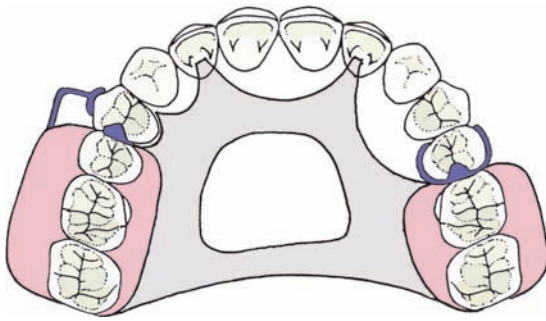
Variations are, however, possible and include the combination of lingual bar and ‘continuous clasp’ (a misnomer since no part of the structure engages undercut – it functions as an indirect retainer). The lingual bar and lingual plate are the most commonly used. The lingual bar does not overlay the gingival margins and therefore does not promote plaque accumulation but requires approximately 8 mm of height measured from the gingival margin to the depth of the sulcus, i.e. 3 mm from the gingiva to the bar, at least 3 mm depth of bar and a further 2 mm below the bar to the sulcus.

The lingual plate covers the lingual surface of the anterior teeth and the upper portion of the lingual aspect of the alveolar process. It provides excellent indirect retention and is generally well tolerated by patients but is likely to lead to an increase in plaque deposition and so is best avoided if there is evidence of susceptibility to periodontal disease.

The *sublingual bar* lies in the floor of the mouth and fills the entire depth and width of the lingual sulcus. It is an attempt to lessen tongue irritation. Since it is shorter than the lingual bar, and also thicker, it is more rigid. A very careful impression technique with functional moulding of the lingual sulcus is required otherwise the bar will cause irritation of the tissues.

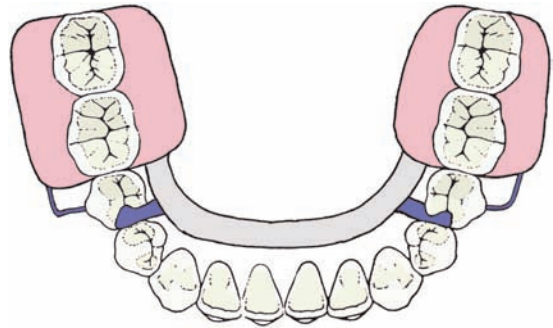
The *dental bar* is a modified ‘continuous clasp’ which lies on the lingual surface of the anterior teeth and is clear of the gingival margins. Although ideally positioned since it can be used regardless of lingual alveolar ridge depth and there is no gingival coverage, it needs to be made sufficiently thick to be rigid and this can reduce its acceptability to the patient.

If the anterior teeth are markedly retroclined and it is impossible to develop a suitable lingual path of insertion, a *buccal bar* can be used. This is positioned in a similar relationship to the gingival margins and sulcus as the lingual bar. Since it has a wider arch



**Fig. 24.8** Schematic partial denture designs:  
(a) Upper bilateral free-end saddle (Kennedy Class I). The components are:

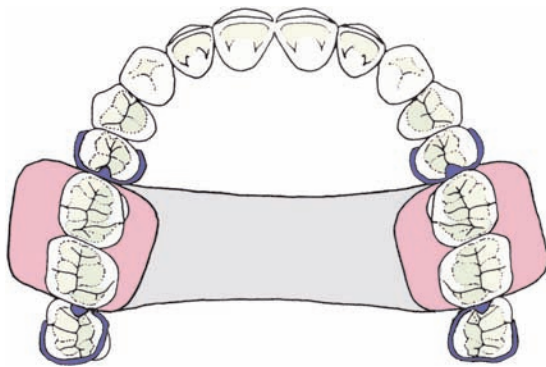
*Saddle areas:* 76|67, denture base and teeth in acrylic  
*Tooth support:* Occlusal rests 4|5 and cingulum rests 2|2  
*Direct retention:* (i) gingivally approaching clasp 4| wrought gold – this has better aesthetics on the more anterior tooth  
 (ii) occlusally approaching clasp unit 1|5 cobalt–chromium  
*Indirect retention:* The posterior aspect of the denture will tend to drop about the fulcrum of the occlusal rests. Components anterior to this fulcrum will resist this displacement. These are cingulum rests 2|2 and anterior aspect of the palatal ring  
*Connector:* Palatal ring  
*Framework material:* Cobalt–chromium



**Fig. 24.8** (c) Lower bilateral free-end saddle (Kennedy Class I)

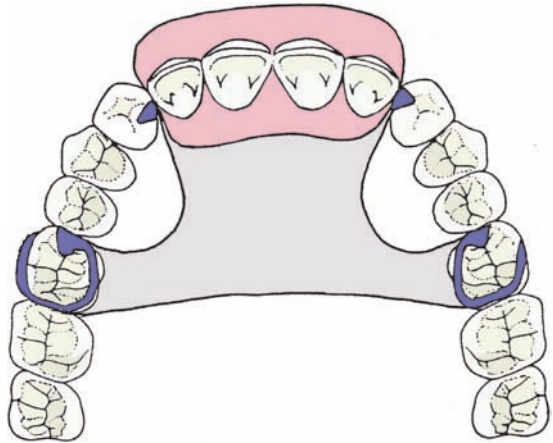
*Saddle areas:* 76|76 denture base and teeth in acrylic  
*Tooth support:* Occlusal rests mesially 5|5  
*Direct retention:* Gingivally approaching clasps 5|5, I-bars  
*Indirect retention:* None  
*Connectors:* Major – lingual bar  
 Minor – to rests 5|5  
*Framework material:* Cobalt–chromium

Occlusal forces on the denture will cause rotation around a fulcrum joining the mesial occlusal rests – See RPI (mesial rest, distal plate and I-bar clasp) system in text – and the gingivally approaching clasps will be disengaged. Unfavourable tipping forces will therefore not be applied to the abutments.



**Fig. 24.8** (b) Upper bilateral bounded saddle (Kennedy Class III)

*Saddle areas:* 76|67, denture base and teeth in acrylic  
*Tooth support:* Occlusal rests 85|58  
*Direct retention:* (i) occlusally approaching clasp units 5|5, buccal arms engaging mesial undercut  
 (ii) occlusally approaching clasps 8|8 again engaging mesial undercuts but because the origin of the clasps is mesial as well the clasps must come from the distal aspects as encircling clasps  
*Indirect retention:* None required  
*Connector:* Posterior palatal bar  
*Framework material:* Cobalt–chromium



**Fig. 24.8** (d) Upper anterior saddle (Kennedy Class IV)

*Saddle areas:* 21|12, denture base and teeth in acrylic  
*Tooth support:* Occlusal rests 6|6 and cingulum rests 3|3  
*Direct retention:* Occlusally approaching encircling clasp units 6|6  
*Indirect retention:* The clasp units on 6|6 approach the mesial undercuts from the distal. Therefore when the denture tends to drop around the fulcrum between the occlusal rests the clasp arms are engaged to prevent it  
*Connector:* Middle and anterior palatal bars  
*Framework material:* Cobalt–chromium

than a lingual bar it is longer and therefore needs to be made thicker to maintain the rigidity. In practice it is rarely used.

In the maxilla there is greater flexibility in the design and type of major connector(s) that can be used. The main requirements are, as with lower connectors, that the structure is rigid, well tolerated by the patient and that it is compatible with gingival health. The following designs are generally recognised:

- Palatal plate
- Anterior palatal bar
- Mid palatal bar
- Posterior palatal bar
- Open ring (anterior and posterior palatal bar combination)
- Horseshoe, U shaped

The term ‘bar’ can include connectors that are wider than the term suggests when compared to use in the lower arch. In these cases others have favoured the term ‘strap’.

### Indicative Designs

Figure 24.8 illustrates four designs that incorporate features that have been discussed above. As with fixed prosthodontics, there are no ‘standard’ designs with

clinical experience being a large factor in choice and there being little biomechanical evidence for many empirical principles.

### The RPI Case System

The RPI (mesial rest, distal plate and I-bar clasp) system was originally described in the 1960s and further developed in the 1970s, although its usage is still limited. The concept attempts to distribute the masticatory loads between the saddles and abutment teeth. For each saddle the occlusal rest is placed mesially (as Fig. 24.8c) since there is evidence that this gives more favourable and even load distribution. Guide planes mesially and distally are utilised by the minor connector joining the rest to the major connector and the distal plate. This plate lies on the 3- to 4-mm guide plane so that when the denture is fully seated the plate contacts only the lower 1 mm of that surface. (The portion over the gingiva is relieved.)

The I-bar clasp tip is positioned on, or anterior to the midpoint of the buccal surface and is braced by the guide plane contacts. The load on the saddle causes the denture to rotate about the occlusal rest and the distal plate and I-bar tend to disengage preventing further stress being posed on the abutment tooth.

#### Partial Denture Design – Summary

The design of partial dentures is the responsibility of the dentist and not the technician.

All partial dentures should, wherever possible and particularly in the lower arch, utilise teeth for support to complement support provided by the alveolus.

Cast metal frameworks (direct and indirect retainers and connectors) are recommended for strength, durability, periodontal health and patient comfort in comparison with acrylic.

Whilst there are many options for inclusion in a denture design, the overriding consideration is to keep the structure as simple as possible.

## Chapter 25

# Removable Prosthodontics: Partial Dentures – Clinical Procedures

The clinical stages in the construction of a partial denture are described together with their practical problems.

The stages in the construction of a partial denture are:

- Preliminary impressions
- Secondary (working) impressions
- Occlusal registration
- Try-in of metal framework
- Try-in of waxed dentures
- Fit
- Review

### Preliminary Impressions

An elastic impression material is required to reproduce the details of the natural teeth and tissue undercuts. Alginate is the material of choice but it requires support from an adequate stock tray made from either metal or plastic. Metal is more rigid, whilst the plastic type may be prone to deformation, depending on its design.

A suitable size should be chosen that encompasses all the teeth and extends into the labial and buccal sulci. In areas where there are several missing teeth, for example free-end saddles in the lower arch, the tray should be modified by the addition of impression compound (suitably moulded) to take up some of the excess space and also extend the tray into the sulcus. This will ensure that the alginate is adequately supported and hence used within its functional limits for maximum accuracy of reproduction. Although only one partial denture may be required, it is necessary to take impressions of both jaws in order to record the occlusion.

After trying in, the impression trays should be dried and an even, thin layer of adhesive applied to aid retention of the impression material to the trays. The alginate should be mixed according to the manufacturer's instructions using water at room temperature

and transferred immediately to the lower tray using a spatula. It is preferable to take the lower impression first since this is generally tolerated better and allows the patient to become accustomed to the procedure.

When taking the upper impression, two techniques are commonly described. In the first the posterior portion of the tray is seated first and then the anterior portion. This is intended to force the alginate upwards and forwards away from the sensitive posterior areas of the palate and fauces. For the second, the anterior portion is inserted with the lip held away from the tissues to aid inspection and then the tray gradually pushed up posteriorly until a slight excess of material exudes from the border of the tray at which point the tray is held firmly in position until the alginate sets.

When the surface of the alginate is no longer tacky it is set and the impression tray can be removed from the mouth. Removal should be performed with a single firm motion after breaking the seal between impression and tissues by pulling the cheeks or lips away from the periphery of the tray. Alginate has poor mechanical properties and is likely to tear when removed from deep undercuts or in thin sections particularly between teeth.

The impressions should be rinsed under running water to remove mucus and/or blood and spray disinfected with aqueous 0.5% chlorhexidine solution or immersed in 1% sodium hypochlorite solution for 10 minutes. Following decontamination, the impressions should be washed in running water and then sealed in a clear polythene bag that allows the laboratory technician to inspect them prior to casting the models.

These models may be used for the diagnostic stage (see Chapter 24) or may be constructed after other restorative work has been done.

## Secondary (Working) Impressions

All other dental treatment should usually be completed prior to the secondary impression stage. This might include:

- Extraction of unsavable teeth
- Scale and polish and oral hygiene instruction
- Restorations
- Other periodontal therapy
- Mouth preparation for the denture

The design for the partial denture may require the preparation of the teeth for rest seats and/or modifying the shape of the teeth in other ways, e.g. grinding, to allow the chosen path of insertion.

### Special tray

A secondary impression is taken in a specially constructed spaced tray and is only necessary for the arch in which a denture will be constructed. The special tray is usually made of acrylic thus allowing it to be easily modified by reduction or addition to the borders. The tray should be tried in the mouth and examined to ensure it is short of the tissue reflection by approximately 2 mm if alginate is to be used. This space allows the impression material to flow around the borders and be moulded by the tissues. There is no need to spend time accurately defining the border extension in those areas of the mouth not related to the fit of the denture; for example, with free-end saddles the anterior labial sulcus depth is of no consequence. However, the areas immediately adjacent to the saddles require special attention.

The tray should be constructed with spacers contacting the teeth or tissues in at least three positions, avoiding teeth with rest seat preparations, to ensure correct relocation of the tray and an even thickness of impression material. In the case of a standard impression technique for a lower arch with free-end saddles, the spacers should contact the ridge towards the posterior aspect of the tray.

The most commonly used impression material for partially edentulous mouths is alginate. It is sufficiently accurate, when supported by an evenly spaced tray, for the construction of cobalt–chromium frameworks. However, it does have some limitations:

- Tearing on removal from severe undercuts
- Poor dimensional stability due to syneresis
- Rapid setting reaction at higher temperatures – the material in contact with the tissues therefore sets first, which may give rise to stresses within the material if the tray is moved during setting

The likelihood of tearing can be reduced by blocking out approximal areas provided they are not essential to the overall impression. Soft carding wax is a suitable material since it is easy to apply and to remove. If it is necessary to reproduce severe undercuts, then an elastomeric impression material should be chosen, i.e. polyether or silicone. The polyethers are stiffer than other elastomers and may therefore be difficult to withdraw from severe undercuts. Both materials are expensive, relative to alginate, and therefore not frequently used in impressions requiring large quantities of material. They are, however, more dimensionally stable and should be considered when the impression cannot be cast within 30 minutes of removal from the mouth (see Chapter 17).

### Free-end saddles

Opinions vary regarding the best impression technique for the lower arch with extensive free-end saddles. The single-stage elastic impression produces a cast which represents the hard and soft tissues at rest (mucostatic). It has been argued that a functional relationship should exist between the various supporting structures so that both the teeth and the mucosa are compressed equally. To achieve this and to control the load applied to both teeth and ridges there are two main approaches:

- Reduce the load
- Distribute the load between teeth and residual ridges

The load can be reduced by leaving a tooth off the saddles and/or by using narrow teeth.

Distribution of load is more complex and includes such methods as stress breaking and various combinations of the position of rests and clasps. Mucocompressive impression techniques attempt to distribute the load by reproducing the tissues covering the ridge as they are under load.

Free-end saddle rock (downward movement of the saddle under load) can occur if the denture is constructed using a mucostatic impression when there is displaceable mucosa overlying the edentulous ridge. When load is applied to the occlusal surface of the artificial teeth, part of the force is transmitted through the denture base and displaces the underlying mucosa. The degree of movement of the saddle will depend on the load applied and the condition of the tissues underneath it.

Although it is possible to use a dual-impression technique comprising a first-stage mucocompressive impression of the saddle areas with an overall

alginate final impression, this is a cumbersome procedure. An easier and more effective way is to construct the metal framework on a cast from a mucostatic impression and then to obtain mucocompressive impressions of the saddle areas in order to modify these areas of the cast. This is known as the *altered cast technique*.

#### **Procedure for the altered cast technique**

- 1 Working impression in alginate taken in evenly spaced special tray
- 2 Construction of cobalt–chromium framework with the addition of close-fitting saddles
- 3 Clinical trial of the metal framework
- 4 Border trimming of the saddles using greenstick tracing compound – or other suitable material
- 5 Zinc oxide–eugenol paste (or elastomer or impression wax) impression of the saddle areas ensuring that the metal framework is held firmly in position on the teeth whilst the material sets; no direct load is applied to the saddle areas – this ensures the fit of the framework is not disturbed
- 6 In the laboratory the free-end saddles are cut away from the original working cast and the denture then seated in place; the cast is made good by pouring gypsum into the saddle areas
- 7 The saddle areas are processed onto the metal framework using the altered working cast

This technique has the advantage that it should avoid free-end saddle rock occurring with a new denture. However, it requires additional clinical and laboratory stages, which it can be argued, are not always necessary. An alternative approach is to complete construction of the partial denture on the original working cast and to assess the fit in the mouth.

### **Occlusal Registration**

There may be sufficient remaining natural teeth to allow the working models to be mounted on the articulator in centric occlusion simply by placing them together by hand. Their relationship should be checked against that of the natural teeth and, if they are in accord, guidelines can be marked across upper and lower teeth to inform the technician of this relationship.

If there are too few teeth to provide a stable and precise relationship but there are some natural teeth that contact and form an appropriate occlusal vertical dimension in centric occlusion, then an occlusal

registration using shellac-based wax rims is required. One or two rims may be necessary depending upon the number of teeth remaining. Here the rim(s) simply aid the registration of the horizontal relationship around the existing teeth.

The wax rim(s) can be trimmed vertically until just out of contact either with each other or the opposing teeth and a layer of bite registration material placed on them. The patient is asked to close his back teeth together and the occlusion registered.

If, however, the natural teeth do not give an indication of either the vertical or horizontal relationship then the reference position for the construction of the dentures will be centric relation. The registration procedure resembles that used in the complete denture technique that will be discussed in Chapter 26.

Sometimes it is more convenient to register the occlusion after the construction of the metal framework with wax rims attached to the framework. For example, in cases of lower free-end saddles. This has the advantage that the framework will ensure proper location and support for the rims. However, if there are sections of the framework that have an occlusal relationship, e.g. the occlusal aspects of rest seats, then occlusal registration and articulation will be essential for the construction of the casting. If the metal framework is not constructed to an accurate occlusal record in the first place, much grinding may be necessary at try-in.

### **Try-In of the Wax/Metal Partial Denture**

First check that the design constructed by the laboratory conforms to the prescription and that the fit on the model is satisfactory.

The try-in procedures will be determined by whether it is a wax or metal try-in. If a wax try-in then the artificial teeth will have been set-up. The check procedure in this case should include:

- Fit and adaptation
- Retention and stability
- Occlusion
- Occlusal vertical dimension
- Tooth position and aesthetics

First examine the mouth and occlusion without the denture as a reminder of the relationship. An appreciation of the retention and stability of the denture can be gained at this stage by checking the general fit of the base and adaptation to the supporting tissues. A comparison should be made of the occlusion with



and without the denture in place to ensure that the natural teeth still come together – unless, of course, the partial denture(s) has been specifically designed to modify the horizontal and vertical occlusal relationships. Tooth position should be assessed in relation to both stability of the prosthesis and aesthetics. Finally, the dentist should check the shade of the artificial teeth against the natural teeth before allowing the patient to inspect them. The patient's opinion is obviously important but, if possible, try to persuade him/her to look at the mouth in a mirror at a realistic viewing distance, i.e. 2 or 3 feet away. Many patients hold a mirror very close to the face and mouth rather than from the distance others normally see them. When both dentist and patient are satisfied with the trial procedures the wax try-in can be returned to the laboratory.

For a metal try-in, first check the general fit by ensuring that the rests fit snugly into the prepared seats and that the denture can be inserted and removed with relative ease. It is most important to check that the metalwork does not interfere with the occlusion. For this reason it is common to inspect the metal framework before the addition of the artificial teeth or saddles. If the patient is to receive partial dentures in both upper and lower arches then the sequence is as follows:

- Check the occlusion of the natural teeth
- Seat one framework in the mouth and reassess the occlusion – if the natural teeth do not contact reduce the metal accordingly
- Take out the first framework and seat the other and repeat the occlusal examination
- When satisfied that both frameworks are individually satisfactory, examine the occlusion with both in place. Once again adjust the metal accordingly

*Note.* It is usually appropriate to limit grinding to the metal framework but on occasions reduction of the opposing tooth structure may be warranted to gain sufficient space to accommodate a sufficient thickness of metal.

If the upper anterior teeth are to be backed with an extension of the metal framework to give them additional protection, then it is important that a wax trial of tooth position is assessed to establish the correct tooth position and hence the appropriate position of the metal backing.

When the metal try-in has been performed, teeth can be added, either in the laboratory or at the chairside (if small in number) and a further try-in completed. On this occasion occlusal discrepan-

cies should, if the previous visit was performed adequately, be due only to the artificial teeth or wax and can be dealt with accordingly. When satisfied with the occlusion and aesthetics the try-in is sent to the laboratory for processing.

## Insertion of Dentures

When the processed dentures are returned from the laboratory the acrylic components should be checked for surface imperfections such as sharp ridges or 'pimples'. The denture should then be inserted without undue pressure until firmly seated. Once again a check is made of fit in relation to adaptation and the extension of the borders. The fitting surface can be checked using a pressure indicating paste to ensure even contact over the entire surface.

If the partial denture has a metal framework, the adaptation of the rests to the teeth and the general fit of the metalwork should be inspected as during the try-in visit. If the denture does not appear to be fully seated then, if the metal try-in was performed properly, it should only be the acrylic component that requires attention. Ensure that acrylic 'flash' has not extruded under the rests or the metal contact areas adjacent to the natural teeth.

If the design of the lower denture includes a free-end saddle, the denture should be examined for downward movement of the saddle under load. This is done by resting the fingers of one hand on the anterior framework while applying pressure to the saddle with the index finger of the other hand. If a free-end saddle rock is evident, it will be determined by movement of the anterior framework away from the teeth. In this case the fitting surface of the free-end saddle(s) will require modification. This can be done using either a chairside or laboratory reline.

## Chairside reline

A chairside reline can be completed using one of the self-curing polymers marketed for use in the mouth (e.g. Tokuso Rebase). The technique is as follows:

- 1 Having checked for correct extension, the fitting surface of the saddles and the borders are cleaned and dried – they can be roughened if the resin is not 'fresh'
- 2 Bonding agent, if supplied, is painted sparingly on the area to be relined

- 3 By following the manufacturer's instructions, a mix of the material is applied to the saddle areas and the denture inserted in the mouth
- 4 The framework is held firmly in place, with no direct load being applied to the saddles
- 5 After 2 or 3 minutes the denture is removed whilst the polymer is still rubbery to check that it has not flowed into undercut areas and that there are no imperfections
- 6 Excess can be trimmed away with a sharp knife and the denture returned to the mouth for a further period to allow curing
- 7 When rigid, the borders are trimmed and polished
- 8 A final check is made of the occlusion

Such a reline should last many months and has the advantage that it is completed with the patient present. A period without the denture is therefore avoided. It is also suitable for making during domiciliary visits.

### Laboratory reline

A laboratory reline requires impressions of the saddles, which can be completed using zinc oxide-eugenol paste, elastomers or impression wax. It may be necessary to reduce undercuts to prevent fracture of the stone model when the denture is removed and also to grind a thickness from the fitting surface to make more space available for the impression material. As before, the fitting relationship of the metal framework to the natural teeth must be maintained by ensuring that the occlusal rests are correctly seated throughout the impression. Readjustment of the occlusion must be anticipated when the relined denture is fitted.

If a reline at the fit stage of denture construction is a planned procedure, sufficient space to accommodate the impression material can be predetermined by using metal foil 1 mm thick over the saddles prior to adding the acrylic resin in the laboratory.

### Completion of the insertion stage

When the fit of the denture is considered satisfactory, it should be examined for an even and simultaneous occlusion and adjusted, if necessary, to allow free

movement between centric occlusion and centric relation.

When satisfied with all aspects of the denture the patient is shown how to insert and remove it from the mouth without damaging either the tissues or susceptible components such as clasps.

Finally, the patient should be given advice and guidance on denture wearing, especially if a first-time wearer, and instructions on cleaning both the denture and the natural teeth. Verbal communication should be reinforced by giving the patient a sheet of written instructions. Simple guidelines on cleaning are as follows:

*Unless your denture(s) and remaining natural teeth and gums are kept really clean, there will be an increasing amount of tooth decay and gum disease. To prevent this you should*

- Clean your teeth and rinse your denture(s) after each meal
- Pay particular attention to cleaning the teeth next to the denture
- Avoid in-between meals snacks, especially sweet and sticky foods.

*When brushing your partial denture, handle it carefully to avoid bending or breaking any of the parts. The intricate design of a partial denture makes it susceptible to plaque build-up and a routine of brushing using a soft toothbrush and soap and water and soaking in a denture cleanser every night will ensure maximum cleanliness.*

### Review

A week after the insertion, the patient should be reviewed. Any problems to do with comfort and function should be discussed and the denture supporting area examined for ulceration or erythema. It may be necessary to ease the denture in such areas.

The occlusion should be rechecked with articulating paper and adjusted if the displacement of the denture bearing areas has resulted in uneven contact.

Continuing care should be arranged and the patient told about the importance of maintenance of the denture and surrounding tissues and the need for regular recall to check for caries and periodontal disease.

# Chapter 26

## Removable Prosthodontics: Complete Dentures

Whilst the number of edentulous individuals is decreasing as more people retain their teeth into old age, the provision of complete dentures remains an important aspect of restorative dentistry. It is still much more of an art than a science and the skilled operator exercising a judgement based on experience and artistry will have greater success. This chapter considers the design and construction of complete dentures together with overdentures.

### Introduction

When the natural teeth are lost, there is a corresponding reduction in the alveolar bone resulting in loss of support for the perioral muscles and tissues. Complete dentures are necessary to restore and preserve the facial appearance and masticatory function and they play a major role in the physical and mental well-being of the individual. The loss of all the natural teeth and the construction of complete dentures can be considered as the final phase of restorative treatment and should, where possible, be the product of a planned transition from the natural dentition. This transition period would normally include a period when partial dentures are worn and would allow the individual to adapt to and master the techniques of wearing prostheses that should encourage ready adaptation to complete dentures.

### Functional Aspects of Complete Dentures

#### Retention

Retention may be defined as the resistance of a denture to dislodgement (usually directly away from the ridge) and in complete dentures depends on two interacting factors. These are:

- Muscular forces
- Physical forces

*Muscular control* is very important for complete dentures, especially in the lower arch. If the shape of the polished surfaces of the denture is in harmony with the oral musculature so that the muscles when functioning tend to seat the dentures rather than dislodge

them, retention will be enhanced and the patient's acquisition and development of the necessary controlling skills will be easier.

*Physical forces* depend upon:

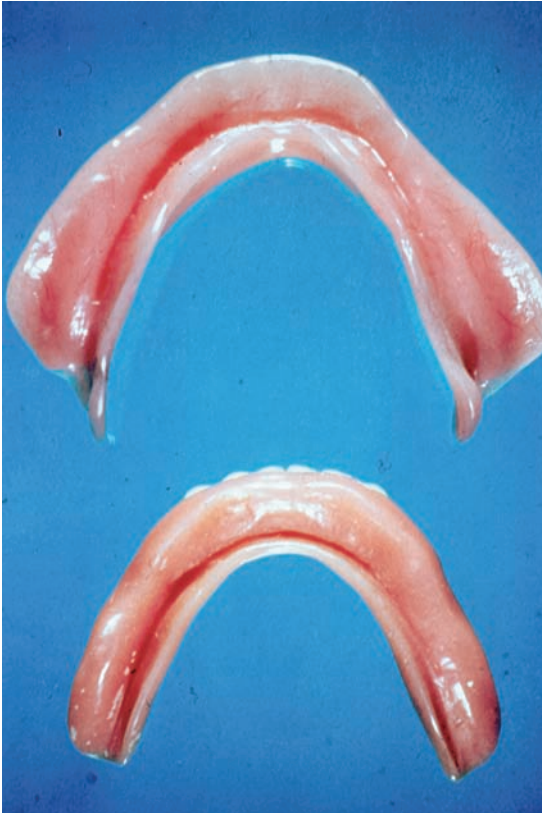- *Adhesion* – the force of attraction between dissimilar molecules in close contact (acrylic–saliva–mucosa)
- *Cohesion* – the force of attraction between like molecules (saliva–saliva)

Both are influenced by the nature, quantity, surface tension and viscosity of saliva as well as the accuracy of fit of the prosthesis. A thin saliva film provides the best retentive force. For optimum retention dentures must be correctly extended and closely adapted to the tissues.

The flanges of a denture must be adequately extended and correctly shaped to produce the border seal and to provide resistance to the ingress of air that would otherwise destroy the physical forces. The magnitude of physical retention is also related to the area covered by the denture and it is therefore important to utilise the maximum available (Fig. 26.1).

#### Support

Support provides the resistance to the compressive forces of chewing, swallowing, clenching etc. The pressure on the underlying mucosa and bone is reduced as the support area is increased, even though there is evidence that individuals with well supported dentures can chew with higher forces, so again the maximum possible area should be used. Close adaptation of the impression surface of the denture ensures an even distribution of load to the tissues.



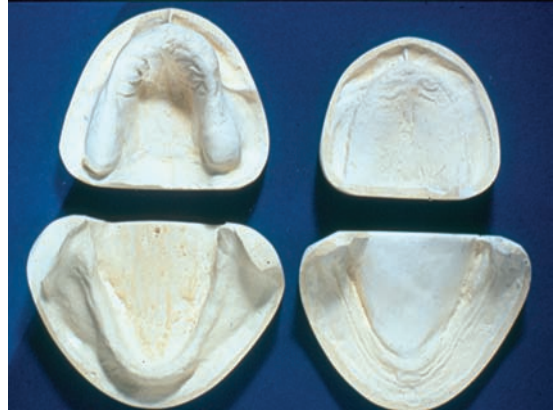**Fig. 26.1** The fitting surface of two lower dentures. The lower picture shows a denture that is grossly underextended in both lingual and buccal sulci. The upper picture shows one that is correctly extended.

### Stability

This may be defined as the resistance of a denture to displacement (mainly in a lateral direction) by functional forces. The degree of stability depends upon the shape and consistency of the ridges and palate for an upper denture and the relationship of the denture base to the underlying bone. Flat ridges readily allow lateral movement of the dentures. Maximum stability is gained when the ridges have pronounced contours and where there is little displaceable overlying soft tissue (Fig. 26.2).

### Construction of Complete Dentures – Clinical Stages

The construction of complete dentures by conventional techniques involves the following clinical stages:



**Fig. 26.2** Types of alveolar ridge. The models on the left show ridges that are pronounced and will give good support to the dentures whilst those on the right show considerable resorption. A denture made for such a flat lower ridge will require considerable adaptation by the patient in order to stabilise and control it.

- Assessment of the patient, treatment planning and preliminary impressions
- Final impressions
- Recording jaw relationships and choice of artificial teeth
- Checking trial dentures
- Inserting and reviewing the dentures

### Assessment of the patient

An assessment of the patient will include a past dental history and medical history taken in a calm and relaxed atmosphere. This background information is possibly more important with complete dentures than with any other aspect of dental treatment. A great deal can be ascertained about the individual's expectations and their motivation for seeking treatment that can have a direct bearing on the eventual success or otherwise of dentures. Sometimes, especially with those with no previous denture wearing experience, the level of expectation for both aesthetics and function from dentures can be unreasonably high.

The history of experience of wearing dentures is particularly valuable since it is likely that the individual who has worn the same set of dentures successfully for a reasonable length of time will more readily adapt to new dentures than will the individual for whom a series of unsuccessful dentures has been made. Time spent at this early stage will help elicit whether it is the design and construction of

previous dentures that is at fault or if the personality and mental attitude of the patient are the overriding factors. It will also help develop a closer rapport with the patient and help the dentist gain a greater understanding of the prosthetic requirements.

### Medical history

A thorough medical history should include knowledge of any drugs being taken since their relationship to certain oral symptoms is well recognised. It is also important to recognise that the elderly tend to suffer from multiple pathology and a patient may be taking several drugs. A complaint of a dry mouth may well be associated with atropinic or tricyclic drugs and can have important consequences for successful denture wearing. There are few medical conditions that contraindicate the construction of complete dentures though several, e.g. stroke, Parkinsonism and debilitating disease, may severely reduce the patient's adaptive capacity and chances of success.

### Examination

An examination of the patient should include an extraoral inspection that effectively begins when the individual enters the room. Information on mobility, communication and general demeanour can be rapidly ascertained. Attention should be paid to the face, particularly lip posture at rest and during function, and possible habits associated with denture wearing such as lifting the lower denture with the tongue. The intraoral examination should include a thorough screening of all the tissues for pathology and a more detailed assessment of the denture bearing tissues. The dentist has an important role in the early detection of oral neoplasia, particularly carcinoma. Palpation of the alveolar ridges will determine their consistency and elicit the presence of painful areas. Denture construction should be delayed if pathology is present until such time as the oral tissues are returned to an appropriate healthy state.

The patient's dentures should be inspected first out of the mouth for cleanliness, general shape, tooth position and occlusal relationships and tooth wear. They can then be examined individually intraorally for fit, border extension, tooth position in relation to the tongue, cheeks and lips and aesthetics before making a general assessment of stability and retention. With both dentures in place, horizontal and vertical occlusal relationships and freeway space can be determined. This examination will identify design features

that can either be reproduced in the new dentures or be modified to create improvements.

Other investigations that may be necessary include radiographs that may reveal the presence of retained roots, buried teeth and other rarer pathology such as cysts, blood screening for deficiency states and smears or culture to confirm the presence of *Candida albicans*.

## Pre-prosthetic preparation of the mouth

### Extractions

Retained root fragments are the most common radiographic finding but, as with unerupted teeth, their removal should not be automatic. Surgical removal can involve the loss of a great deal of bone, which may already be in short supply, and could result in a reduction of the useful denture bearing foundation. Removal of roots or teeth should normally therefore be limited to those that are:

- Incompletely covered by bone
- Associated with periapical infection
- Showing signs of cystic change around the crown
- Associated with pain or discomfort

### Modifications to the alveolar ridge

The success of complete dentures may be improved by surgical modification to the alveolar ridge. The procedures that might be used are:

- Reduction of bulbous maxillary tuberosity
- Smoothing of irregular bony prominences
- Removal of flabby ridge
- Ridge augmentation
- Implants

## Treatment plan and prognosis

Having considered all the available information it may well be that the dentist will consider that he cannot improve upon the existing dentures. Also, if it has not been possible to determine the cause of a complaint, it is unwise to offer to make new dentures since faults (if they exist) may be perpetuated and the chances of success reduced. In either case, consideration should be given to referring the patient to a specialist. Certainly, in these circumstances, the first option on the treatment plan could be to explain matters carefully to the patient with suitable reassurance, but to offer no treatment.

Other treatments, depending on the clinical findings, could include:

- Relining/rebasing or other adjustments to an existing denture
- Construction of new dentures using either a conventional or a duplication technique

The prognosis for successful treatment is dependent on a number of factors including the patient's age, adaptability, demeanour, previous denture experience and the anatomy of the mouth.

### Preliminary impressions

Preliminary impressions can be taken using either metal stock trays or plastic disposable trays. A high viscosity, irreversible hydrocolloid (alginate) or impression compound is the material of choice.

### Coverage

Each impression should cover the entire denture-bearing area and should achieve the closest possible contact with the mucosa.

### Extension

The upper impression should extend to the functional depth of the labial and buccal sulci, including the tuberosities and hamular notches, and posteriorly to the junction of the hard and soft palate. The lower should extend to the functional depth of the lingual, labial and buccal sulci and cover the retromolar pads posteriorly. Only limited accuracy is needed at this stage since this will be an essential component of the final impression.

### Final impressions

#### Special trays

Special trays are required to ensure that the final (secondary or working) impressions can be achieved with accuracy of detail and borders moulded to the functional width and depth of the sulci. Stock trays are manufactured to average sizes and therefore are likely to be less than ideal for any individual. Although modification of stock trays is possible, the resultant impression is still unlikely to be extended correctly.

Self-curing acrylic is most commonly used for special tray construction. It has the advantages of being relatively inexpensive, simple to shape and is rigid in modest thickness. The upper tray should have a small handle placed in the midline of the anterior region, sloping forwards at an angle of 45°. This configuration avoids interference with the lip. On the lower,

the handle is vertical and two finger rests are placed, one in each of the second premolar regions. This enables the index fingers to support the tray without interfering with the borders of the impression.

Special trays can be divided into two types, close-fitting or spaced.

#### Close fitting

As the term implies, no spacing is used. Zinc oxide–eugenol paste is usually the material of choice in this type of tray, although other materials such as silicone perfecting pastes may be used. These materials are accurate in thin film but require adequate support, especially at the borders. Correct tray extension is therefore important and can best be achieved by checking that the borders are slightly short (1–2 mm) of the functional depth of the sulci and then using greenstick tracing compound (or other suitable material) to establish the optimum extension. This technique will define not only the depth of the sulcus but also its width. This combination can be used for upper and lower impressions provided there are no opposing bony undercuts.

It has the advantage that the materials are stable when set and less susceptible to distortion than alginate. No adhesive is necessary for zinc oxide–eugenol but the tray must be clean and dry.

#### Spaced

Alginate and plaster of Paris impressions require spaced trays. The spacers ensure an even thickness of the impression material for maximum accuracy. Alginate is specifically indicated when opposing substantial undercuts exist that could prevent the withdrawal of a close-fitting tray and a non-elastic material.

The tray can be constructed with 'built-in' stops, that contact the mucosa, or greenstick tracing compound can be added at the chairside. This should be completed before checking the border extension since the stops will effectively lift the tray away from the tissues and it may then appear underextended.

The tray borders should only extend to within 1–2 mm of the full depth of the sulcus to leave room for the impression material to flow around them and fill the remaining space. This avoids the common error found with alginate impressions of displacing the tissues and thus overextension.

Adhesive specific to alginate is more efficient than depending solely on holes drilled in the trays for retention. No adhesive is required for plaster impressions but the tray must be clean and dry.

### Objectives of final impressions

The objectives of the final impression are to define the support area for the denture to achieve optimum retention and stability.

### The flabby upper ridge

The combination of a complete upper denture opposing natural lower anterior teeth may result in the destruction of the maxillary alveolar ridge opposite the natural teeth and its replacement with fibrous tissue. Conventional impression techniques will tend to displace this type of ridge which needs to be recorded in its 'rest' position. To minimise displacement a low viscosity alginate or plaster of Paris can be used. An alternative is to take a two-stage impression using a zinc oxide–eugenol paste in a close-fitting tray that covers only the firm part of the ridge and then filling in the anterior region with a fluid mix of plaster of Paris.

### Jaw relationships

Jaw relationships are recorded using occlusal rims; these consist of a base and a rim. A variety of materials may be used for constructing the bases, but a rigid material such as shellac or acrylic is preferred, to avoid distortion. Rims are invariably made of wax, either performed or fashioned from sheets.

### Objectives of occlusal rims

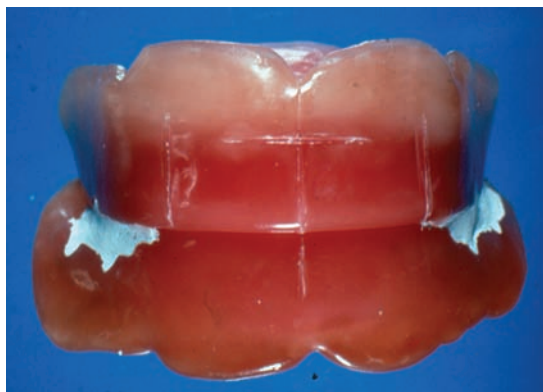Occlusal rims are used to transfer morphological information about the eventual polished surfaces and occlusal surfaces of the dentures from the patient to the laboratory, to enable the technician to proceed to the wax trial denture stage. In essence, they provide the technician with details of precisely where in relation to the denture-bearing areas, the artificial teeth and supporting material should be located. Occlusal rims should record the following information:

- Aesthetics and arch form
- Jaw relationships

#### *Aesthetics and arch form*

The upper rim should be adjusted to the required incisal level with the appropriate lip support. This depends on the length of the lip and the age of the patient and although the average visibilities of the central incisors to the upper lip line (at rest and without smiling) are often quoted as:

- *Young person:* 2 mm below lip
- *Middle age:* 1–1.5 mm below lip
- *Old age:* 0–2 mm above lip



**Fig. 26.3** Occlusal registration for complete dentures. The upper rim shows the registration of the occlusal plane, the intercanine distance, incisal length and tip position and midline. The rims are sealed in centric relation by ZOE paste.

There can be considerable individual variation and these measurements should therefore only be used as a guide.

The labial surfaces of the upper anterior teeth give support to the upper lip and provide facial contour. Frequently, the artificial incisors may be incorrectly sited in a more lingual position than their natural counterparts. The incisive papilla is an important landmark that can be used as a guide when trimming the labial face of the rim. Studies have shown that the incisal edges of the upper central incisor teeth lie approximately 8–10 mm anterior to the centre of the incisive papilla when the dental base relationship is class I. This structure is affected very little by resorption and remains fairly constant in position.

The upper rim should be trimmed parallel to the interpupillary line. The ala-tragal line (passing through the tragus of the ear near the external auditory meatus and the ala at the base of the nose) can be used as a guide in the antero–posterior plane. The centre line is marked on the labial face of the rim; this usually corresponds with the centre of the philtrum (Fig. 26.3).

Correct arch form is achieved by trimming the buccal and palatal surfaces so that the rim lies within the neutral zone, i.e. it lies between the opposing forces of the lips/cheeks and tongue which ensures stability. The tongue should not be cramped and therefore the lower rim should be trimmed from the lingual aspect until the tongue can lie in its normal resting position without dislodging the rim.

### Registration of jaw relationships

The objective is to record the jaw relationship at the chosen occlusal vertical dimension with the mandible in its most superior, posterior position (centric jaw relation/centric relation, Chapter 8). With complete dentures centric occlusion is constructed to be coincident with centric relation.

The height of the lower occlusal rim must be adjusted so that, with the patient in the upright position and the mandible at rest, there is a space of approximately 3 mm between the rims. This separation is called the *freeway space* (interocclusal clearance). This is achieved by assessing the rest vertical dimension with the patient sitting upright with the head supported so that the tissues are in their normal relationships. Direct measurement is usually made with either a Willis gauge or marker dots (on the skin) and dividers. The weight of the lower denture (or occlusal rim) can affect the rest position of the mandible, and the lower rim should therefore be in situ during the assessment. The occlusal vertical dimension is then assessed with the two rims in contact and wax removed from the height of the lower until there is sufficient freeway space.

In the elderly it is usually wiser to accept a slightly larger than average freeway space, especially if old dentures with a reduced occlusal vertical dimension, resulting from a combination of alveolar resorption and tooth wear, have been worn for many years.

When the rims have been adjusted to their final shape and size, *centric jaw relation* can be recorded. This can be achieved using a variety of techniques but the objective is to ensure that the rims contact simultaneously on both sides and therefore that there is even pressure. This can be ensured by removing 1–1.5 mm of wax from the anterior and posterior parts of the lower rim leaving pillars of wax in the premolar areas to maintain the occlusal vertical dimension.

The patient is manipulated into the retruded arc of closure with both occlusal rims in the mouth. Locating lines can be scored through both rims in the premolar areas to serve as a guide. V-shaped notches are cut into the upper rim in the molar regions and it is then returned to the mouth. Mounds of a recording medium, such as plaster of Paris (Gypsogum), softened wax or an occlusal registration paste, are placed on the lower rim, which is then placed in the mouth. The patient is guided again into the retruded arc so that the rims contact evenly and the mandible is supported whilst the material sets. Both rims can then be removed from the mouth while sealed together (Fig. 26.3).

The guidelines are checked to ensure that they correspond, and finally sticky wax is run over the rims and recording medium to reinforce the areas prior to despatch to the laboratory for the fabrication of trial dentures.

### Choice of teeth

The prescription to the technician should include the mould size and shade, together with the make and material to be used for the anterior and posterior teeth. Anatomical or non-anatomical (cusplless) posterior teeth should be considered with non-anatomical usually being reserved for those with:

- Atrophic alveolar ridges
- The elderly
- Difficulty in consistently returning to the centric jaw relation (e.g. Parkinsonism)
- Existing dentures with very worn teeth that have permitted unrestricted jaw movements

The size, shape and arrangement of anterior teeth have a significant influence on facial appearance and the psychological importance of the face and teeth cannot be over exaggerated. The choice of tooth mould is difficult when no natural teeth or pre-extraction records are available. There is little evidence to support the much-publicised theories of matching tooth mould to face form or that females have rounded teeth and males square, rugged teeth. In general, the size and mould of the artificial teeth should be chosen to fill the space available in the inter-canine region of the upper occlusal rim.

Individuals often request small, light coloured teeth arranged symmetrically to create a youthful appearance but this can result in a typical ‘denture wearers’ look’ not reflecting their biological age. There is, however, much that can be done to achieve a natural appearance including setting the teeth irregularly and using darker shades to more appropriately match the patient’s age.

### Articulation

In the laboratory, the type of articulator appropriate to the chosen posterior teeth should be used. An average condylar path (average movement) or adjustable articulator is necessary for setting up cusped teeth to ensure a balanced articulation. This type of articulator simulates protrusive and lateral movements of the jaw and working and balancing side contacts can therefore be assessed.



A simple hinge articulator should only be used for setting up cusplless teeth using either metal templates of a sphero-ellipsoidal nature (Boyles plates) or the teeth set to a flat occlusal plane with posterior balancing ramps to maintain a three point contact rather than full balanced articulation.

### Trial dentures

The wax try-in denture should be returned to the clinic together with the articulator. This allows the clinician to assess the dentures on the articulator prior to examining them in the mouth. The assessment on the articulator should include tooth position, arch shape, extension of the wax work into the sulci and across the retromolar pads and the posterior aspect of the palate. It should also include the occlusion and the general standard of the wax contouring and surface finish.

The objective of the intraoral inspection is to check the information recorded on the occlusal rims and to correct any errors before processing the dentures. The wax try-ins should therefore be checked for retention, ensuring that maximum coverage has been achieved, and that the borders are suitably extended. The jaw relationships can then be assessed first in the horizontal plane and then the vertical dimension. With the patient sitting upright, the head supported and the mandible in the retruded position, the occlusion should be even and simultaneous without interference or deviation.

If the occlusion is obviously incorrect then, following an assessment of the occlusal vertical dimension and freeway space, the lower posterior teeth should be removed and the wax rim re-established prior to a new occlusal registration.

When the dentist is satisfied with all aspects of the try-in the patient should inspect the trial dentures in front of a mirror. It may be helpful if the patient's partner also takes part in this exercise to ensure agreement on the appearance of the teeth.

Finally the extension of the posterior border of the upper trial base is checked. This should normally be placed at the junction of the moving tissues of the soft palate and the fixed tissues anteriorly and should extend laterally over the hamular notches. The Cupid's bow shape gives an effective seal and is achieved by carving into the surface of the working model using, for example, a Lecron carver. The shape is carved deeper at the posterior edge with a gradual taper anteriorly to account for the reduced thickness of the submucosa. This carving

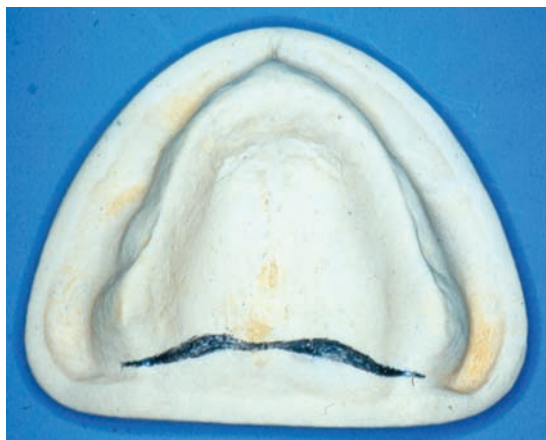

Fig. 26.4 Post dam outlined on model.

can be performed after the patient has left the surgery (Fig. 26.4).

### Processing

The procedures used to flask, pack and process heat-cured acrylic can result in dimensional changes and are commonly known as the *laboratory processing errors*. These can cause occlusal disharmony and an increase in the occlusal vertical dimension which will need to be eliminated at the fitting stage. The most likely causes are:

- Dimensional change of the wax during flasking
- Excessive packing pressure resulting in the teeth being forced into the plaster
- Incorrect alignment or badly fitting sections of the two halves of the metal flask
- Excessive flash either because the acrylic resin dough was too rubbery when packed or insufficient packing pressure was used
- Thermal and polymerising changes in the acrylic resin

If the dentures have been processed using the split cast technique they can be remounted on the original articulator. Usually the incisal guidance pin will not be in contact with the incisal guidance table and equilibration of the artificial teeth will be necessary. This involves first correcting the centric occlusion at the defined occlusal vertical dimension and then developing balanced articulation.

### Insertion of the dentures

Prior to inserting the processed dentures they should be inspected to ensure that the fitting (impression)

surfaces are free of imperfections, such as acrylic pearls or sharp ridges. If present, these should be trimmed and smoothed. Excessive, opposing undercuts should have been assessed at an earlier stage and, if appropriate, blocked out prior to processing but it may be necessary to remove minor undercuts to allow the dentures to be inserted.

The dentures should be assessed individually in the mouth for fit, stability and comfort before examining them in combination. If there are signs of discomfort, pressure disclosing pastes in spray form can be used to determine local areas of pressure that can then be trimmed and smoothed accordingly.

On closure the teeth should meet evenly and simultaneously without interference or lateral deviation. Minor adjustments to the occlusion can be performed at the chairside using thin articulating paper to mark the teeth and appropriately sized burs or stones. The aim should be for a positive, even occlusion with evidence of some lateral and protrusive movement without interference. If a more major occlusal error is evident, this should be corrected using laboratory facilities.

### Check record

A thin layer of warmed, toughened wax is applied to the lower posterior teeth and the mandible closed in the retruded relationship ensuring that closure of the mandible is stopped before tooth contact occurs to prevent premature contact and lateral or protrusive slide. This pre-centric record allows the technician to remount the dentures on the articulator and to carry out the necessary modifications to the occlusion.

When satisfied with all aspects of the dentures the patient is given information and guidance on wearing dentures and instructions on keeping them clean. Follow-up visits are made, as necessary, to ensure that the new dentures are comfortable and successful.

## Duplication Technique (Copy Dentures)

The duplication technique can be used to construct new complete (or partial) dentures if suitable existing dentures are available. The dentures are duplicated (copied) and these duplicates then form the framework for the new set. A variety of techniques is available but all have the same objective with a number of the techniques being very similar, only differing in the materials used.

The existing dentures need to have been worn successfully to warrant duplication although (rarely) the 'best of a bad bunch' can be chosen for a patient

who has had many dentures constructed by a variety of dentists in order to make controlled modifications without damaging the set that they prefer. The common indications for duplicating dentures are:

- The elderly who may have a reduced adaptive capacity that restricts the use of conventional construction techniques
- Others with reduced adaptive capacity (e.g. stroke and Parkinsonism patients)
- Immediate dentures – to reproduce the original tooth position
- Dissatisfied patients – in order to modify the most acceptable dentures
- Special features – to copy the shape of an existing denture that may have unusual design features such as flange plumping in cases of seventh nerve facial palsy
- Spare dentures – for those who require an extra set to avoid embarrassment

Advantages of the duplication technique include:

- Exact reproduction of tooth position and contour of the polished surfaces
- Ability to incorporate controlled modifications
- The minimisation of problems of adaptation
- Clinical attendances are reduced

The most commonly used techniques can be performed at the chairside although laboratory methods are available. The objective of them all is to take impressions of the existing dentures in order to be able to pour duplicates in self-curing acrylic which are then used to record the impressions of the mouth and jaw relationships. The duplicates (copies) are obtained at the chairside by taking impressions of both surfaces of each denture with alginate or silicone putty either in pairs of disposable plastic trays or in a plastic soap dish which has had a window cut in the side to allow space for the sprues. The sprues, which are attached to the heels of the dentures, permit the duplicates to be poured using a fluid mix of self-curing acrylic. This is usually carried out in the laboratory under an extraction hood, for health and safety reasons.

The acrylic duplicates can be modified to correct under/over extension and used as 'special trays' in order to obtain final impressions and also to record the jaw relationships by placing a suitable registration material between the teeth. The contours of the polished surfaces should be carefully guarded, unless there is reason for change, in order to preserve the overall shape of the final dentures. It should be appreciated that the self-cure duplicates are only used as templates for the processing of the heat-cured

acrylic dentures and are not incorporated into the final prostheses.

## Immediate Dentures

An immediate denture is one that is constructed prior to the extraction of the natural teeth and inserted into the mouth immediately after their removal.

The benefits to the patients are that they are never without teeth and therefore the soft tissue profile is maintained; the dentures assist mastication and hence nutrition; adaptation is enhanced and the development of abnormal muscle behaviour is avoided by maintaining normal function. Benefits to the dentist include the use of the existing dentition for recording jaw relationships and for choosing shade and mould of artificial teeth; tooth position can be reproduced or controlled modifications made as desired.

Disadvantages of immediate dentures include the extra clinical visits that are necessary for after care and eventual replacement of the dentures. It is not possible to check the aesthetics of the teeth to be replaced as there can be no try-in stage. If it is not possible to extract the teeth without resorting to surgical techniques cast trimming to simulate the residual ridge may be unsatisfactory.

Due to the improvements in adult oral health it is now relatively uncommon to have to provide immediate dentures replacing most of the natural teeth. However, depending on the number of teeth remaining various options for tooth replacement should be considered:

- 1 Extract posterior teeth, allow the ridges to heal for at least 3 months and construct immediate dentures to replace the anterior teeth. The advantages of this are that the healed posterior ridges extend the life of the prostheses and it is an economic procedure requiring the minimum number of patient visits – it may, however, allow the possibility of lateral tongue spread
- 2 The first procedure can be modified to either extract the posterior teeth and allow the ridges to heal, construct partial dentures and then add the remaining teeth to these dentures as an immediate procedure. Alternatively, extract the posterior teeth and fit immediate partial dentures and then add the remaining teeth to these dentures as an immediate procedure

Both modifications attempt to bring about a successful transition to complete dentures; however,

the number of extra visits may be unrealistic. Also, a high level of motivation is required to wear simple acrylic partial dentures replacing only posterior teeth.

- 3 Extract all the remaining anterior and posterior teeth and fit immediate dentures. This has the advantage of completing the extractions at one operation which may be important, for example, prior to cardiac surgery but can result in rapid loss of fit of the dentures caused by widespread alveolar resorption which necessitates frequent maintenance visits

Whenever practicable, flanged immediate dentures should be used since they give superior retention, increase the life of the dentures, add strength to the denture base, allow for repositioning of the artificial teeth, protect extraction sockets and aid healing. They can also be used when marked periodontal pocketing is present which would preclude the use of the open-face (gum-fitted) design and they support the use of temporary lining materials which is helpful during the maintenance phase.

## Principles of Overdentures

The term overdenture describes a prosthesis that derives support from one or more abutment teeth or roots by completely enclosing them beneath its fitting surface. Complete overdentures are more common than partial overdentures.

### Rationale for overdentures

The maintenance of alveolar bone is probably the strongest argument for the retention of teeth or roots as overdenture abutments:

- The mandibular ridge is particularly susceptible to post-extraction change; maxillary and mandibular alveolar resorption rates are approximately in the ratio 1:4
- Clinical experience confirms that alveolar bone is maintained whilst healthy teeth or roots remain
- Retention of a number of abutments maintains a positive ridge form with a greater height and volume of bone. The denture is therefore more stable and retention should also be improved

The success or failure of a prosthesis is dependent upon the integration of sensory feedback and motor response and the masticatory system relies on

feedback from receptors in temporomandibular joints, ligaments, muscles, mucosa and periodontal tissues. The loss of teeth decreases the level of proprioceptive information.

Sensory feedback can be considered under two headings that relate to research studies:

- *Tactile sensitivity discrimination* (the discrimination of differences in thickness of objects placed between the teeth). Little difference has been reported between natural teeth, conventional complete dentures and overdentures; it is possible that muscle spindles play the major role
- *Minimal load thresholds* (the discrimination of varying levels of force). Overdentures give improved discriminatory ability at both higher and lower biting force levels. This may prevent excessive loads being applied and hence maintain loads directed to the alveolar bone within physiological limits

There may be some psychological benefit gained from an overdenture. By retaining some of the teeth it may prevent the feeling of total loss of natural teeth and perhaps make eventual transition to conventional complete dentures more acceptable. Masticatory performance is enhanced since the overdenture wearer has a functional advantage over those with conventional dentures. There is scientific evidence that overdentures allow the food to be chewed more effectively.

### Indications for overdentures

- Complete denture opposing natural teeth – prevents overloading of mucosa caused by high masticatory forces and retards rate of alveolar resorption thus enhancing long-term success of the prosthesis
- Cleft palate and surgical defects – if the defect is extensive, it may be impossible to provide a satisfactory conventional denture if teeth are lost
- Extreme wear of natural teeth – see Chapter 27
- Hypodontia – often a substantial number of permanent teeth absent
- Poor prognosis for conventional complete dentures – degree of bone loss in edentulous areas and unfavourable muscle attachments may indicate potential problems
- Doubtful partial denture abutment – overerupted or periodontally involved teeth may not be satisfactory as conventional partial denture abutments

### Patient selection

Overdentures should be considered whenever the loss of teeth is anticipated. There are few general health contraindications except for severe debilitating illness, mental handicap, history of bacterial endocarditis and some candidates for cardiac surgery. Youth or old age is not a contraindication in itself and overdentures should be constructed when clinically indicated. It is important to inform potential patients of the number of visits and time required since this will be greater than, for example, for a clearance and conventional dentures. The ability to attain and maintain a high standard of oral hygiene is essential.

### Abutment selection

The choice of abutment is dictated by the number and location of remaining teeth. Bi-lateral abutments symmetrically located are ideal. Canines are the most often used teeth with premolars the next favourite (the second premolar being preferred in the maxilla since it is commonly single rooted). Maxillary incisors are satisfactory but mandibular incisors are the least acceptable and the use of molars may be limited by endodontic considerations. Adjacent abutments are more difficult to clean and can make the maintenance of gingival health a problem.

### Dental examination

The clinical examination should include charting of caries and defective restorations, assessment of gingival condition, periodontal pocket depth and tooth mobility and periapical radiographic survey of possible abutments and study models.

A high level of caries activity is undesirable since there is a possibility of recurrence in unprotected abutment teeth or adjacent to margins of copings. Root caries precludes the use of a tooth.

Teeth with a less than ideal periodontal condition may have to be accepted. However, the abutment should have minimal mobility and adequate bone support (half the root length surrounded by bone). An improved crown/root ratio, achieved by reduction of the clinical crown in the doming procedure, will enhance likely success. If positive retention, in the form of root face attachments, is envisaged the abutment tooth will be subjected to considerably greater forces. Substantial bone support for the root is therefore essential. Active gingival and periodontal disease should be eliminated prior to further treatment.

When considering endodontic therapy, radiographic evaluation is essential although root canal therapy may be unnecessary in cases of severe wear when the root canal may be obliterated by secondary dentine. Single-rooted teeth are preferred for ease of root filling and the possible use of the canal for post retention if copings on the abutments are envisaged.

### Treatment plan

There are several methods of progressing to complete overdentures.

#### Immediate complete overdentures

The treatment sequence might include periodontal therapy and endodontics prior to preliminary and final impressions and recording the jaw relationship.

At the try-in of the trial set-up, a decision is taken on the position of the artificial teeth to replace those being extracted or reduced as abutments, and on the provision of a flange. Similar criteria are used as for the normal immediate denture procedure, i.e. the appearance of the natural teeth to be copied or is the position of the artificial teeth relative to their natural predecessors to be altered to modify the aesthetics? Although desirable, it may not be possible to use a full flange because of bony undercuts adjacent to the abutments.

On completion of the denture the chosen teeth are prepared as overdenture abutments to produce a smooth dome shape with the highest point approximately 2 mm above gingival level. A glass ionomer restoration is placed in the entrance to the root canal. Other teeth are then extracted and the denture fitted.

At the first review visit, one day after the extractions, the root faces and restorations are polished. The overdenture is adapted to the abutments by adding self-curing acrylic to the depressions in the denture over the root faces. Excess acrylic is allowed to escape via small vent holes drilled through the denture base whilst the denture is retained in position by light occlusal pressure.

Further review appointments will be necessary during the socket healing and ridge remodelling period. After approximately 6 months the root face can be assessed for possible coverage with copings.

#### Conversion of existing partial denture to complete overdenture

Existing partial dentures can be utilised and converted to complete overdentures using either a laboratory based technique or a chairside method.

#### Laboratory method

- 1 Dome-shaped preparation of endodontically treated abutment teeth
- 2 Impression with partial denture in situ (plus impression of other arch and occlusal record)
- 3 In the laboratory – artificial teeth positioned over domed root faces and flange added
- 4 Converted dentures fitted

This method has the advantage that the converted denture has been made in the laboratory and the disadvantage that the patient will be without a denture during construction.

#### Chairside method

- 1 Endodontic treatment of abutment teeth
- 2 Impression with denture in situ (leave denture in impression)
- 3 Dome-shaped preparation of abutment teeth
- 4 Tooth coloured self-curing acrylic is placed in the abutment teeth indentations of the impression and the impression (with the denture still included) is positioned carefully in the mouth
- 5 When polymerisation is complete, the flange is added with hard chairside reline material

This method has the advantage that the patient is not without the denture but has the disadvantages that a lengthy appointment is necessary and the additions may be weaker and more prone to fracture.

### Treatment of abutment teeth

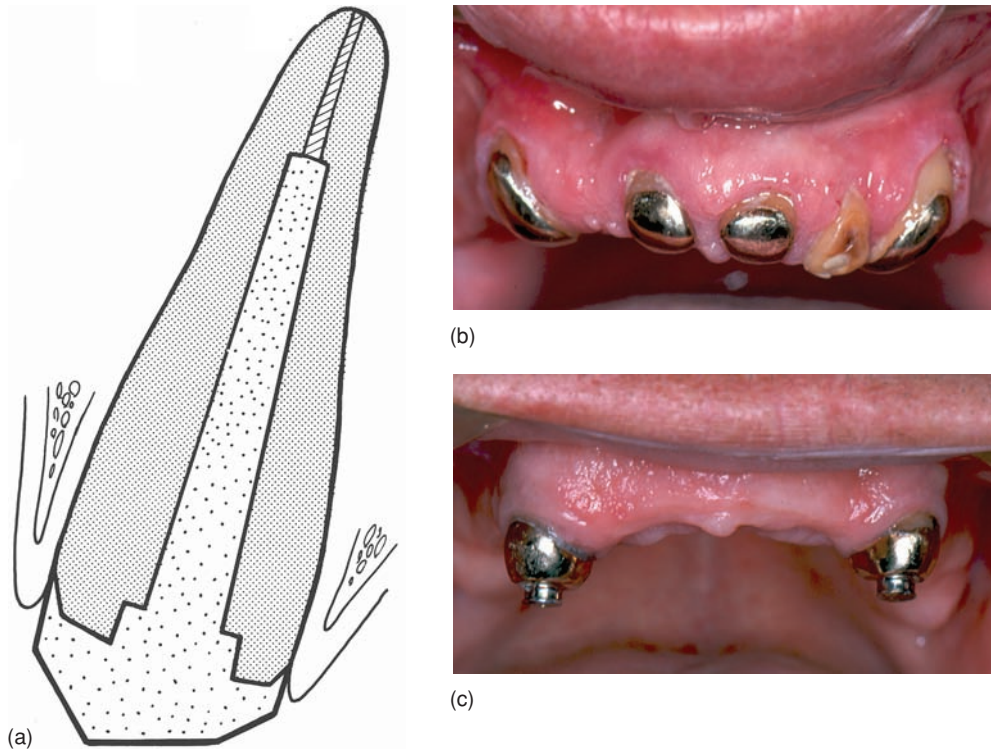
There are several ways in which abutment teeth can be used in association with overdentures:

- Domed with access sealed with glass ionomer cement
- Gold coping on root face with post
- Gold thimble on vital tooth
- Attachment fitted to the coping

The selection may often be a personal preference but the essential difference between the systems is the retention of the denture and the extent to which lateral forces are transmitted to the abutment teeth. The dome transmits the least force whilst the attachment transmits the most.

#### Domed root face

This is the simplest method. The teeth will normally be root filled and the access sealed with glass ionomer cement to provide a fluoride reservoir to assist the prevention of recurrent caries. The level of the dome in relation to the gingival tissue may vary according



**Fig. 26.5** Overdenture abutments: (a) Diagram of root face coping and post; (b) clinical case with gold copings on 31113 and glass ionomer cement in 12; (c) stud attachments on 313.

to the restorative state of the tooth. Whilst the ideal level is 2 mm above the soft tissue, pre-existing deep restorations may cause the removal of more tissue. In any event the root face should not be sub-gingival. If this occurs, a coping should be used.

### Gold copings

#### *Dome shape*

This will provide some protection to the root face from recurrent caries together with some additional resistance to lateral displacement of the denture. It is the most common and usually uses the root canal for retention on a cast post; therefore, endodontic treatment is necessary. The profile of the coping may be flat or raised as a stud (Fig. 26.5) and deficiencies caused by previous caries/restorations can be occluded. The placement of the copings should be delayed, if possible, for approximately 6 months after the overdenture is fitted to allow the gingivae to reach a realistic level.

#### *Thimble shape*

This is designed to protect the dentine overlying a vital pulp. It offers more retention and stability to the denture but greater stress is placed on the root and

the extra height creates a less favourable crown/root ratio. Because of its size it intrudes further into the denture base.

### Attachments

These increase the retention of the denture greatly but increased stresses are transmitted on insertion and removal of denture and during function. Therefore the abutment roots require excellent periodontal support. Good maintenance is essential and time consuming, and the laboratory costs are greatly increased over simple castings.

They are very useful when the denture foundation is unfavourable as in a cleft palate or a flat lower ridge or when displacing forces may be high, e.g. a complete overdenture opposed by natural teeth. In patients who cannot tolerate a conventional denture palate, attachments can overcome the loss of retention where palatal coverage has to be reduced.

There are three basic types of attachments:

- Stud attachments
- Bar attachments
- Magnets

The male portion of the *stud attachment* is usually on the root and the female portion in the denture (Fig. 26.5c). The space required is approximately midway between a dome shape and thimble coping; space is also required in the denture base to accommodate the female portion. Examples of this type are the Rothermann Eccentric, Dalla Bonna 604 and the Kurer Press Stud system.

The *bar attachment* consists of a rigid bar attached to abutment teeth and a sleeve in the overdenture. The bar splints the abutments and distributes stress between them. Substantial loads can, however, be generated with this system. Plaque control is difficult and maintenance of attachments complicated. The Dolder bar and Ackerman bar are examples of this type.

The *magnet* system involves a magnet being soldered to a root face coping and a corresponding ferromagnetic block being processed into the denture base.

### Clinical appraisal

Good oral hygiene is the single most important factor that influences the continued health of the supporting tissues. With inadequate oral hygiene wearing overdentures can cause:

- Periodontal damage – either gingival hypertrophy or retraction of the gingival tissue with loss of bony support. There is a specially high risk if attachments are used
- Caries of the root face

### Preventive measures and continuing care

Patients should be on a structured continuing care programme to provide regular inspection and maintenance of the denture and abutments.

Effective plaque control of the root faces is essential using a fluoride toothpaste. Topical fluoride gel may also be useful, both applied directly to the root face and into the depressions in the fitting surface of the denture that overly the abutments. The patient must also adopt an efficient denture cleansing programme using hypochlorite solution (see later section on ‘Keeping dentures clean’).

*Gingival recession* is a possible problem and this may indicate reshaping of the dome preparation and modifying the fit of the dentures using self-curing acrylic resin chairside reline material and carry out periodontal treatment as appropriate.

*Recurrent caries* of the root face may be removed thus modifying its shape or a gold coping might be provided.

*Alveolar resorption* occurs mainly distal to the abutments following which stability of the denture will deteriorate. This will require correction either with a conventional reline technique or with a chair-side reline material.

### Advice for New Denture Wearers

A patient receiving new dentures should be given guidance as to the difficulties that may be encountered and advice on a cleaning and maintenance regime. Since patients tend to forget verbal information given at the chairside, written instructions to take home and read at leisure are helpful. There are many denture-cleansing agents on the market but the following guidelines are suggested:

#### *Getting used to complete dentures*

*The best results from your new dentures can only be achieved with practice and patience. It may take several weeks for you to become fully accustomed to the dentures. Do not be discouraged by friends or relatives who tell you how easy it was for them.*

*To begin with, the dentures may cause an increase of saliva in your mouth. This should return to normal in a few days. Eat mainly soft foods for the first few days and don't take large bites.*

*Cut your food into small portions and try to chew with your back teeth on alternate sides. Some people with new dentures find that sucking boiled sweets helps them to get accustomed to the dentures.*

#### *When to wear your dentures*

*You may wear your dentures during the day and night for the first week to help you get used to them more quickly. From then on you should leave them out at night, in a container of water or recommended cleaning agent. Your mouth needs a rest if it is to remain healthy.*

#### *Keeping your dentures clean*

*Ensure that your dentures are kept really clean. Rinse them after each meal and brush all of the surfaces morning and night with a soft toothbrush and soap and water.*

*Use the commercially produced cleanser ‘Dentural’ regularly. Follow the instructions on the container carefully. If your denture has any metal components,*

*the 'dentural' will not cause any damage provided you use only the short (half-hour) cleaning period. Rinse your dentures well after using 'dentural'.*

***The comfort of your mouth***

*New dentures sometimes cause areas of soreness. These may be relieved by leaving the dentures out of*

*your mouth for 24 hours. If the trouble persists, an adjustment will be necessary. However, if it has been necessary to leave the dentures out, ensure that they are worn for 12 hours immediately prior to visiting the dentist for an adjustment. This will help in locating the exact cause of the trouble.*





# Section V

## Problems



# Chapter 27

## Tooth Surface Loss

The loss of enamel and dentine caused by means other than caries and trauma has become more significant as teeth are retained for longer and people's dietary habits change.

The aetiology is often complex as can be the treatment. Prevention of the condition by education and intervention by the dentist is important.

Tooth surface loss, also called *tooth wear*, refers to the interrelated effects of attrition, abrasion and erosion.

- Attrition is the loss of enamel and dentine resulting from tooth to tooth contact
- Abrasion involves an abrasive agent between or against the tooth surface
- Erosion involves a chemical agent

The principal causes or predisposing factors are:

- Developmental anomalies
- Malocclusion
- Posterior tooth loss
- Parafunctions and habits
- Restorative materials
- Diet
- Systemic disease
- Natural wear and tear

### Aetiology and Clinical Features

#### Developmental anomalies

Localised enamel hypoplasia is never a serious problem since isolated zones of surface loss will not usually disturb occlusal stability.

However, the more difficult conditions are those of *amelogenesis imperfecta* and *dentinogenesis imperfecta*. These are part of a range of pathology, including osteogenesis imperfecta, that are manifestations of disturbances in the formation of calcified tissues. These disturbances are genetic in origin and are often seen as familial traits.

In amelogenesis imperfecta, the enamel matrix formation is disturbed with normal calcification of what

does form. The extent of the disorder varies from localised areas of pitting, to a very thin shell of enamel. The enamel is hard but may be deposited in fine lamellations as well as in normal prismatic structure in other areas.

The teeth are poor aesthetically and vulnerable to caries and attrition in affected areas.

Dentinogenesis imperfecta (Fig. 27.1) is uncommon and is due to defective odontoblastic activity. The dentine is soft with the deeper layer having few tubules and incomplete calcification. Also, the pulp chamber becomes obliterated.

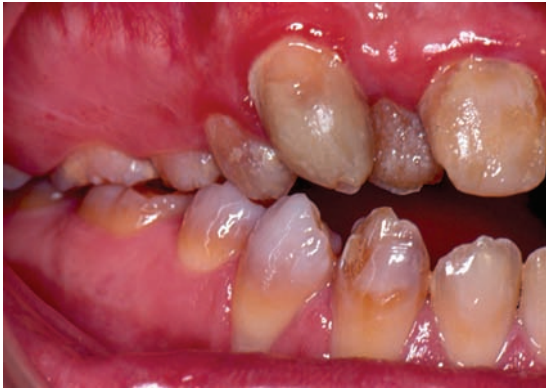Clinically, the weak bond of the enamel to the dentine results in enamel loss, even though the enamel itself is usually normal. The colour of the teeth is abnormal, being brownish and the roots may be stunted. Because of the obliteration of the root canals, apical infection may occur.

#### Malocclusion

Certain malocclusions, particularly involving the anterior teeth, may bring the teeth into abnormal functional contacts. Those that create the most problems are an edge-to-edge incisor relationship and an unfavourable Angle's Class II division 2 incisor relationship. The latter case may involve close apposition of the palatal surfaces and tips of the upper incisors with the labial surfaces of the lower incisors. Also, gingival trauma may result from the deep overbite. Surface loss can be dramatic (Fig. 27.2) if the malocclusion remains untreated.

#### Posterior tooth loss

If several posterior teeth are lost, mastication is likely to be effected on the remaining anterior teeth. These

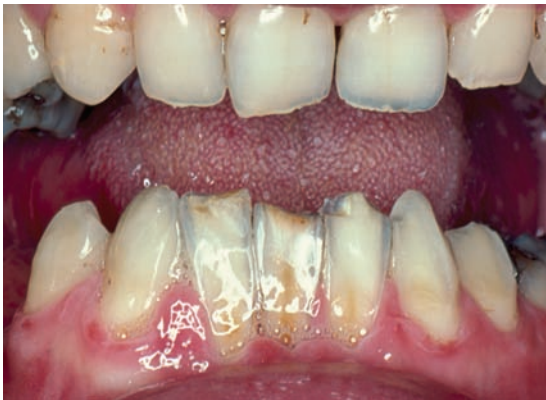

**Fig. 27.1** Dentinogenesis imperfecta.

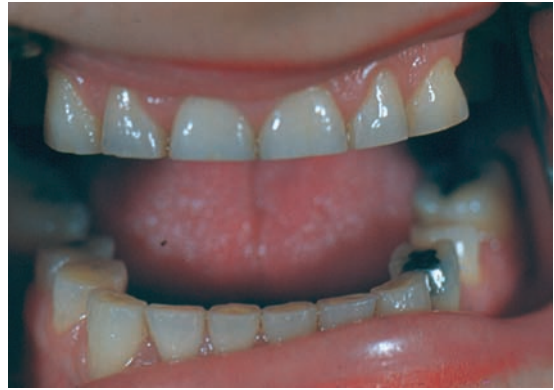teeth are not well suited to grinding movements and rapid surface loss can result. This type of problem is more common in geographic areas where the level of dental care and awareness has been inadequate, and is usually coupled with non-provision of, or refusal to wear, dentures.

Even with partial dentures present, there is a great tendency to use the natural teeth, and part of the education of the patient at the fitting stage of the dentures should be to stress the need to use them effectively.

Cases exhibit progressive loss of incisor and canine crown length and when this becomes unsightly the patient is prompted to seek treatment (see Fig. 18.5).



**Fig. 27.2** Severe surface loss and periodontal trauma caused by a long-standing Angle's Class II division 2 malocclusion. Management of such a case would require pre-restorative orthodontics.



**Fig. 27.3** The typical flat occlusal plane of a bruxist.

### Parafuncions and habits

Bruxism (Chapter 28) is the most dangerous parafunction, with enamel and dentine loss. Again, the incisor length loss is what prompts the request for treatment, but prevention, in the form of an occlusal splint, should be applied as soon as the surface loss is noted (Fig. 27.3).

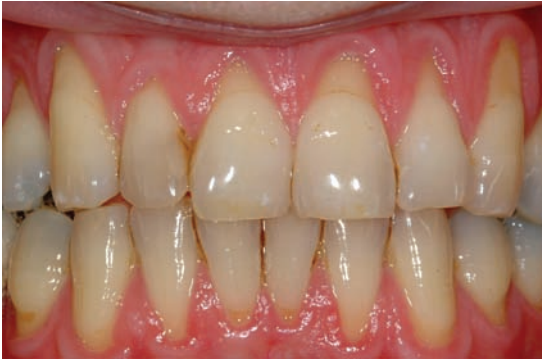The exposed dentine may be sensitive, but since the attrition is usually coupled with secondary dentine formation and the retreat of the pulp, it is more often symptomless. The obliteration of the root canals by secondary dentine can lead to apical infection and the use of apical radiographs in the diagnostic phase is important. Root canal therapy would be indicated before the canals become obstructed.

Habits, such as nail biting, pipe smoking, hair grip opening and so on, can cause abnormal wear patterns, particularly of an isolated nature.

*Tooth brush abrasion* may be caused by incorrect brushing technique, seen particularly at the cervical margin of the buccal surfaces of the left side in a right handed person (or vice versa). It is accompanied by gingival recession and loss of exposed cementum (Fig. 27.4). It has been proposed that the occlusion may cause cervical stresses leading to dentine fatigue and breakdown rather than brushing and this is referred to as *abfraction*.

### Restorative materials

Conventional large particle composites and unglazed dental ceramics can remove enamel quite successfully during normal function, with their effect greatly accelerated by parafunction. Again, correct treatment planning, or early intervention, is the best course.

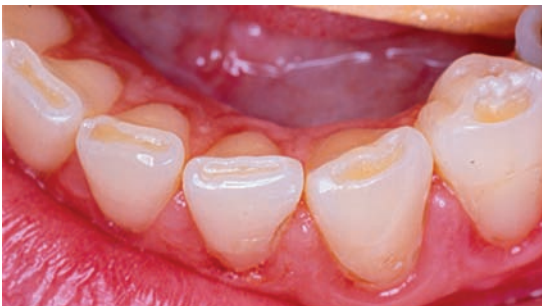

**Fig. 27.4** Tooth brush abrasion.

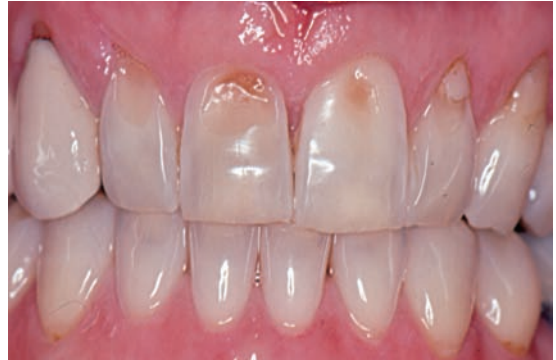Coarse particle composites should be avoided for large restorations. If a ceramic occlusal surface has been prescribed (in spite of the advice given in Chapter 14), this should be reglazed following adjustments, rather than 'polished'.

### Diet

High consumption of acidic food and drinks such as citrus fruits, cola, lemonade, alcopops and some 'sports drinks' removes surface enamel; even wine and tea are incriminated. Cola is a particular hazard as it contains phosphoric acid, citric acid and carbonic acid. The labial aspects are usually affected, unless drinking is via a straw, in which case the palatal aspects of the upper incisors may dissolve. The worst cases are 'diet freaks' who eat large amounts of citrus fruit and brush their teeth immediately afterwards. The acid removes the mineral and the brushing removes whatever matrix is left – thus accelerating the process. The dentine is less mineralised than the enamel and this is removed first leaving a saucerised



**Fig. 27.5** Saucerisation of the incisal edges is a sign of erosion.

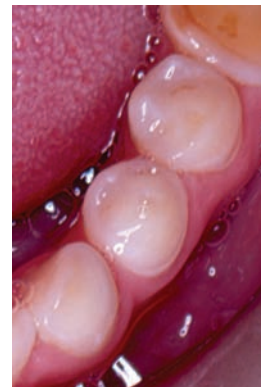

**Fig. 27.6** Labial erosion of the upper incisors and canines with exposure of dentine. The patient was obsessed with a fresh fruit diet and tooth brushing. There is loss of much enamel with absence of lamellae, with the dentine showing through and consequent sensitivity.

appearance (Fig. 27.5). Another modern habit is to sip cans of fruit drinks throughout the day; this simply drips acid continuously onto the tooth surface. As with carbohydrate intake and caries it is the frequency of exposure rather than the volume.

The surface enamel loses its lamellated appearance and will have a high amorphous gloss. Eventually, dentine will be exposed in the eroded areas, particularly bucco-cervically and occlusally. Because the erosion causes a more rapid enamel loss than that caused by attrition alone, secondary dentine does not form quickly enough to prevent sensitivity (Fig. 27.6).

Another diagnostic sign of acid erosion is 'lipping' at the cervical margin of the crown where enamel occlusally to the lip has been removed, whilst that below the lip has not (Fig. 27.7).



**Fig. 27.7** Erosion of the buccal surface showing lipping.

Prevention via dietary advice is the best approach, and patients could be advised to rinse with fresh water after eating fruit, rather than brushing. A reduction in intake of fruit and acidic drinks should also be advised and particular effort be made in advising parents about their childrens' diet.

### Systemic disease

Childhood diseases may interfere with the enamel mineralisation of developing teeth and these may erupt with bands or localised zones of hypomineralisation. These areas will be weak and, if in functional relationship with opposing teeth, will be lost fairly rapidly. The zones or bands will be chalky white and rough; they will be more prone to staining than the adjacent enamel.

In the adult, the most common systemic problem affecting the tooth surface is *gastric reflux*. Due to cardiac sphincter problems, or even very acidic indigestible meals, gastric secretions are forced up the oesophagus and into the mouth. These secretions are highly demineralising and the areas most commonly affected will be the palatal surfaces of the upper teeth. Occlusal surface loss also occurs leading to existing restorations being left above the level of the surrounding tooth.

This is a classic feature of erosion in the absence of occlusal forces, where the affected tooth surface has no occlusal contact.

Prolonged vomiting may also create the same picture, and is one hazard of pregnancy. In addition, the disorders of bulimia and anorexia nervosa are accompanied by vomiting.

### Natural wear and tear

Teeth are kept longer by a population of increasing average age. It is therefore inevitable that teeth simply wear out.

### Indications for Treatment

Cases with tooth surface loss will require restorative treatment if there is:

- Associated pathology, e.g. caries, apical infection
- Sensitivity
- Loss of occlusal stability and function
- Deterioration in aesthetics

### Principles of Treatment

Where there is a clear external aetiological agent, this should be eliminated prior to restorative work. Elimination of habits, dietary advice for acid erosion, medical referral for gastric reflux and occlusal splints for bruxism fall under this heading.

Provision of partial dentures to provide posterior support prior to the consideration of advanced restorations for worn anterior teeth is essential. A complicated treatment plan will fail if the patient will not wear the dentures!

The severe malocclusions mentioned above will require orthodontic correction or simply extractions. The correction of unfavourable relationships by crowns has limitations due to the position of the roots.

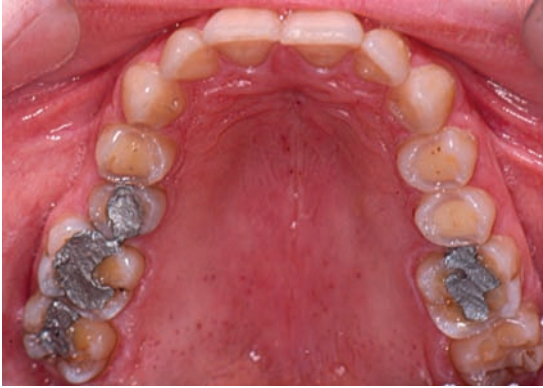Patients with progressing anterior surface loss, particularly male, may only be concerned that the condition does not worsen. Timely provision of partial dentures coupled with glass ionomer cement restoration of incisal edge 'saucers' may well be sufficient in many cases.

Application of desensitising agents for patients with dentine sensitivity of occlusal surfaces may not be successful. There seems to be a difference between the response of a relatively localised zone of cervical dentine and the larger area of occlusal exposed dentine. This is particularly true of acid erosion cases where the dentinal tubules will be opened by demineralisation.

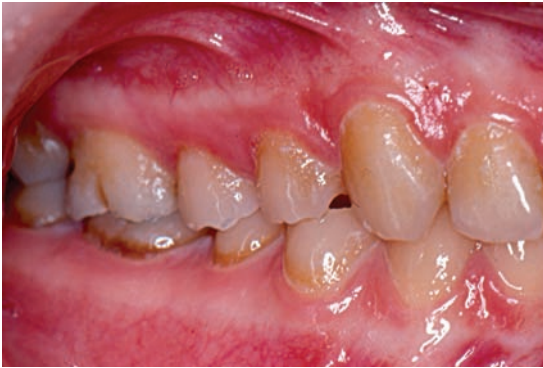Localised hypomineralised areas of enamel can be successfully restored with acid-etch-retained composite and larger areas with aesthetic problems will require veneers or crowns.

In relation to posterior teeth there has been a change in approach in recent years. Figure 27.8 shows the upper arch of a young adult with extensive disruption of the occlusion (Fig. 27.9). The mainstay of management for many years of such a case was multiple crowns accompanied by an increase in vertical dimension to accommodate them in the occlusion (Fig. 27.10).

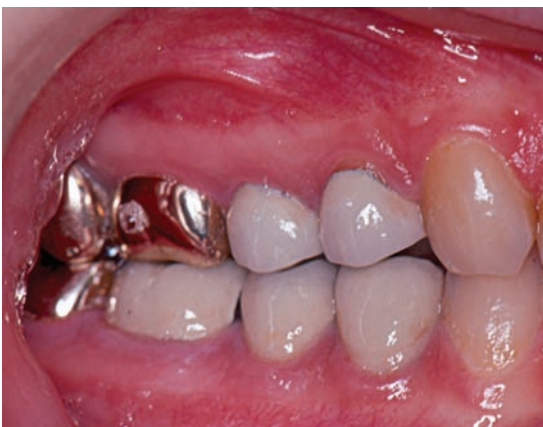This approach is technically demanding for both the dentist and the technician and requires the patient to be fastidious with oral hygiene and diet control. The long-term maintenance of patients with multiple crowns can be demanding with recurrent caries and pulp disease being risks. Furthermore, nothing lasts forever and the replacement of 10- or 12-year-old crowns can be more challenging and problematic than the original provision.



**Fig. 27.8** Posterior surface loss in a young adult. The incisors were the only teeth relatively unaffected.



**Fig. 27.9** The buccal occlusion of the case shown in Fig. 27.8.



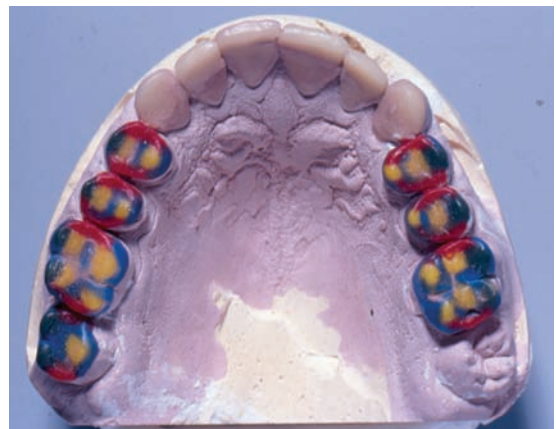**Fig. 27.10** The restoration of the case shown in Fig. 27.8. The vertical dimension was increased to accommodate the crowns because the surface loss had reduced the crown height and further tissue reduction would have been dangerous.

The provision of 28 crowns is also horrendously expensive!

The preferred treatment for many cases of posterior tooth surface loss is now the provision of acid etch retained composite 'onlays'. The composite will be retained by being attached to the 'halo' or lip of enamel that usually remains at the cervical region of the damaged teeth and this can be supplemented by dentine bonding agents. In comparison with multiple crowns, this treatment is relatively simple to perform and the composite can be easily repaired or replaced in the event of damage. The remaining tooth will not be usually compromised. The technique is well within the skills of a general dentist and specialist training is not needed. It is therefore very cost effective.

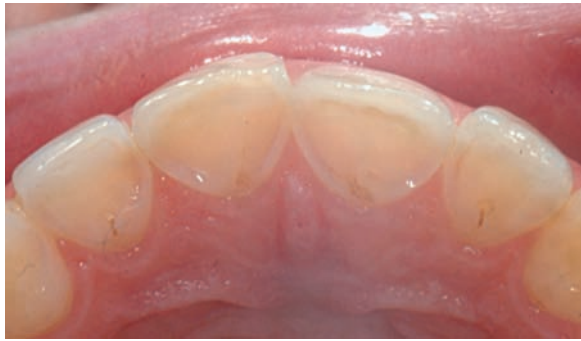The building of the composite can be done free-hand but more accuracy will be achieved by using an occlusal mould made from a pre-operative diagnostic waxing (Fig. 27.11). When the diagnostic waxing is complete, it should be duplicated into stone and a vacuum formed transparent mould made. This mould can be used to shape the composite occlusal surfaces and alternate teeth should be built up to ensure that separation of the contact areas is achieved.

The consequences for the occlusion are interesting. The posterior surface loss is usually accompanied by compensatory alveolar bone growth and this maintains face height, or occlusal vertical dimension, in spite of the wear. Restoration of the worn areas will intrude into the freeway space and it used to be considered that this needed to be planned in detail and

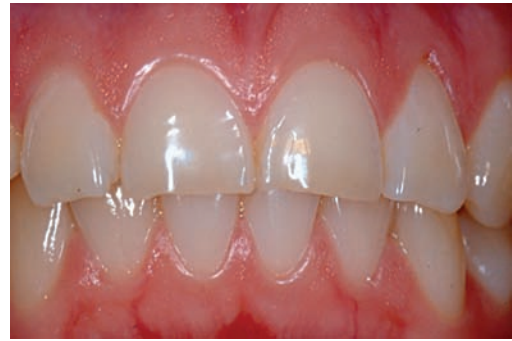

**Fig. 27.11** Diagnostic waxing for a wear case. The waxed model can be duplicated in stone and a thermoformed vinyl mould made to be a matrix for the composite additions.





(a)



(b)

**Fig. 27.12** Upper incisors with the surface loss caused by dietary erosion.

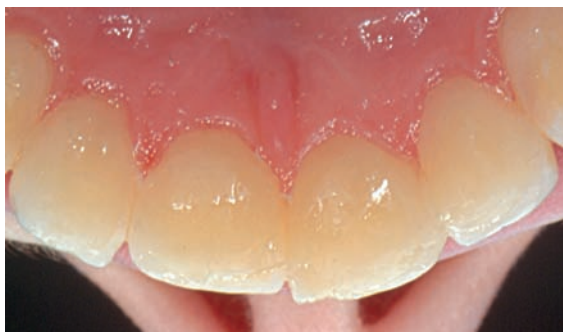the patient's tolerance of such intrusion be checked by means of an occlusal splint.

It is now recognised that worn teeth can be built up by several millimetres without causing disturbance to the neuromusculature and that subsequently there are changes in tooth position by intrusion and extrusion of teeth.

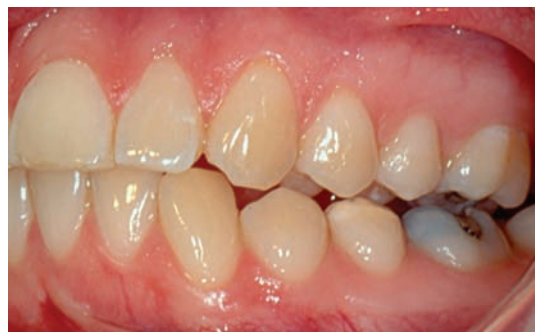These changes can be used in changing the occlusion prior to treatment and this technique was first reported by Dahl. Many versions of the principle can be applied to simple treatment. Figure 27.12 shows a case with both labial and palatal surface loss of the upper incisors caused by acid erosion. Restoration of these by crowns would require much removal of the remaining tooth tissue. However, the Dahl principle can be applied to increase the vertical dimension by the application of composite to the palatal surfaces of the incisors (Fig. 27.13), which leads to intrusion

of these teeth accompanied by extrusion (or over-eruption) of the posterior teeth (Fig. 27.14). By this method, space is created for restoration of the worn surfaces without destructive tooth preparation. (The same effects can be created by an occlusal splint with partial occlusal coverage.) The incisors were then restored by crowns but an alternative method which reduces the amount of tooth reduction is to place pairs of palatal and labial veneers, sandwiching the remaining tooth tissue between them.

It is more difficult to restore worn anterior teeth when posterior teeth have been lost. Here posterior occlusal stability needs to be provided by dentures which in turn will need to increase the vertical dimension to create space for the restorations. Without the posterior support, any new restorations of the anterior teeth would be subjected to occlusal stresses and would break. Again, anterior restorations in these

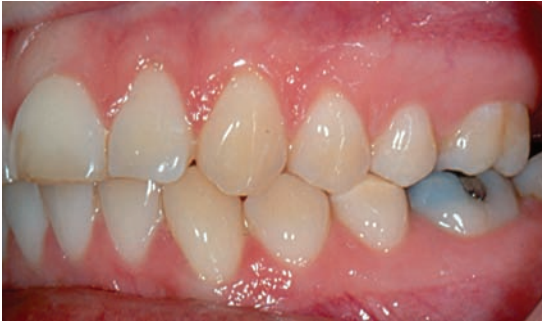

(a)



(b)

**Fig. 27.13** (a) Composite applied to the palatal surfaces of the incisors shown in Fig. 27.12; (b) the composite has increased the vertical dimension and the posterior teeth have been taken out of occlusion.



**Fig. 27.14** Four months later there has been intrusion of the incisors and extrusion of the posterior teeth and the posterior teeth are in occlusion. The incisors may now be restored without removing tooth tissue on their palatal aspects.

cases should be acid-etch-retained composites and not complex crowns whose failure would lead to loss of the teeth.

Whether the posterior occlusion is restored by dentures or composite build-ups, the restoration of the

anterior teeth needs to be done carefully and sequentially.

The lower incisor tip is the starting point for determining the new incisal guidance. Its new position should be in line with the long axis of the tooth to maintain it in muscle balance. The height of the tip, determined from the new occlusal plane, in turn dictates the position of the cingulum centric stops on the upper incisors. The remainder of the incisor crowns can be shaped empirically to provide overbite and overjet consistent with the dental base relationship and, if known, the patient's previous appearance.

### Overdentures

These are the treatment of choice for the older patient with a number of missing teeth in addition to surface loss. The principles of treatment were described in Chapter 26.

#### Tooth Surface Loss – Summary

There are many ways that tissue may be lost from tooth surfaces without caries being involved and prevention of surface loss is essential by education of the public. Also, early recognition of the problem by the dentist allows the provision of the appropriate interceptive treatment.

Removal of the aetiological agent(s) is important following which the emphasis is now on simple treatment that does not compromise the remaining tooth substance and the provision of restorations that can be replaced easily when they are lost, without the risk of losing the teeth.

# Chapter 28

## Temporomandibular Dysfunction

This topic is very controversial. The number of therapies proposed to treat the condition probably reflects the lack of a fundamental scientific understanding of its aetiology and pathology. Much confusion is caused by the inclusion of several different conditions under the one heading.

In spite of this, there is a body of moderate opinion that is in basic agreement; this chapter presents this mainstream approach.

### General Features

Pathology in the temporomandibular joints (TMJs) and muscles of mastication together with disturbance of their neural control may lead to incoordination or restriction of mandibular movement and pain.

Whilst the principal outcome of this is pain in the muscles of mastication, which may be reported as headache or even toothache, the underlying pathologies that give rise to this are complex and varied. The primary cause may be within the joints themselves, leading to movement problems or, more commonly, a relatively simple, but poorly understood, muscle problem.

The most straightforward aspect of this wide range of pathology is that affecting the TMJs. This includes:

- Derangement of the joint
- Inflammation of the joint
- Degenerative disease
- Extrinsic trauma
- Growth disorders

Detailed description of the last four conditions is outside the scope of this book and the reader is referred to texts on oral pathology and surgery for this. However, the conditions must be included in the differential diagnosis of temporomandibular dysfunction.

Derangement of the joint has already been mentioned in Chapter 8 and may involve the articular disc being out of phase with the condylar head or simply trapped permanently out of place. This is considered further later.

The muscle problem, *temporomandibular dysfunction* (TMD) also termed *muscle dysfunction*

*syndrome, craniofacial dysfunction or temporomandibular joint/muscle dysfunction syndrome*, is characterised by one or more of the following, *independent of other oral pathology*.

- Incoordination of mandibular movement
- Pain in the muscles of mastication
- Restriction of movement

The disorder may or may not be accompanied by joint derangement or may have been preceded by painless clicking of the TMJ.

It is important to note the proviso that the condition is independent of other oral pathology. That is, it is a primary condition (see later).

### Aetiology

The neuromuscular control of mandibular movement is extremely complex and was outlined in Chapter 8. There are various irregularities of tooth relationships, some caused by dentists, which were discussed in Chapters 8, 14 and 18. These include pre-centric prematurities, working and non-working interferences, tilting, overeruption, missing teeth, malocclusions and, sometimes, faulty restorations.

There is a central nervous system function, referred to as the 'adaptive capacity', that is able to compensate for hard tissue irregularities by controlling muscle function. This CNS centre is able to modify control of mandibular movement to take account of all the irregularities mentioned above. Probably the most important oral function affected is swallowing which involves the learnt position of centric occlusion.

The closure of the mandible into centric occlusion is performed on a preferred arc of closure that avoids any pre-centric prematurities. Being able to reach centric occlusion without touching interferences is partly learnt and partly reflex behaviour and, in the normal subject, is easily reproduced. Further, man has the capacity to adapt to and use many extremes of malocclusion quite successfully for functional purposes. Indeed, this adaptation can be quite rapid in the presence of, say of a newly restored occlusal surface whose 'strangeness' disappears after a few days.

However, several things may interfere with muscle and joint coordination, which may have more lasting effects:

- Trauma, such as prolonged opening, wide yawning, or tough foods
- Pernicious habits such as nail biting
- Parafunctional clenching or grinding – *bruxism*
- 'Correction' of gross malocclusion by posture
- Extensive restorations or dentures of incorrect occlusal contour
- Independent oral pathology
- Emotional stress – anxiety, worry, major life event
- Psychiatric illness

The effects of trauma as an aetiological agent are very basic and can be understood clearly. Nail biting requires the mandible to be advanced to edge-to-edge incisal contact and maintained in that position for nibbling. The masticatory apparatus is not well suited to this function, and fatigue and spasm may develop in the lateral pterygoid and masseter muscles.

Bruxism consists of continued parafunctional movements, which again cause the muscles to tire.

The moderate to gross Class II division 1 malocclusion causes problems in the achievement of a conventional oral seal and also, to compensate for the aesthetic problems of a chinless profile, subjects often posture forward continuously. This again fatigues the muscles.

A faulty occlusal surface may induce an abnormal pattern of chewing, either because of avoidance or because of awareness of a problem, and incoordination results. It is assumed that the adaptive capacity is exceeded in these cases.

Independent oral pathology is a major heading in the differential diagnosis of TMD. The true syndrome occurs in the absence of such pathology, but sometimes similar muscle pain is induced by other disorders. These include carious teeth, pulpal conditions, apical pathology, split-roots – the list is very long. The

aetiology is simply based on avoiding a painful or uncomfortable contact during function or parafunction.

The neuromuscular coordination is lost because a new pattern of movement is being attempted and joint clicking and muscle tenderness may be the results. Treatment to remove the pathology will usually induce the muscle pain to resolve with no active occlusal therapy.

Emotional stress, worry, anxiety-based disorders or psychiatric disorders are considered to be major factors in the aetiology. These factors are recognised to be of importance in other conditions such as duodenal ulcer, low back pain and migraine, and TMD falls into the group of stress related pathology. Why some people get ulcers while others get facial pain is not clear but it would seem that susceptible patients are at risk of certain conditions.

The influence of the psychological factors would appear to be the interference with central functions. Again, the neural control of mastication is affected leading to incoordination. Psychological problems are complex and it is not for dental surgeons to play the amateur psychiatrist! However, some understanding is necessary.

Surveys have indicated that 40% of the population may have TMD during their lives. Classically, there is an acute episode in late teens that clears quickly, followed by a more chronic recurrence in middle age. Women and men are affected equally but in many clinical studies there are as many as seven times more women than men attending for treatment. This finding is likely to be influenced by the fact that women seek medical advice more frequently than men.

## Clinical Features

The principal symptoms are masticatory muscle pain or spasm that builds to a peak of pain that then declines over a period of several months or even years. The disorder has no physical signs and is solely reported by the patient on the basis of symptoms. Whilst palpation of the muscles will result in reported tenderness and there may be limitation of opening, all these are reliant on the patient's response.

Pain around the face and head will cause patient's concern and may be exaggerated by focused attention, misconception and fear. An account of the pain picture based on the information, seen in Fig. 2.1, may be valuable for diagnosis. As was mentioned above, the condition affects susceptible patients and such patients may be treatment seekers, exaggerating

their symptoms for attention. The superimposition of anxiety may reduce the pain threshold of the individual.

Bilateral palpation of each pair of masticatory muscles in turn is required to build up a picture of the severity of the disorder but subjectively this can be done by careful questioning. The extent of sleep loss, inability to chew and pain on opening will all contribute to an understanding of the extent of the problem; this in turn will give a guide to the possible success of treatment.

### Temporomandibular joints

The acute muscle symptoms may have been preceded by painless clicking and locking of the mandible or be accompanied by clicking in the TMJs. Other TMJ pathology may provoke muscle pain but this, although the same as that of TMD, is a secondary aspect of another primary pathology.

The classic TMJ click occurs on opening and/or closing with tooth separation of about 1–2 mm that is caused by the articular disc becoming displaced from the head of the condyle and then catching up either from posterior or anterior. The disc can become permanently displaced but this may be found in the absence of any symptoms at all. The click can be felt by palpation of the joints or heard via a stethoscope.

Failure of the relocation of the disc–condylar complex during opening can result in locking of the mandible at mid-opening. The disc is trapped anteriorly on or beyond the eminence. This again can be painless and patients may become used to relieving the problem themselves. However, once locking is accompanied by pain, the patient will usually seek treatment.

If treatment is not sought and the condition does not resolve, then progress of the disorder may continue with painful function, permanent displacement of the disc and eventually osteoarthritis. However, locking will usually have disappeared to be replaced by the pain from the joint in all functional positions.

The diagnosis of disc displacement is notoriously difficult to confirm since conventional radiographs are often normal. There may be pain in the joints, functional difficulty and there will often be occlusal derangement associated with the displacement. With the discs being displaced anterior to the condylar heads, the condylar heads can position themselves further superiorly. On closure the teeth at the posterior ends of the arches will touch only with the appearance of an anterior and partial lateral open bite.

The teeth no longer in contact in centric occlusion may have non-contacting wear facets which reveal that they used to be in contact.

Joint derangement may also cause speech problems because the anterior teeth no longer occupy the same position. To confirm the pathology, an MRI scan is required.

Muscle pain, spasm or tenderness plus limitation of opening can occur without joint disturbance, but the reverse is unlikely.

### Management

This is perhaps one of the most controversial areas of dentistry and the multitude of treatments that are used probably reflects the difficulty of accurate diagnosis and the low level of understanding of the pathology of the disorder.

The other complicating factor in the assessment of treatment methods is the self-limiting nature of the disease. There is definitely a peak of pain and dysfunction and then resolution, and much treatment is likely to be applied in the declining phase of the disease, thereby showing favourable results.

Broadly, conservative treatment may be categorised as follows:

- Reassurance and explanation of the condition
- Basic physiotherapy
- Occlusal therapy
- Systemic therapy

Of these, probably the third and fourth are mutually exclusive, with individual practitioners having a strong preference for using one or the other. A balanced view would be that there is a place for all of these possibilities in the treatment of the condition, but the difficulty is to define the exact type of patient and syndrome which would benefit from each therapy.

There is some evidence to suggest that personality type or susceptibility to psychological disease may have a bearing on the success of treatment. Some patients may be treatment seekers and would not be satisfied with reassurance only. Others with a high psychological morbidity might be better treated with systemic antidepressants rather than local occlusal therapy.

There is a high level of placebo response reported in several studies and the confidence of the operator in his favoured therapy also influences the outcome.

## Reassurance and explanation

This is of fundamental importance, particularly in those patients who are in severe pain, may have lost sleep and find it difficult to eat. They need a simple explanation of the condition that will allay their fears that their condition is serious or even sinister.

An explanation based on the analogy of the pulled muscle or sprained ankle seems readily acceptable to most patients. The particular muscles involved can be demonstrated, and headache from the temporals or neckache from the sterno-mastoid or posterior belly of the digastric is easily explained. Clicking of the TMJs can also be compared with common clicking in other joints.

The relationship of the condition to anxiety or stress can be discussed, particularly if the patient admits to clenching or grinding during the day.

## Basic physiotherapy

This is to rest the affected muscles, ease spasm by the application of moist heat or cold (as in sports injury therapy) and the use of appliances, again to rest or support the affected parts.

Patients should be advised to avoid wide opening, to let their jaw 'hang loose' to relax the muscles, and take a soft diet. An insulated hot water bottle is probably the most readily available way of applying heat to the muscles, though there are commercially available 'heat packs' which are very useful.

Having relieved muscle spasm, the jaws should be gently and steadily restored to normal function, either by positive exercise or by increasing the normality of the diet.

The exercises could be called neuromuscular retraining and one of the more popular is making symmetrical opening and closing movements from a central starting position. However, if these cause pain or fatigue they should be restricted. Indeed the use of exercises before the pain has been relieved by rest can be positively harmful.

The most common physiotherapeutic appliance is the occlusal splint which will be considered next.

## Occlusal splint

In the early descriptions of TMD and its management, irregularities of the occlusion were incriminated as the principal aetiological agents. This led to the use of occlusal equilibration (Chapter 14) as a primary treatment. In the ensuing years, the role of stress and

psychological problems became evident and the occlusion was relegated to a secondary role.

The purpose of the occlusal splint is to rest the masticatory muscles and allow the musculature to place the mandible into whatever position is desired without being influenced by the teeth. The precision of centric occlusion requires the mandible to always reach this position for swallowing and this may not be the most 'comfortable' position for the muscles with their neuromuscular incoordination. The splint should introduce freedom of movement and also balance and stability to the mandible in its closed position.

A further function is to increase the muscle length which thereby reduces the power that can be generated by the muscles.

Many designs have been advocated and these include upper splints, lower splints, soft splints, hard splints, part occlusal coverage splints, total occlusal coverage splints, smooth splints, indented splints. The reader who would like to pursue this myriad of techniques is referred to the bibliography to complete his confusion!

All designs seem to have moderate to good success rates and, because of the particular history of TMD, Solberg has suggested that the occlusal splint is 'the gold-plated placebo'. The confidence of the operator in his splint could be very important in inducing a positive response from the patient. There are very high placebo responses in many studies, some of the order of 45%. Suggestion and cognitive awareness complement the placebo effect. Cognitive awareness in this context is the reminder of there being something to be avoided by the presence of the splint.

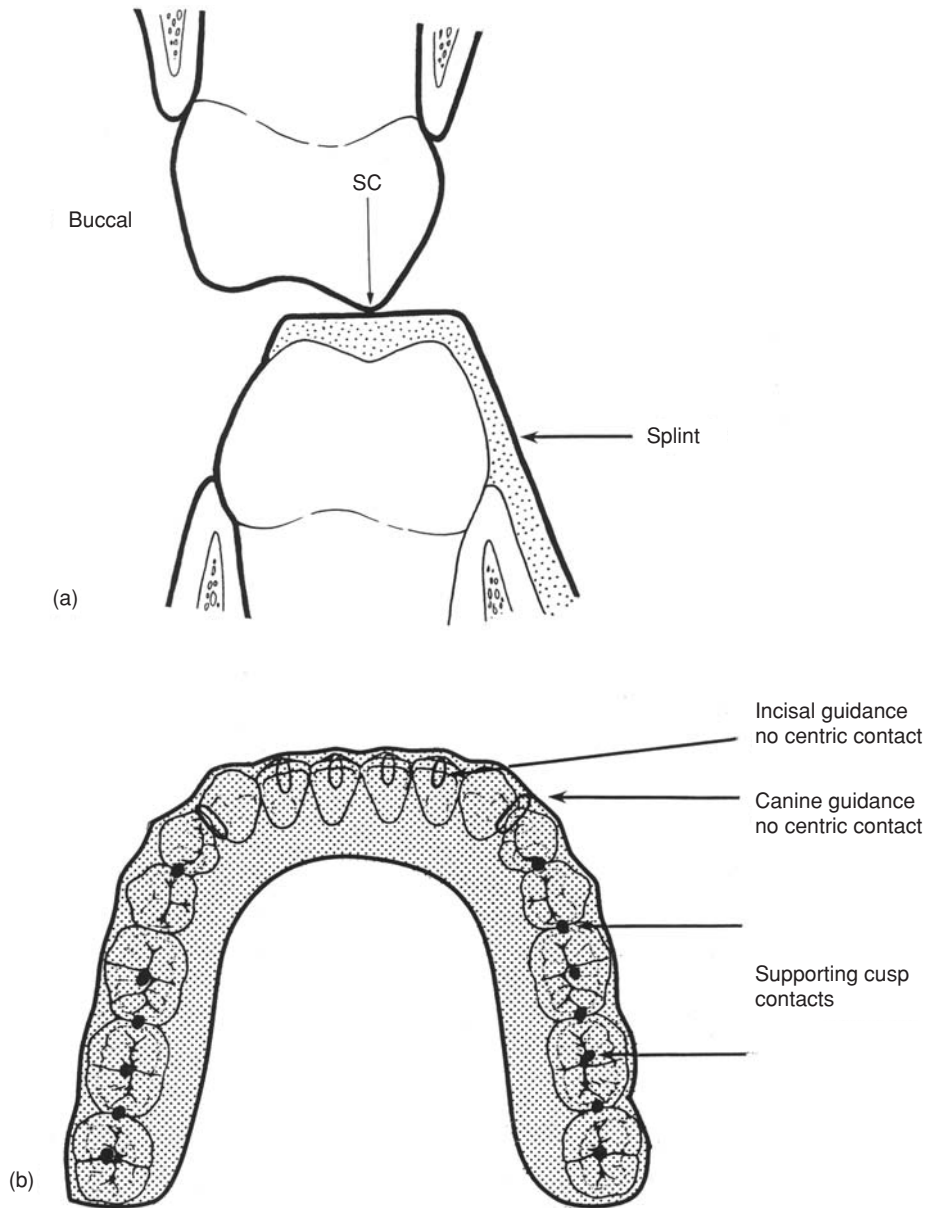
This writer has his own favourite, which works in his hands, and intends to describe this in detail together with his justification for using it.

The type and features are as follows:

- *Lower* – this is less obtrusive than an upper and seems better tolerated
- *Hard* – accurate adjustment is possible together with exact stability on closure
- *Smooth* – allows freedom for the musculature to take the mandible to a range of stable positions

Again, the explanation of the function of the splint to the patient is crucial to its success.

The splint is basically acrylic and can be made either in the laboratory on an articulated mounting, or from a vacuum-formed plate that has cold-curing acrylic added at the chairside. The former is expensive of laboratory time and the latter is expensive of

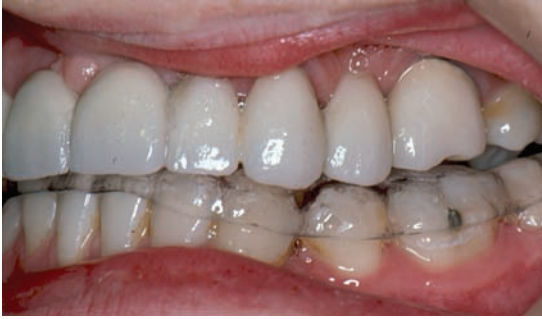

**Fig. 28.1** (a) Transverse section of a splint in the molar region. The upper supporting cusp meets the splint on a flat plateau, (b) Ideal occlusal contacts shown diagrammatically.

chairside time. The final features of each should be the same:

- The base must be stable on the lower teeth, be retentive and not rock
- The supporting cusps of the upper canines, premolars and molars should meet the splint with

even contact on flat plateaux in any position from centric relation to centric occlusion and slightly anterior to that (long centric) (Fig. 28.1a). This freedom of movement and evenness of contact should extend about 1 mm in each lateral direction. The patient should be able to slide smoothly



**Fig. 28.2** Lower occlusal splint.

on the splint by about 1-mm radius from centric occlusion

- There should be no incisal contact in long centric. This allows freedom in the arc of closure (Fig. 28.1b)

Variations in this design are the incorporation of canine guidance and incisal guidance by a raised plane anteriorly providing posterior disclusion. However, no real advantage as been found for this.

The occlusal contacts should be checked carefully with articulating paper (Fig. 28.2).

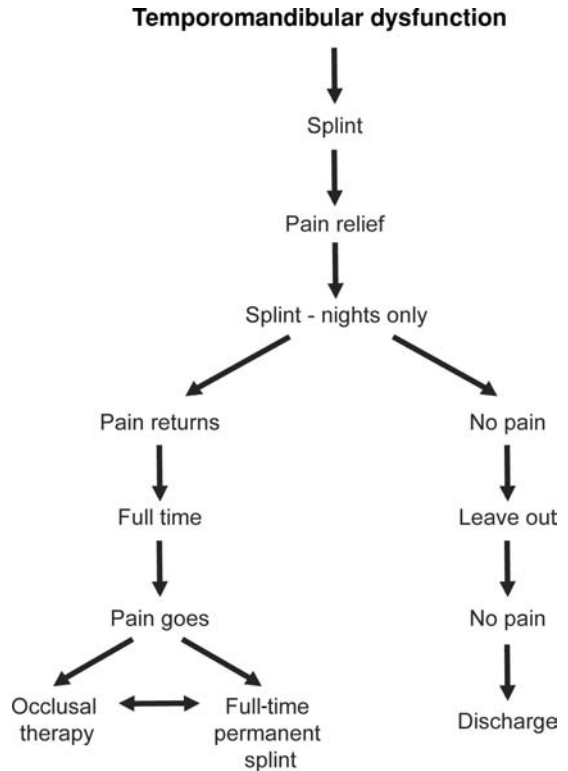
The splint should be worn full-time, particularly during eating and only removed for cleaning. It should be reviewed at 1 week and the occlusal contacts checked again, and then at 4–6 weekly intervals.

The resolution of the muscle pain is likely, provided it is not severe and long standing, within 2–3 months. The superimposition of an internal derangement of the joint may require consideration after the muscular pain has diminished (see later).

Following relief of symptoms, a decision must be made as to when the splint can be discarded. Initially, the splint should be reduced to night wearing only for 4 weeks to judge response. If pain does not recur, then the splint can be left out altogether, followed again by review (Fig. 28.3). Many patients then keep the splint to hand for any recurrence of symptoms.

*Bruxism* may also be managed by such a splint, though it should be heat cured for strength, and an upper one is usually more durable. Nights-only wearing is quite successful as this is when most parafunction occurs. Recent work has suggested that bruxism is an inherited trait and whilst a splint will protect the teeth from damage and may change the parafunctional pattern, the overall condition cannot be ‘cured’.

Other splint types can be equally successful and a lower full coverage soft splint is popular. This has the



**Fig. 28.3** Flow chart showing the progress of temporomandibular dysfunction with treatment.

advantage that occlusal adjustment is not required and it is easily replaced if it splints.

### Occlusal aspects

The vast majority of people have occlusal irregularities but few of these people suffer from TMD. Indeed, in those patients who suffer from TMD the occlusal disharmonies will have been present for some years prior to the commencement of the disorder, and in many patients once the muscular pain has been resolved and whatever has predisposed them to the condition has been resolved, they return to adapting to the disharmonies.

Certainly, occlusal equilibration should never be used as the primary treatment, since the musculature will be provoked by the periods of opening required for the therapy and CR is not likely to be reproducible with muscle pain and incoordination present.

If the pain is resolved by the use of the splint, then some workers consider this to be diagnostic of occlusal disharmonies being a primary aetiological



agent. The complexity of the disorder, though, does not lend itself to such simple assumptions. A comparative study of equilibration versus feigned equilibration showed better resolution in the latter group!

Correction of major occlusal disharmonies is possibly of long-term value. This would include orthodontic correction of instanding incisors or the extraction of overerupted wisdom teeth. There is some evidence to support the correction of a lateral deviation on closure into CO.

However, the presence of postero-anterior slides from CR to CO on closure is so common, that these really cannot be classed as aetiological agents in their own right. It may be that they become significant when the syndrome has developed, and their reversible elimination by a splint helps the syndrome to resolve. But after this, they appear to return to their previous level of insignificance.

### Provision of restorations

An incorrect occlusal surface can clearly initiate avoidance and then muscle pain that is similar to that of TMD. In these cases the muscle pain is secondary to the primary agent, the poor restoration, whose correction would be likely to eliminate it.

This approach can be used in mild cases, but in others the muscle pain must be resolved first, before restorative therapy is commenced. This is again related to the likelihood of provoking the muscles by treatment and the difficulty in obtaining reproducible occlusal contact positions whilst the muscle pain is present.

The occlusal splint is without doubt appropriate here and is almost certain to succeed. Following this, re-restoration can be started.

Simple restoration replacement should be straightforward, but more extensive restorations can present difficulties. Alongside this, one can consider the problems of providing restorative therapy in general for resolved TMD patients.

The dangers are that the provision of prolonged treatment could restart the syndrome by fatiguing the muscles, and then that the new restorations could also restart it.

The patient must also understand these dangers so that the operator is not held liable for the recurrence of the disorder.

Restorative therapy should be kept to the minimum possible and performed over short visits. An intraoral prop should be used to give a firm platform on which to stabilise the muscles. If there is any sign of the syndrome during treatment, treatment should

be suspended immediately. It may be necessary to reimplement the splint therapy and restabilise the condition.

### Systemic therapy

Some systemic therapy may be used to accompany the occlusal splint. This could be analgesics (soluble aspirin or non-steroidal anti-inflammatory drugs can be very effective), or muscle relaxants. The most common muscle relaxant for TMD is diazepam but this should only be used for 2 or 3 days and then in very low doses, about 4 mg at night. The tranquilliser effect and the possibility of dependence is then very low.

The major use of systemic therapy is to counteract the central aetiological agents of stress and anxiety by prescribing antidepressants. The proponents of this approach argue that occlusal disharmonies may be present but they always have been and that what has happened is a neuromuscular problem induced by interference with neural pathways. Various antidepressants have been used and good success rates have been reported. However, these are not substantially better than the rates for splint therapy.

The average dental surgeon, if he or she believes in this approach, should make the diagnosis and then refer the case to a medical practitioner for prescription. Whilst lower doses of antidepressants are effective, possibly by virtue of their action in reducing muscle tone, the side effects of the therapy must be monitored and appropriate training is necessary to do this.

### Other therapies

Outside the mainstream of conventional and reasonably well-substantiated therapy are other approaches. These are based on empirical theories and observations and may be related to chiropractic and osteopathy. A relationship of the occlusion to the biomechanics and balance of the vertebral column has been proposed, particularly to the skull position. Treatment aims here appear to be directed at correcting occlusal anomalies to reposition the skull and vertebral column. This is claimed to relieve headache and low back pain. The occlusal therapy may be accompanied by therapy from a cranial osteopath.

None of this has any scientific substantiation and it must be remembered that these patients are susceptible individuals, perhaps with sub-clinical psychiatric problems, who may be vulnerable to suggestion.

## Internal Derangement of the TMJ

The articular disc may simply be out of phase with the condylar movement or may be permanently displaced. In addition, there may be derangement of the articular surfaces, either from trauma or from chronic inflammation.

The simplest form of derangement is the click caused by the out of phase disc catching up with the condyle, and if this is painless, no treatment is usually necessary.

If the clicking is accompanied by muscle pain, then this is stabilised first, and the result may be a painless click. Again, no active treatment for the residual click is necessary. The only problem is that the elastic fibres posterior to the disc, which bring it back from protrusion, can become stretched, leaving a prolapsed disc.

However, if the joint pain persists after splint therapy, together with limitation of opening and joint sounds, then further treatment will be necessary. This is also true of locking, which can occur without clicking.

Further treatment must be done upon the basis of an accurate diagnosis and to do this MRI scans of

the TMJs are necessary. These will reveal whether the disc is displaced or whether there are arthritic or other changes in the joint.

Simple conservative therapy has some success in releasing the displaced disc back to its normal position. This is done with a repositioning splint, which is very similar to the muscle stabilising splint described earlier, but has positive tooth-guiding planes for closure.

The path of closure is anterior to that normally employed, and the maximum contact position is forward also. Thus, the condyles are advanced and pulled downwards in the fossae. The splint should be made from a wax record which reproduces the position of the mandible on closure just before the click occurs. The splint must be worn continuously and should not be used in the presence of muscle pain, which will be made worse by the abnormal forward posture.

Success rates for repositioning splint therapy are variable and this type of therapy should be reserved for those cases which have remained insoluble from the muscle stabilisation splint.

The internal derangements resulting from trauma or osteoarthritic change require surgical management.

### Temporomandibular Dysfunction – Summary

The condition remains a controversial area because of the difficulties of defining and diagnosing the syndrome and the large number of treatments, including placebo, which have reasonable success rates.

Simple, reversible, non-invasive therapies are recommended as the first option with the more difficult procedures and systemic drug therapy held in reserve for those who do not respond to the first approach.

There is clearly a small group of patients who show little response to all forms of treatment, and who eventually get better by themselves!

## Chapter 29

# Management of Failure in the Restored Dentition 1: Fixed Restorations

We all have failures! But it is essential to learn from them and not make the same mistake again. This book has tried to give a practical, common-sense approach to many aspects of restorative dentistry, and to follow its advice, the authors believe, would reduce the incidence of failures. The management of failures is a major challenge because of the damage already done. This chapter and the next deal with the problems.

Failure of restorations may be caused by the dentist, the patient, continuing pathology, inadequacies in materials and a combination of all four!

The dentist may be responsible for:

- Treatment planning errors
- Technical errors

The treatment plan must be tailored to fit the patient and be based on an accurate diagnosis of the pathologies present (Chapter 4). It must also fit the dentist's skills and facilities. For instance, a treatment plan based on the skills and experience of a specialist and his supporting team is likely to be quite beyond the reach of the average general practitioner and his.

Poor treatment planning, then, is a major problem, often compounded by technical errors. Simple plans, made up of easy stages are always best, no matter how skilled the operator. Unreasonable demands on technical expertise that does not exist, and patient motivation and awareness that is half-hearted, are recipes for disaster!

It would be boring world if everything was perfect, and thankfully a lot of less than perfect dentistry requires no treatment, other than regular observation.

The questions to be answered in the affirmative before embarking on re-restoration are:

- Is there any active pathology in the area of the problem?
- Are there any symptoms?
- Is there an aesthetic problem that disturbs the patient?
- Is there a functional problem?

If the answer is 'yes' to any of these, then action is required; but there are many examples of imperfection, where nothing should be done.

### Examples for Masterly Inactivity

#### The ditched, corroded amalgam restoration

Do not replace such a restoration unless there is evidence of recurrent caries, either clinically or radiographically, or there are symptoms of microleakage (see Fig. 3.4).

#### The under- or overfilled root canal

Do not interfere unless there are clinical or radiographic signs of an enlarging apical area, or symptoms. If you do decide to interfere, be certain that there is some glimmer of hope that you can do better! Is the canal apical to the short filling obstructed, for example?

### Intracoronary Restorations

#### 'Cracked tooth syndrome'

This condition can cause considerable difficulty in diagnosis. There is a hairline, vertical fracture extending from the base of a large cavity, either to the root furcation or down the root. The patient will complain of vague symptoms, perhaps mainly on biting, that are often poorly localised. Radiographs will usually show no abnormality. Diagnosis may be assisted by using a device that places pressure on individual teeth during biting. A small piece of rubber attached to a hand instrument works well and the patient will say which tooth feels uncomfortable on biting.

The affected tooth will usually have a large MOD amalgam present, again possibly with no apparent defects. Removal of the amalgam will reveal a deep

occlusal floor and a flat plastic should be gently turned within the cavity to attempt to open the buccal wall from the lingual. A crack in the floor may then be revealed.

The prognosis for the tooth is poor, though symptoms may be relieved by placing an acid-etched composite restoration. The cusps will be held together, thus preventing the flexure stimulating the periodontium. However, the fracture line is vulnerable to infection, which may occur at time.

### Dentine pins

Pins in the periodontal ligament or pulp are a complication that can be unavoidable, due to the blind nature of their insertion. The misplacement of the pinhole should be diagnosed as soon as it has been drilled, either because the resistance to cutting was suddenly lost or because blood appeared in the hole.

The hole should not be used, but filled with calcium hydroxide. However, if a pin has been inadvertently placed in such a hole, then pulpal or periodontal infection can occur. Treatment of the pulpal infection might require root canal therapy, whilst the periodontal infection may require raising a flap, cutting the excess pin away and smoothing it flush with the root.

If the pin is superficial, then a crown preparation could cover it as a method of sealing. If the pin is inaccessible, then extraction could be the only solution.

Beware of interpreting the two-dimensional radiograph incorrectly. A correctly placed pin may be superimposed on the pulp shadow.

### Post Crowns

These are particularly vulnerable to operator error during preparation. The root morphology is unknown and unseen, and it is easy to be misled by an apparently large root face which tapers dramatically in the alveolus.

The side of the post hole may be perforated during preparation, or the root may be weakened leading to vertical fracture during preparation, cementation or later function. Posts may fracture in the canal.

### Lateral perforation

Large, parallel-sided posts are prone to this complication and particular teeth are also vulnerable. The

upper lateral incisor being small and angulated distally and palatally is a particular trap, as are roots with mesial and distal concavities (see later).

Teeth that can be either two rooted or single rooted, such as upper premolars, also give rise to problems, simply because the root morphology is unseen.

Perhaps the best advice is to avoid posts in teeth which are known to be variable in morphology, and construct pinned cores instead (see Chapter 11).

The differential diagnosis for a post crowned tooth that is giving problems must always include the possibility of a perforation, and a second radiographic view can be helpful (Fig. 29.1). This will also show the position of the perforation as labial or palatal by parallax.

The management of the lateral perforation depends upon its site and size, and the restorability and prognosis of the tooth as a whole. A carious, short-rooted tooth is better extracted, rather than embarking upon difficult treatment. Also, if a perforation can be positively diagnosed as palatally placed, then the tooth should be extracted.

Having decided upon trying to save the tooth, the first decision is whether to remove the offending post, or leave it in situ. A small-rooted tooth may not survive the stress involved in withdrawing a post, and a threaded post can stress the root excessively on being unscrewed.

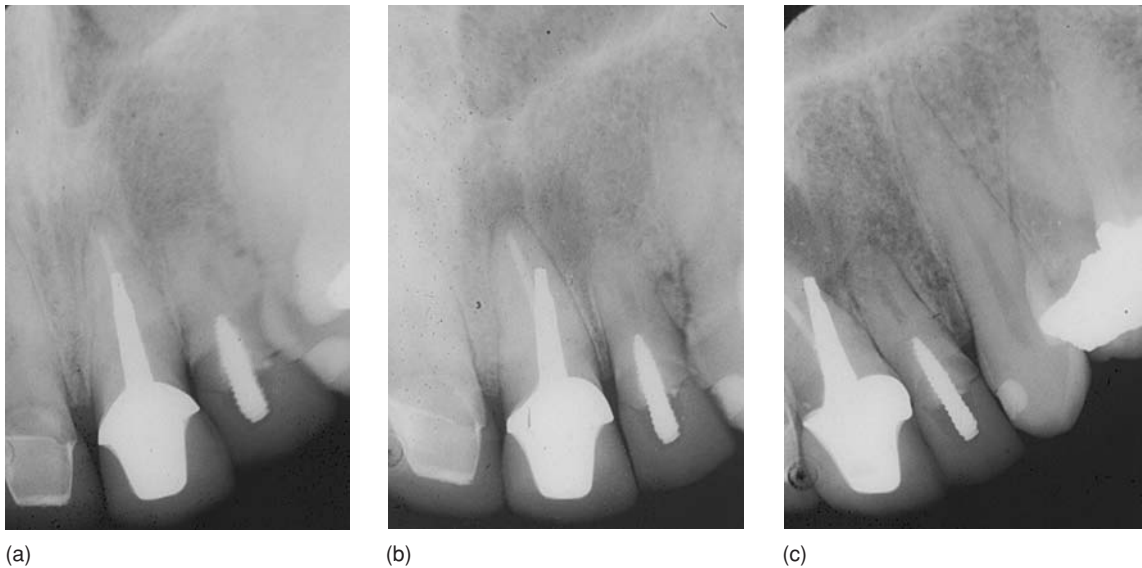
If the post can be removed (or if the perforation has been observed at preparation), then the post hole should be re-established in the correct line (Fig. 29.2), an impression taken and the new post fitted at the time of surgical exposure of the perforation.

The perforation should be isolated so that cement does not enter the bone, and the post cemented with polycarboxylate cement. An acrylic provisional crown should be placed as well. The perforation is cleaned and retention provided around it by a small round bur. Mineral trioxide aggregate (MTA) is then placed to seal the perforation (Fig. 29.2).

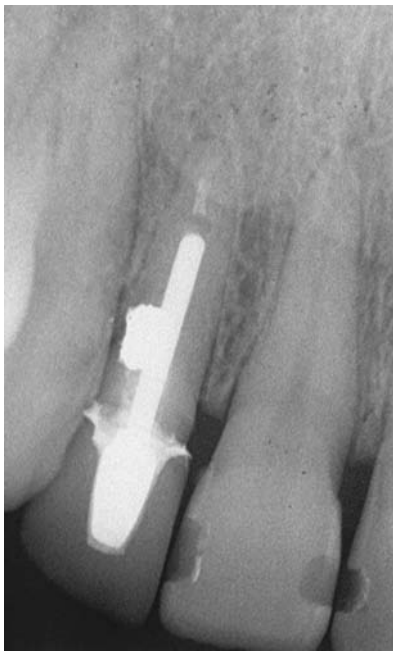This procedure may be complicated by the wedge-shaped nature of the perforation, which may be long in the long axis of the tooth and whose walls can be very thin.

If the original post cannot be removed, then surgical repair may be attempted by removing the post material that is outside the root profile, and cutting a channel around its end. This is then sealed with MTA.

A small perforation, noticed at the time of preparation, may be packed with MTA from within the canal, the post made in the correct line, cemented as usual, and reviewed radiographically periodically.



**Fig. 29.1** Periapical radiographs of the  $\overline{12}$  region: (a) suggests that the post is in the correct line of the canal; (b) taken to show the  $\overline{2}$ , reveals the post off-line; (c) taken for the  $\overline{3}$ , reveals a palatal perforation of  $\overline{1}$ . Unfortunately, the original diagnosis had been made using 'a' only, and the patient had been treated for temporomandibular dysfunction. The central incisor was later extracted.



**Fig. 29.2** A post crown with a lateral perforation has been removed, and the canal re-established in the correct line. A new post was constructed and cemented at apical surgery and the perforation sealed.

## Two cautionary tales

### A diagnostic disaster 1

The case illustrated in Fig. 29.3 had a post crown constructed on the upper left lateral incisor some 8 years previously. The tooth had given problems subsequently, and an apicectomy was performed. This did not resolve the problem and the patient, having moved home, consulted a new practitioner.

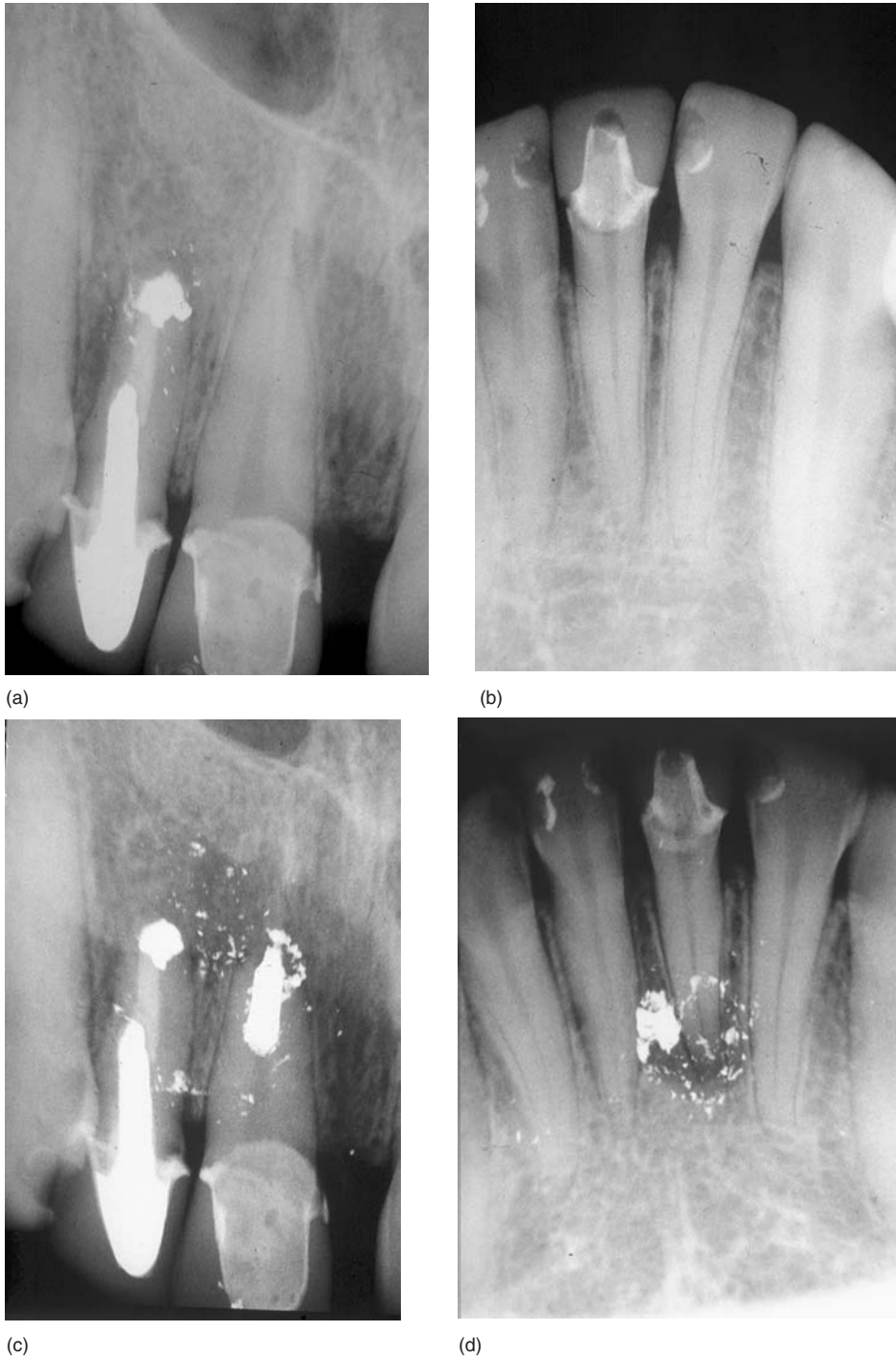He said that the previous apicectomy had failed, and the operation should be repeated. He provided the root seal shown in Fig. 29.3a.

The tooth still gave trouble, and a further house move brought the patient yet another adviser. The hospital practitioner who saw her advised that the second apicectomy had failed, and that the operation should be repeated.

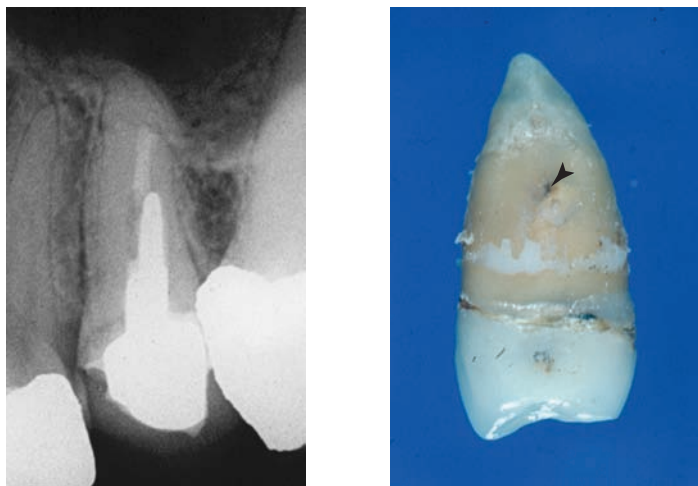
He also tested the vitality of the crowned central incisor and the crowned lower incisor (Fig. 29.3b) with ice and concluded that they were non-vital (Ceramic is a good insulator!). He advised that both these teeth should be apicected also, in spite of the absence of any apical pathology.

After a 9-month wait, the three apicectomies were done by a further practitioner, as a day case. He provided the surgical results shown in Figs. 29.3c and d.

The upper lateral still did not recover, and the patient was seen by the author. Surgical investigation

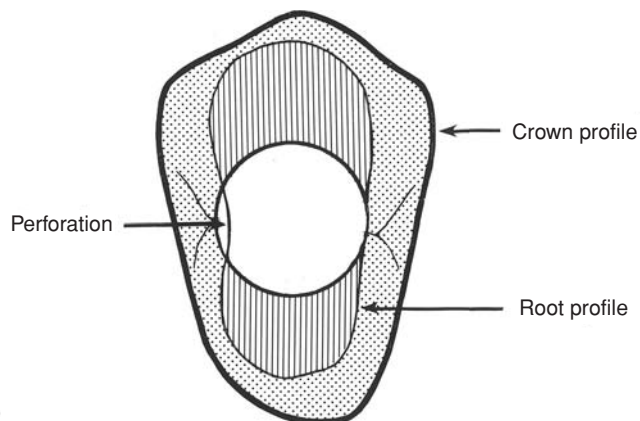


**Fig. 29.3** (a) The post crown on the lateral incisor had given trouble since it had been fitted, and the tooth had been apicectored twice previously, with no benefit. There is no apical pathology present on the crowned  $\bar{1}$ , (b) The lower central incisor had a badly fitting crown on it, but no apical pathology. The practitioner prescribed a further apicectomy for  $\underline{2}$ , and because of negative pulp tests on  $\bar{1}$  and  $\bar{1}$ , apicectomies were prescribed for these as well, (c) and (d) The results of the apical surgery. (c) The upper lateral incisor continued to be painful, (d) The operator has failed to identify the apex of  $\bar{1}$  and has deposited amalgam in bone. The tooth was subsequently found to be vital.



(a)

(c)



(b)

**Fig. 29.4** (a) The radiograph shows the post in  $\underline{5}$  to be slightly off-line, but not dramatically so. However, the root profile of single rooted upper premolars tends to have concavities (b), which cannot be seen. The large crown profile gives a false sense of security, but a perforation has occurred ((c), arrowed).

of the strong possibility of a lateral perforation by the off-line post was done, a perforation found and repaired, and the tooth settled.

The lower incisor turned out to be vital, was root filled and post crowned, and the large mass of misplaced amalgam left under review.

The patient pressed a successful claim for damages, and all teeth were still present and symptomless 4 years later.

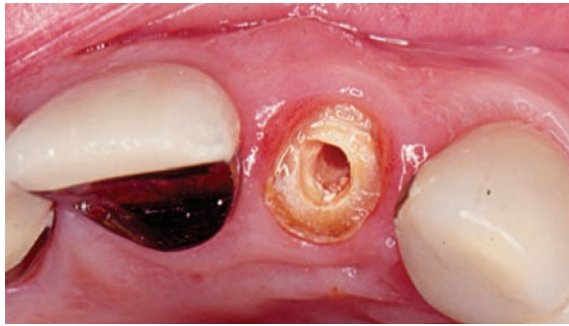
### A diagnostic disaster 2

The upper second premolar illustrated in Fig. 29.4 had given trouble since the post crown had been fitted. Acute inflammation developed such that the whole quadrant was painful with all the teeth being tender.

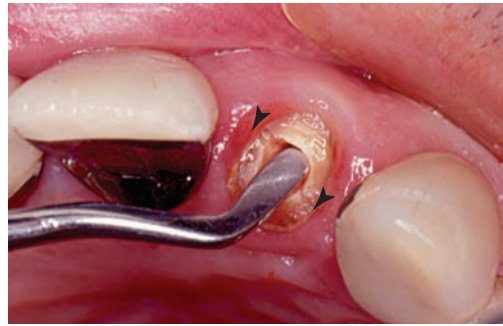
The patient attended a Sunday morning emergency service and, for some reason, the dentist diagnosed acute apical infection of the two perfectly sound incisors of the upper left side. These were 'opened to drain' and the patient attended hospital the next day.

The vital pulps, still present in the incisors, were extirpated and the teeth root filled later. The patient elected to have the perforated premolar extracted. No legal action resulted.

This case illustrates firstly, the danger of making posts on roots with unseen concavities, and secondly, the need to have the fullest information available before a committed diagnosis is made. In the face of seven tender teeth in a quadrant and no radiographs, the prescription of analgesics and antibiotics is a safer course of action.



(a)



(b)

**Fig. 29.5** Check for root fracture when a post crown has been lost. (a) The root face appears normal; (b) the flat plastic is twisted gently in the canal and the fracture (arrowed) has opened.

### Vertical fracture

Complete vertical fracture is often the consequence of a blow or jar to a post crown which knocks it out. Short, or ill fitting, posts are particularly vulnerable. Diagnosis may not be obvious, but root integrity must be checked before recementing the crown. A small flat plastic instrument should be inserted into the post hole, and turned gently to open any fracture line (Fig. 29.5). Excessive force is not necessary and should be avoided. In the event of a vertical fracture, the tooth is unsavable.

Incomplete fracture is very difficult to diagnose. It is an occasional finding during apical surgery, and all roots with posts should be inspected carefully at the time of surgery.

The crack, or cracks, may have been caused by over-zealous preparation with large twist drills, or by a later blow. They can remain stable for some time, but in some cases tissue fluid leaks through and initiates corrosion, either of the post or of a metallic root filling.

The corrosion products open the fracture line, infection supervenes, and the tooth gives symptoms. The tooth is unsavable, but diagnosis may not be made until surgery is attempted, at which time a stained root is revealed (Fig. 29.6).

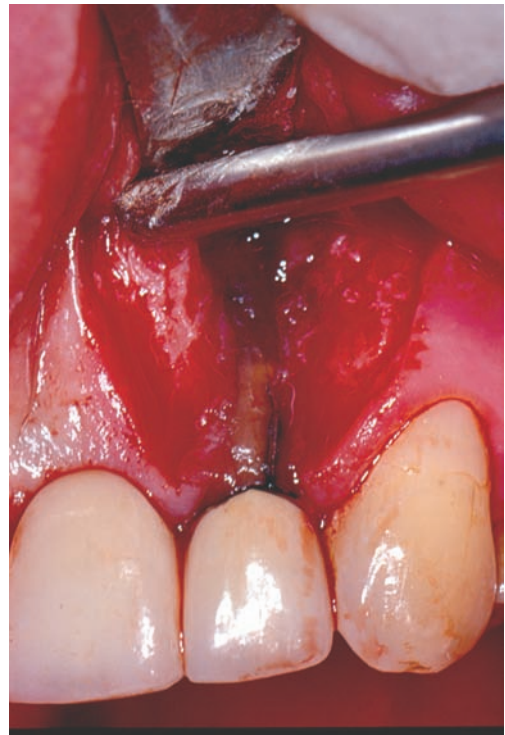
Vertical fractures may also be caused by tapered, threaded posts upon insertion. These are dangerous and should not be used.

### Fractured post

This is a particular complication of cast posts or small posts of all types. A blow, or a jar during eating, shears the post at a casting defect. The root should be


checked for vertical fracture, and if intact, removal of the fragment performed.

A special kit (Masserann, Micro-Mega) is recommended (Fig. 29.7). This is a series of cutting tubes (trepan) that are designed to cut an annulus around



**Fig. 29.6** A partly fractured root which has allowed tissue fluid to reach the metal post, and corrosion has resulted. This was found at apicectomy and the tooth was later extracted.





**Fig. 29.7** A Masserann trepan. The cutting tube removes cement or dentine from around the object in the canal, which is thereby released.

the fragment, thus releasing it. Direct and straight access is required to the fragment and the choice of diameter of trepan used is important. It should be only fractionally larger than the fragment so that the minimum of dentine is removed. Assuming that the root filling remains intact the tooth can then be re-restored.

## Fixed Prosthodontics

High standards of treatment planning and construction coupled with the joint efforts of the patient and the dentist in a continuing care programme ought to result in bridgework that has a minimum life expectancy of 10 years. Faults in treatment planning, such as the use of dubious teeth as abutments, faults in construction, such as poorly fitting margins, or inadequate oral hygiene by the patient may all reduce this dramatically.

Possible sources of failure are:

- Cementation failure
- Recurrent caries
- Non-vitality and apical pathology
- Periodontal disease
- Incorrect occlusion
- Fractured ceramic
- Wear and tear

### Cementation failure

This may be due to poor stability of preparations, differential biomechanical loading of abutments or fatigue of the cement. In multi-retainer conventional bridgework, it can be very difficult to diagnose, since

it may be partial, with the crown apparently still secure. The patient may report vague symptoms that will relate initially to dentine stimulation by microleakage and then to carious attack. These symptoms may not be specific to one tooth, and in a multiple unit restoration, this can be perplexing.

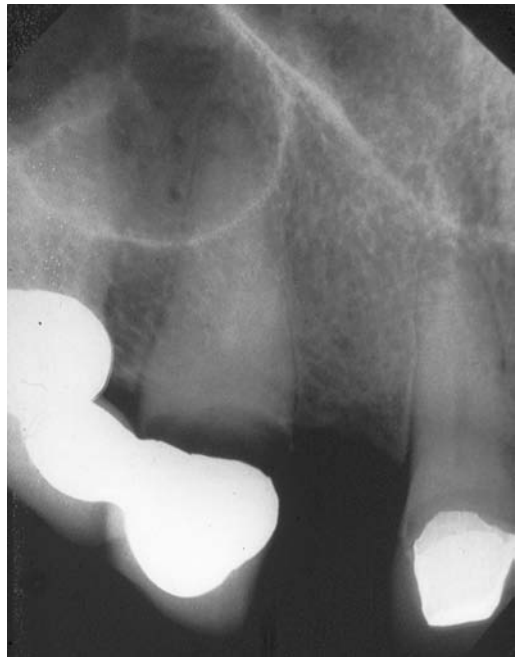
Radiographs will not reveal anything at the early stage, unless there is a deficient crown margin.

Applying displacing pressure to the restoration may reveal looseness or tell-tale bubbles at the cervical margin. This can be helpful in single crowns or on one side of a pontic, but multiple retainers may be supporting the failed one.

Unfortunately, the diagnosis can only be made with confidence when the crown is fully unseated, by which time caries could have destroyed most of the preparation (Fig. 29.8).

All this points to choosing luting agents of the highest possible resistance to dissolution and fitting bridges with the best possible marginal adaptation and retention.

Once cementation failure has been diagnosed on a bridge, the whole restoration must be removed without damage (see later), the integrity of the



**Fig. 29.8** Cementation failure. Radiograph of a bridge retainer whose connection with the bridge has been destroyed by slow caries. The pulp has disappeared also.

abutments checked and the bridge recemented if the abutments are satisfactory.

### Recurrent caries

This is potentially serious, since once the preparation dentine is reached, caries can spread rapidly. It will be revealed at routine maintenance visits, either by clinical or radiographic observation. Provided it is limited to the immediate area of the margin, the caries can be removed and the area restored with glass ionomer cement. A more extensive zone of caries, and particularly any that runs some way out of sight under a retainer, will necessitate the removal of the crown.

It is interesting to note how patients' habits and diet may change. A stable mouth with low caries rate at the time of treatment planning may exhibit increased caries activity if the patient changes to a high-refined carbohydrate diet. This may be provoked by stress – sugary tea as a stress relief mechanism, or changes in working pattern – sucking sweets as a way of passing long journeys.

These factors need to be considered within the continuing care programme.

### Non-vitality and apical pathology

Teeth that have suffered carious attack and are then subjected to pins and core placement followed by crown preparation will have had their pulps considerably insulted. It is not surprising that a small proportion of crowns and bridge retainers become non-vital, often without symptoms. Teeth that have been traumatised may also succumb. Symptomless non-vitality is difficult to diagnose without there being apical pathology to reveal it. Hence the need for radiographic review of the apices of crowned teeth, as well as those that have been root filled.

The management of such cases is by root filling the tooth through an access cavity in the crown. If this is impossible then apical surgery should be considered and failing this, the tooth should be extracted after sectioning it from the bridge.

### Periodontal disease

Assuming that the bridge was made on a sound periodontium, i.e. one that was stable and free of inflammation, then prevention is better than cure! Whilst every patient should be instructed to use Superfloss at least twice a day, it is quite surprising to note how this slips to twice a week and even less. The

result of lack of diligence in plaque removal will be marginal inflammation, particularly in the embrasure areas. Regular reinforcement of oral hygiene instruction with periodic visits to the hygienist will always be necessary.

Periodontal breakdown accounts for a surprisingly small number of bridge failures. This reflects the operation of the biofeedback occlusal load modification mechanism as well as the resilience of the periodontal ligament. Rotational forces are potentially the most damaging and these may be caused by an incorrect occlusion, usually on a cantilever design in lateral excursions.

Breakdown may be manifested by pain on biting, tenderness to percussion and mobility. Group function should be established by equilibration of the bridge or the bridge remade to a fixed–fixed design.

### Incorrect occlusion

This may give the patient the feeling that the teeth do not meet evenly, or worse, induce muscle pain similar to that experienced in temporomandibular dysfunction. Changes in overjet may make the patient feel as though the teeth are 'cramped'.

The occlusion should be examined first with articulating paper and shimstock, as described in Chapter 14. If the discrepancies are seen clearly and are not large, simple equilibration can be successful. Where there is any doubt about the errors, a diagnostic centric relation mounting should be done to permit clear examination of the occlusal contacts.

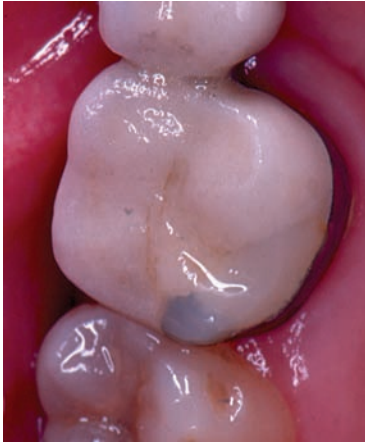A trial equilibration can be carried out on the articulation, and, if successful, repeated on the patient. If the discrepancies are too large, then the bridge will require remaking (see later).

If the bridge appears to have induced muscle pain, then this condition must be stabilised first by fitting a splint and under no circumstances should there be any irreversible adjustments made to the bridge. When the pain has been resolved, a detailed examination of the bridge can be made with a view to accurate diagnosis.

### Fractured ceramic

The most likely causes of this are incorrect metal sub-frame design so that the ceramic is not supported or insufficient occlusal clearance leading to the ceramic being too thin.

Small areas may be repaired using a proprietary silane coupling agent and a composite material (Fig. 29.9). The disadvantage of this is that the



**Fig. 29.9** Repair of fractured ceramic by composite on a bridge retainer.

composite is less durable than the ceramic and may deteriorate in time. Replacing the lost material with a ceramic veneer is a useful technique if a standard veneer preparation can be done on the fractured component (Fig. 29.10).

### Wear and tear

Long-term durability of bridge components is variable, even without the supervision of the pathology mentioned above. The most vulnerable aspect of a well-made bridge is the ceramic. The material absorbs water and undergoes static fatigue as well as losing surface stain and becoming lighter. Before the advent of shoulder ceramic, a dark line at the

gingival margin was an inevitable consequence of gingival recession.

Changes in colour that affect aesthetics can only be improved by replacing the whole prosthesis.

### Management of the failed bridge

A bridge may be a candidate for replacement if:

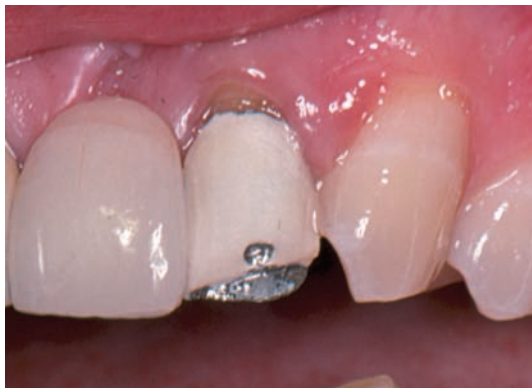- There is recurrent caries
- There is cementation failure
- One or more abutments show active pulpal or apical pathology
- One or more retainers show bad marginal adaptation
- The aesthetics are unacceptable
- The function is unacceptable

Limited recurrent caries might be amenable to local excavation and restoration, and a single pulpally involved tooth in an otherwise acceptable bridge, could be root filled through the retainer.

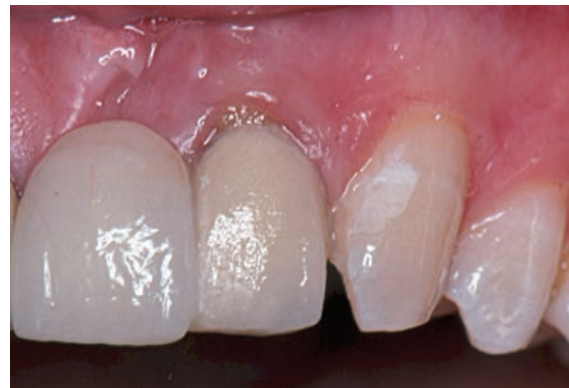In other cases, particularly where several of the replacement criteria are fulfilled, removal of the bridge is the only satisfactory solution. Because the basic condition of the abutments is hidden by the retainers, the patient must be clearly informed that no guarantees can be given about the eventual re-restoration. They must understand that if the abutment teeth prove unsatisfactory, a partial denture could be the end result.

The sequence for management is:

- 1 Preoperative diagnostic mounting
- 2 Provisional replacement constructed, usually a partial denture

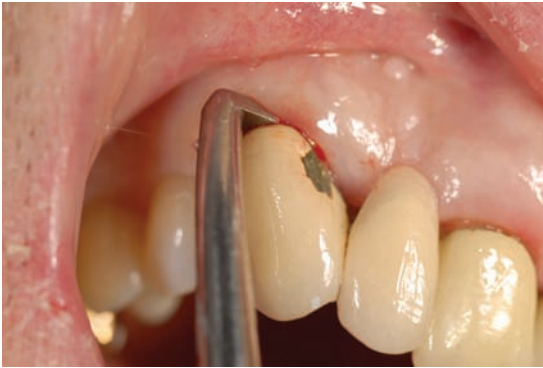

(a)



(b)

**Fig. 29.10** (a) The incisal edge of the bridge retainer on  $\underline{12}$  had fractured. A veneer preparation has been done on the remaining crown. (b) A ceramic veneer has been cemented with dual-affinity resin-retained bridge cement.



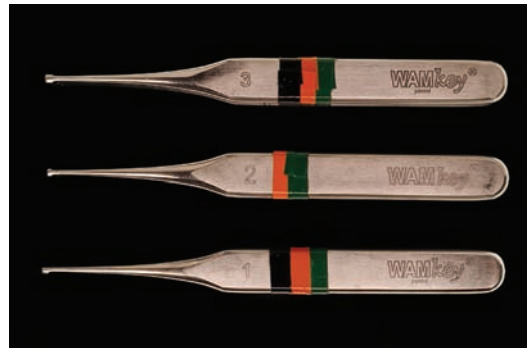**Fig. 29.11** A proprietary crown remover being used to dislodge a retainer. The device has a spring loading system that delivers a jolt through the hook. In order to apply the jolt, the retainer should have a prominent or open margin. There is a risk of tooth fracture if too large a force is used.

- 3 Remove the bridge
- 4 Section bridge into individual retainers for use as provisional crowns; fit denture
- 5 Inspect and assess each abutment tooth – vitality, restorability, prognosis
- 6 Stabilise abutment teeth as appropriate – e.g. RCT, pinned cores
- 7 Plan new bridge (or alternative replacement)
- 8 Construct new bridge

Perhaps the most difficult stage is the removal of the old bridge. Since it may be desirable to use the retainers as individual provisional crowns, removal should create the least damage possible. There is, of course, the very real danger of damaging the abutment teeth as well.

Gentle prising, by placing a Mitchell's trimmer or chisel at each retainer margin in turn, should be tried first. Then, if no movement results, mechanical shock can be applied to each retainer in an attempt to break the lute seal. Ultrasonic scalers can be successful, but the hammer blows of proprietary crown removers are more common. These are particularly unpleasant for the patient, and can fracture teeth underneath the bridge if not used with extreme care (Fig. 29.11).

A recent innovation are WAMkeys (Mirage Dental Products); Fig. 29.12. The instrument is intended to lever the crown off the preparation by being inserted in the cement layer between the occlusal surface of the preparation and the inner aspect of the crown. The location of this is by guesswork and the speculative cutting of a narrow horizontal hole in the crown. This is deepened until it reaches the centre of the tooth preparation. The appropriately sized WAMkey is



(a)



(b)

**Fig. 29.12** WAMkeys.

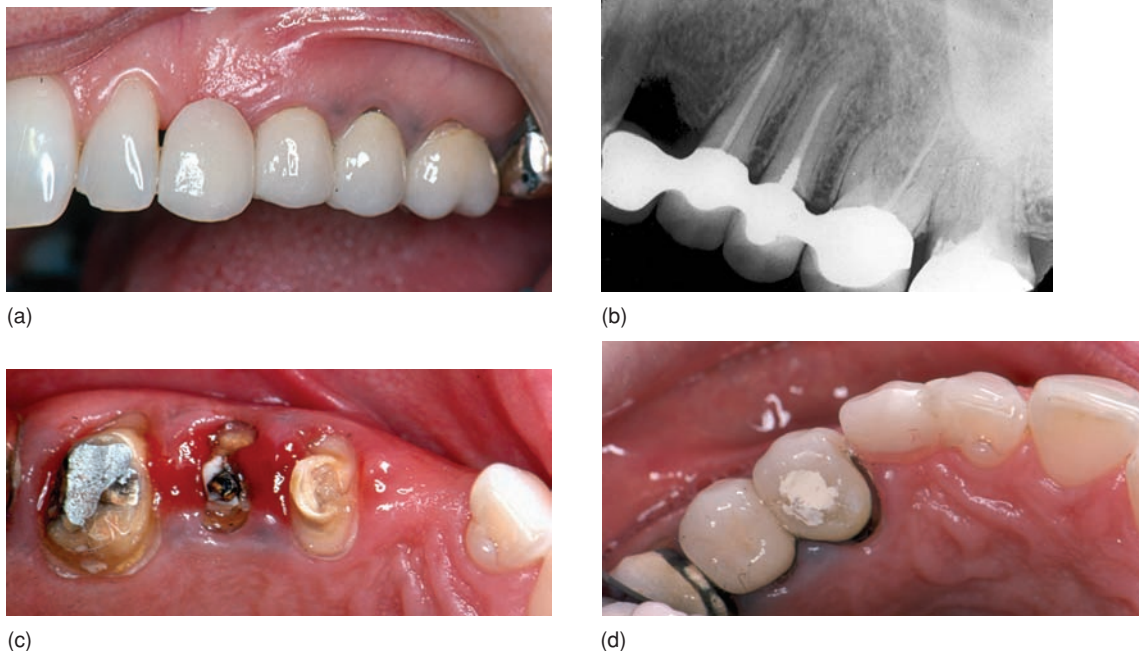
inserted into the cavity and rotated by a quarter turn. The crown should lift off.

If finally no movement is seen after a few minutes the last resort is to cut each retainer with the air turbine. This technique, whilst destroying the bridge, at least means that the abutments escape with minimal damage.

A vertical cut should be made on the buccal aspect of each retainer, through the metal/ceramic only, using the appearance of the luting agent as a guide to depth. Special burs are available to do this. Care should be taken not to cut dentine, since this leaves grooves that may dictate an unfavourable path of insertion for the new bridge. A cut across the occlusal surface may also be necessary for the retainer to be released.

To construct the provisional restorations, temporary crown forms may be used or, alternatively, the preoperative mounting can be used as the template for polymer-based provisionals.

The failed bridge shown in Fig. 29.13 presents several problems for its replacement and the



**Fig. 29.13** (a) This bridge replacing  $\underline{13}$  is cantilevered from  $\underline{456}$ , which is probably one retainer too many, (b) The radiograph shows that the premolar crowns have poor margins and short root fillings. There is an apical area on the  $\underline{4}$ , and a second root which has not been filled. The buccal root canals of  $\underline{6}$  have not been filled, (c) The underlying teeth showing recurrent caries, and inadequate preparations on the premolars, (d) The bridge has been sectioned into individual provisional crowns to allow the root canal therapy to be redone, and a denture tooth has been acid etched to the  $\underline{12}$ . Following the root therapy, the bridge was remade from  $\underline{45}$ , with the  $\underline{6}$  being restored with a separate crown.

patient needs to understand these properly before any attempt is made to start treatment. The radiographs show inadequate root fillings, all of which need to be replaced, and the state of the preparations of the abutments cannot be determined until the bridge is removed. The replacement of this bridge took several months.

### The Obsessive Patient

This is a failure, or series of failures waiting to happen! Feinmann and Harris have coined the term ‘Oral Dysaesthesia’ for patients who have an unnatural concern about their dentitions. The term ‘phantom bite’ is also used.

Dentists and plastic surgeons are very vulnerable to the demands of perfection seeking individuals, and in dentistry, whilst sometimes reasons for treatment can be found, no organic disorder will usually be found to underlie the request for treatment. (This is the third

time this warning has been written in this book – it bears repeating!)

Such patients may complain about the aesthetics of their teeth or the arrangement of their ‘bite’. In the writer’s experience, many are women in their thirties, with apparently stable family backgrounds.

Other patients, particularly in the older age groups, complain of pain for which no organic pathology can be found. Some also give impossible pathologies as their diagnosis; e.g. a patient believed that microleakage around a crown lead to air entering the nervous system and causing paralysis of the left side at night!

The dentist can easily be tempted by the history to undertake replacement of the dubious amalgam, provide crowns or even extract perfectly healthy teeth.

Unless a pathological process is diagnosed, *no operative treatment* should be performed. This will be doomed to failure, and the patient will continue to demand more and more until the dentist calls a halt. The patient will then leave in a distressed state.

Recognition of the problem is the key to avoiding it. Beware of the patient who asks numerous technical questions, offers a history of unsatisfactory care elsewhere or who is overbearingly demanding about the standards of care required.

### Medico-Legal Aspects of Failures

Every patient with a failed restoration is a potential litigant, but fortunately the vast majority of patients are loyal to their professional advisers. By discussing possible problems as they are foreseen during treatment, the patient is taken into the dentist's confidence, and if the worst happens, the patient is expecting it too! The patient then sympathises with the dentist.

The ability of the dentist to communicate effectively is a major factor in avoiding litigation.

When discussing failures with the patient, it is important to put the problem in the context of the general difficulty of the technical aspects of dentistry. Explanations about the variation in tooth form, technique sensitive materials and so on, often gain the patient's sympathy and understanding.

However, this is not to suggest that deceiving the patient is appropriate. It is very necessary to explain exactly what is wrong and what needs to be done to put it right, without apportioning blame. If the patient continues to express dissatisfaction with previous care, it is best to be non-committal and supportive of the previous dentist if at all possible.

The courts do not expect every dentist to have specialist skills and to be successful in every case. They require that the treatment provided is of a reasonable standard appropriate to the dentist's training and experience, and has been delivered in a careful manner.

# Chapter 30

## Management of Failure in the Restored Dentition 2: Dentures

### Management of Denture Problems

Although the possibilities for complaints about dentures are numerous, the more common denture problems are:

- Pain/discomfort
- Looseness/loss of fit
- Inability to chew efficiently
- Appearance
- Speech
- Retching
- Broken dentures
- Burning mouth

### Pain/discomfort

Important information necessary for diagnosis and treatment planning includes: site, duration, aggravating/relieving factors.

Pain/discomfort may be related to:

- Extension of the borders
- Condition of the fitting (impression) surface
- Extension of the base
- Anatomy of the denture bearing tissue
- Occlusal errors
- Occlusal vertical dimension

Overextension of the border usually causes localised pain and is most common in the early period following the provision of a new denture. It may be possible to detect the offending area by looking for deflection of the tissues in the sulci when the denture is inserted, otherwise pressure indicating paste or spray can be used.

The fitting surface of a new denture should be examined for sharp ridges or acrylic resin pearls which, if present, should be trimmed and smoothed. Undercuts may need to be reduced or eliminated to allow the dentures to be inserted atraumatically. With the passage of time and alveolar resorption the adaptation of the fitting surface to the tissues may deteriorate and result in localised pressure spots. These can be identified with pressure indicating paste/spray and

relieved but other treatment; e.g. relining might also be considered.

In the lower arch, a complaint of generalised discomfort may result from an underextended base transmitting high pressure to the reduced area of supporting tissue. The remedy is to correctly extend the base and, of course, to optimise other design factors such as occlusion and occlusal vertical dimension.

Localised pain may be caused by anatomic features such as a narrow, sharp mandibular ridge and gross alveolar atrophy resulting in the superficial positioning of the mental foramen. The complaint is normally of sharp pain on pressure and, if the mental nerve is involved, of a shooting pain along its distribution into the lower lip.

If the occlusion is not even and simultaneous then excessive pressure will be transmitted to the underlying tissues on the side of the premature contacts. A locked occlusion will not permit lateral excursions without resulting in movement (dragging) of the entire denture base over the tissues (commonly the lower). This can be more obvious when new dentures with anatomic teeth replace an old set with a very worn occlusion which permitted unrestricted lateral movements.

Errors in the occlusal vertical dimension can lead to symptoms from the denture bearing tissues or the masticatory apparatus. Lack of freeway space may cause excessive loading of the tissues and resultant generalised discomfort. It might also lead to pain in the muscles of mastication. Excessive freeway space is unlikely to result in painful ridges but may cause symptoms in the musculature.

### Looseness/loss of fit

A most important factor in looseness of a denture is the time scale. If the complaint is made at the insertion stage of a new denture the dentist should first be satisfied that the design features and standard of technology are adequate, i.e. border and base extension, adaptation of the base to the tissues, posterior palatal seal etc. The patient should then be reassured that all is well and that their muscular control of

the denture(s) with habituation will enhance denture wearing. On occasions the patient may be advised to use a denture fixative to give added confidence in this early phase.

Inevitably the alveolar ridges will resorb with time, with the mandible losing ridge height and width at approximately four times the rate of the maxilla, and the denture base will no longer 'fit' the tissues. It may, however, be some time before the patient complains of looseness because during the period of gradual ridge loss (s)he has learnt control of the dentures. Indeed, some patients can control and manipulate old dentures that, in the view of the dentist, are well past their useful life.

If the looseness can be attributed to the fitting surface of the denture whilst other design factors are satisfactory, a relin/rebase can correct the deficiency.

### Inability to chew efficiently

The complaint of lack of chewing efficiency may be due to worn teeth on an old denture or the use of non-anatomic teeth on a new denture. Excessive grinding of new teeth to correct occlusal errors will also spoil the shape of the teeth and limit their capacity to reduce foodstuffs.

Occasionally patients may find difficulty chewing if the occlusal vertical dimension is outside their tolerance limit. A poor occlusion, for example, when the number of teeth contacting is reduced, may also contribute to chewing difficulties.

### Aesthetics

A complaint of poor appearance relating to dentures usually occurs either immediately the dentures are fitted or following gradual deterioration of the condition of the dentures, some years later. If the wax trial stage has been correctly carried out the patient should have had adequate time to examine and approve the appearance and therefore the finished dentures should be satisfactory. It is possible, though unlikely, that the teeth have moved or other errors have occurred during the flasking and processing procedures. Occasionally the dissatisfaction arises because the patient receives an unfavourable comment about their new teeth from a relative or friend. Whatever the reason, a patient unhappy with the appearance of the teeth is unlikely to persevere with the dentures.

Factors which may detract from the appearance include:

- Unsatisfactory tooth shade, contour or size
- Labio/lingual tooth position leading to incorrect lip support
- Too much/too little length of crown visible – lip coverage
- Poor contour of gingival margins
- Errors in the occlusal vertical dimension

New dentures can greatly enhance the appearance but there are limitations and some patient's expectations may be unrealistic. For example, dentures cannot reverse the ageing process and they cannot eradicate the normal lines and creases in the skin.

Old dentures may have poor aesthetics because of worn or stained teeth and because of loss of lip support as the dentures 'settle' in the mouth following long-term alveolar resorption. Bleaching due to over enthusiastic or incorrect use of cleaning agents will also deleteriously affect both the denture base polymer and the teeth.

### Speech

A new denture may cause a change in the speech patterns although, with adaptation, these usually disappear within a few days. If persistent, it is probably because the shape of the polished surfaces and/or tooth position on the dentures has been changed beyond the adaptive capacity of the individual. In this case, the shape should be compared to the previous denture and, if necessary, consideration given to repositioning the incisors and/or modifying the palatal contours accordingly. The most common complaints relate to the 'S' sound which is dependent on the correct relationship of the tip of the tongue and the palatal aspect of the upper anterior teeth.

### Recurrent fracture of dentures

There are two mechanisms to describe the way dentures can break:

- Impact fracture
- Fatigue fracture

An impact fracture occurs due to a high, short-acting force impacting on the denture such as can occur if the denture is dropped onto a hard surface. This type of fracture can occur at any time in the life of a denture. A fatigue fracture is the result of numerous, relatively low magnitude, repeated forces being applied which eventually cause a small crack, commonly in the midline, which then progresses by crack propagation to ultimate failure. Failure by this



mechanism is common after a period of wear of several years.

Midline fatigue fracture is usually associated with one or a number of the following:

- Median diastema
- Large fraenal notch
- Absence of labial flange
- Wedging action of very worn occlusion
- Inherent weakness following previous repair

It will occur more readily in those with the ability to chew or clench using heavy masticatory loads and in those with bruxism.

A majority of the midline fractures can be avoided by the application of established prosthodontic principles during denture construction. For example, even and adequate bulk of denture base material cured to achieve optimum polymerisation and free of porosity; relief of incompressible tissue in the centre of the hard palate; addition of labial flange to increase rigidity of denture base; even and balanced occlusion to reduce wedging effect and locking of occlusion. Reduction of stress concentrators such as notches and diastema to a minimum would also help prevent these fractures. If notches are to be incorporated, a rounded notch is preferred to a sharp one. Consideration should be given to the use of either a high impact acrylic resin denture base material or a metal (cobalt–chromium) base.

## Retching

A few patients have great difficulty coping with a foreign body in the mouth resulting in retching. Some, those with extreme difficulties, may retch even when an examination mirror is placed between the lips. Most, however, can tolerate instrumentation or a denture in the mouth for varying lengths of time. In the extreme cases there are strong psychological overtones which cannot be overcome simply; however, in others, the design and fit of dentures is the predisposing factor.

The most common cause of retching related to dentures is posterior overextension of the upper or lower denture. The soft palate and posterior areas of the tongue are sensitive to contact causing the protective retching reaction. Thickness of the bases is also relevant as besides encroaching on the tissues it may also lead to tongue cramping. Occasionally, a normally extended or underextended poorly fitting upper denture will cause retching when it drops and contacts the posterior region of the

tongue. The management (modification) of the dentures will depend on the diagnosis and may well include guidance on the wearing of dentures as well as reassurance.

## Burning mouth

A complaint of burning or tingling associated with the oral tissues or lips is referred to as the burning mouth syndrome. It is most common in women who are over 50 years of age. Diagnosis is by a process of elimination since there are numerous potential causative factors. A detailed history and examination will lead to a provisional diagnosis in most cases but it can be very difficult, even with the aid of special tests, to reach a definitive diagnosis in a few cases. Timing and mode of onset should help define if the complaint is related to the provision of a new prosthesis.

Local factors such as denture design (e.g. incorrect occlusal vertical dimension, excessive loading of the supporting tissues, tooth position causing lip/tongue irritation etc.) should be assessed and eliminated. Excessive residual monomer content (more than 1%) due to incomplete curing of the polymethylmethacrylate can lead to chemical irritation with a new or recently relined/rebased denture. This can only be confirmed by chemical analysis of the denture base using, for example, gas chromatography but if suspected the practitioner could request the laboratory to re-process the denture. Other contributory factors include denture-induced stomatitis, a dry mouth (note the variety of causes including pharmacotherapy) and smoking.

Systemic factors include deficiencies that are only evident following blood screening tests for iron, folic acid and the vitamin B complex. Investigations might include: serum iron, serum folate, serum vitamin B<sub>12</sub>, red cell folate as well as the haemoglobin. Anxiety and depression (and their associated pharmacotherapy) should be borne in mind. Close liaison with the general medical practitioner is obviously important.

## Denture Relines

A reline can be described as the addition of material to the existing fitting surface of a denture base. The reline procedure can utilise a permanent or temporary material which could be either hard or soft and which could be applied at the chairside or in the laboratory.

A reline is normally prescribed to improve the fit of an existing denture when the looseness is related to the fitting (impression) surface of the denture. This usually occurs due to alveolar resorption and is therefore time dependent. The denture should be examined to ensure that it is otherwise satisfactory, i.e. the occlusion, occlusal vertical dimension and aesthetics. Deficiencies in the border extension should be corrected using tracing stick impression compound and undercuts removed from the base before the wash impression is taken. The aim is normally to record maximum surface detail without disturbing either the vertical dimension or the occlusion and therefore an impression material such as zinc oxide–eugenol paste or silicone which can be used in thin section is ideal. When recording the impression the borders should be moulded and then the denture brought into occlusion with the opposing natural teeth or denture whilst the material sets. This avoids disturbing the occlusion.

This clinical procedure is the same for both laboratory performed hard and soft relines (and for a rebase which involves removal and replacement of a significant proportion of the old base material).

### Soft lining

A soft lining may be added as a reline procedure for a patient with a history of mucosal discomfort and chronic soreness provided other predisposing factors have been eliminated. To be effective a permanent soft lining should be 2–3 mm thick. The lining acts to absorb part of the force of occlusion, releasing the stored energy as elastic recoil. It also assists in producing an even distribution of functional load over the entire denture-bearing area, avoiding local concentrations of stress. It should therefore increase a patient's ability to use a denture comfortably.

The most effective material is heat polymerised silicone since this has good elastic properties and remains soft. An adhesive is required to ensure an adequate bond to the polymethylmethacrylate denture base material. Plasticised acrylic is an alternative but is less soft than silicone and hardens as the plasticiser leaches out. It does, however, bond chemically to the denture base.

Autopolymerising silicones and plasticised acrylic soft linings are available but their properties do not compare favourably with those of the heat polymerised materials. They can, however, be used at the chairside and are suitable for domiciliary visits if laboratory support is not available.

### Temporary soft lining, tissue conditioners

These only remain soft for a limited period (days to weeks) and can be used when it is necessary to give the supporting tissues an opportunity to recover before fabricating a new denture or permanently relining an existing one. They may also be used as functional impression materials, for immediate denture maintenance, cleft palate speech aids and immediate surgical splints. The powder is a higher methacrylate, e.g. polyethylmethacrylate or copolymers, while the liquid is usually a mixture of ethyl alcohol as solvent and dibutyl phthalate as plasticiser. The alcohol and ester are solvents for the polymer beads, swelling them and allowing the plasticiser to diffuse in and rapidly forming a gel through a physical process. Although initially very soft and fluid, leaching and evaporation of the compounds leads to hardening of the material in the mouth.

### Repairs

The material most commonly employed in the construction of dentures is polymethylmethacrylate. Despite its popularity, the material, although adequate in satisfying aesthetic demands, is far from ideal in fulfilling the mechanical requirements of such appliances. This is reflected in the unresolved problem of denture fracture and the accompanying costs to effect repair.

The causes of denture fracture have been discussed earlier. Although repair of a broken denture should be carried out in the laboratory, to achieve maximum strength, the patient and denture should be examined first clinically. This examination should elicit the cause of the fracture, the health of the oral tissues and the suitability of the denture.

If relatively new and otherwise satisfactory, the denture should be sent for a standard repair. However, if the denture is also loose it may be necessary and appropriate to carry out a reline (or rebase) at the same time as the repair since this will both strengthen the base and improve the fit.

The component parts should be assembled and if there is any doubt about their relocation sticky wax should be used to hold them together so that the denture can be tried in the mouth. This same procedure is necessary before a reline impression although it may be necessary to reinforce across the fracture line using pieces of wire, old burs or even matchsticks.

If the denture is inherently weak due to the design, e.g. no anterior flange on an upper complete denture or a small lower complete denture with a soft lining, then consideration should be given to modifying the denture by adding a flange or incorporating a cast lingual metal plate. The construction of a new denture should be considered.

Fractured metal components may be more difficult to repair. It is not possible to solder new clasps to a cobalt–chromium denture framework. It may be possible to construct a new clasp and retain it within the acrylic saddle region.

## Causes of Denture Intolerance

An inability to cope with dentures can be due either to factors related to the design and construction of the dentures or attributed directly to the patient. A close examination and assessment of the dentures should always be made before putting the blame for failure elsewhere.

There are many possible causes of denture intolerance and often a diagnosis is reached only by a process of elimination. It is important therefore to follow an orderly pattern in the examination of denture and patient. This should always be preceded by a history of the complaint(s) relating it to previous denture experience and the age and general health of the patient.

### Design faults

Many complaints of intolerance can be related to extension of the bases, the occlusal vertical dimension or the relationship of the denture to the neutral zone. Overextension or excessive thickness of the borders is poorly tolerated and, on occasions, can lead to a complaint of retching. It can, of course, also cause discomfort and looseness. The complaint of retching is usually related to the posterior lingual extension of the lower denture and the posterior palatal extension of the upper.

Patients are less likely to cope with dentures with reduced (or negative) freeway space than if there is excessive freeway space. With reduced freeway space they may complain of the dentures feeling too big for their mouth, teeth clattering or meeting too early, generalised discomfort of the denture bearing tissues or pain in the muscles of mastication.

A denture that does not conform with the neutral zone is likely to be displaced in function with the patient complaining of looseness.

Design faults leading to poor aesthetics will, with a discerning patient, lead to rejection of a denture since good appearance is probably the strongest motivating factor for denture wear.

### Adaptive capacity

The capacity of an individual to adapt to change may be determined by a number of factors including age and general health. Chronological age is less relevant than biological age since a sprightly, mentally active older person is more likely to be adaptive than a biologically old younger individual.

Adaptive capacity will also depend on general health and is reduced in chronic or debilitating conditions. The after effects of cerebrovascular accidents can severely handicap adaptation leading to considerable difficulties with dentures.

Even a normally adaptable individual can have difficulty meeting the demands of excessive changes in design if a new denture differs markedly from the old. For example, an individual having worn the same under extended dentures for more than 20 years and having become accustomed to the gradual loss of occlusal vertical dimension with resultant gross overclosure, due to wear of the teeth and alveolar resorption, is perhaps unlikely to adapt to the sudden change to 'textbook' dentures fully extended and with the average 3 mm of freeway space.

### Personality and mental attitude

Most patients cope well with complete dentures even when the dentures are perhaps less than ideal. There are, however, some who are fussy and demanding with a high level of expectation. These individuals can usually be satisfied provided adequate time and appropriate expertise is devoted to them. Unfortunately, there are a few who are obsessive and often illogical in their attitude to denture treatment who cannot be satisfied. These individuals may seek treatment from a number of different practitioners but continue to find fault with all the prostheses and to place the blame on anyone or anything other than themselves.

### Lack of motivation

As has already been stated, most edentulous patients are strongly motivated to wear dentures to maintain or improve their appearance. Many, of course, also gain from the improvement in masticatory function. However, there are those who can cope with their

diet perfectly adequately without teeth and who are not unduly concerned with their appearance. These individuals may be put under pressure from relatives or health workers to have dentures. In some cases they have been without teeth or dentures for years and it is unlikely that they will put sufficient effort into wearing dentures to give much chance of success.

### Chronic alcohol abuse

Patients with a known history of alcoholism often do not tolerate dentures well. They may complain of retching whenever the dentures are inserted and may not persevere in order to learn control of the dentures. This link between retching and alcoholism may be due to the condition of gastritis which is common.

## Soft Tissue Pathology Related to Wearing Dentures

### Traumatic ulceration

This is the most common pathology resulting from wearing dentures. This can occur during the first few days when new dentures are worn usually because of areas of overextension, traumatic contact (in relation to undercuts) or irritation from sharp or rough areas of the fitting (impression) surface. Ulceration can also occur when a denture becomes loose and ill fitting. When the source of irritation is removed the ulcer should heal within a few days. If it persists the area should be further inspected and, if necessary, biopsied.

### Denture-induced stomatitis

This occurs mainly in the maxilla and is more common in females. It is a chronic irritation of the denture-bearing tissues causing the mucosa to appear bright red. Most patients are unaware of its presence since it is normally asymptomatic. A number of factors are believed to contribute to the condition:

- *Candida albicans*
- Denture wearing habits
- Fit of the denture
- Excess residual monomer
- General health

### *Candida albicans*

Poor oral and denture hygiene allows plaque and food deposits to accumulate with an associated

overgrowth of the mycelial and yeast forms of the fungus on both the tissues and denture base.

### Denture wearing habits

When dirty dentures are worn day and night the tissues are in constant contact with the infected denture bases and the condition will be aggravated.

### Fit of the denture

Mechanical trauma from rough or ill-fitting dentures tends to irritate the tissues and make them more susceptible to candidal infection.

### Excess residual monomer

It is possible that the residual monomer will chemically irritate the tissues and increase their susceptibility to infection.

### General health

Systemic factors such as deficiencies of the vitamin B complex, iron and folic acid and immunological defects should be borne in mind especially in those resistant to normal treatment regimes.

### Treatment

The treatment of the condition can be summarised under three headings:

- Improved oral hygiene
- Modifications to the fit of the denture
- Antifungal therapy

Advice should be given on denture hygiene and cleaning (see Chapter 26) and the patient requested to leave the dentures out during the night. A hypochlorite solution is probably the most effective cleaner for plaque removal and for sterilisation of the denture base. A poorly fitting denture can be modified using a hard or soft chairside lining material (see section on relines). Antifungal therapy is directed locally using Nystatin tablets (500,000 units) or amphotericin B lozenges (10 mg) dissolved in the mouth four times a day for up to 2 weeks or by the use of miconazole oral gel (25 mg/mL) which can be smeared on the fitting surface of the denture.

### Other conditions

*Angular stomatitis* is an inflammatory, and sometimes erosive, condition which occurs in the folds at the corners of the mouth. It is usually seen in association with denture-induced stomatitis and the presence of

*Candida albicans* should therefore be suspected. Secondary bacterial infection can occur; also, *Staphylococcus aureus* is claimed to be a causative organism of the lesion even in the absence of *Candida albicans*. Inadequate lip support or insufficient occlusal vertical dimension from the dentures may lead to the development of folds at the corners of the mouth which, due to saliva moistening them, can be susceptible to infection. Initial treatment is based on that prescribed for denture-induced stomatitis; miconazole oral gel is probably the most effective agent since it is both antifungal and antibacterial. Modifications may be required to the dentures to improve lip support and occlusal vertical dimension. If the lesion is resistant to therapy the possibility of an underlying associated deficiency (e.g. iron, or vitamin B or C) should be investigated.

*Papillary hyperplasia* of the palate is an inflammatory lesion which presents as multiple small nodules of granulation tissue. It usually occurs in the central portion of the palate and can correspond to the area underlying a relief chamber. Causative factors include chronic irritation from the denture and a superimposed denture-induced stomatitis. Again, treatment is first aimed at improving the oral hygiene and reducing irritation. Surgical treatment is probably only required in extensive cases or if there is doubt about its benign nature.

Denture-induced hyperplasia is an overgrowth of granulation tissue usually associated with the borders of ill-fitting dentures. Trauma from the borders causes recurrent ulceration and healing with resultant

growth of fibrous tissue. This can present as a fold or multiple folds of tissue and is more common in the lower jaw associated with the buccal and labial borders. Treatment is aimed first at eliminating the source of irritation by substantially reducing the border of the denture or by persuading the patient not to wear the denture (not always acceptable). Temporary lining of the denture may also be appropriate in order to improve the fit and stability. Since there is an inflammatory component to this pathological process these measures should allow a regression in size of the lesion due to the resolution of the inflammatory process. The resultant lesion may then be sufficiently small to allow routine prosthetic treatment to be continued however more extensive lesions, which would interfere with the construction of dentures, may require surgical excision.

### Oral carcinoma

Whilst this pathology is not related to denture wearing it is important to remember the role of the dentist in identifying early lesions of the oral mucosa and lips. Discomfort, ulceration and/or loose dentures might relate to a soft tissue lesion. As was stated above any ulceration that does not heal quickly should be investigated further.

Regular recall of complete denture wearers is not routine. After the first review the patient, if satisfied, is discharged. To be able to make an early diagnosis of silent lesions, a yearly examination should be arranged.

# Bibliography

This lists some current textbooks on the individual principal subjects of *restorative dentistry* together with selected papers. Some of the papers are of considerable historical significance whilst others deal with the ‘state of the art’.

## The Patient

### Texts

British National Formulary (2007) BMJ Publishing Group Ltd, London.

Scully C, Cawson R (2004) *Medical problems in dentistry*, 5th edn. Wright, Oxford.

### Guidance

British Dental Association (2003) *Infection control in dentistry*. Advice Sheet A12.

National Institute for Clinical Excellence (2004) *Dental recall*. Clinical guideline 19.

## Radiology and Radiography

### Text

Whaites E (2007) *Essentials of dental radiography and radiology*, 4th edn. Churchill Livingstone, Edinburgh.

### Guidance and legislation

Faculty of General Dental Practitioners (UK) (2005) *Selection criteria in dental radiography*, 2nd edn. Faculty of General Dental Practitioners, London, UK.

Health Protection Agency (2001) *Guidelines on radiology standards in primary dental care*. Health Protection Agency, London, UK.

Ionising Radiation (Medical Exposure) Regulations (2000) (IRMER).

## Anaesthesia, Analgesia and Sedation

### Texts

Girdler NM, Hill M (1998) *Sedation in dentistry*. Wright, Oxford.

Hill CM, Morris PJ (1991) *General anaesthesia and sedation in dentistry*. Wright, Oxford.

Meehan JG *et al.* (1998) *Pain and anxiety control for the conscious dental patient*. Oxford University Press, Oxford.

Robinson PD, McDonald F (2001) *Local analgesia in dentistry*, 4th edn. Wright, Oxford.

## Trauma

### Text

Andreassen JO, Andreassen FM (2000) *Essentials of traumatic injuries of the teeth*. Munksgaard, Copenhagen.

## The Restoration and its Environment

## Oral Biology and Pathology

### Texts

Berkowitz B *et al.* (2003) *Oral anatomy, histology and embryology*, 3rd edn. Mosby, St Louis.

Kidd EAM (2005) *Essentials of dental caries: the disease and its management*, 3rd edn. Oxford University Press, Oxford.

## Periodontology

### Text

Lindhe J *et al.* (2003) *Clinical periodontology and implant dentistry*, 4th edn. Blackwell-Munksgaard, Oxford.

### Papers

Hassell TM (ed) (1993) *Periodontal tissues – structure and function, Vol. 3: Periodontology 2000*. Munksgaard, Copenhagen.

Lang NP, Karring T (eds) (1994) *Proc 1st European workshop on periodontology*. Quintessence Publishing, London.

Lang NP, Karring T (eds) (1997) *Proc 2nd European workshop on periodontology*. Quintessence Publishing, London.

*World workshop in periodontics* (1996) Vol. 1, No 1. American Academy of Periodontology, Chicago.

## Occlusion

### Texts

Ash MM, Ramfjord S (1995) *Occlusion*, 4th edn. Saunders, Philadelphia.

Kleinberg I (1991) *Occlusion: principles and assessment*. Wright, Oxford.

### Papers

Alexander PC (1965) The periodontium and the canine function theory. *J Prosthet Dent* 18:571–577.

Bennett NG (1908) A contribution to the study of the movement of the mandible. *Trans R Soc Med* 1:77–84.

Beyron HL (1969) Optimal occlusion. *Dent Clin North Am* 13:537–542.

- Celenza FV (1973) The centric position: replacement and character. *J Prosthet Dent* 30:591–595.
- Chasens AI (1990) Controversies in Occlusion. *Dent Clin North Am* 34:111–123.
- D'Amico A (1961) Functional occlusion of the natural teeth of man. *J Prosthet Dent* 11:899–915.
- Denbo J (1990) Malocclusion. *Dent Clin North Am* 34:103–109.
- Jent T, Lundquist S, Hedegard B (1982) Group function or canine protection. *J Prosthet Dent* 18:719–720.
- Lauritzen AG, Bodner GH (1961) Variations in location of arbitrary and true hinge axis points. *J Prosthet Dent* 11:224–229.
- Lindhe J, Nyman S (1977) The role of occlusion in periodontal disease and the biologic rationale for splinting in the treatment of periodontitis. *Oral Sci Rev* 10:11–17.
- Posselt U (1957) Movement areas of the mandible. *J Prosthet Dent* 7:375–379.
- Schuyler SH (1969) Freedom in centric. *Dent Clin N Am* 13:681–685.
- Stuart CE, Stallard H (1960) Principles involved in restoring occlusion to natural teeth. *J Prosthet Dent* 10:304–313.

## Restorative Dental Biomaterials

### Texts

- Anusavice KJ (2003) *Phillips' science of dental materials*, 11th edn. Elsevier, Oxford.
- McCabe JF, Walls A (2007) *Applied dental materials*, 9th edn. Blackwell-Munksgaard, Oxford.

### Papers

- Chadwick BL *et al.* (2001) *Longevity of dental restorations – a systematic review*. NHS Centre for Reviews and Dissemination, York.
- European Commission (1998) *Dental amalgam*.
- Jacobsen PH (1987) Biological and clinical testing of materials. *J Dent* 15:266–268.
- Jacobsen PH (1988) Design and analysis of clinical trials. *J Dent* 16:215–218.

## Clinical Management and Techniques

### Intracoronal Restorations

#### Texts

- Kidd EAM, Smith BGN (2003) *Pickard's manual of operative dentistry*, 8th edn. Oxford University Press, Oxford.
- Roulet J-F, Herder S (1991) *Bonded ceramic inlays*. Quintessence, Chicago.

#### Papers

- Burke FJT, Qualtrough AJE (1993) Aesthetic inlays: composite or ceramic. *Br Dent J* 176:53–59.
- Jacobsen PH, Rees JS (1992) Luting agents for ceramic and polymeric inlays and onlays. *Int Dent J* 42:145–149.
- Rees JS, Jacobsen PH (1996) Restoration of teeth with composite resin 1: direct-placement composite. *Dent Update* 23:406–410.
- Rees JS, Jacobsen PH (1996) Restoration of teeth with composite resin 2: indirect-placement composite. *Dent Update* 24:25–30.

## Management of Deep Caries

- Brannstrom M, Isaacson G, Johnson G (1976) Effect of calcium hydroxide and fluorides on human dentine. *Acta Odontol Scand* 34:59–66.
- Kidd EAM, Joyston-Bechal S, Beighton D (1993) The use of a caries detector dye during cavity preparation: a microbiological assessment. *Br Dent J* 174:245–248.
- Oligushi K, Fusayama T (1975) Electron microscope structure of the two layers of carious dentine. *J Dent Res* 54:1019–1026.
- Outhwaite WC, Garman TA, Pashley DH (1979) Pins v slot retention in extensive amalgam restorations. *J Prosthet Dent* 41:396–400.

## Endodontics

### Texts

- Cohen S, Burns RC (2006) *Pathways of the pulp*, 9th edn. Mosby, St Louis.
- Pitt-Ford TR (2004) *Harty's endodontics in clinical practice*, 5th edn. Wright, Oxford.

### Guidelines

- European Society of Endodontics (2006) Consensus report of the European Society of Endodontology on quality guidelines for endodontic treatment. *Int Endod J* 39:921–930.

### Papers

- Bonsor SJ *et al.* (2006) Microbiological evaluation of photo-activated disinfection in endodontics (an in vivo study). *Br Dent J* 201:114–117.
- Saunders WP, Saunders EM (1994) Coronal leakage as a cause of failure in root canal therapy: a review. *Endod Dent Traumatol* 10:105–108.
- Zehnder M (2006) Root canal irrigants. *J Endod* 32:389–398.

## Crowns

### Papers

- Cheung GSP (2005) Fate of vital pulps beneath a metal-ceramic crown or a bridge retainer. *Int Endod J* 38:521–530.
- Jacobsen PH *et al.* (2006) The effect of preparation height and taper on cement lute thickness: a three-dimensional finite element analysis. *Eur J Prosthodont Rest Dent* 14:151–157.
- Jorgensen KD (1955) The relationship between retention and convergence angle in cemented veneer crowns. *Acta Odontol Scand* 13:35–40.
- McAndrew R, Jacobsen PH (2002) The relationship between crown and post design on root stress – a finite element study. *Eur J Prosthodont Rest Dent* 10:9–13.
- McLean A (1998) Predictably restoring endodontically treated teeth. *J Can Dent Assoc* 64:782–787.
- Nayyar A *et al.* (1980) An amalgam coronal dowel and core technique for endodontically treated posterior teeth. *J Prosthet Dent* 43:511–515.

## Colour and Aesthetics

### Text

Ahmad I (2006) *Protocols for predictable aesthetic dental restorations*. Blackwell, Oxford.

## Bridgework

### Texts

Rosenstiel SF *et al.* (2006) *Contemporary fixed prosthodontics*, 4th edn. Mosby, St Louis.

Shillingburg HT *et al.* (1997) *Fundamentals of fixed prosthodontics*, 3rd edn. Quintessence, London.

### Papers

Ante IH (1926) The fundamental principles of abutments. *Mich State Univ Soc Bull* 8:24–28.

Eshleman JR *et al.* (1988) Tooth preparation designs for resin bonded fixed partial dentures related to enamel thickness. *J Prosthet Dent* 60:18–22.

Livaditis GJ, Thompson VP (1982) Etched castings: an improved retentive mechanism for resin-bonded retainers. *J Prosthet Dent* 47:52–57.

Nyman S, Ericsson I (1982) Capacity of reduced periodontal tissues to support fixed bridgework. *J Clin Periodontol* 9:409–412.

Rochette AL (1973) Attachment of a splint to enamel of lower anterior teeth. *J Prosthet Dent* 30:418–422.

## Implants

### Texts

Palacci P, Ericsson I (2000) *Esthetic implant dentistry: soft and hard tissue management*. Quintessence, London.

Palmer R (2000) *A clinical guide to implants in dentistry*. BDA Books, London.

Sclar AG (2003) *Soft tissue and esthetic considerations in implant therapy*. Quintessence, London.

Sethi A, Kaus T (2005) *Practical implant dentistry: diagnostic, surgical, restorative and technical aspects of aesthetic and functional harmony*. Quintessence, London.

### Papers

Davies JE (2003) Understanding peri-implant endosseous healing. *J Dent Ed* 67:932–949.

Koka S (1998) The implant–mucosal interface and its role in the long-term success of endosseous oral implants: a review of the literature. *Int J Prosthodont* 11(5):421–432.

Quirynen M, De Soete M, van Steenberghe D (2002) Infectious risks for oral implants: a review of the literature. *Clin Oral Implants Res* 13:1–19.

## Removable Prosthodontics

### Texts

Basker RM, Davenport JC (2002) *Prosthetic treatment of the edentulous patient*, 4th edn. Blackwell, Oxford.

Davenport JC (2000) *A clinical guide to removable partial dentures*. British Dental Association, London.

### Paper

Kanno T, Carlsson GE (2006) A review of the shortened dental arch concept focusing on the work by the Kayser/Nijmegen group. *J Oral Rehabil* 33:850–862.

## Problems

### Tooth surface loss

#### Papers

Dahl BL *et al.* (1975) An alternative treatment of cases with advanced localised attrition. *J Oral Rehabil* 2: 209–214.

Milosevic A (1999) Eating disorders and the dentist. *Br Dent J* 186:109–113.

Poyser NJ *et al.* (2005) The Dahl concept: past, present and future. *Br Dent J* 198:669–676.

Shaw L, Smith AJ (1999) Dental erosion – the problem and some practical solutions. *Br Dent J* 186:115–120.

### Temporomandibular dysfunction

Feinmann C, Harris M (1984) Psychogenic facial pain. *Br Dent J* 156:165–170, 205–209.

Gray RJM *et al.* (1995) *Temporomandibular disorders: a clinical approach*. British Dental Association, London.

Greene CS, Laskin DM (1972) Splint therapy for myofascial pain dysfunction syndrome: a comparative study. *J Am Dent Assoc* 84:624–628.

Solberg WK (1986) *Temporomandibular disorders*. British Dental Association, London.

### Failures in the Restored Dentition

#### Text

Grant AA, Heath JR, McCord JF (1994) *Complete prosthodontics: problems, diagnosis and management*. Wolfe, London.

#### Papers

Bader JD *et al.* (1998) Meta-analysis of fixed partial denture survival: prostheses and abutments. *J Prosthet Dent* 79:459–464.

Cheung GSP, Dimmer A, Mellor R, Gale M (1990) A clinical evaluation of conventional bridgework. *J Oral Rehabil* 17:131–136.

Creugers NHJ, Kayser AS (1992) An analysis of multiple failures of resin bonded bridges. *J Dent* 20:348–351.

Karlsson S (1986) A clinical evaluation of fixed bridges 10 years following insertion. *J Oral Rehabil* 13: 423–429.

Tan K *et al.* (2004) A systematic review of the survival and complication rates of fixed partial dentures (FPD's) after an observation period of at least five years III conventional FPD's. *Clin Oral Impl Res* 15:654–666.

Randow K, Glantz P-O, Zoger B (1986) Technical failures and some related clinical complications in extensive fixed prosthodontics. *Acta Odont Scand* 44:241–247.





# Index

- Abrasion resistance of materials, 75, 77, 78
- Adhesion and adhesives, 83–85  
bond strength testing, 85–86  
cements, 189  
clinical applications  
cores, 110  
intracoronar cavities, 88  
resin-retained bridgework, 216  
veneers, 181  
conditioners, 83  
physical and chemical properties, 83–85  
systems, 83
- Aesthetics, 88, 175–186  
colour, 175–177,  
dentures, 271  
in crown and bridgework, 158, 171, 224, 227, 232, 233, 234  
in implants, 250–252
- Age changes in dentition, 28, 42
- Allergy, 8  
antibiotics, 127  
cements, 94
- Alloys  
bridgework, 188–9  
ceramic bonding, 164–165  
Alveolar bone, 54  
resorption, 204–207
- Amalgam, 95, 102, 110  
carving, 105  
condensation, 105  
core placement, 113–114  
corrosion, 18, 81, 259  
creep, 77, 81, 246  
mixing, 104  
physical properties, 76  
polishing, 105  
proportioning, 104  
toxicity, 86
- Amelogenesis imperfecta *see* Tooth surface loss
- Anaesthesia, general, 25
- Analgesia, 124, 257
- Antibiotics, 126–7  
allergy, 127  
prophylactic, 9  
systemic, 20, 119, 127
- Apical pathology, 53–54, 266  
abscess, 20  
cyst, 20, 53  
diagnosis, 18–20  
granuloma, 20, 53  
infection, 7, 53  
perforation, 109  
treatment, 20
- Apical surgery, 129–133  
flap design, 133  
indications, 129  
review, 132  
technique, 130–132  
through and through, 132
- Apprehension, 26–27
- Articulators, 144–147  
*see also* Occlusion
- Bacterial endocarditis, 28
- Basic Periodontal Examination (BPE), 9–10
- Biological compatibility of materials, 81
- Bleaching, 178–179
- Blood dyscrasias, 27
- Blood tests, 11
- Bridgework, conventional, 217–225  
*See also* resin-retained bridgework, implants  
abutment tooth assessment, 223  
aesthetics, 220–221, 224  
anterior, 234–239  
biological factors, 217–218  
cantilever, 210, 317  
cementation, 233  
clinical procedures, 226–239  
connectors, 210, 219, 220  
contact areas, 222  
definitions, 210  
design, 217–221  
failures, 316–320  
fitting, 231–233  
indications, 201–204  
mechanical factors, 218–220  
occlusal registration, 229, 230  
occlusion, 151–152, 153, 222, 232, 233  
path of insertion, 218, 219, 220, 227, 229  
pontics, 210, 221, 222  
precision retainers, 224–225, 238, 239, 289  
preoperative considerations, 221–224  
diagnostic articulation, 222  
preparations, 227–229  
problems, 203  
provisional, 226–228  
relocalisation, 230–231  
review, 233  
spring cantilever, 210  
stages in construction, 226  
treatment planning, 201–207  
try-in, 229, 231–233
- Bruxism, 296, 307
- Burning mouth, 324
- Burs, 99
- Calcium hydroxide  
liners, 101  
root canal dressing, 22, 125  
*Candida albicans*, 327–328
- Cardiovascular conditions, 28
- Caries, 46–52  
aetiology, 15–16, 46–48  
approximal, 89–90, 91  
cervical, 92–3  
coronal, 51  
deep lesion, management of, 99–104  
dentine, 48–50  
diagnosis, 14–16  
early (white spot) lesion, 49, 51  
enamel, 49–51  
excavation, 51–2  
fissure, 50  
microorganisms, 46–47, 52  
occlusal, 89  
pathology, 44–52  
progression, 44, 48  
pulpal response, 50–1  
rate, 15  
recurrent, 10, 266  
remineralization, 44, 51, 91  
research techniques, 48–49  
ground sections, 48  
microbiopsy, 49  
microradiography, 49  
scanning electron microscopy, 49  
transmission electron microscopy, 49
- root, 51  
stabilisation, 19  
symptoms, 6  
treatment, 96–99  
tooth susceptibility, 48

- Cavity preparation  
 for amalgam, 85–6, 91–2  
 for composite, 85–6, 88  
 margin finishing, 93  
 preventive resin restoration, 88, 89, 90  
 principles of, 85–6
- Cementation, 187–8, 210–11  
 failure, 265–6  
*see also* Cements
- Cements  
 bases, 101–102  
 cementation, 172–173, 233  
 liners, 101, 102  
 luting agents, 173  
 physical properties, 76
- Cementum, 42, 54
- Centric occlusions *see* Occlusion
- Centric relation *see* Occlusion
- Ceramics, dental  
 bonding alloys, 164–165  
 castable, 163  
 colour, 157–9  
 core shine, 182  
 corrosion, 81  
 crowns, 163–165  
 fractured, 267  
 inlays, 92, 106  
 milled, 164  
 strengthening, 163–165  
 veneers, 179–181, 187
- Charting, 11  
 dental, 11  
 periodontal, 11
- Cleft palate, 225
- Clinical examination, 9–11
- Clinical trials of materials, 86
- Colour, 175–186
- Colour stability of materials, 81
- Complete dentures, 278–290  
 construction, 279–285  
 duplication (copy dentures), 285–286  
 immediate dentures, 286  
 ovedentures, 286–290  
 retention, 278  
 stability, 279  
 support, 278
- Compomers, 94, 95
- Composites, 92–93, 102  
 adhesion, 88  
 clinical indications, 92, 96, 98, 101  
 colour stability, 77  
 fluoride leach, 88  
 handling, 82, , 83, 99, 103–104  
 inlays, 88, 105–106  
 light curing, 93–94, 88  
 metal reinforced, 110  
 properties, 76, 77, 80, 81, 92–93, 94, 95  
 technique, 103–104
- Consent to treatment, 26
- Continuing care, 31
- Corrosion of materials, 18, 81
- Cracked tooth syndrome, 310–311
- Creep of materials, 77, 246
- Cross-infection prevention, 29, 173
- Crowns, 157–174  
 cementation, 172–173  
 choice of material, 163–166  
 errors, 165  
 margins, 160–161, 166  
 metal-ceramic, 164–166  
 multiple, 50, 298–299  
 occlusion, 162  
 post, 168–171, 312–314  
 principles of preparation, 158–163  
 provisional, 171  
 root filled teeth, 166–171  
 stability, 159  
 treatment planning, 157–158, 298
- Dahl, 300
- Deep carious lesion, 107–114  
 diagnosis, 107  
 direct pulp cap, 109  
 indirect pulp cap, 108  
 management, 107–109  
 photo-activated disinfection, 108  
 postoperative assessment, 109  
 pulp assessment, 107  
 restoration, 110–114  
*see also* Caries; Root canal treatment
- Dentine, 37–39  
 age changes, 42  
 bonding agents, 79–80  
 caries, 48–50  
 formation, 37–39  
 hypersensitivity, 6  
 mineralization, 38  
 odontoblasts, 38, 36  
 physical properties, 71  
 pins, 111  
 secondary, 38, 42, 44, 49–50  
 sensitivity, 38–39, 44–45  
 structure, 37  
 tertiary, 49–50  
 tubules, 36, 38, 49
- Dentinogenesis imperfecta *see* Tooth surface loss
- Dentist  
 abilities, 4, 26  
 facilities, 180
- Denture problems, 322–328  
*See also* Complete dentures, Partial dentures  
 aesthetics, 323  
 burning mouth, 324  
 carcinoma, 328  
 denture intolerance, 326–327  
 design faults, 326  
 looseness, 322  
 pain/discomfort, 322  
 recurrent fracture, 323  
 relines, 324–325  
 repairs, 325  
 retching, 324  
 soft lining, 325  
 soft tissue pathology, 327  
 speech problems, 323
- Diabetes, 8, 29
- Diagnosis, 15–21  
 apical pathology, 18–20  
 caries, 16–17  
 confirmation, 15  
 occlusal disorders, 20  
 periodontal disease, 20, 135–138  
 prosthodontics, 199–209  
 provisional, 18–19  
 pulpal disorders, 17–18  
 restorations, 16  
 root canal treatment, 105–8
- Diet  
 analysis, 15  
 in caries, 15, 47–48  
 in tooth surface loss, 246–7
- Dimensional changes of materials, 80, 195
- Discoloured teeth, 177–178  
 management, 17–181  
 bleaching, 178–179  
 microabrasion, 178  
 veneers, 179–181
- Dislocation  
 of teeth, 23  
 of temporomandibular joint, 253
- DMF index, 15
- Ductility of metals, 75
- Enamel, 35–37  
 age changes, 42  
 ameloblasts, 37  
 aprismatic enamel, 37  
 bonding agents, 79–80  
 caries, 47–48  
 early (white spot) lesion, 47–48, 51  
 formation, 37  
 hypoplasia, 177, 178  
 incremental lines, 37  
 ionic exchange, 37  
 matrix, 35, 37

- physical properties, 71  
prisms, 35, 36, 41  
remineralization, 42  
restorative implications, 41–43  
structure, 37–39  
surface, 37, 44
- Enamel-dentine junction, 39
- Epilepsy, 27
- Examination  
clinical, 9–11  
complete dentures, 280  
extraoral, 9  
partial dentures, 263  
intraoral, 9
- Extractions, 31, 138, 184, 280
- Facebow, 145
- Failures in fixed restorations, 310–321  
cementation failure, 316, 318  
cracked tooth syndrome, 310  
dentine pins, 311, 317  
fixed prosthodontics, 316–320  
fractured ceramic, 317–318  
intracoronar restorations, 85, 310  
management of failed bridge, 318–320  
medico-legal aspects, 321  
non-vitality, 317  
obsessive patient, 320  
occlusion, 317, 246  
post crowns, 311–316  
fractured posts, 315–316  
lateral perforation, 311–314  
Masserann kit, 315–316  
vertical fracture, 315  
recurrent caries, 317  
WAMkeys, 319  
wear and tear, 318
- Family and social history, 8
- Fracture toughness of materials, 75
- Freeway space, 67
- Full mouth reconstruction, 298–299
- Gastric reflux, 247
- General anaesthesia, 27
- Gingiva, 53–4
- Gingival retraction cord, 168, 169
- Gingivitis, 57–59  
acute, 17, 22  
aetiology, 57  
chronic marginal, 20  
clinical features, 57  
definition, 57  
epidemiology, 58  
modifying factors, 58  
pathogenesis, 58  
plaque formation, 57  
prevention, 58–59
- Glass ionomer cement, 93–95, 110  
adhesion, 88  
clinical indications for use, 94, 110  
fluoride leach, 82, 94  
handling characteristics, 97  
properties, 71, 88  
resin-modified, 88, 93–94, 95
- Glenoid fossa *see* Temporomandibular joint
- Gold  
ceramic bonding alloys, 164–165  
crowns, 161–163  
inlays, 92, 96, 105  
properties, 76
- Haemophilia, 27
- Handling characteristics of materials, 82–83  
amalgam, 104–105  
composite, 103–104  
glass ionomer cements, 104  
mixing, 82  
setting time, 83  
working time, 83
- Hardness of materials, 76, 78
- Hepatitis B, 29
- Hinge axis *see* Occlusion
- History taking, 5–8  
dentures, 263, 279
- Human immunodeficiency virus (HIV), 29
- Hypodontia, 225
- Immediate dentures, 286
- Implants, 240–262  
aesthetics, 250–252  
anatomy, 245  
basic principles, 240–248  
bone structure, quantity and quality, 204, 206, 246  
bone augmentation, 256  
bone-implant interface, 247  
cement-retained prosthesis, 242  
clinical cases, 262  
clinical review, 258  
complications, 257–258  
contraindications, 249–250  
emergence profile, 206, 253  
external connection type, 241  
failure, 243–244  
guided bone regeneration, 257  
history, 240  
immediate placement, 244, 245  
implant-mucosal interface, 248–249  
indications, 208, 249  
materials, 242  
osseointegration, 243  
overdentures, 261, 262  
peri-implantitis, 258  
placement techniques, 242–243  
platform switching type, 241  
position, 253–255  
radiographic assessment, 247  
screw-retained prosthesis, 241  
soft tissue augmentation, 257  
survival studies, 261  
terminology, 240  
tissue augmentation, 256–257  
treatment planning
- Impression techniques and materials, 187–196  
addition cured silicones, 188–189  
assessment, 194  
classification, 189  
clinical techniques, 192–194  
components, 189  
condensation cured silicones, 188, 189  
decontamination, 194  
electrosurgery, 191  
gingival management, 190–191  
handling, 192–194  
materials, 187–190  
partial dentures, 273–275  
polyethers, 189  
polysulphides, 189–190  
properties, 187  
requirements, 187  
special trays, 191, 192, 193, 226, 281  
syringe, 192
- Indices  
BPE (CPITN), 9–10  
DMF, 15  
oral hygiene, 10
- Infrabony pockets, 17, 18
- INR, 11–12
- Instrumentation, 112–113  
in cavity preparation *see* Burs fractured, 126
- Intracoronar restorations, 91–106, 108–114  
anterior, 99–100  
approximal caries, 96–101  
cavity design and preparation, 91–92, 96–99  
cavity finishing, 93  
ceramic inlays, 92, 106  
choice of material, 92–96  
composite inlays, 92, 96  
composite restoration, 92, 96, 99, 103  
cracked tooth syndrome, 260

- Intracoronar restorations (*cont.*)  
 glass ionomer cement restoration,  
   99, 102  
 gold inlays, 92, 96, 105  
 indications for treatment, 91  
 linings, 101  
 matrices, 102  
 preventive resin restoration, 97  
 stability, 92, 134  
 tunnel preparation, 98
- Isolation, 108
- Light curing  
 composite, 92  
 liners, 102
- Lining materials  
 bases, 101–102  
 liners, 102  
 varnishes, 82
- Mandibular guidance *see* Occlusion
- Mastication  
 neural control, 72  
 cycle, 73  
 innervation, 67, 68  
 muscles, 64, 144  
 physiology, 71–72
- Materials *see* Restorative materials
- Matrices, 102–103  
 for amalgam, 102–103  
 wedges, 103
- Medical history  
 influence on treatment planning,  
   28–30  
 influence on implants, 249–250  
 influence on periodontal  
   management, 137, 138  
 taking, 7–8
- Medico-legal problems, 313, 321
- Microabrasion, 178
- Microleakage, 82, 86
- Microradiography, 48
- Model construction, 195
- Modulus of elasticity, 75–78
- Mouthrinses, 125
- Occlusal management, 143–156  
 analysis, 143–150  
 articulators, 144–146  
 confirmation of articulation, 149  
 deprogrammer, 149  
 equilibration, 152, 154, 222,  
   307–308  
 equipment, 144–147  
 errors in articulation, 149–150  
 facebows, 145–146  
 partial dentures, 263  
 principles of treatment, 150–156  
 reconstruction, 150,  
 records, 146–147, 172  
   copings, 230  
   dynamic, 147  
 splints, 305–307  
 surface loss, 295–301  
*see also* Occlusion;  
   Temporomandibular  
   dysfunction
- Occlusion  
 analysis, 143–145  
 centric occlusion, 65–66, 128, 144,  
   146,  
 centric relation, 66–67, 128–9, 144,  
   146  
 clinical examination, 11, 128, 143,  
   216–17  
 cusp/fossa relationship, 65–67, 143  
 definition, 62  
 disorders, 163–4  
 diagnosis, 18  
*see also* Temporomandibular  
   dysfunction  
 functional anatomy, 62–71  
 hinge axis, 65, 130  
 incorrect, 317  
 influence on treatment planning, 30  
 interferences, 143  
 mandibular displacement, 67, 143  
 mandibular guidance, 69–71  
   condylar, 69  
   tooth, 69  
     anterior, 66  
     canine, 70, 153  
     group function, 70  
     incisal, 70, 152  
     posterior, 69  
 muscles of mastication, 64, 144  
 parafunction, 71  
 Posselt's envelope, 65, 66  
 premature contacts, 68, 69  
 registration, 152, 207–8, 227, 235  
 retruded arc of closure, 67, 143  
 retruded contact position, 67, 143  
 side-shift, 70  
 stability, 134–5, 136, 199  
*see also* Occlusal management
- Oral hygiene, 8, 20, 24, 25, 30, 31,  
   57, 58, 61, 139  
 in bridgework, 181, 209  
 indices, 10  
 influence on treatment planning, 30  
 instruction, 22  
 in intracoronar restorations, 91  
 review, 29
- Orthodontics, 162–3  
 pre-bridgework, 193, 196
- Overdentures, 286–290, 301
- Pain  
 in apical disorders, 7  
 atypical facial, 7  
 in caries, 7  
 dentures, 270  
 diagnosis, 7  
 evaluation of, 5–7  
 neural mechanisms, 19  
 in periodontal disease, 7  
 in pulpal disorders, 6–7  
 trigeminal neuralgia, 7  
*see also* Analgesia
- Partial dentures, 263–272, 273–277  
 clasps, 267–269  
 clinical procedures, 273–277  
 connectors, 264, 266, 270, 271  
 crowns, 270  
 design, 142, 264–266, 271  
 diagnosis and treatment planning,  
   263–264  
 free-end saddle, 274–275  
   altered cast technique, 275  
 insertion, 276–277  
 materials, 266  
 occlusal registration, 275  
 path of insertion, 265–266  
 preliminary impressions, 273  
 problems,  
   reline, 276–277  
 review, 277  
 RPI system, 272  
 secondary (working) impressions,  
   274  
 surveying, 264–266, 269  
 try-in, 275–276  
 undercut gauges, 268
- Patient  
 aspirations, 3–4  
 influences on treatment planning,  
   25–26, 123–4, 180  
 motivation, 3, 25–26, 141  
 obsessive, 269  
 previous experience of dentistry,  
   3, 8
- Perforation of root  
 apical, 109  
 lateral, 113  
 repair, 113
- Periapical infection, 53–54  
 cyst formation, 54
- Periodontal disease, 7, 17, 18, 20,  
   54–57, 56–60, 135–142,  
   199, 266–267  
 aetiology, 56–7  
 bone loss, 181–2  
 periodontitis, 59  
 definition, 59  
 clinical features, 59

- clinical management, 135–139  
 guided tissue regeneration, 140  
 maintenance, 141  
 pathogenesis, 59, 60, 135–137  
 patient factors, 137  
 pocketing, 17, 18  
 surgical techniques, 141  
 susceptibility, 59–60  
 treatment planning, 138–139
- Periodontium**, 40–42, 56–57  
 cells, 40, 42  
 charting, 9–10  
 diagnosis, 17–18  
 examination, 11  
 fibres, 40  
 gingiva, 53–4  
 ground substance, 40  
 mastication, 72  
 nerves, 40  
 pathology *see* Periodontal disease  
 response to movement and load, 41–2  
 and restorations, 60–61  
 vasculature, 40
- Photo-activated disinfection (PAD)**, 108, 125
- Pins**, dentine, 111–113  
 cemented, 111  
 failure, 260  
 friction grip, 111  
 placement, 111–112  
 self-threading, 102–3
- Plaque**, 43, 44  
 in caries, 178  
 in periodontal disease, 61  
 following tooth loss, 199  
 formation, 43, 54–5  
 index, 10  
 scores, 121–2, 135  
 structure, 43  
*see also* Oral hygiene
- Polycarboxylate cement**, 94
- Porcelain** *see* Ceramics
- Post crowns**, 149–51  
 core characteristics, 150  
 failures, 260–5  
 lateral perforation, 260–4  
 in overdentures, 239–40  
 preparation, 150
- Precision retainers** *see* Bridgework
- Pregnancy**, 27–8
- Prosthodontics**, general  
 choice of prosthesis, 201–209  
 deleterious effects, 207  
 replacement of missing teeth, 200–209  
 treatment planning, 200–209
- Provisional bridges** *see* Bridgework
- Provisional crowns**, 151
- Pulp**, 39–40  
 age changes, 42  
 anatomy, 39  
 assessment in deep caries, 107  
 capping  
   direct, 109  
   indirect, 108  
 necrosis, 16, 52  
 pathology  
   acute pulpitis, 6, 16, 20  
   chronic pulpitis, 6–7, 16  
   diagnosis, 16  
   stabilisation, 20  
   physiological response, 6  
   response to caries, 52–53  
   testing, 11, 107  
   treatment *see* Root canal treatment
- Pulpal protection**, 101–102  
 bases, 101  
 liners, 102  
 principles, 101
- Pulpotomy**, 101
- Radiographs**  
 bitewing, 12, 19, 86  
 cone beam CT, 247  
 distortion, 12–13  
 orthopantomogram, 12, 28  
 periapical, 12–13, 17–19  
 review, 31  
 in diagnosis, 30  
 in root canal treatment, 12, 13, 116–117  
 technique, 12–13
- Radiotherapy**, 27
- Resin modified glass ionomer cements**, 88, 94
- Resin retained bridgework**, 210–216  
 alloys, 215  
 cementation, 214–215  
 cements and bonding, 215–216  
 debonding, 216  
 design, 211–212  
 history, 210  
 immediate replacement, 214  
 indications, 212  
 tooth preparation, 211–212  
 treatment planning, 212
- Restorative materials**, 74–87, 111  
 adhesion, 83–85  
 biological compatibility, 86  
 choice, 92, 135, 153  
 clinical testing, 86  
 degradation, 70, 80  
 dimensional changes, 80  
 handling characteristics, 82–83
- implants, 242  
 mechanical properties, 74–81  
 partial dentures, 266–267  
 physical properties, 74, 77  
 surface finishing, 83  
 thermal properties, 79–80  
 tooth surface loss, 296–297  
*see also individual materials*
- Retruded arc of closure** *see* Occlusion
- Retruded contact position** *see* Occlusion
- Review and recall**, 31
- Rheumatic heart disease**, 26
- Risk assessment and prognosis**, 31
- Root canal treatment**, 115–134  
 canal preparation, 118–125  
   access, 118–119  
   apical anatomy, 117  
   high-torque rotary, 123–124  
   instrumentation, 122  
   irrigation, 124  
   orifice enlargement, 119  
   pulp extirpation, 119  
   step-back technique, 123  
   working distance determination, 119–120  
 complications, 127  
 crowns, 151  
 diagnosis, 115  
 disinfectants, 125  
 filling, 121, 126, 259–60  
 filling material, 120–121  
 fractured instrument, 126, 127  
 isolation rubber dam, 118  
 medication, 125  
 open apex, 128  
 outcome, 133  
 perforation, 123, 124, 127,  
 photo-activated disinfection (PAD), 125  
 pre-endodontic preparation, 117–118  
 problems, 124, 126–127  
 radiography, 106, 107  
 recurrent infection, 129  
*see also apical surgery*  
 review, 128  
 root canal morphology, 116  
 technical objectives, 115  
 treatment planning, 115–118
- Root fracture**  
 traumatic injuries, 21  
 vertical, 264–5
- Saliva**, 43, 44  
 in caries, 45  
 components, 41  
 influence on materials, 76

- Sedation  
inhalation, 27  
intravenous, 27  
oral, 27
- Shade  
guides, 176  
taking, 176–177
- Shortened dental arch, 208–209
- Smear layer, 84
- Sorption and solubility of materials, 80
- Stabilisation, 21–24  
of apical pathology, 22  
of caries, 21  
definition, 15  
of gingival conditions, 24  
of pulpal pathology, 21
- Swallowing, 63, 68
- Temporomandibular dysfunction, 7, 302–309  
aetiology, 302–303  
clinical features, 303–304  
definition, 302  
management, 304–308  
basic physiotherapy, 304, 305  
occlusal therapy, 307  
equilibration, 307  
restorations, 257  
splints, 305–307  
reassurance, 305  
systemic therapy, 307
- Temporomandibular joint  
anatomy, 62–64  
bones, 62, 63  
disc, 62, 63  
ligaments, 63  
microscopic, 63  
arthritis, 304  
dislocation, 304  
examination, 144  
function, 65  
glenoid fossa, 63  
internal derangement, 302, 309  
scan, 309
- Thermal properties of materials, 79  
conductivity and diffusivity, 79–80  
expansion, 79
- Tooth loss, consequences, 199–200
- Toothbrushes, 139  
abrasion, 296
- Toothpastes, 139
- Tooth surface loss (attrition, abrasion and erosion), 295–301  
aetiology, 295, 245–7  
developmental anomalies, 295  
amelogenesis imperfecta, 156, 295  
dentinogenesis imperfecta, 156, 295, 296  
diet, 297–298  
gastric reflux, 298  
malocclusion, 295  
misuse of restorative materials, 296–297  
parafunctions and habits, 296  
posterior tooth loss, 295–296  
systemic disease, 298  
treatment planning, 298–300
- Traumatic injuries, 22–24  
dislocation and avulsion, 23  
enamel/dentine, 22  
enamel/dentine/pulp, 23  
enamel only, 22  
root fracture, 23, 264–265
- Treatment plan  
general structure, 30–31
- Treatment planning, general principles, 4, 25–32  
in Prosthodontics, 199–209
- Trigeminal neuralgia, 7
- Veneers, ceramic, 179–181, 187
- Viscoelasticity of materials, 75
- Vitality tests, 11, 123  
electrical, 11  
test cavity, 11  
thermal, 11
- Wedges, 103
- Xerostomia, 29
- Zinc oxide-eugenol cement, 22, 101, 111
- Zinc polycarboxylate cement, 102





