

SLE. Dentistry MCQs Part (1)

MCQs Review for Saudi Licensing Exam (SLE)

TOPIC	No of MCQs
Operative	200
Periodontics	70
Pedodontics	85
Endodontic	225
Community	85
Radiology	35
Surgery	240
Oral medicine	175
Pharmacology	25
Prosthodontics Fixed	120
Prosthodontics Removable	150
Total	1410

Ahmad AL-Aouni

For further information contact with me
Twitter & Kik : @dr_watheg

Operative 200 MCQs

1. The following chemically bond to the tooth:

- A. Composite resin.
- B. Dental sealants.
- C. Glass ionomer cement. ***
- D. All of the above.

2. Compomer restorative materials are:

- A. Glass ionomer with polymer components
- B. Resin systems with fluoride containing glasses. ***
- C. Composite resin for cervical restorations only.

The composition of compomers is similar to that of a **dental composite** however it has been modified, making it a polyacid-modified composite. This results in compomers still requiring a bonding system to bond to tooth tissue.

Although the name compomer implies that the material possesses a combination of characteristics of both composite and glass ionomers, these materials are essentially polymer-based composites that have been slightly modified to take advantages of the potential fluoride-releasing behavior of glass ionomers.

3. Loose enamel rods at the gingival floor of a class II amalgam cavity should be removed using :

- A. Straight chisel.
- B. Hatchet.
- C. Gingival curetla.
- D. Gingival marginal trimmer. ***

Gingival marginal trimmers are primarily used for beveling gingival margins, and rounding or beveling of the axiopulpal line angle of Class II preparations.

The gingival margin trimmer is designed to produce a proper bevel on gingival enamel margins of proximoocclusal preparations.

4. Removal of Undermined Enamel in Class II cavity is done by :

- A. Chisel. ***
- B. Angle former
- C. Excavator

PROXIMAL (CLASS II):

A chisel can be used to plane away unsupported enamel from the margins of the completed preparation to produce a 90° butt joint.

5. What is the cavo-surface angle of prep for amalgam restoration:

- A. 30 degree
- B. 60 degree
- C. 90 degree ***
- D. 130 degree.

6. Hand instrument which we used to make internal angles retentive grooves and preparation of cavity walls in the cavity is:

- E. Angle former. ***
- F. Chisel.
- G. File.
- H. Enamel hatched.

- 7. To provide maximum strength of amalgam restoration the cavo-surface angles should:**
1. Approach 75° with outer surface.
 2. Approach 90° with outer surface.
 3. Be supported by sound dentine.
 4. Be located in area free of occlusal stress.
- A. 1+3 and 4.
B. 1+3.
C. 2+3+4. ***
D. 3+4.
- 8. Which of the following materials has been shown to simulate reparative dentine formation most effectively when applied to the pulpal wall of a very deep cavity:**
- A. Copalite varnish.
B. Calcium hydroxide preparation. ***
C. Zinc phosphate cement.
D. Anhydrous class inomer cement.
- 9. Calcium hydroxide is best pulp capping material because:**
- A. It has best seal over pulp.
B. It is alkaline + less irritating to pulp.
C. It induces reparation dentine formation. ***
- 10. Clinical failure of the amalgam restoration usually occurs from:**
- A. Improper cavity preparation. *****
B. Faulty manipulation.
C. Both of the above.
D. None of the above.
- 11. It has been proven that amalgam restoration has the following characteristics:**
1. Micro leakage decrease with aging of the amalgam restoration.
 2. It is the least techniques sensitive of all current direct restorations.
 3. High dimensional changes.
- A. 1 , 2 and 3.
B. 1 and 3.
C. 1 and 2. ***
D. 2 only.

** During electrochemical corrosion of low-copper amalgams, The Sn-Hg phase is oxidized into Sn-O and/or Sn-O-Cl. The oxychloride species is soluble.
 ** The oxide Precipitates as crystals and tends to fill up the spaces Occupied by the original Sn-Hg phase. Along the margins Of the amalgam, Sn-O helps seal the space against Microleakage.
 ** During setting, most amalgams undergo very little Dimensional change.
 ** The dimensional change during the setting of amalgam is one of its most characteristic properties.
 ** Modern amalgams mixed with mechanical amalgamators usually have negative dimensional changes.
 **The only exception to this statement is the excessive delayed dimensional change resulting from contamination of a zinc-containing alloy with water during tritura-tion or condensation.

12. When polishing the amalgam restoration:

- A. Avoid heat generation by using wet polishing paste.
- B. Wait 24 hours.
- C. **A and b. *****
- D. B only.

13. Maximum time elapsed before condensation of amalgam after titration:

- A. 1minute.
- B. **3minutes. *****
- C. 9minutes.

14. After amalgam titrations, the mix should be placed within:

- A. 1 min. ***
- B. **3 min. *****
- C. 5 min.

15. MOD amalgam restoration with deep mesial box, PT come with pain related to it after 1 month due to:

- A. **Pulp involvement. *****
- B. Supraocclusion.
- C. Upon contact.
- D. Gingival recession.

16. Reduction in amalgam restoration should be:

- A. 1-1.5 mm.
- B. **1.5-2 mm. *****
- C. 2-3 mm.
- D. 3-5 mm.

**** It must have a minimum thickness of 0.75 to 2 mm.
(because of its lack of compressive strength)**

17. Depth of amalgam restoration should be:

- A. 1 – 1.5 mm.
- B. **1.5 – 2 mm. *****
- C. 2 – 3 mm.
- D. 3 – 5 mm.

18. Silicate cement:

- 1. First tooth colored restoration.
- 2. It can be used as permanent filling.
- 3. It contains 15 % fluoride.
 - A. 1 , 2 and 3.
 - B. 1 and 2.
 - C. **1 and 3. *****
 - D. 1 only.

Silicate cement , the first translucent filling material, was introduced in 1878 by Fletcher in England dental material & thier selection 2002 . Silicate cement contain 12-25 Flouride.

ZOE , reinforced ZOE, ZOE-EBA, Silicate and zinc phosphate cements are no longer routinely used to permanently cement restorations.

19. Length of pins must be equals in both tooth and restoration by a depth of:

- A. 1 mm.
- B. 2 mm. ***
- C. 3 mm.
- D. 4 mm.

20. Stainless steel pin is used in amalgam for:

- A. Increase retention. ***
- B. Increase resistance.
- C. Increase streangth.
- D. A and b.

21. What can we use under composite restoration:

- A. Ca (oh). ***
- B. ZOE.
- C. ZINC phosphate cement.

22. The x- ray of choice to detect the proximal caries of the anterior teeth is:

- A. Periapical x-ray. ***
- B. Bitewing x-ray.
- C. Occlusal x-ray.
- D. None of the above.

23. What is the copper ratio that eliminates gamma phase 2:

- A. 2% copper
- B. 4% copper
- C. 10 % copper
- D. 13 % copper ***

24. To prevent discoloration under amalgam filling:

- A. Use Zn phosphate box.
- B. Use cavity varnish. ***
- C. Wash the cavity with NaOCL b4 filling.
- D. Use the correct amalgam-alloy ratio.

25. Polishing bur have:

- A. Less than 6 blades.
- B. 6-7 blades.
- C. 10-12 blades.
- D. More than 12 blades. ***

26. Rubber dam is contraindicated in:

- A. Pt with obstructive nose. ***
- B. Mentally retarded Pt.
- C. Un comparative child.
- D. A and b.

27. Pt complain from pain in 45 which had gold onlays. The pain could be due to:

- A. Chemicals from cement.
- B. High thermal conductivity of gold. *****
- C. Related to periodontal ligament.
- D. Cracked tooth or fractured surface.

Disadvantages of gold restoration:

Esthetics – cost – time consuming – difficulty of technique – the need to use cement.
(the weakest point in the cast gold restoration) –
Gold has high thermal conductivity.

28. Pt complain from pain during mastication which had gold onlays. The pain could be due to:

- A. Chemicals from cement.
- B. High thermal conductivity of gold.
- C. Related to periodontal ligament. *****
- D. Cracked tooth or fractured surface.

29. Class II composite resin is lined by:

- A. G.I. *****
- B. Reinforced ZOE.
- C. ZOE with epoxy cement.
- D. Cavity varnish.

30. In cavity preparation, the width of the cavity is:

- A. 1/2 inter cuspal distance.
- B. 1/3 inter cuspal distance. *****
- C. 2/3 inter cuspal distance.

31. Selection of shade for composite is done:

- A. Under light.
- B. After drying tooth and isolation with rubber dam.
- C. None of the above. *****

32. Most commonly, after placement of amalgam restoration PT. Complain from pain with:

- A. Hot.
- B. Cold. *****
- C. Occlusal pressure.
- D. Galvanic shock.
- E. Sweet.

33. Calcium hydroxide is used in deep cavity because it is:

- A. Simulate formation of 2nd dentine. *****
- B. Not irritant to the pulp.
- C. For thermal isolation.

34. In placement of rubber dam:

- A. 4 jaw contact in teeth.
- B. Only 4 contacts 2 lingual surface and 2 buccal surface. *****
- C. Only 4 contacts 2 mesial and 2 distal.

- 35. (7 days) after amalgam restoration, Pt came complaining of pain during putting spoon on the restored tooth because:**
- A. Irreversible pulpitis.
 - B. Reversible pulpitis.
 - C. Broken amalgam.
 - D. Galvanic action. ***
- 36. Filling amalgam in the first mandibular molar when touch the spoon there is a pain the reason is:**
- A. Galvanic action. ***
- 37. The aim of conditioning agent on dentine before GI cement is to remove smear layer:**
- A. True. ***
 - B. False.
- 38. Compomer release fluoride as GI:**
- A. True.
 - B. False. ***
- 39. PT feel pain of short duration after class II restoration. Diagnosis is:**
- A. Reversible pulpitis (Hyperemia). ***
 - B. Irreversible pulpitis.
 - C. Periodontitis.
- 40. In the preparation of cavity class II , for restoration with composite resin all Cavosurface angles should be:**
- A. Well rounded. ***
 - B. Right angles.
 - C. Acute angles.
 - D. Obtuse angles.
- 41. Selection of shade for composite is done:**
- A. Under light.
 - B. After drying tooth & isolation with rubber dam.
 - C. None of the above. ***
- 42. A class IV composite resin restoration should be finished with a:**
- A. No. 330 Tungsten carbide bur.
 - B. Mounted stone.
 - C. 12- fluted carbide bur. ***
 - D. Coarse diamond point (stone).
- The 12-fluted carbide burs (#7901, #7804 ET series) have traditionally been used to perform gross finishing of resin composites.
- 43. In Class V composite restorations a layer of bonding agent is applied:**
- A. Following removal of cement then cured. ***
 - B. Following removal of cement and not cured.
 - C. Cured then remove cement.

44. After class V GI restoration removal of a thin flush of GI is done by:

- A. Scaller or knife immediately.
- B. Finishing stone immediately.
- C. Scale or knife later.
- D. Finishing stone later.
- E. A+B.
- F. A+D. ***

45. After finish class v glass-ionomer cement we do finishing with:

- A. Pumice slurry.
- B. Aluminum-oxide disc. ***

Micron finishing diamonds used with a petroleum lubricant to prevent desiccation are ideal for contouring and finishing conventional glass ionomers. Also, flexible abrasive discs used with a lubricant can be very effective.

A fine grit aluminum oxide polishing paste applied with a prophyl cup is used to impart a smooth surface.

46. Indirect composite inlay has the following advantages over the direct composite EXCEPT:

- A. Efficient polymerization.
- B. Good contact proximally.
- C. Gingival seal.
- D. Good retention. ***

47. Indirect composite inlay has the following advantages over the direct composite EXCEPT:

- A. Efficient polymerization.
- B. Good contact proximally.
- C. Gingival seal.
- D. Price ***

48. Indirect composite inlay overcome the direct composite by:

- 1. Insufficient polymerization
- 2. Good contact proximally
- 3. Gingival seal
- 4. Good retention
- A. 1-2-4.
- B. 1-2-3. ***
- C. 4-3.

49. A glossy finish is best retained on a:

- A. Microfilled composite resin restoration. ***
- B. Macrofilled resin restoration.
- C. Hybrid composite resin restoration.
- D. Fiber reinforced composite resin restoration.

Microfill (fine particle composite)
0.01- 0.1 *** Develop smoothest finish.

Microfilled resin composite can be polished to the highest luster and smoothest surface of all the resin composites.

50. Composite for posterior teeth:

- A. Microfilled + fine filler.
- B. Macrofilled + rough filler.
- C. Hybrid + rough filler. ***

The strength and other physical properties, EXCEPT wear resistance and surface roughness, of macrofilled composites are adequate for Class III, IV, and V restorations. Excessive wear when used for Class I and II restorations limited their posterior use. Macrofills were used before dentinal bonding systems were developed; placing them in posterior teeth resulted in postoperative sensitivity, leakage, and recurrent decay.

The problem with microfilled composites is the low percentage filler (40–50%). The surface area of the very small filler particles requires much more resin to wet the surface of the filler particles. This high resin content results in an increased coefficient of thermal expansion and lower strength.

Microfilled composites were used when esthetics are the dominant concern. Large composite restorations, such as an extensive Class IV restoration, are built in layers of several different shades and translucencies. The first layers to be placed are a hybrid composite selected for strength. The final layer, a veneer of sorts, is a microfilled composite selected for surface luster.

Microfilled composites are also used in Class V restorations at the cemento–enamel junction. Microfills have a lower modulus of elasticity and flex with the tooth better than the strongest composite materials. Clinical research has shown Class V microfill composite restorations are more likely to be retained than other composite materials.

Hybrid composites are very popular; their strength and abrasion resistance are acceptable for small to medium **Class I and II restorations**. Their surface finish is nearly as good as that of microfills; thus, they are also used for Class III and IV restorations.

51. For etching 15 sec, for composite restoration use:

- A. 37% phosphoric acid. ***
- B. 15% fluoric acid.
- C. 3% sulfuric acid.

52. After class II amalgam fill , broken is happen in isthmus area why:

- A. Over high of filling vertically. ***
- B. Over flair Cavo surface angle or edge.
- C. Improper mixed fill.

53. Small caries confined to enamel:

- A. Preventive measure. ***
- B. Amalgam feeling.
- C. Keep under observation.

54. In enamel caries passing half of enamel:

- A. Leave it.
- B. Restoration. ***

55. At which location in enamel is the density of enamel crystals is lowest:

- A. Prism less enamel.
- B. DEJ. ***
- C. Center of enamel Prisms.
- D. Edge of enamel Prisms.
- E. Facial enamel.

56. Rampant caries in adult in anterior teeth restored by:

- A. Glass ionomer. ***
- B. ZOE.
- C. Amalgam.

57. Most of dentine bonding material need conditioning time:

- A. 15 sec. ***
- B. 30 sec.
- C. 45 sec.
- D. 60 sec.

58. Time of curing of dentine:

- A. 10 sec.
- B. 15 sec.
- C. 30 sec. ***
- D. 60 sec.

59. Light curing time for simple shallow class III composite:

- A. 10 sec.
- B. 15 sec.
- C. 20 sec. ***

60. Cavity varnish should be applied at least in:

- A. One layer.
- B. Two layer. ***
- C. Three layer.
- D. Four layer.

61. During placement of amalgam pins, the number of pins per cusp is:

- A. 1 pin. ***
- B. 2 pins.
- C. 3 pins.

62. The cause of fracture in amalgam class II restoration is:

- A. Thin thickness at the marginal ridge. ***
- B. Wide flared cavity
- C. Deep cavity.

63. Contact area is in incisal/occlusal 1/3 in which tooth:

- A. Mandibular incisors. ***
- B. Mandibular molars.
- C. Maxillary molars.

64. Incipient caries is diagnosed by:

- A. Fiber optic light. ***
- B. Tactile examination.
- C. X-ray film.

65. The spontaneous production of an electric current resulting from two dissimilar metal in the oral cavity is called:

- A. Nuclear reaction.
- B. Galvanic action. *****
- C. Precipitation reaction.
- D. Thermodynamics.

66. One week after filling of class II restoration, the Pt present with a complain of tenderness on mastication and bleeding from the gingival. The dentist should initially:

- A. Check the occlusion.
- B. Check the contract area. *****
- C. Consider the probability of hyperemia.
- D. Explain to the Pt that the retainer irritated the surrounding soft tissue and prescribe an analgesic and warm oral rinse.

67. Which one of the following is not a characteristic of dentinal hypersensitivity:

- A. It is one of the most successfully treated chronic dental problems. *****
- B. Its prevalence range from 8 to 30%.
- C. The majority of the Pts who experience it are from 20 to 40 years of age.
- D. One source of the irritation that leads to hypersensitivity is improper tooth brushing.

Dentin hypersensitivity is a common clinical condition that is difficult to treat because the treatment outcome is not consistently successful.

68. Hypersensitivity is due to:

- A. Exposed dentine with opened dentinal tubules. *****
- B. Obliterated dentinal tubule.

69. The function of the anterior teeth is:

- A. Disarticulate the posterior teeth.
- B. Incise food. *****
- C. Prevent attrition.
- D. Prevent food impaction.

70. In geriatric Pt, Cementum on the root end will:

- A. Become thinned and almost nonexistent.
- B. Become thicker and irregular. *****
- C. Render apex to locator useless.
- D. Often not be seen on the radiograph.
- E. Indicate pathosis.

71. Hydrogen peroxide is the ideal bleaching agent because:

- A. It bleaches effectively at natural ph.
- B. It bleaches faster than carbamide peroxide.
- C. Protection for sensitive tissues can be incorporated into the hydrogen gel.
- D. All of the above. *****

72. Which statement concerning sensitive teeth is false:

- A. Small dentin exposure can result in sensitivity.
- B. The extent of dental hard tissue loss always correlates with sensitivity. *****
- C. A wide variety of clinical condition can cause teeth to become sensitive.
- D. Oral hygiene habits and diet can contribute to clinical sensitivity problems.

73. Dentine hypersensitivity is best relieved or controlled by:

- A. Using efficient cooling system.
- B. Blacking exposed tubules on the dentin surface. *****
- C. Opening tubules to permit release of intrapulpal pressure.
- D. Applying anti inflammatory agent to exposed dentin.

74. When you do amalgam finishing.....

- A. Immediately.
- B. 24 hours later. *****

75. When polishing amalgam restoration .

- A. Avoid heat generation by using wet polishing paste.
- B. Wait for 24 hours.
- C. A & b. *****
- D. A only.
- E. B only.

76. How can you prevent dental hyper sensitivity:

- A. Restoration by adhesion. *****
- B. Controlled by alcohol.
- C. Put sedative medication.

77. The following cavity bases are moisture sensitive:

- A. Polycarboxylate
- B. Zinc phosphate
- C. GI cement. *****
- D. ZOE
- E. A, c.

Glass ionomer cements are very sensitive to contact with water during setting. The field must be isolated completely. Once the cement has achieved its initial set (about 7 minutes), coat the cement margins with the coating agent supplied with the cement.

78. Which of the following types of base materials can be placed in contact with polymethyl methacrylate & not inhibit the polymerization of the resin:

- A. ZOE.
- B. GI cement.
- C. Zn phosphate cement.
- D. Varnish.
- E. B, C. *****

79. Cement which contains fluoride:

- A. GI. ***
- B. ZOE.
- C. Reinforced ZOE.
- D. Polycarboxylate cement.

80. Marginal deterioration of amalgam restoration should be due to:

- A. No enough bulk of dentine.
- B. Corrosion.
- C. Over carving.
- D. Improper manipulation of amalgam.
- E. A and b.
- F. C and d.
- G. All the above. ***
- H. B, c and d.

Amalgams that are corroded or have inadequate bulk to distribute stresses may fracture. At margins, where amalgams are thinner, extrusion may have occurred, and corrosion may have compromised the integrity of the amalgam, fracture is even more likely.

81. Marginal deterioration of Amalgam restoration may be due to:

- A. No enough bulk.
- B. No dentin (undermined enamel).
- C. Corrosion, over carving.
- D. Improper manipulation of Amalgamg.
- E. B, C, D.
- F. All of above. ***

These objectives help to conserve the dentinal support and strength of the tooth, and they aid in establishing an enamel cavosurface angle as close as possible to 90 degrees . They also help to minimize marginal deterioration of the restoration by locating the margins away from enamel eminencies where occlusal forces may be concentrated.

82. A restoration of anterior teeth with RCT, abraded incisal edge & small M&D caries is by:

- A. Ceramometal crown. ***
- B. Composite laminated.
- C. Veneer.
- D. None of the above.

83. The powder for GI cement contain:

- A. Sio2, Al2o3, Caf. ***
- B. Sio2,zno, barium sulphate.
- C. None of the above.

GIC Powder:

Silica 41.9%.
Alumina 28.6%.
Calcium Fluoride 15.7%.
Sodium Fluoride 9.3%.
Aluminium Phosphate 3.8%.
Aluminium Fluoride 1.6% .

84. Proximal caries should be opened when:

- A. Confined within enamel.
- B. Pass DE junction. ***
- C. Dentin laterally.
- D. All of the above.

85. In a study, it should ??

- A. Protect you against role of the statistician.
- B. Protect you against legal risks. ***
- C. Protect against physical risks.

86. Most common bacteria causing caries:

- A. Streptococcal mutans. ***

87. Proximal caries confined to enamel:

- A. Prevention. ***
- B. Observation
- C. Restore with G I

88. In community diagnosis and treatment program:

- A. Water flouridation
- B. Diagnose , prevent , treat. ***

89. The cement under MOD amalgam have this character:

- A. High modulus of elasticity (stiff). ***
- B. Low modulus of elasticity (stiffness).
- C. The high modulus of elasticity prevent of bonding and decrease tensile strength.
- D. Both A & C.

90. Both glass ionomer & polycarboxylate cement contain:

- A. Polyacrylic acid. ***
- B. ZOE powder.

91. Most common cyst oral cavity:

- A. Radicular cyst. ***
- B. Peridontal cyst.

92. Dentinogenesis imperfecta have all EXCEPT:

- A. Broken enamel.
- B. Blue sclera.
- C. Broken bone.
- D. Supernumerary teeth. ***

Symptoms of Dentinogenesis imperfecta, type I.

The list of signs and symptoms mentioned in various sources for Dentinogenesis imperfecta, type I includes the 14 symptoms listed below:

- ✓ Bluish-gray teeth - Amber-colored teeth - Bulbous teeth crowns.
- ✓ Absent tooth roots – canals - pulp chambers.
- ✓ Too small tooth roots - canals - pulp chambers.
- ✓ Enamel separation from the ivory (dentin) .
- ✓ Misaligned teeth - Recurring dental abscess - Brittle bones - Blue sclera.

93. Generalized gray discoloration in a 28 years old patient's teeth, with blue sclera & an enlarged pulp chambers & short roots, multiple fractures in Enamel, the diagnosis:

- A. Dentinogenesis Imperfecta. ***
- B. Amelogenesis Imperfecta.

Type I and II show total obliteration of the pulp chamber.

Type III shows thin dentin and extremely enormous pulp chamber. These teeth are usually known as Shell Teeth

Type 1: Roots are short, blunt and conical. In deciduous teeth, pulp chambers and root canals are completely obliterated in permanent they may be crescent shaped.

Type 2: The pulp chamber of the deciduous teeth become obliterated in deciduous teeth. While in permanent teeth, large pulp chamber is seen in coronal portion of the tooth - referred to as thistle tube appearance. Pulp stones may be found.

94. (30 year) old pt came to the clinic with brownish discoloration of all his teeth (intrinsic discoloration) & yellowish in U/V light the most likely cause is:

- A. Fluorosis.
- B. Tetracycline. ***
- C. Amelogenesis imperfect.
- D. Dentogenesis imperfecta.

95. Pins are insert into:

- A. Enamel.
- B. Dentin. ***
- C. Enamel and dentin (DEJ).
- D. Any of the above .

The Pin should be in length, 2 mm in dentine and filling and should be 1 mm far away from DEJ.

96. After etch enamel and bond it with 5th generation the strength of?

- A. 5-10Mp.
- B. 25Mp. *** ((Dentine it will be 35 Mp.))
- C. 30Mp.
- D. 100Mp.

97. Composite restoration that was matching in shade, after one week it became much light ... The reason could be:

- A. light started photoinitiation.
- B. Absorption water.
- C. Shade selected after rubber dam. ***

98. Disadvantage of digital x-ray EXCEPT:

- A. Large disk space Storage.
- B. Clarity and resolution. ***
- C. Expensive.

99. Zinc phosphate cement:

- A. Mechanical attachment. ***
- B. Chemical.

100. Traditional Glass ionomer:

- A. Mechanical bonding.
- B. Acid-base reaction ***
- C. -Mechanical chemical bonding.

101. Patient with amalgam usually complain of pain with:

- A. Cold. ***
- B. Galvanic.
- C. Hot.

102. Pain of short duration with hot and cold:

- A. Dentin sensitivity. ***
- B. Irreversible pulpitis.
- C. Chronic pulpitis.
- D. Apical periodontitis.

103. Organism that initiates caries:

- A. S. Mutants. ***
- B.
- C.

104. Incipient caries:

- A. Surface zone is relatively unaffected. ***
- B. The surface zone is the largest portion with the highest pore volume.
- C. Tooth preparation and composite is the best treatment.
- D. Pulpal reaction is not possible.
- E. Caries progress in enamel faster than dentin.
 - Surface zone relatively unaffected by the carious attack.

105. The depth of cavity prep for composite in posterior:

- A. Limited to enamel.
- B. 0.5 mm in dentin.
- C. Depends on caries extension. ***
- D. Depends on tooth discoloration.
- E. 0.2 mm in dentin.

106. GIC compared to composite:

- A. Increase linear coefficient of Thermal Expansion.
- B. More wear resistant.
- C. Less soluble.
- D. Stiff.
- E. Polymerization shrinkage ***

107. Dentine permeability increases:

- A. Coronal less than root dentine. ***
- B. Permeability increase toward DEJ.
- C. Permeability increase toward DCJ.

108. Restoring lost tooth, which is least important:

- A. Esthetic.
- B. Pt demand ***
- C. Function.
- D. Arch integrity and occlusal stability.

109. Enamel tufts are:

- A. Extensions of odontoblasts in the DEJ.
- B. Enamel rods change their direction.
- C. Enamel rods get crowded ***
- D. Arrange the steps $\text{Ca}(\text{OH})_2$ placing –varnish-base –amalgam

110. Since in composite tooth prep should be conservative so the design:

- A. Amalgam in moderate and large cavities.
- B. Beveled amalgam margins.....
- C. Conservative restorations. ***

111. Preparation of all incipient cavity within enamel:

- A. Acquired pellicle.
- B. Structures layer protect tooth. ***
- C. Aid in remineralization.

112. During the orthodontist removes orthodontic braces he noticed white hypocalcific lesion around the bracket what to do:

- A. Microabrasion and application of pumice then fluoride application. ***
- B. Composite resin.
- C. Leave and observe.

113. Daily wear of amalgam:

- A. 1-3 microgram /DAY ***

114. Cracked enamel best Dx by:

- A. Dye***

115. How can test crack tooth?

- A. Xray.
- B. Elictric test.
- C. Ethyle dye test. ***
- D. Vitality test.

116. Which one of the following was the most frequently reason for replacement of a molar restoration with larger restoration:

- A. New caries.
- B. Recurrent caries.
- C. Faulty restoration.
- D. All of the above. ***

- 117. When restoring asymptomatic healthy tooth with amalgam, the normal physiologic symptom after that is:**
- A. Pain on hot.
 - B. Pain on cold ***
 - C. Pain on biting.
 - D. Pain on sweet.
- 118. Patient suffering from a cracked enamel, his chief complaint is pain on :**
- A. Hot stimuli.
 - B. Cold stimuli.
 - C. A & B. ***
 - D. Electric test.
- 119. Patient came complaining of severe pain on biting, related to a certain tooth. Upon examination no pulpal or periodontal findings, and pulpal vitality is positive, your Dx:**
- A. Cracked tooth syndrome. ***
- 120. Method of Detection of Cracked teeth :**
- A. Horizontal percussion
 - B. Vertical percussion
 - C. Electric pulp test
 - D. Transillumination / visible light test. ***
- 121. Cracked tooth syndrome is best diagnosed by?**
- A. Radiograph.
 - B. Subjective symptoms and horizontal percussion. ***
 - C. Palpation and vertical percussion.
 - D. Pulp testing.

The diagnosis of cusp fracture is easy when the cusp has fallen off. Before this actually happens, however, the patient may experience pain but often finds it remarkably difficult to locate this to a particular tooth. The patient will frequently complain of sensitivity to hot and cold and discomfort on biting. Even on clinical examination it is often difficult to pinpoint which tooth is causing the pain, but a **fiber-optic light or disclosing solution** may assist the diagnosis by making the crack easier to see. Lateral pressure on the suspect cusp may also help by producing a sensitivity that mirrors the patient's symptoms. Often the pain occurs when the pressure is released. A crack usually **does not show up on an x-ray**, a physical examination of the tooth will have to be performed. A sharp instrument will be used to allow us to explore the tooth for cracks. We will also place pressure on the tooth to see if we can expand the crack until it is seen. You may have X-rays taken but X-rays often do not reveal the crack. Your dentist may use a special tool to test the tooth. There are different kinds of tools. One looks like a toothbrush without bristles. It fits over one part of the tooth at a time as you bite down. If you feel pain, the part of the tooth being tested most likely has a crack in it.

Diagnostic tests of cracked tooth visual examination of cracks: aided by staining with dye such as methylene blue.

Tactile examination crutch the tooth surface with a **sharp explorer widening a gap of the crack may elicit extremely painful response.**

Tooth sloth: Bite tests each cusp tip must be tested individually pain on release often indicates crack tooth.

Transillumination: Fiberoptic light source held perpendicular to the suspected crack **that mean the prober exam for crack in the tooth (b) subjective symptoms and horizontal percussion.**

122. After bleaching a tooth, we want to restore the tooth with composite resin, we don't want to compromise the bonding, we wait for:

- A. 24 hours.
- B. A week ***
- C. Choose a different material.

Esthetic restoration of teeth should be delayed for 2 weeks after the completion of tooth whitening.

123. Which type of burs is the least in heat generation:

- A. Diamond.
- B. Carbide. ***
- C. Titanium.

124. Secondary dentine occur due to:

- A. Occlusal trauma.
- B. Recurrent caries.
- C. Attrition dentine.
- D. All of the above. ***

125. How much subgingivally do you go with the band in class II restorations:

- A. 0.5 – 1 mm. ***
- B. 1 – 2 mm.
- C. 2 – 3 mm.

126. The matrix band should be above the adjacent tooth occlusal surface by :

- A. 1 - 2 mm. ***
- B. 2 – 3 mm.
- C. 2.5 - 3.5 mm.
- D. Below to it.

Matrix band should extend 2 mm above the marginal ridge height and 1 mm below gingival margin of the cavity. The matrix band should not extend more than 2 mm beyond the occluso-gingival height of the crown of the tooth. this facilitates vision and speed up working. Thickness of band is 0.05 mm = 0.002 inch. For adequate closure of the margin, a minimum 0.5 mm of matrix band beyond the margin is necessary.

127. Bitewing exam is used to diagnose EXCEPT:

- A. Proximal caries.
- B. Secondary caries.
- C. Gingival status.
- D. Periapical abscess. ***

128. Which of the following types of base materials can be placed in contact with polymethyl methacrylate & not inhibit the polymerization of the resin:

- A. ZOE.
- B. GI cement.
- C. Zn phosphate cement.
- D. Varnish.
- E. B & C. ***

129. We can use under the composite restoration:

1. Varnish.
2. Zinc oxide and eugenol.
3. Ca (OH)₂.
4. Zinc phosphate cement.
 - A. 1+2.
 - B. 2+3.
 - C. 3+4. ***
 - D. 2+4.

130. At which of the following locations on a mandibular molar do you complete the excavation of caries first:

- A. Axial walls.
- B. Pulpal floor over the mesial pulp horns.
- C. Peripheral caries. ***
- D. All of the above are correct.

131. Dentist provided bleaching which also known as (Home Bleaching) contain:

- A. (35-50%) Hydrogen peroxide.
- B. (5-22%) Carbamide peroxide. ***

A solution of 10% carbamide peroxide in a soft splint has been advocated for home bleaching.

132. Fractured tooth to alveolar crest, what's the best way to produce ferrule effect:

- A. Restore with amalgam core subgingivally. ***
- B. Crown lengthening.
- C. Extrusion with orthodontics.

1- " If the fracture is subgingivally , remove the coronal segment and perform appropriate pulp therapy, then reposition the remaining tooth structure coronally either Orthodontically or Surgically"

2- In the absence of a ferrule, Aykent et al 19 found that in vitro use of a dentine bonding agent with an amalgam core and a direct stainless steel post provided a significant increase in fracture resistance in extracted premolars. Whilst dentine bonding of the amalgam core did not offer any significant improvement when a (1 mm) ferrule was present , this study suggests that there may be a role for dentine bonding of amalgam cores when a ferrule cannot be achieved. Both crown lengthening and orthodontic extrusion may allow for an increased ferrule , but they add additional cost , discomfort and length of treatment times for the patient. Crown lengthening increases the crown to root ratio. Whilst Ichim et al 16 used finite element analysis to predict that crown lengthening did not alter the levels or pattern of stress within the palatal dentine, Gegauff²⁰ concluded that crown lengthening could be problematic. Gegauff 20 investigated whether crown lengthening to achieve a ferrule would affect the static load failure. By placing the finish line further apically, Gegauff²⁰ postulated that the tooth may be weakened as a result of the resultant decrease in cross-sectional area of the preparation and the increased crown to root ratio. Orthodontic extrusion may avoid this problem as it results in a smaller change in the crown to root ratio.

133. Patient that has a central incisor with severe resorption and who's going through an orthodontic treatment that is going to make him extract the premolars, which of the following won't be present in the treatment plan:

- A. RPD.
- B. Implant.
- C. Maryland bridge.
- D. Auto implant of the premolars. *****

134. Dr. Black (GV Black) periodontal instrument classification:

- A. Study what the number represent in the instrument formula. ***

135. For G.V Black classification study what the number refers to angulation?

- A. Number 1.
- B. Number 2.
- C. Number 3. ***
- D. Number 4.

"For g.v black classification study what the number represent in the instrument formula one for width one of length one for angulation.
1st: Width of blade.
2nd: Length of the blade in millimeter.
3rd: Angle of blade.
4th: When cutting edge at AB angle other then right"

136. Patient had bulimia and had lesion in palatal surface in upper teeth with recurrent vomiting. What is the type of lesion:

- A. Attrition.
- B. Abrasion.
- C. Erosion. ***

137. The primary source of retention of porcelain veneer:

- A. Mechanical retention from under cut.
- B. Mechanical retention from secondary retentive features.
- C. Chemical bond by saline coupling agent.
- D. Micromechanical bond from itching of enamel and porcelain. ***

138. 2nd maxillary premolar contact area:

- A. Middle of the middle third with buccal embrasure wider than lingual embrasure.
- B. Middle of the middle third with lingual embrasure wider than buccal embrasure.***
- C. Cervical to the incisal third x
- D. x

139. Hunter Schreger bands are white and dark lines that appear in:

- A. Enamel when view in horizontal ground.
- B. Enamel when view in longitudinal ground. ***
- C. Dentin when view in horizontal ground.
- D. Dentin when view in longitudinal ground.

Hunter-Schreger band formation as it exists in enamel structure. When examined by reflected light, these bands appear as alternating light and dark areas in the enamel portion of a longitudinal ground tooth section.

140. To hasten Zinc Oxide cement, you add:

- A. Zinc sulfide.
- B. Barium sulfide.
- C. Zinc acetate. ***
- D. Barium chloride.

141. In which tooth the contact is at the incisal edge:

- A. Lower anterior teeth. ***
- B. x

142. Scale to measure marginal deterioration:

- A. Mahler scale.***
- B. Color analogues scale.

143. One of these has no effect on the Life span of handpiece:

- A. Low Air in the compressor. ***
- B. Trauma to the head of the hand piece.
- C. Pressure during operating.

144. Color Stability is better in:

- A. Porcelain. ***
- B. Composite.
- C. GIC.

145. Best stress transfer under amalgam:

- A. With thin base layer.
- B. With thick base layer. ***
- C. If put on sound dentin.

146. Tooth with full crown need RCT, you did the RCT through the crown, what is the best Restoration to maintain the resistance of the crown:

- A. Glass ionomer resin with definite restoration. ***
- B. Amalgam.

147. Old pt came to replace all old amalgam filling he had sever occlusal attrition the best replacement is:

- A. Composite.
- B. Amalgam.
- C. Cast metal restoration.
- D. Full crowns. ***

148. Galvanic shock :

- A. Put separating medium.
- B. Wait. ***
- C. Put varnish.

Galvanic Shock: Generally it gradually subsides and disappears in a few days"

149. Bonding agent for enamel we use:

- A. Unfilled resin. ***
- B. Primer & adhesive bonding agent.
- C. Resin dissolve in acetone or alcohol.
- D. Primer with resin modified glass ionomer.

- 1- **The etchant:** Phosphoric acid, nitric acid, or another agent that is used to etch enamel and/or precondition the dentin.
- 2- **The primer:** A hydrophilic monomer in solvent, such as hydroxymethylmethacrylate. It acts as a wetting agent and provides micromechanical and chemical bonding to dentin
- 3- **The unfilled resin:** is then applied and light or dual-cured. This layer can now bond to composite, pretreated porcelain luted with composite, or amalgam in some products.

150. For cavity class II amalgam restoration in a second maxillary premolar, the best matrix to be Used:

- A. Tofflemire matrix. ***
- B. Mylar matrix.
- C. Gold matrix.
- D. Celluloid strips.

Types of matrices:

Metal Firm , used for amalgam restorations.

Mylar Easily mouldable and can light-cure through; used for resin composite.

Plastic Rigid, can light-cure through; used in Class V cavities.

Difficult cases **In deep subgingival cavities** use of special matrices such as **tofflemire** or automatrix or copper bands often achieve better contact points and marginal adaptation. Occasionally electrosurgery required to permit matrix adaptation.

151. Reciprocal arm in RPD help to resist the force applied by which parts:

- A. Retentive arm. ***
- B. Guide plane and.

152. When removing moist carious dentin which exposes the pulp, dentist should:

- A. Do direct pulp cap.
- B. Do indirect pulp cap.
- C. Prepare for Endo. ***

There is general agreement that carious exposure of a mature permanent tooth generally requires endodontic therapy.

Carious exposure generally implies bacterial invasion of the pulp, with toxic products involving much of the pulp. However, partial pulpotomy and pulp capping of a carious exposure in a tooth with an immature apex have a higher chance of working.

Cavity Cleansing , Disinfection , and Hemorrhage Control.

A clinical review failed to support direct pulp-capping or pulpotomy procedures in teeth when a mechanical exposure pushes infected carious operative debris into the subjacent pulp.

Because of the stigma of long-term failures, our profession generally selects traditional endodontic treatment. Only in the treatment of pulp exposures in fractured young anterior teeth with open apices does the literature discuss pulpotomy or direct pulp-capping with Ca(OH)₂.

153. Treatment of cervical caries in old patients with a temporary restoration is best done by:

- A. Glass ionomer. ***
- B. Composite resin.
- C. x
- D. x

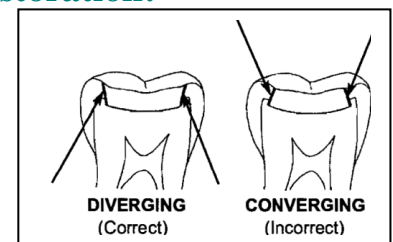
154. The retainer of rubber dam:

- A. Four points of contact two buccally and two lingually without rocking. ***
- B. Four points of contact two buccally and two lingually above the height of contour.
- C. Four points of contact two mesially and two distally.
- D. 2 Points

Dental Dam Retainer Clamp: is that the four prongs must contact the tooth, if they do not, the clamp may need to be ground. A properly selected retainer should contact the tooth in four areas—two on the facial surface and two on the lingual surface. This four-point contact prevents rocking or tilting of the retainer. All four points of the jaws of the clamp must contact the tooth gingival to the height of contour.

155. The divergence should be mesiodistally for an amalgam restoration:

- A. No it should be convergent.
- B. If the remaining proximal marginal ridge = 1.6 mm.
- C. If the remaining proximal marginal ridge only > 1.6.
- D. If the remaining proximal marginal ridge only < 1.6. ***



156. In a class III composite with a liner underneath, what's the best to use:

- A. Light cured GI. ***
- B. ZNO Eug.
- C. Reinforced ZNO Eug.

157. The percentage of simple caries located in the outer wall of the dentin (proximal sides of the tooth) which left without cavitations is around:

- A. 10%.
- B. 30%.
- C. 60%. ***
- D. 90%.

Approximately 60% of teeth with radiographic proximal lesions in the outer half of dentin are likely to be non-cavitated.

158. Amalgam pain after restoration due to:

- A. Phase 2 gamma.
- B. Phase 1 gamma.
- C. Zinc containing alloy. ***
- D. Admix alloy.

159. Zinc if added to amalgam:

- A. Increase moisture sensitivity and cause expansion. ***
- B. Increase marginal integrity and longevity than zinc free amalgam.
- C. A***
- D. B.
- E. A+ B.

160. Distal surface for first upper premolar ,contact with the neighbor teeth:

- A. In the middle with buccal vastness wider than lingual one.
- B. In the middle with lingual vastness wider than buccally one. ***

161. Cavity etching before applying GIC is:

- A. Polyacrylic acid 10 seconds. ***
- B. Polyacrylic acid 60 seconds.
- C. Phosphoric acid 10 seconds.
- D. Phosphoric acid 60 seconds.

162. To increase retention of GIC u should use:

- A. (37%) polyacrylic acid for 15 second.
- B. (35%) polyacrylic acid for 10second.
- C. (10%) polyacrylic acid for 10 second. ***
- D. (10%) polyacrylic acid for 15 second.
- E. A , B.
- F. A , D.
- G. C only. ***

163. Amalgam is used in extensive cavities:

- A. When the cusp is supported by dentine and proper retentive preparation.
- B. When Cusps lost and thin supported wall. ***
- C. When one cusp is lost and need to apply restoration to replace it.

164. What is the most factor encouraging dental caries :

- A. Xerostomia. ***
- B. Hypocalcification.
- C. Smoking.

165. Incipient caries in the old patients is MOSTLY due to:

- A. Smoking.
- B. Saliva.
- C. Xerostomia. ***

166. A Tailor is presented to your dental office , what's the most common feature to be found in His teeth upon examination :

- A. Attrition.
- B. Abrasion. ***
- C. Erosion.
- D. Abfarcation.

167. Abrasion of enamel and root surfaces may result from the long term use of:

- A. A hard tooth brush.
- B. Tooth abrasive tooth paste or powder.
- C. Vigorous use of the tooth brush.
- D. A and B only.
- E. A , B and C. ***

168. Patient came to your clinic complaining of pain, upon examination you can't find a clue. What's the next logical step to do in investigation :

- A. Panoramic x-ray. ***
- B. CT Scan.
- C. MRI.
- D. Regular tomography.

169. Contra indication of implant EXCEPT:

- A. Many dental caries. ***
- B. Malignancy.
- C. Radiation therapy.

170. Dental implant are successfully with min failure:

- A. Pre-maxilla area in the upper arch.
- B. Posterior area of the maxillary arch.
- C. Mandible between the mental foramen. ***
- D. Buccal shelf of the mandible.

Which anatomic site is the most likely to yield failed implants. Implants placed in the maxillary anterior region are the most likely to fail. Because short implants are more likely to fail than longer implants , the longest. Implant that is compatible with the supporting bone and adjacent anatomy should be used.

171. What's the best implant type allowing Osseointegration:

- A. Root-form End-osseous implant. ***

172. The indications of implantation:

- A. Diabetic patient.
- B. Loss of one tooth only with the adjacent teeth. ***

173. Which of the following teeth has a contact area between the incisal (occlusal) third and middle third:

- A. 1st Maxillary premolar.
- B. 1st Mandibular premolar. ***
- C. 1st Maxillary molar.
- D. Central mandible Incisor.

174. Which surface of the central incisor that contacts the median line:

- A. Distal.
- B. Mesial. ***
- C. Buccal.
- D. Lingual.

175. Direct pulp capping is done in:

- A. Primary molar.
- B. Primary incisor.
- C. Permanent molar. ***
- D. None of the above.

176. Indirect pulp capping done in:

- A. Primary molar.
- B. Premolar and molar.
- C. Incisors.
- D. All the above. ***

177. What do we use as temporary filling material in anterior region when aesthetic is important:

- A. Composite.
- B. Glass-ionomer cement. ***
- C. Zinc oxide eugenol.

178. We should select the shade for a composite resin utilizing a:

- A. Bright light.
- B. Dry shade guide.
- C. Dry tooth isolated by the rubber dam.
- D. None of the above are corrects. ***

179. Patient returned to you after 1 month from doing amalgam filling with definite severe pain, due to:

- A. Contamination with moisture leading to amalgam expansion. ***
- B. Unidentified pulpal exposure.
- C. Supra occlusion.
- D. Gingival access.

180. When esthetic is important , posterior class I composite is done in:

- A. Subgingivally box.
- B. Bad oral hygiene.
- C. Contact free area.
- D. Class I without central contact. ***

181. Retention of amalgam depends on:

- A. Amalgam bond.
- B. Convergency of walls occlusally. ***
- C. Divergency of walls occlusally.
- D. Retentive pins.

182. The test for testing the bur all the blades of the burs path through 1 point called:

- A. Ronted. ***
- B. Constidty.
- C. Routed and constedety.
- D. None of above.

Two terms are in common use to measure this characteristic of bur heads **Concentricity** and **Runout**. **Concentricity** is a direct measurement of the symmetry of the bur head itself. It measures how closely a single circle can be passed through the tips of all of the blades. Thus, concentricity is an indication of whether one blade is longer or shorter than the others. It is a static measurement not directly related to function. **Runout**, on the other hand, is a dynamic test measuring the accuracy with which all blade tips pass through a single point when the instrument is rotated. It measures not only the concentricity of the head, but also the accuracy with which the center of rotation passes through the center of the hand.

183. Composite is used mainly for

- A. Anterior teeth. ***
- B. Posterior.
- C. A + B.
- D. None.

184. The instruments for examination are:

- A. Probe and Tweezers.
- B. Mirror.
- C. A + B. ***
- D. Amalgamator.

185. Panorama x-ray is used for:

- A. Periapical tissues.
- B. Interproximal caries.
- C. Giving complete picture for upper and lower jaw. ***
- D. None.

186. According to two digits system 42 means

- A. Lower right lateral incisor. ***
- B. Upper left lateral incisor.
- C. Upper right lateral incisor.
- D. None.

187. A preventive agent is :

- A. Composite.
- B. Glass-Ionomer.
- C. Fluoride. ***
- D. Zinc oxide eugenol.

188. One of the following releases fluorides:

- A. Composite.
- B. Glass-Ionomer. ***
- C. Fluoride.
- D. Zinc oxide eugenol.

189. Saliva ejector is placed:

- A. At the side of working.
- B. Under the tongue.
- C. Opposite the working side.
- D. B + C. ***
- E. A + C.

190. Glass-ionomer:

- A. Introduction 1970.
- B. Need dry field when application.
- C. Both.
- D. None of the above. ***

191. According to the universal system 6 means:

- A. Upper left first molar.
- B. Lower left first molar.
- C. Lower right first molar.
- D. None. ***

Number 6 refers to upper right canine.

192. Burs is:

- A. Critical items. ***
- B. Semi critical.
- C. Non critical.
- D. All of the above.

193. Mouth mirror is:

- A. Critical items.
- B. Semi critical. ***
- C. Non critical.
- D. All of the above.

194. HVE is placed:

- A. At the side of working. ***
- B. Under the tongue.
- C. Opposite the working side.
- D. B+C.

195. Composite can be done in :

- A. Conservative class one. ***
- B. Uncontrolled application c12 proximal.
- C. Deep gingival margin.

196. Grasping the HVE is by:

- A. Thumb to nose grasp.
- B. Pen grasp.
- C. A + B. ***
- D. None.

197. Shade guide:

- A. Under light.
- B. Dry tooth.
- C. None of above. ***

198. When Do class I preparation of posterior tooth for Composite Restoration:

- A. Remove caries only. ***
- B. Extend 2mm in dentin.

199. We redo high copper amalgam restoration when we have:

- A. Amalgam with proximal marginal defect. *** > (Food Accumulation)
- B. Open margin less than 0.5 mm.

200. Thickness of amalgam in complex amalgam restoration in cusp tip area:

- A. 0.5 mm.
- B. 1 - 1.5 mm.
- C. 1.5 - 2 mm.
- D. 2 - 3 mm. ***

Working cusp reduction for amalgam 2.5 - 3 mm.

201. The vertical fracture of the tooth detected by:

- A. Periodontal pocket. ***
- B. Radiographically.
- C. Vertical percussion.

Detected by:

1. Transillumination with fiberoptic light
2. Persistent periodontal defects in otherwise healthy teeth
3. Wedging and staining of defects
4. Radiographs rarely show vertical fractures but do show a radiolucent Defect laterally from sulcus to apex (which can be probed).

Vertical Fracture

A vertical fracture of a tooth may result in communication between the gingival sulcus (oral cavity) and the apical periodontium. The fracture line will be a portal of entry for bacteria from the mouth into the tissues, causing inflammation and bone destruction. A periapical lesion often forms which may have the appearance radiographically of a pulpally related lesion. Since a vertical fracture may be incomplete, its diagnosis in many instances is extremely difficult. Sometimes it is recognized clinically because a periodontal pocket forms along the fracture line and in other instances a simple exploratory surgical procedure may aid in establishing the correct diagnosis.

1. The **hoe excavator** → has the cutting edge of the blade perpendicular to the axis of the handle. It is commonly used in **Class III and V preps for direct gold**.
2. The **angle former** → has the cutting edge at an angle (*other than 90°*) to the blade. It is used for **sharpening line angles and is especially useful to form convenience points for gold foil preps**.
3. An **ordinary hatchet excavator** → has the cutting edge of the blade directed in the same plane of the handle and is bibeveled. **Used primarily on anterior teeth for preparing retentive areas.**
4. A **spoon excavator** → has a curved blade with a rounded cutting edge. **It is used to remove carious dentin and sometimes to carve amalgam. Note:** These can be sharpened with handpiece stones.

Periodontics 70 MCQs

1. Treatment of gingival trauma from faulty oral hygiene is mainly:

- A. To advice the patient to change their faulty habits immediately ***
- B. Reassure the patient that it will disappear by itself.
- C. To buy a new brush.

2. Which of the following statement is true regarding dental calculus:

- A. It is composed entirely of inorganic material.
- B. It is dens in nature and has a rough surface.
- C. It is mineralized dental plaque.
- D. All of the above.
- E. B & C only. ***
- F. None of the above.

3. Overhanging restoration margins should be removed because:

- A. It provides ideal location for plaque accumulation.
- B. It tears the gingival fibers leading to attachment loss.
- C. Stimulate inflammatory reaction directly.
- D. Its removal permits more effective plaque control.
- E. A & D. ***

4. Main use of dental floss:

- A. Remove calculus.
- B. Remove over hang.
- C. Remove bacterial plaque. ***
- D. Remove food debris.

- ✓ The goal of flossing your teeth is to scrub dental plaque.
- ✓ It can be done in primary and permanent.

5. What is the benefit of rinsing the mouth with water:

- A. Plaque removal.
- B. Calculus removal.
- C. Washing the food debris. ***

6. What is the benefit of rinsing the mouth with water:

- A. Plaque removal.
- B. Prevent the formation of plaque. ***
- C. Dilute the concentration of bacteria.

7. The water reins devices for periodontal therapy has a main goal which is:

Remove plaque.

- A. Prevent plaque attachment. ***
- B. Dilute bacterial toxin.
- C. Remove dental pocket.

8. Calculus induce further periodontal lesion due to:

- A. Directly stimulates inflammation.
- B. More plaque adhere to it. ***
- C. Irritate the gingiva.

9. Floss used to:

- A. Remove Interproximal plaque. ***
- B. Remove overhangs.
- C. Stimulate gingival.

10. Plaque consists of:

- A. Bacteria. ***
- B. Inorganic material.
- C. Food.

11. To prevent perio problem MOST effective method is:

- A. Community program.
- B. Removal of plaque. ***
- C. Patient education.

12. Caries consist of:

- A. Bacteria. ***
- B. Fluid.
- C. Epithelial cells.

13. Use of miswak and toothbrush:

- A. Toothbrush after meals and miswak at prayer time and when out of home. ***
- B. Miswak and toothbrush must be used together.
- C. Use the miswak only when they can not afford to buy the toothbrush and toothpaste.
- D. Not use the miswak and use the toothbrush instead.

14. Acute periodontal abscess:

- A. Fistula present.
- B. Swelling enlargement in tooth site. ***
- C. None of the above.

15. Tooth brushing and dental floss help in community prevention of periodontal disease:

- A. True. ***
- B. False.

16. Subgingivally scaling and root planning is done by:

- A. Gracey Curette. ***
- B. Hoe.
- C. Chisel.

17. Dental plaque composed mainly of:

- A. Bacteria. ***
- B. Inorganic materials.
- C. Food.

18. Chronic suppurative periodontitis:

- A. PT complains from moderate pain.
- B. Fistula with drain. ***
- C. Pulp polyp in open coronal carious lesion.

19. Currently the only effective preventive measure for periodontal disease (apart from limited use of antiseptic solutions) is:

- A. Regular and rough removal of dental plaque. ***
- B. Salt fluoridation.
- C. Dental health education.

20. Periodontal ligament fibers in the middle third of the root is:

- A. Oblique. ***
- B. Horizontal.
- C. Transeptal.

21. Which of the following statement is true for the reported relationship of periodontal disease and diabetes mellitus:

- A. The reported incidence of periodontal disease in the diabetes is less than that for nondiabetic.
- B. Pts with history of diabetes of less than 10 years have more periodontal disease destruction than those with history of longer than 10 years.
- C. The prevalence of periodontal disease increase with the advancing age of the diabetic. ***
- D. The prevalence of periodontal disease increase with the better metabolic coronal of the diabetic state.

22. Chlorhexidine is used as mouth wash in the concentration of:

- A. 0.1-0.2 %. ***
- B. 1-2 %.
- C. 5-10 %.
- D. 20 %.

23. Cementum in cervical 2/3 have:

- A. A Cellular intrinsic fiber.
- B. A Cellular extrinsic fiber. ***
- C. Cellular mixed fibers.
- D. Intermediate cementum.

24. Supra calculus all true EXCEPT:

- A. Hard and rough. ***
- B. Easy to detach.
- C. Has component of saliva.

25. Important factor in long term success of perio treatment:

- A. Skill of the operator.
- B. Perio maintenance. ***

26. Which causes gingival enlargement:

- A. x
- B. Cyclosporines. ***

27. Cementum is formed from:

- A. Cementoblasts ***
- B. Fibroblasts.
- C. Cementicles.

28. Teeth have convexity in buccal and lingual:

- A. Upper premolars. ***
- B. x

29. Main disadvantage of Chlorhexidine:

- A. Staining. ***
- B. Burning sensation.
- C. Altered taste.

Chlorhexidine has several disadvantages. One of the most important disadvantages is that if a patient rinses his mouth with Chlorhexidine compositions regularly, his teeth and tongue obtain a brownish colour. This is off course a major disadvantage. Another disadvantage of Chlorhexidine is that it has no significant anti-bacterial effect on gram positive bacteria at relatively low concentrations. This means that gram positive bacteria will not be effected by the rinse composition and may thus still cause periodontitis or produce the volatile sulphur compounds that cause the malodour.

30. The best method for tooth brush is Bass method because:

- A. It enter to interproximal area
- B. Can be used by patient with gingival recession and it rotainary advice to all types of patients.
- C. The both sentences are correct. ***
- D. The first sentence is correct and the second is wrong.

31. Bass brushing has the advantage of the bristles enters in the cervical area , and it is recommended for all patients:

- A. Both statements are true. ***
- B. Both statements are false.
- C. First is true ,second is wrong.
- D. First is wrong , second is true.

Bass method advantages:

- It concentrates the cleaning action on the cervical and Interproximal portions of the teeth.
- The Bass technique is efficient and can be recommended for any patient with or without periodontal involvement.

32. Patient comes to you with edematous gingiva, inflamed, loss of gingival contour and recession, what's the best tooth brushing technique?

- A. Modified bass.
- B. Modified stillman. *****
- C. Charter.
- D. Scrub.

The brushing technique which is recommended after periodontal surgery is Charter.

The brushing technique which is recommended for areas with progression gingival recession is modified stillman.

33. The best method to protect teeth that underwent bicuspidization procedure from fracture?

- A. Full crown. *****
- B. Splint with composite.
- C. Orthodontic splint.

34. Sharpening the curette and sickle, the cutting edge should be at angle:

- A. 50-60.
- B. 70-80. *****
- C. 80-90.
- D. 60-70.

35. The aim of treatment maintenance is:

- A. Prevent secondary infection. *****
- B. Check tissue response.

36. The aim of maintain therapy is:

- A. Prevent recurrent diseases. *****
- B. Check tissue response.

37. To remove a broken periodontal instrument from the gingival sulcus:

- A. Schwartz Periotriever. *****
- B. x

38. An 18 years old Pt present complaining of pain, bad breath and bleeding gingival. This began over the weakened while studying for the final exam. The Pt may have which of the following conditions:

- A. Acute necrotizing ulcerative gingivitis *****
- B. Rapidly progressive periodontitis
- C. Desquamative gingivitis.
- D. Acute periodontal cyst.

Thus , the former term , “Acute Necrotizing Ulcerative Gingivitis” (ANUG) is summed up in necrotizing gingivitis (NG). NG is a relatively rare disease and is generally described as existing in young adults between the ages of 18 and 30 years. It tends to emerge more frequently when the patient is under conditions of both physical and psychological stress. The disease is characterized by pain, bleeding and papillary necrosis with tendency to relapse. Abrupt onset. If the patient has had prior outbreaks, he/ she is capable of reporting prodromal symptoms; for instance, a burning sensation in the gums. Poor general health status and low-grade fever Halitosis. ; it varies in terms of both intensity and degree.

39. Gingival condition occur in young adult has good oral hygiene was weakened:

- A. ANUG. ***
- B. Desquamative gingivitis.
- C. Periodontitis.
- D. Gingivitis.

"Tyldesley's Oral Medicine"

The influence of poor oral hygiene in the initiation of ANUG has been often stressed, but there is no doubt that there are some patients whose standard of hygiene must be considered by normal criteria to be good.

40. Differences between ANUG and AHGS is:

- A. ANUG occur in dental papilla while AHGS diffuse erythematous inflamed gingival.
- B. ANUG occur during young adult and AHGS in children.
- C. All of the above. ***

41. Student, came to clinic with severe pain, interdental papilla is inflamed, student has exams, heavy smoker, poor nutrition:

- A. Gingivitis.
- B. ANUG. ***
- C. Periodontitis.

42. Proxy brush with which type of furcation:

- A. Furcation Grade 1-1.
- B. Furcation Grade 2-2.
- C. Furcation Grade 3-3. ***
- D. Furcation Grade 4-4.

43. Contraindication of Gingivectomy:

- A. Periodontal abscess. ***

44. Sharping of hand instrument mounted air driven better than unmounted due to:

- A. Fine grift. ***
- B. Sterilization.
- C. Ability to curve instrument.

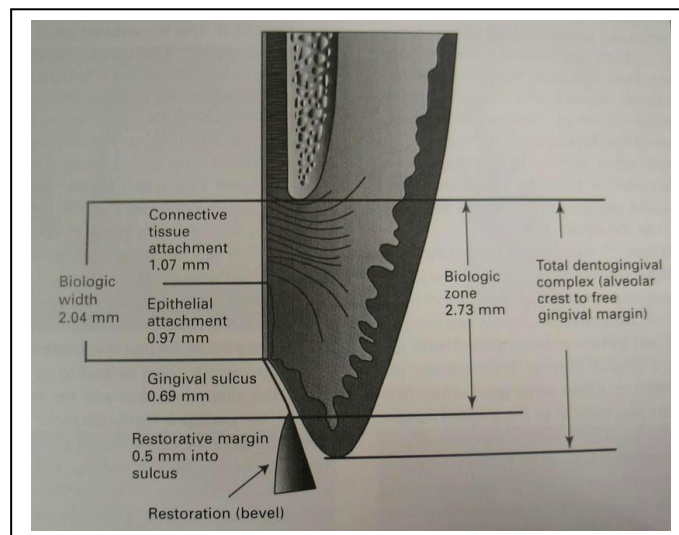
The mounted-stone technique. The second technique for sharpening dental instruments is the mounted-stone technique. This technique is especially useful in sharpening instruments with curved or irregularly shaped nibs. Equipment consists of mandrel-mounted stones, a straight handpiece, lubricant, two-inch by two-inch gauge, and again, the instrument to be sharpened. Mounted stones are made of two materials, Arkansas stones and ruby stones (sometimes called sandstones). Ruby stones are primarily composed of aluminum oxide. The ruby stone is comparatively coarse, has a rapid cutting ability, and is used for sharpening instruments that are dull. Mounted stones are cylindrical in shape and appear in several sizes. **They have a fine grit** and are used with the straight handpiece. The stones permit rapid sharpening, but without extreme care, will remove too much metal and may overheat the instrument. Overheating the instrument will destroy the temper, thereby causing the instrument to no longer hold a sharp edge.

- 45. Unmounted sharpening instruments are better than mounted because:**
- A. Has finer grains.
 - B. Don't alter the bevel of the instrument.
 - C. Easier to sterilize.
 - D. Less particles of the instruments are removed. *** (Cut less of the blade).

- 46. Electro surgery rate:**
- A. 1.5 – 7.5 million cycle per seconds. ***
 - B. 7.5 – 10 million cycle per seconds.
 - C. 10 – 25 million cycle per seconds.
 - D. 30 million cycle per seconds.

- 47. Main reason for surgical pocket therapy:**
- A. Expose the roots for scaling and root planning. ***
 - B. Remove supragingival calculus.

- 48. Biological width:**
- A. 1 mm.
 - B. 2 mm. ***
 - C. 3 mm.
 - D. 4 mm.



- 49. Biological depth:**
- A. Crestal bone to gingival sulcus ***
- 50. Periodontal attachment contain:**
- A. Epithelium , sulcus , connective tissue. ***

- 51. Periodontally involved root surface must be root planed to:**
- A. Remove the attached plaque and calculus.
 - B. Remove the necrotic cementum.
 - C. Change the root surface to become biocompatible
 - D. All of the above.
 - E. A & b only. ***

- 52. Best measurement of periodontitis by:**

- A. Pocket depth.
- B. Bleeding. ***
- C. Attachment level.

Probing to elicit bleeding (Which is the single most useful indicator of disease activity) , measuring pocket depth attachment levels, and detecting subgingivally calculus.

53. The tissue response to oral hygiene instruction is detected by:

- A. Probe pocket depth.
- B. Less bleeding. ***

Both the MBI and PII can be expressed as bleeding or plaque-free scores in this way obtaining a high score is a good thing, which may be both easier for the patient to understand and a more positive motivational approach.

54. After scaling and root planning healing occur by:

- A. Long junctional epithelium. ***
- B. New attachment.
- C. New bone and connective tissue formation.
- D. New attached periodontal ligament fibers.

55. During examination 34 show gingival recession buccally, the least correct reason is:

- A. Frenum attachment.
- B. Pt is right hand brushed.
- C. Occlusal force. ***
- D. Inadequate gingival.

56. Periodontal pocket differ most significantly from gingival pocket with respect to:

- A. Depth.
- B. Tendency to bleed on gentle probing.
- C. The location of the bone of the pocket. ***
- D. All of the above.

Chronic gingivitis is, as the name suggests, inflammation of the gingival tissues. It is not associated with alveolar bone resorption or apical migration of the junctional epithelium. Pockets > 2 mm can occur in chronic gingivitis due to an increase in gingival size because of oedema or hyperplasia (false pockets).

57. All of these are right ways to handle the instrument EXCEPT ??

- A. Modified pen handle.
- B. Inverted pen.
- C. Pen handle. ***
- D. Palm and thumb.

There are four grasps used with the hand instruments: Modified pen. Inverted pen. Palm and thumb. Modified palm and thumb.

58. What is the dominant type of fibers found in Cementum:

- A. Longitudinal.
- B. Circular.
- C. Sharpey's fiber. ***

59. Fibers which completely embedded in cementation and pass from cementation of one tooth to the cementation of adjacent tooth is:

- A. Sharpey's fiber.
- B. Transseptal fibers. ***
- C. Longitudinal fibers.

60. The best method for brushing :

- A. Vertical.
- B. Horizontal.
- C. Bass sulcular method. ***
- D. All of the above.

61. Dental plaque is formed after :

- A. 6 hours. ***
- B. 12 hours.
- C. 24 hours.
- D. 48 hours.

62. Color of normal gingiva in interplay between:

- A. Keratin - Vascularity - Melanin - Epithelial thickness. ***

63. Amputation means:

- A. Surgical removal of the apical portion of the root.
- B. Removal of one or more roots. ***
- C. The root and the crown are cut lengthwise.
- D. None.

64. Hemisection means:

- A. Surgical removal of the apical portion of the root.
- B. Removal of one or more roots.
- C. The root and the crown are cut lengthwise. ***
- D. None.

65. For treatment of pericoronitis:

- A. Extraction of the tooth.
- B. Analgesic + Sterility + Antibiotic.
- C. Cleaning with concentrated phenol.
- D. None. ***

66. Attrition may be caused by

- A. Friction due to pipe.
- B. Friction during sleep. ***
- C. Gastric acid.
- D. None.

67. What is the name of the instrument used to diagnose halitosis:

- A. Halometer***

68. Probe used to detect furcation:

- A. Nabers probe. ***

69. Difference between Gracey and universal curette:

- A. Section of gracey is hemicircular and in universal triangular.
- B. Gracey has one cutting edge while universal has two.
- C. Gracey Used for cutting in specific area while universal is in any area.
- D. Universal 90 not offset, gracey 60 offset.
- E. A and d
- F. A, b and c.
- G. B, c and d.

70. The periodontium comprise which of the following tissues:

- A. Gingiva and the PDL.
- B. Gingival, PDL, and alveolar bone.
- C. Gingival, PDL, alveolar bone, and cementum. ***
- D. Gingival, PDL, alveolar bone, cementum, and enamel.

• Attachment loss

Attachment loss is **much more significant** than periodontal pocketing (*actually it is the most significant factor*) because with attachment loss **supportive structures are being destroyed**. Pocketing can increase or decrease, depending on the amount of inflammation without attachment loss. On the other hand, extensive attachment loss and gingival recession may be accompanied by shallow pockets (*poor prognosis of tooth*).

Important: The two most critical parameters for the prognosis of a periodontally involved tooth are **attachment loss** (*most critical*) and **mobility**.

Attachment level refers to the position of the junctional epithelium at the base of a sulcus or pocket. In **health**, the junctional epithelium is on enamel or at the CEJ. In **disease**, the junctional epithelium migrates apically along the root surface. It is measured from an established reference point (*CEJ or restoration margin*) to the attachment with a **periodontal probe**. The periodontal pocket is measured from a changeable point (*margin of the free gingiva*) to the attachment.

Note: Shallow pockets attached at the level of the apical third of the root suggests more severe destruction than deep pockets attached at the coronal third of the roots. When the gingival margin coincides with the cementoenamel junction, the loss of attachment equals the pocket depth.

Pedodontics 85 MCQs

1. **In primary teeth, pathologic changes in radiographs are always seen in:**

- A. Periapical area.
- B. Furcation area. ***
- C. Alveolar crest.
- D. At base of developing teeth.

2. **Pulpitis in deciduous teeth in radiograph see related to:**

- A. Furcation. ***
- B. Apex of root.
- C. lateral to root.

3. **In deciduous tooth the first radiographic changes will be seen in:**

- A. Bifurcation area.
- B. Apical area.
- C. External root resorption. ***

4. **Eruption cyst "Eruption Hematoma" can be treated by:**

- A. No treatment. ***
- B. Immediate incision.
- C. Complete uncoverage.
- D. Observe for one week then incise.

No treatment is needed because the tooth erupt through the lesion.

5. **After trauma a tooth become yellowish in color, this is due to:**

- A. Necrotic pulp.
- B. Irreversible pulpitis.
- C. Pulp is partially or completely obliterated. ***
- D. Hemorrhage in the pulp.

A yellowish discoloration of the crown is often a Manifestation of Calcific metamorphosis.

6. **Pain during injection of local anesthesia in children could be minimized by:**

- A. Slowly injection.
- B. Talking to the child during injection.
- C. Using long needle.
- D. A and B. ***

7. **Formicrisol when used should be:**

- A. Full Saturated.
- B. Half saturated.
- C. Fifth saturated. ***
- D. None of the above.

8. Space loose occur in:

- A. Proximal caries.
- B. Early extraction.
- C. Ankylosis.
- D. All of the above. ***

9. Polyvinyl silicon compared with polysulfide:

- A. Can be poured more than once.
- B. Can be poured after 7 days.
- C. Less dimensional stability.
- D. A and B. ***

10. The most accurate impression material for making impression of an oral cavity is:

- A. Impression compound.
- B. Condensation type silicon.
- C. Polyvinyl silicon's. ***
- D. Poly sulfide.

The addition silicones are the best choice of the rubber impression materials. Addition curing silicones have the least amount of shrinkage on setting making them the most accurate class of rubber impression material. The poly(vinylsiloxanes) are characterized by excellent dimensional accuracy and long-term dimensional stability.

11. Hand over mouth technique is used in management of which child:

- A. Mentally retarded.
- B. Positive resistance.
- C. Uncooperative.
- D. Hysterical. ***

12. Pits and fissure sealants are indicated in:

- A. Deep Pits and fissure.
- B. Newly erupted teeth.
- C. A and B. ***

13. Pit and fissure sealants are indicated to prevent dental caries in pits and fissure:

- A. In primary teeth
- B. In permanent teeth
- C. A & B. ***

14. The rationale for pit-and-fissure sealants in caries prevention is that they:

- A. Increase the tooth resistance to dental caries.
- B. Act as a barrier between the sealed sites and the oral environment. ***
- C. Have anti-microbial effect on the bacteria.
- D. None of the above answers is correct.

15. Teeth that have lost pits and fissure sealant show...

- A. The same susceptibility to caries as teeth that have not been sealed
- B. Higher susceptibility than non sealed teeth
- C. Lower susceptibility than non sealed teeth. ***
- D. The same susceptibility as teeth with full retained sealant

Teeth that have been sealed and then have lost the sealant have had fewer lesions than control teeth. This is possibly due to the presence of tags that are retained in the enamel after the bulk of the sealant has been sheared from the tooth surface. When the resin sealant flows over the prepared surface, it penetrates the finger-like depressions created by the etching solution. These projections of resin into the etched areas are called tags.

16. Pit and fissure sealant:

- A. New erupted teeth
- B. Deep fissure and pits in molars
- C. Proximal caries
- D. A & B. ***

17. (7 Year) old patient all first molars carious and suspected pit and fissure areas of the second molars. Treatment plan:

- A. Restore all first molars and observe second molars.
- B. Restore all first molars and topical fluoride on second molars.
- C. Restore all first molars and seal pits and fissures of second molars. ***
- D. Restore first and second molars with composite.
- E. Restore first and second molars with amalgam.

18. Most tooth surface affected by caries:

- A. Pit and fissure. ***
- B. Root surface.
- C. Proximal surface.
- D.x

19. Pit & fissure least effective with:

- A. Twenty-four month year.
- B. Primary molar. ***
- C. 2nd molar.

20. Pit & fissure least effective with:

- A. Twenty-four month year.
- B. 2nd primary molar.
- C. 5 years old child. ***

21. Procedure done before applying pit & fissure sealant:

- A. Acid etch by phosphoric acid. ***

22. The most prevalent primary molar relationship:

- A. Flush terminal plane. ***
- B. Mesial step terminal plane.
- C. = = = C-end.
- D. = = = D-distal.

23. In primary teeth. The ideal occlusal scheme is:

- A. Flush terminal.
- B. Mesial step. ***
- C. Distal step.

24. When you give a child a gift for good behavior this is called:

- A. Positive reinforcement. ***
- B. Negative reinforcement.

25. To detect interproximal caries in primary teeth, the best film is:

- A. Periapical.
- B. Bitewing. ***
- C. Occlusal.

26. Best treatment of choice for carious exposure of a primary molar in a 3 year old child who complain of toothache during and after food taking:

- A. Direct pulp capping with caoh.
- B. Direct pulp capping with zao paste.
- C. Formocresol pulpotomy. ***
- D. Caoh pulpotomy.

27. Which of the following would be clinically un acceptable as a primary of isolating a tooth for sealant placement:

- A. Cotton roll.
- B. Rubber dam.
- C. VAC-ejector moisture control system.
- D. None of the above. ***

28. Infection is more dangerous in children than adult because:

- A. Marrow spaces are wide ***
- B. Affect growth centre.
- C. Hypo calcification in enamel.

29. Mandibular foramen in young children is:

- A. At level of occlusal plane.
- B. Above the level of occlusal plane.
- C. Anterior the level of occlusal plane.
- D. Below the level of occlusal plane. ***

30. When you want to give inferior alveolar block for a child you have to take attention that the mandibular foramina is :

- A. At level of occlusal plane.***
- B. Above the level of occlusal plane.
- C. Anterior the level of occlusal plane.
- D. Below the level of occlusal plane .

The mandibular foramen was located 4.12 mm below the occlusal plane at the age of 3. It subsequently moved upward with age. By the age of 9, it had reached approximately the same level as the occlusal plane. The foramen continued to move upward to 4.16 mm above the occlusal plane in the adult group. The height percentage averages ranged from the lower 1/3 of the ramus height in the 3 year-old group to the middle of the ramus height in adults. The depth percentage averages ranged from 67.8% in 3 year-old children to 61.7% in adults. For greater accuracy in anesthetic procedures, dentists should relate the locational changes in the mandibular foramen with age when performing block anesthesia for the inferior alveolar nerve. Mandibular foramen is below the occlusal plane in children but in adults it is above the occlusal plane and post to molars.

31. Tooth germ of primary teeth arise from:

- A. Dental lamina. ***
- B. Dental follicle.
- C. Enamel organ.
- D. Epithelial cell of malassez.

The dental lamina is a band of epithelial tissue seen in histological sections of a developing tooth. The dental lamina is first evidence of tooth development and begins at the sixth week in uterus or three weeks after the rupture of the bucco-pharyngeal membrane.

32. Apical periodontal cyst arise from:

- A. Hertwig sheath.
- B. Epithelial cell Rest of Malassez. ***

Apical Periodontal Cyst = Periapical Cyst = Radicular Cyst : these inflammatory cysts derive their epithelial lining from the proliferation of small odontogenic epithelial residues (rests of Malassez) within the PDL.

33. Formation of periodontal cyst due to:

- A. Nasolacrimal cyst.
- B. Hertwigs. ***
- C. Epithelial rest of malassaz.
- D. Peals of serres.

In dentistry, the epithelial cell Rests of Malassez or Epithelial Rests of Malassez (frequently abbreviated as ERM) are part of the periodontal ligament cells around a tooth. They are discrete clusters of residual cells from Hertwig's epithelial root sheath (HERS) that didn't completely disappear. It is considered that these cell rests proliferate to form epithelial lining of various odontogenic cysts such as radicular cyst under the influence of various stimuli. They are named after Louis-Charles Malassez (1842–1909) who described them. Some rests become calcified in the periodontal ligament (cementicles)

34. Which is the most Likely cause of periodontal cyst?

- A. Cell Rest of Malassez.
- B. Cell rest of serous.
- C. Cell of Hertwig sheath. ***

35. Primary malignant melanoma of the oral mucosa:

- A. Always originates within the surface epithelium.
- B. Mostly originates within the surface epithelium.
- C. Always originates from nevus cells in the connective tissue. ***
- D. Always originates from Langerhans cells within epithelium.

36. Histopathologically adenoid cystic carcinoma is characterized by islands of:

- A. Basophilic islands of tumor cells that are intermingled with areas of pseudocartilage.
- B. Basophilic islands of tumor cells having a "Swiss cheese" appearance. ***
- C. Basophilic islands of tumor cells having a "Swiss cheese" appearance and evidence of serous acini.
- D. Basophilic islands of tumor cells that contain mucin and normal acini.

37. The risk of malignant change being present in epithelium is greatest in:

- A. Homogenous Leukoplakia
- B. Erythroplakia. ***
- C. Chronic hyperplastic candidiasis
- D. Speckled Leukoplakia

Erythroplakia should be viewed as a more serious lesion because of a significantly higher percentage of malignancies associated with it.

38. The term acanthosis refers to:

- A. A decreased production of keratin.
- B. An increased production of keratin.
- C. An increased thickness of the prickle cell zone (stratum spinosum). ***
- D. None of the above.

Acanthosis: Thickening of the epidermis and elongation of the rete ridges due to thickening of the spinous layer. May be associated with enlargement of rete pegs, an abnormal but benign thickening of the prickle-cell layer of the skin (as in psoriasis)

39. The most common malignant tumors of the minor salivary glands are:

- A. Adenoid cystic carcinoma and Adenocarcinoma.
- B. Adenoid cystic carcinoma and acinic cell carcinoma.
- C. Mucoepidermoid carcinoma and adenoid cystic carcinoma. ***
- D. Mucoepidermoid carcinoma and polymorphous Low grade Adenocarcinoma.

The most common malignant minor salivary gland tumors are adenoid cystic and mucoepidermoid carcinomas.

40. Ugly duckling stage:

- A. 9-11 years old. ***
- B. 13-15 years old.
- C. 7-9 years old.

41. Eruption of primary dentition starts from:

- A. 6-7 months.***
- B. 1 year.
- C. 9 months.

42. The use of low speed hand piece in removal of soft caries in children is better than high speed because :

- A. Less vibration.
- B. Less pulp exposure. ***
- C. Better than high speed.

43. Pedro use rubber dam for :

- A. Improve visibility and access.
- B. Lowers risk of swallowing.
- C. Sterile field.
- D. A & B. ***

44. Pedro , has trauma in 11 y , half an hour ago , with slight apical exposure , open apex, treatment is:

- A. Pulpotomy with formacresol.
- B. Apexification.
- C. DPC (direct pulp capping). ***
- D. Extraction.

45. Which intracanal medicament causes protein coagulation:

- A. Formocresol. ***
- B. Naocl.
- C. Wad
- D. Hydrogen peroxide.

46. (6 years) old child have #74 and #84 extracted best space maintainer is:

- A. Lingual arch.
- B. Bilateral band and loop. ***
- C. Bilateral distal shoe.
- D. No need for space maintainer.

47. (6 years) old child lost his upper right 1st molar, arrangement:

- A. Lingual bar.
- B. Crown and loop.
- C. Band and loop. ***

48. Band and loop space maintainers is most suitable for the maintenance of space after premature loss of:

- A. A single primary molar ***
- B. Two primary molars.
- C. A canine and a lateral incisor.
- D. All of the above.

49. Pedro (forgot the age) , lost #75 , best retainer is:

- A. Band and loop ***
- B. Nance appliance.
- C. Crown and loop.

50. (5 years) old patient lost his primary first maxillary molar the best retainer is:

- A. Band and loop. ***
- B. Crown and loop.
- C. Lingual arch.
- D. Nance appliance.

51. (6 years) child with bilateral loss of deciduous molars & the anterior teeth not erupted yet , the space maintainer for choice is:

- A. Lingual arch.
- B. Bilateral band and loop.
- C. Bilateral band and loop with distal shoe.
- D. Removable partial denture. ***

52. One of the main cause of malocclusion:

- A. Premature loss of primary teeth. ***

53. A child at dentation age is suffering from:

- A. Diarrhea.
- B. Sleep disorders.
- C. Increased salivation. ***

54. Three year old pt , has anodontia (no teeth at all), what would you do:

- A. Full denture. ***
- B. Implant.
- C. Space maintainer.
- D. No intervention.

In cases of anodontia, full dentures are required. These can be provided, albeit with likely limited success, from about 3 years of age, with the possibility of implant support for prostheses provided in adulthood.

Autoimmune factors ++ (one of the signs of Autoimm dis's)

55. A child patient undergone pulpotomy in your clinic in 1st primary molar. Next day the patient returned with ulcer on the right side of the lip ... your diagnosis is:

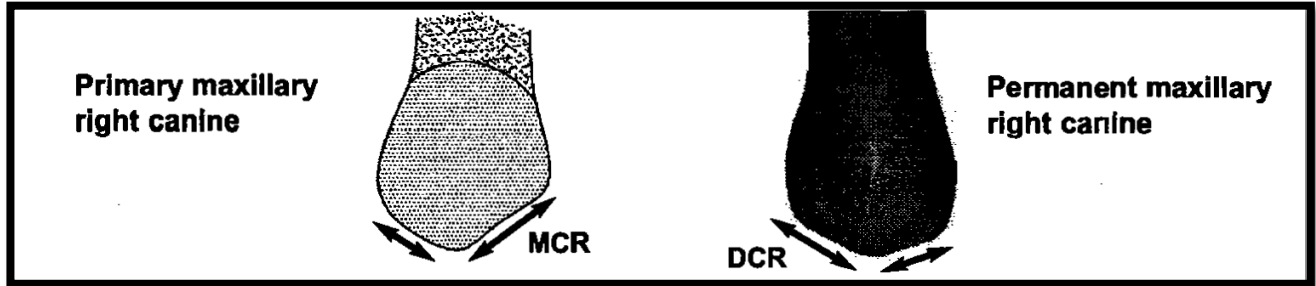
- A. Aphthosis.
- B. Zonal herpes.
- C. Traumatic ulcer. ***

56. (8 years old) come with fractured Max incisor tooth with incipient exposed pulp after 30 min of the trauma , what's the suitable Tx:
- A. Pulpatomy.
 - B. Direct pulp capping. ***
 - C. Pulpectomy.
 - D. Apexification.
57. Child has a habit of finger sucking and starts to show orodental changes, the child needs:
- A. Early appliance. ***
 - B. Psychological therapy.
58. Father for child 12 year pt < asked you about ,the age for the amalgam restoration of his child ,you tell him:
- A. 2 years.
 - B. 9 years.
 - C. 2 decades. ***
 - D. All life.
- Complex amalgam restoration with pins: Smales reported that 72% of amalgam restorations survived for 15 years, including those with cusp coverage.
59. (8 years old) pt. Had trauma to 8 presented after 30 minute of injury He had crown fracture with incipient pulp exposure what u do:
- A. Direct pulp capping. ***
 - B. Pulpotomy.
 - C. Pulpectomy.
 - D. Observe.
60. Child with mental disorder suffer from orofacial trauma, brought to the hospital by his parents, the child is panic and Irritable, the treatment should done under:
- A. Local anesthesia.
 - B. General anesthesia. ***
 - C. Gas sedation.
 - D. Intravenous sedation.
61. Fracture before 1 year of upper central incisor reach the pulp in 8 year old child. How will you manage this case:
- A. RCT.
 - B. Apexification. ***
 - C. Direct pulp capping.
 - D. Indirect pulp capping.
62. (8 years old) child came to your clinic with trauma to upper central incisor with pulp exposure and extensive pulp bleeding your treatment will be:
- A. Direct pulp capping.
 - B. Pulpectomy with gutta percha filling.
 - C. Apexification.
 - D. Pulpotomy with calcium hydroxide. ***

63. Distinguishing between right & left canines can be determined:

- A. Because distal concavities are larger.
- B. With a line bisecting the facial surface the tip lies distally. ***
- C. Others.

Primary canine: We can differentiate between the upper mesial & distal canine by the functional cusp tip is inclined distally if bisectioning crown the cervical line on lingual surface is inclined mesially root curved mesially.



64. (5 years old) pt had extraction of the lower primary molar & he had fracture of the apex of the tooth what is the best ttt:

- A. Aggressive remove .
- B. Visualization & remove.
- C. Visualization & leave. ***

65. (7 y/o boy) came to the clinic in the right maxillary central incisor with large pulp exposure:

- A. Pulpectomy with Ca(OH)₂.
- B. Pulpotomy with Ca(OH)₂. ***
- C. Direct pulp capping.
- D. Leave it.

66. Khalid has Bruxism to be treated with :

- A. Sedative.
- B. Cusp capping.
- C. Vinyl plastic bite guard. ***

A vinyl plastic bite guard that covers the occlusal surfaces of all teeth plus 2 mm of the buccal and lingual surfaces can be worn at night to prevent continuing abrasion. The occlusal surface of the bite guard should be flat to avoid occlusal interference.

67. The most technique use with children:

- A. TSD*** (Tell- Show – Do)
- B. Hand over mouth.
- C. Punishment.

68. Y/o boy came to the clinic in the right maxillary central incisor with large pulp exposure:

- A. Pulpectomy with Ca(OH)₂.
- B. Pulpotomy with Ca(OH)₂. ***
- C. Direct pulp capping.

Children who were pacifier users were significantly more likely to show open bite, posterior crossbite increased overjet, and alteration in cheek mobility than habit-free children action during sucking, which leads to gingival injury recession, and loss of alveolar bone.

69. Pacifier habit what you see in his mouth?

- A. Open bite. ***
- B. Cross bite

70. The most common injures in child is:

- A. Tooth .
- B. Root.
- C. Intrusion of the tooth inside the socket well. ***

71. Child with previous history of minor trauma with excessive bleeding we do test the result is prolong PT & slightly increase clotting time & Test is +ve. the diagnosis is:

- A. Hemophelia B.
- B. Thrombocytopenia.
- C. Vit.K deficiency. ***

A clot may fail to form because of a quantitative or functional platelet deficiency. The former is most readily assessed by obtaining a platelet count. The normal platelet count is 200,000—500,000 cells/mm³. Prolonged bleeding may occur if platelets fall below 100,000 cells/mm³. Treatment of severe thrombocytopenia may require platelet transfusion. Qualitative platelet dysfunction most often results from aspirin ingestion and is most commonly measured by determining the bleeding time. Prolonged bleeding time requires consultation with a hematologist.

72. Netros oxide interference with

- A. Vit b12***
- B. Vit b6
- C. Vit a
- D. Vit c

73. Two weeks baby born with 2 anterior teeth which is highly mobile , and his mother have no problem or discomfort during nursing him what is ur management:

- A. Do not do anthing as the baby have no problem during feeding.
- B. Do not do anything as the mother don`t feel discomfort.
- C. U must extract as soon as possible to avoid accident inhalation of them. ***
- D. Do nothing , it will shell by it self.

Natal teeth are usually members of the primary dentition, not supernumerary teeth, and so should be retained if possible. Most frequently affect mandibular incisor region and, because of limited root development at that age, are mobile. If in danger of being inhaled or causing problems with breastfeeding, they can be removed under local analgesia.

74. After a trauma on a primary tooth what is the least possibility :

- A. Change in the permanent tooth enamel color . ***
- B. change the primary tooth color .
- C. Apex pathologic on primary tooth.

75. At which age will a child have 12 permanent and 12 primary teeth:

- A. 9. ***
- B. 11.

76. In primary tooth for restoration before putting the filling u put:

- A. Base.
- B. Calcium hydroxide.
- C. Varnish.
- D. You put the filling after proper cleaning and drying ***

77. A child with thumb sucking habit he will develop:

A. Anterior open-bite and posterior cross-bite***

78. Immature tooth with external apical third resorption:

A. Ca(OH)₂ application. ***

B. Apexification & GP filling.

79. You examined a child and found that the distal part of the upper primary molar is located mesial to the distal outline of the lower primary molar ... This is called:

A. Distal step***

80. With children rubber dam not use with:

A. Hyperactive patient.

B. Obstructive nose. ***

C. Patient with fixed orthoappliance.

D. Mildly handicapped and uncooperative.

81. Mandibular 1st permanent molar look in morphology as:

A. Primary 1st mand molar.

B. Primary 2nd mand molar. ***

C. Primary 1st max molar.

D. Primary 2nd max molar.

81. Success of pit & fissure sealants is affected mainly by:

A. Increased time of etching.

B. Contamination of oral saliva***

C. Salivary flow rate.

D. Proper fissure sealant.

82. Caries progress in children more than adult due to :

A. Difference in pH.

B. Generalized dentin sclerosing by age. ***

C. Increasing in organic content of tubular dentin by age.

83. The most affect tooth in nurse bottle feeding :

A. Lower molars.

B. Upper molars.

C. Max incisor. ***

D. Man incisor.

84. Child have tooth which have no mobility but have luxation best treatment:

- A. Acrylic splint.
- B. **Non rigid fixation. *****
- C. Rigid fixation.

Luxation with immobilization treatment:

Non-rigid 'physiological' splinting should be applied for a period of no more than two weeks. The various splinting methods are discussed.

85. In children, the mandibular foramen is low in relation to the occlusal plane. When you give inferior dental block for pedit Pt the angulations for the needle :

- A. 7 mm below the occlusal plane.
- B. 5 mm below the occlusal plane.
- C. 7 mm above the occlusal plane.
- D. **At the occlusal plane. *****

Inferior alveolar and lingual nerve blocks:

The height of insertion is about 5 mm above the mandibular occlusal plane, although in young children entry at the height of the occlusal plane should also be successful.

The needle enters the tissues at a point midway between the external oblique ridge and the pterygomandibular raphe at the level of the occlusal plane.

Needle must be inserted at the level of occlusal plane:

The mandibular foramen is situated at a level lower than the occlusal plane of the - primary teeth, therefore the injection must be made slightly lower and more posteriorly than for an adult patient.

What is the difference between a lateral radicular cyst and a lateral periodontal cyst?

A lateral radicular cyst is an **inflammatory** cyst in which the epithelium is derived from Rests of Malassez (like a periapical or apical radicular cyst). It is in a lateral rather than an apical location because the inflammatory stimulus is emanating from a lateral canal. The associated tooth is always NONVITAL.

The lateral periodontal cyst is a **developmental** cyst in which the epithelium probably is derived from rests of dental lamina. It is usually located between the mandibular premolars, which are VITAL.

Apical <<<< Malasseze

Lateral <<<< Serris

Peridontal <<<< Hertwing

Endodontic 225 MCQs

1. **Actual destruction of micro-organisms in the root canal is attributed mainly to:**
 - A. Proper antibiotic thereby.
 - B. Effective use of medicament.
 - C. Mechanical preparation and irrigation of the canal. ***
 - D. None of the above.
2. **A tooth very painful to percussion, doesn't respond to heat, cold or the electric pulp tester. The most probable diagnosis is:**
 - A. Reversible pulpitis.
 - B. Irreversible pulpitis.
 - C. Acute apical periodontitis. ***
3. **RCT contraindicated in:**
 - A. Vertical fracture of root. ***
 - B. Diabetic Pt.
 - C. Unrestored teeth.
 - D. Periodontally involved teeth.
4. **Gutta percha contain mainly:**
 - A. Gutta percha 20%.
 - B. ZINC oxide 75%. ***
 - C. ZINC phosphate.
5. **Single rooted anterior teeth has endodontic treatment is best treated by:**
 - A. Casted post and core. ***
 - B. Performed post and composite.
 - C. Performed post and amalgam.
 - D. Composite post and core
6. **Which of the following endodontic failure may be retreated only with surgery:**
 - A. Missed major canal.
 - B. Persistent interappointment pain.
 - C. Past and core. ***
 - D. Short canal filling.
7. **Which of the following failure may be treated non-surgically:**
 - A. Post filling that has removed. ***
 - B. Severe apical perforation. انتقاب شديد
 - C. Very narrow canal with a periapical lesion and the apex cannot be reached.
 - D. None of the above.
8. **Amount of G.P should after post preparation:**
 - A. 1 mm.
 - B. 4-5 mm. ***
 - C. 10 mm.
 - D. None of the above.

9. Post retention depends on:

- A. Post length.
- B. Post diameter.
- C. Post texture.
- D. Core shape.
- E. Design of the preparation.
- F. A and b
- G. A, B and C. ***
- H. All of the above.

10. The pH of the calcium hydroxide is:

- A. 7.2
- B. 12 ***
- C. 19
- D. 5.5

Promotes a destructive effect on cell membranes and protein structure Dycal (pH of 11) and Pulpdent (pH 12)

11. Hyperemia of the pulp result in :

- A. Trauma of occlusion.
- B. Pain of short duration. ***
- C. Radiographic changes.
- D. All of above.

12. The irrigation solution is good because:

- A. Lubricate the canals.
- B. Flushes the debris and minimizing the No. of micro organism.
- C. None of the above.
- D. All of the above. ***

13. 21 years old Pt with pathological exposure in #35. Management:

- A. Direct pulp capping.
- B. Indirect pulp capping.
- C. Root canal treatment. ***

14. During instrumentation, sudden disappear of root canal due to:

- A. Bifurcation of main canal. ***
- B. Apical perforation.
- C. Calcification.

15. In combined Endo-Perio problem:

- A. Start with endodontic Tx. ***
- B. Start with periodontic Tx.

16. AH26 is root canal sealer consist of:

- A. ZOE.
- B. Epoxy resin. ***

17. Buccal object role in dental treatment of maxillary teeth:

- A. MB root appear distal to P if cone is directed M to D.
- B. DB root appear mesial to P if cone is directed M to D.***

We are talking about the position of the MB, or DB root in relation to the P root if the cone will be directed from M to D (both options) so , according to the BUCCAL OBJECT RULE it says Same Lingual Opposite Buccal (SLOB) , i think that MB and DB root is NATURALLY on the buccal aspect to the Palatal root , so IT SHOULD , an MUST MOVE TO THE OPPOSIT DIRECTION OF THE CONE , because we know that they are on the buccal of P root , the question stated that the cone direction is from M to D in RELATION TO PALATAL ROOT , so the MB and DB roots should move and look in the mesial aspect of the palatal because again WE KNOW that it is BUCCAL to P root i think option b (B) is the correct one.

18. 20 years old male PT came with severe pain on chewing related to lower molars. Intraoral examination reveals no caries, good oral hygiene, no change in radiograph. PT give history of bridge cementation 3 days ago. Diagnosis:

- A. Pulp necrosis.
- B. Acute apical periodontitis. ***
- C. Chronic apical abscess.
- D. None of the above.

19. By aging, pulp tissue will:

- A. Decrease in collagen fibers.
- B. Increase cellularity and vascularity.
- C. Decrease in size. ***

20. Diagnosis prior to RCT should always be based on:

- A. Good medical and dental history.
- B. Proper clinical examination.
- C. Result of pulp vitality test.
- D. A periapical radiographs.
- E. All of the above. ***

21. Which of the following may be used to disinfect gutta percha points

- A. Boiling.
- B. Autoclave.
- C. Chemical solutions. ***
- D. Dry heat sterilization.

22. To disinfect gutta percha points use:

- A. H_2O_2
- B. 5.2% NaOCL
- C. CHX
- D. All of the above. ***

23. Which one of the following is a disadvantage of autoclaving Endo instruments:

- A. It can dull the sharp edges of instruments-cause corrosion- clean should done before. ***
- B. All forms of bacteria are not destroyed by it.
- C. Compared to other technique it takes too long to sterilize.
- D. None of the above.

24. The radiographic criteria used for evaluating the successes of endodontic therapy

- A. Reduction of the size of the periapical lesion. ***
- B. No response to percussion and palpation test.
- C. Extension of the sealer cement through lateral canals.
- D. None of the above.

25. If the maxillary first molar is found to have four, the fourth canal is likely found:

- A. In the disto-buccal root.
- B. In the mesio-buccal root. ***
- C. In the palatal root.
- D. None of the above.

26. What is the basis for current endodontic therapy of a periapical lesion:

- A. Due to rich collateral circulation system, the peripical area usually heals despite the condition of the root canal.
- B. If the source of periapical irritation is removed, the potential for periapical healing is good. ***.
- C. Strong intracanal medications are required to sterilized the canal and periapical area to promote healing.
- D. Periapical lesions, especially apical cyst, must be treated by surgical intervention.

27. Bacteria in endodontic Pathosis mostly is:

- A. Porphyromonas endodontalis obligate anaerobic: ***
- B. Streptococcus mutans.
- C. Streptococcus anaerobic.

28. Bacteria in root canal:

- A. Mixed. ****.
- B. Anaerobes obligatory.
- C. Aerobes only

29. Bacteria in root canal Pathosis:

- A. Mixed anaerobe and aerobe. ***
- B. Single obligate anaerobe.
- C. Aerobic.
- D. None of the above.

When intact teeth with necrotic pulps were cultured, over 90% of the bacteria were strict anaerobes. Because bacteria isolated from root canals are usually a subgroup of the bacteria found in the sulcus or periodontal pockets, it is believed that the sulcus is the source of bacteria in root canal infections.

29.1. Dentin permeability

- A. Decreases with the increase of cavity preparation.
- B. Increase when sclerotic dentin develops under a carious lesion.
- C. Increase with smear layer.
- D. Bacterial toxins can pass through before the actual penetration of bacteria. ***

30. Reparative dentine:

- A. Same like secondary dentine.
- B. Happen as site if irritation. ***

31. Reparative dentine:

- A. 2nd dentine.
- B. Formed as dentine Bridge above the pulp. ***
- C. Highly tubular dentine and it is detective from 1st dentine.
- D. Sclerosing dentine with less permeability.

32. Physiological reaction of edema on vital pulp:

- A. Decrease tissue fluid by decompression of blood vessel.
- B. Increase blood pressure. ***
- C. Necrosis of pulp due to hyperoxia and anaryxia

33. Microabscess on vital pulp: start necrosis of small part and sequela of destruction cycle and full repair:

- A. True.
- B. False. ***

34. Cementum contain cell like bone. It is yellow in color in vital, extracted or avulsed tooth. But in non vital tooth, its color is dark:

- A. True. ***
- B. False.

35. Dentine composition:

- A. 60-65 inorganic by wgt . (70% inorganic by volume). ***
- B. 25% water by wgt. (13% water by volume).
- C. 43% organic by wgt. (20% organic by volume).

36. Barbed broach in endodontic is used for pulp examination in straight canals:

- A. True. ***
- B. False.

37. Emergency endodontic should not be started before:

- A. Establishing the pain.
- B. Check restorability of the tooth.
- C. Establishing the diagnosis. ***

38. Pulp chamber in lower 1st molar is mesially located:

- A. True. ***
- B. False.

39. Radiopacity at the apex of a tooth with chronic pulpitis: Radiopacity at the apex of a tooth with deep carious lesion related to lateral surface of root

- A. Condensing osteitis (a focal sclerosing osteomyelitis). ***
- B. Cemental dysplasia.
- C. Periapical granuloma.

40. Extra canal if present in mandibular incisor will be:

- A. Lingual. 45% - upper incisor 60%
- B. Distal.

41. The access opening in lower incisor:

- A. Round.
- B. Oval. ***
- C. Triangular.

42. The accesses opening for a maxillary premolar is most frequently:

- A. Oval. ***
- B. Square.
- C. Triangular.
- D. None of the above.

43. The correct access cavity preparation for the mandibular second molar is:

- A. Oval.
- B. Quadrilateral.
- C. Round.
- D. Triangular. ***

Lower:

Central: Ovoid
Lateral ; Ovoid
Canine: Ovoid
First Premolar: Ovoid
Second Premolar : Ovoid
First Molar: Trapezoid
Second Molar: Trapezoid

Upper:

Central : Triangular
Lateral: Ovoid
Canine: Ovoid
First Premolar: Ovoid
Second Premolar: Ovoid
First Molar: Triangle
Second Molar Triangle

44. Acute periapical cyst and acute periodontal cyst are differentiated by:

- A. Vitality test. ***
- B. Radiograph.
- C. Clinical examination.

45. Acute periapical abscess associated with :

- A. Swelling. ***
- B. Widening of PDL.
- C. Pus discharge.

46. The most common cause of endodontic Pathosis is bacteria:

- A. True. ***
 - B. False.
- Other causes : Truma – Microleakage

47. Palatal canal in upper molars is curved:

- A. Buccally. ***
- B. Palatally.
- C. Distally.

48. If tooth or root is pushed during surgical extraction into Max Sinus:

- A. Leave it and inform the Pt.
- B. Remove it as soon as possible. ***
- C. Follow the Pt for 3 months.
- D. None of the above.

- 49. To obturate the canal the most important step is:**
A. Cleaning and shaping of the canal. ***
B. Irrigation of the canal.
- 50. The most common endodontic cyst is:**
A. Radicular cyst. ***
B. Keratocyst.
C. Acute apical periodontitis.
- 51. Pt complains from severe spontaneous pain related to upper 6. It respond to vitality test no pain on percussion, diagnosis is:**
A. Irreversible pulpitis. ***
B. Reversible pulpitis.
C. Acute apical periodontitis.
- 52. The most important in RCT is seal:**
A. Apical 1/3. ***
B. Middle 1/3.
C. Cervical 1/3.
- 53. Lateral canal is detected by:**
A. Radiograph. ***
B. Tactile sensation.
C. By clinical examination.
- 54. Disinfection of GP is done by:**
A. Autoclave.
B. Naocl.
- 55. Broken instrument during RCT, best prognosis if broken at:**
A. Apical 1/3. ***
B. Middle 2/3.
C. Cervical 3/3.
- 56. Pulp stone:**
A. Cause discomfort and pain.
B. Free in pulp chamber. ***
C. None of the above.
- 57. Pulp stone can be the following EXCEPT:**
A. Present freely in the pulp.
B. Cause discomfort & pain to the patient. ***
C. In radiographs, Small spheroidal radiopaque.
D. False stone occurs due to dystrophic dentin.
- 58. Among the reasons that molar teeth are more difficult to treat It Endo than anterior teeth:**
A. Molar have more complex canal configuration.
B. Molar tend to have greater canal curvature.
C. A and b. ***
D. None of the above

59. The basic difference between K files and reamers is:

- A. The number of spirals or flutes per unit length.
- B. The geometric cross section. ***
- C. The depth of flutes.
- D. The direction of the spirals.

60. In case of traumatic intrusion of young permanent incisor, the treatment of choice is:

- A. Surgical repositioning of intruded tooth and splinting.
- B. To wait for re eruption of the intruded tooth during months. ***
- C. Slow orthodontic extrusion using light force.
- D. Only antibiotic prescription and wait for eruption.

61. Actual destruction of the micro organism in root canal attributed mainly to:

- A. Proper antibiotic therapy.
- B. Effective use of medicaments.
- C. Natural defenses in healthy person.
- D. Mechanical preparation and irrigation of the canal. ***

62. It is recommended to avoid an intraligamental injection when the planned dental treatment is:

- A. Pulp extirpation.
- B. Pulpotomy. ***
- C. Full crown preparation.
- D. A and b.

63. The root canal treated teeth has the best prognosis when the root canal is instrumented and obturated:

- A. To the radiograph apex.
- B. 1 mm beyond the radiograph apex.
- C. 1-2 mm short of the radiograph apex. ***
- D. 3-4 mm short of the radiograph apex.

64. Pulpal pain may NOT be referred from:

- A. The right maxilla to the left maxilla. ***
- B. The third molar to the ear.
- C. A max molar to the sinus.
- D. An incompletely fractured tooth.
- E. A max cuspid to ear.

65. Spontaneous pulpal pain is indicative of:

- A. Reversible pulpitis.
- B. Irreversible pulpitis. ***
- C. Neurotic pulp.
- D. Hyperplastic pulp.
- E. Atrophic pulp.

66. Internal Resorption:

- A. Painful.
- B. Seldom differentiated external resorption.
- C. Can occur in primary teeth. ***

- 67. Primary teeth had trauma, tooth change in color become white yellowish ,what should you tell the parents:**
- A. Pulp is dead
 - B. Inflammation of pulp.
 - C. Calcification of dentin.
 - D. B & C. ***
- 68. Teeth that are discolored as a result of internal resorption of the pulp may turn:**
- A. Yellow.
 - B. Dark brown.
 - C. Pink. ***
 - D. Green.
- 69. Treatment of internal resorption involves:**
- A. Complete extirpation of the pulp to arrest the resorption process. ***
 - B. Enlarging the canal apical to the resorbed area for better access.
 - C. Utilizing a silver cone and sealer to fill the irregularities in the resorbed area.
 - D. Filling the canal and defect with amalgam.
 - E. Sealing sodium hypochlorite in the canal to remove the inflammatory tissue necrotic in the area of the resorption.
- Irrigation with copious amounts of 5 % sodium hypochlorite may have some effect, but the treatment of choice is to pack the canal and the resorption lacuna with calcium hydroxide paste. By the next visit, the calcium hydroxide will have necrotized any remaining tissue in the lacuna, and the necrotic remnants are readily removed by irrigation with sodium hypochlorite.
- 70. Sensitivity to palpation and percussion indicates:**
- A. Reversible pulpitis.
 - B. Irreversible pulpitis.
 - C. Neurotic pulp.
 - D. Hyperplastic pulpitis.
 - E. Inflammation of the periradicular tissues. ***
- 71. Trauma lead to fracture in the root between middle cervical and apical third:**
- A. Poor prognosis.
 - B. Good prognosis. ***
- 72. Tooth with a fracture between the apical and the middle third, your management:**
- A. RCT for the coronal part only.
 - B. RCT for both.
 - C. Splint the two parts together.
- 73. Pt presented to u with trauma of the central incisor with open apex tooth clinical examination revealed cut of blood supply to the tooth what is the next step:**
- A. Extraction.
 - B. Endo.
 - C. Observe over time. ***

74. Apexification is procedure that:

- A. Finds the most apical stop of the Gutta-Percha in RCT.
- B. Induce the formation of a mineral barrier in the apical region of incompletely root. ***
- C. Is new in the endodontic field.
- D. Involves the surgical removal of the apical region of the root and placement of a retrograde filling material:

75. The preferred material used in Apexification is:

- A. Zinc Phosphate cement.
- B. Zinc Polycarboxylate cement.
- C. Calcium hydroxide. ***
- D. Dycal.

76. What is the time bet. the first onset of HIV virus and the appearance of acute symptoms :

- A. 1-5 years.
- B. 9-11 years. ***
- C. No specific time is known.

77. What is the estimated incubation period of HIV infection:

- A. 4 weeks.
- B. 6 months.
- C. 3 years.
- D. 6 years.
- E. 10 years. ***

The absence of antiretroviral therapy, the median time of progression from infection to AIDS is nine to ten years, and the median survival time after developing AIDS is only 9.2 months. However, the rate of clinical disease progression varies widely between individuals, from two weeks up to 20 years.

78. The normal response of a inflamed pulp to the thermal testing is:

- A. No response.
- B. Lingering painful response.
- C. Hypersensitive painful response.
- D. Painful response that disappears soon after stimulus is removed.

79. The normal response of a vital pulp to the electric pulp testing is:

- A. No response.
- B. Higher than that of the control teeth.
- C. Lower than that of the control teeth.
- D. In a range similar to that of the control teeth. ***

80. Asymptomatic tooth has a necrotic pulp, a broken lamina dura, and circumscribed radiolucency of long duration. The periradicular diagnosis:

- A. Acute apical periodontitis.
- B. Chronic apical periodontitis. ***
- C. Acute exacerbation of chronic apical periodontitis.
- D. Abscess.

81. **A Pt with severe periradicular pain has a necrotic pulp, a broken lamina dura, and circumscribed radiolucency of long duration. The periradicular diagnosis:**
- A. Acute apical periodontitis.
 - B. Chronic apical periodontitis.
 - C. Acute exacerbation of chronic apical periodontitis. ***
 - D. Abscess.
82. **A Pt present in severe pain. The periapical area over the involved tooth is inflamed and swollen. The tooth is mobile and depressible in its socket with a diffused radiolucency. The diagnosis is:**
- A. Acute apical periodontitis.
 - B. Chronic apical periodontitis.
 - C. Acute exacerbation of chronic apical periodontitis.
 - D. Abscess. ***
83. **Which of the following is the longest in the dental arch:**
- A. Maxillary central incisor.
 - B. Maxillary second premolar.
 - C. Mandibular canine.
 - D. Maxillary canine. ***
84. **Traumatically fractured crown of central incisor in an 8-years-old child with pulp exposure (more than 1 mm) half hour ago, medical history is non- contributory and the tooth is not displaced. What is your management:**
- A. Endodontics-pulpectomy and obturation.
 - B. Direct pulpcap with caoh and composite.
 - C. Caoh pulpotomy. ***
 - D. Total extirpation of pulp and CaOH
85. **The use of the rubber dam in endodontics is:**
- A. Frequently required.
 - B. An established rule. ***
 - C. c- Not required.
 - D. d- Time consuming.
 - E. e- Dictated by Pt comfort.
86. **Lesion similar to Endo Lesion:**
- A. Hyperparathyroidism
 - B. Initial stage of cemental dysplasia ***
 - C. Ossifying Fibroma
 - D. Dentigerous cyst.
 - E. Ameloblastoma.
 - F. Lateral periodontal cyst.
 - G. Myxoma & hemangioma.
87. **Endomethasone is a root canal sealer that:**
- A. Dissolve in fluid so it weaken the root canal filling.
 - B. Very toxic contain formaldehyde.
 - C. Contain corticosteroids.
 - D. All the above. ***

88. Cause that master G.P not reach working length although it is the same size of last file:

- A. Dentin debris.
- B. Ledge formation.
- C. A & b. ***
- D. None of the above

Causes if Master Cone did Not Fit to Length :

- Dentine chips packed into the apical extent of the root canal preparation will lead to a decrease in working length, and consequently the master cone will appear to be short. This can be avoided by using copious amounts of irrigant during preparation.
- A ledge in the root canal wall can prevent correct placement of the cone. If the cone hits an obstruction during placement then the end may appear crinkled. It may be possible to remove or smooth a ledge by refining the preparation with a greater taper instrument.
- If the canal is insufficiently tapered, the master cone may not fit correctly because it is binding against the canal walls coronally or in the mid-third. The completed root canal preparation should follow a gradual taper along its entire length. Further preparation may be required with Gates-Glidden burs, orifice shapers or a greater taper instrument.

89. Small access opening in upper central incisor lead to:

- A. Complete removal of the pulp.
- B. Incomplete removal of the pulp. ***
- C. Conservative restoration.

90. In sickle cell anemia O₂ decreased in oral mucosa:

- A. True. ***
- B. False

91. We distinguish between periapical and periodontal abscess:

- A. X-ray examination
- B. Clinical examination
- C. Vitality of the pulp. ***

92. Component of Gutta percha:

- A. 50% Gp & 50% ZOE
- B. 20% Gp & 70% ZOE. ***

(75%) Gutta percha & barium sulfate (inorganic organic (gutta percha) 23% transpolyisoprene.

93. All are irrigation for canals EXCEPT:

- A. Saline.
- B. Hydrogen peroxide.
- C. Naocl
- D. RC prep. ***

94. Properties of ideal Endo Obturation material are all EXCEPT:

- A. Biocompatible.
- B. Radiolucent. ***

95. Very important part in Endo treatment:

- A. Complete debridement of the canal

96. Perio endo lesion the primary treatment:

- A. Endo treatment. ***
- B. Deep scaling and root planning.

97. False negative response of an electric pulp test given:

- A. After trauma
- B. Periodontal disease
- C. In teenager.
- D. ?????????

98. Young with open apex examination test:

- A. Reliable.
- B. Non reliable. ***
- C. None of the above.

99. Tooth requires RCT with bone resorption. Terminate RCT at:

- A. Radiographic apex.
- B. 0.5-1 mm short of radiographic apex.
- C. 0.5-1 mm beyond radiographic apex.

Weine's recommendations for determining working length based on radiographic evidence of root/bone resorption.

A, If no root or bone resorption is evident, preparation should terminate 1.0 mm from the apical foramen.

B, If bone resorption is apparent but there is no root resorption, shorten the length by 1.5 mm.

C, If both root and bone resorption are apparent, shorten the length by 2.0 mm.

Some researchers suggest calculating the working length 1 mm short of the radiographic apex with normal apical anatomy, 1.5 mm short with bone but no root resorption, and 2 mm short with bone and root resorption.

100. Pt came with pain awaken her from sleep 20 a.m. And could'nt sleep later:

- A. Reversible pulpitis.
- B. Irreversible pulpitis. ***
- C. Periodontal pain.

101. Pt with severe pain in lower left mandibular molar, examination positive pulp test , percussion test, no radiographic abnormality, Right side have recent FPD upper:

- A. Chronic apical periodontitis.
- B. Acute apical periodontitis ***
- C. Apical abscess.
- D. None of the above.

102. Most common cyst :

- A. Apical radicular cyst. ***
- B. Keratocyst.

103. To disinfect gutta percha:

- A. Chemical agents.
- B.

104. File #40 means:

- A. 0.40 is the diameter at D. ***
- B. 0.40 is from D1 to D16.

105. Cause of radicular cyst:

- A. Non vital tooth ***
- B. Vital tooth.

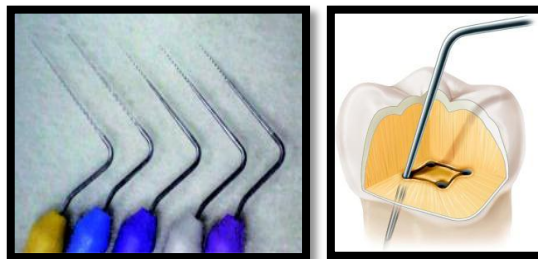
106. To locate the canal orifice use :

- A. Barite probe.
- B. Endo spreader.
- C. Endo file with curved tip.
- D. Round bur.

- Conventional stainless steel files can be precurved and "hooked" into canals.
- Examining the pulp chamber floor with a sharp explorer. (Maxillary Molar)
- An oval orifice must be explored with apically curved small instruments.

The clinician should place the file tip in the orifice with the tip to buccal when trying to locate the buccal canal. A curved file tip is placed toward the palate to explore for the palatal canal.

- Micro-Openers (Dentsply Maillefer, Tulsa, OK) are excellent instruments for locating canal orifices when a dental dam has not been placed.



An endodontic explorer is used to search for canal orifices.

107. Contraindication for Endo treatment EXCEPT:

- A. Non strategic tooth.
- B. Non restorable teeth.
- C. Vertical fracture teeth.
- D. Tooth with large periapical lesion ***

108. Osteogenesis during endodontic surgery aimed to prevent :

- A. Fibrous in growth ***
- B. Growth factor.
- C. Formation of blood.

109. Mix in walking non vital bleaching:

- A. H₂O₂ with phosph.....
- B. Superexol with sod parporate.
- C. Superexol with ca hydroxide.
- D. H₂O₂ with Sodium perborate: ***

110. Irrigant that kills e-faecalis :

- A. NaOCL.
- B. MTAD. ***
- C. Saline.
- D. CHX.

New irrigants are being developed in an attempt to address some of the shortcomings of past and current materials. **MTAD** is a mixture of a tetracycline isomer (i.e., doxycycline), an acid, and a detergent. In an in vitro study, **MTAD** was found to be an effective solution for killing E. Faecalis.

111. The easiest Endo retreatment

- A. Over obturation w GP.
- B. Under obturation w GP.
- C. Weeping canals. ***
- D. Obturated w silver cone.

112. Tug back refers to:

- A. Retention of GP inside the canal. ***
- B. Fluidity of GP.

113. Dental student using thermoplastized GP , He may face;

- A. Extrusion of G.P. From the canal ***
- B. Inability to fill the proper length.
- C. Failure to use master cone at proper length.
- D. Ledge.

It is difficult to control the apical extent of the root filling and in addition some contraction of the GP occurs on cooling. Useful for irregular canal defects.

114. During Endo Tx pt is complaining of pain with percussion what u suspect?

- A. Apical periodontitis.
- B. Secondary apical periodontitis.
- C. Over instrumentation. ***
- D. Over medication.

115. During Endo Tx pt is complaining of pain with percussion what u suspect ?

- A. Apical periodontitis.
- B. Secondary apical periodontitis. ***

Pain following instrumentation: This is usually due to instruments or irrigants, or to debris being forced into the apical tissues.

Postoperative discomfort generally is greater when this area (apical constriction) is violated by instruments or filling materials, and the healing process may be compromised.

116. During doing RCT, pt complains from pain during percussion due to:

- A. Apical infection.
- B. Impact debris fragment
- C. Over instrumentation.

Shaping to the radiographic apex is likely to produce overinstrumentation past the apical foramen, with possible clinical sequelae of postoperative pain and inoculation of microorganisms into periapical spaces.

Over instrumentation

الجواب الأنسب وهو ما يحدث في الحياة العملية هو

117. After u did RCT to your pt he came back to the clinic after few days with severe pain on biting, you did x-ray and it revealed that the RCT filling is very good, but u saw Radiopaque , thin (film like) spot on the lateral border of the root what is the most probable diagnosis?

- A. Accessory canal.
- B. Vertical root canal fracture. ***

118. Pt came after 24 month of tooth replantation which had ankylosis with no root resorption. It most likely to develop root resorption in:

- A. Reduce greatly. ***
- B. Increase.
- C. After 2 years.
- D. After 4 years.

يحدث التكلس في ٦-٣٥ % من حالات الانخلاع الكامل ، وإذا ترافقت إعادة الزرع بالتصاق فيكون احتمال النجاح ٨٠ % ونسبة تموت اللب ١٣-١٦ %

119. Tracing of GP used for :

- A. Source of periapical Pathosis ***
- B. Acute periapical periodontitis.
- C. Periodontal abscess.
- D. None.

120. Isolated pocket in:

- A. Vertical root fracture.
- B. Palato-gingival groove.
- C. Endo origin lesion.
- D. All. ***

121. CMCP contains phenol in concentration:

- A. 0.5 %.
- B. 35 %. ***
- C. 65 %.
- D. 5 %.

Disadv's of McSpadden Tech:

1. Use of speed higher than recommended>> poor seal.
2. Extrusion of the filling material.
3. Fracture of thermocompactor.
4. Gouging of the canal wall.
5. Inability to use the technique in curved canals.
6. Heat generation may lead to PDL damage, resorption and ankylosis.
7. Voids in final filling.

If the file is turning in reverse, it can screw itself into the canal and periapical tissues

122. What is the disadvantages of McSpadden technique in Obturation :

- A. Requires much practice to perfect. ***

123. Thermo mech. Tech of obturation is:

- A. Thermafil.
- B. Obtura.
- C. Ultrafil.
- D. McSpadden. ***

124. During clinical examination the patient had pain when the exposed root dentine is touched due to:

- A. Reversible pulpitis.
- B. Dentine hypersensitivity. ***
- C. Irreversible pulpitis.

125. The patient have dull pain and swelling and the PA shows apical radiolucency your diagnosis will be:

- A. Acute periodontal abscess.
- B. Chronic periodontal abscess with swelling. ***

126. The most superior way to test the vitality of the tooth with:

- A. Ice pack.
- B. Chloro ethyl.
- C. Endo special ice. ***
- D. Cold water spray.

Once we have determined that a particular tooth is indeed percussive, the next step is to determine the pulp status of that tooth (vital or non-vital). Without question, the method most commonly employed by Endodontists is the thermal test. When doing a cold test, "Endo Ice", (a refrigerant) can be sprayed on a cotton pellet and then placed on a dry tooth. This test, along with the percussion test are the two most important tests in diagnosis. If the patient feels nothing and there is no response from the tooth, we must assume this tooth to be necrotic (non vital).

127. All these are contraindicated to RCT EXCEPT:

- A. Non restorable tooth.
- B. Vertical root fracture.
- C. Tooth with insufficient tooth support.
- D. Pt who has diabetes or hypertension. ***

128. Avulsed tooth is washed with tap water , it should be replaced again:

- A. Immediately. ***
- B. After 2 hours.
- C. 24 hr's.

129. Mechanochemical prep'n during RCT main aim:

- A. Widening of the apex.
- B. Master cone reaches the radiographic apex.
- C. Proper debridement of the apical part of the canal. ***

130. Master cone doesn't reach the apex:

- A. Ledge.
- B. Residual remnants (debris)
- C.
- D. 1&2. ***

131. Child patient with obliteration in the central permanent incisor. What to do :

- A. RCT.
- B. Pulpotomy.
- C. Pulpectomy.
- D. Careful monitoring*****

132. At which temperature that gutta percha reach the alpha temp:

- A. 42-48C ***
- B. 50-60.
- C. 70-80.
- D. 100C.

133. After completion of orthodontic treatment he came complaining of pain in 11 tooth radiograph show absorption in the middle third of the root of 11 wt is the proper management:

- A. Apply caoh at the site of resorption. ***
- B. Do RCT in a single visit.
- C. Extract the tooth & reimplant it.
- D. Extract the tooth & do implantation.

Bowl -shaped area of resorption in involving cementum dentin characterize external inflammatory root resorption, this type of external resorption is rapidly progressive and will continue if treatment is not instituted. the process can be arrested by immediate root canal treatment with calcium hydroxide paste. remembre the etiology of external resorption : excessive orthodontic forces, periradicular inflammation, dental trauma, impacted teeth.

134. In a curved root u bent a file by:

- A. Put gauze on the file & bend it by hand ***
- B. Bend the file by pliers.
- C. By bare finger.

135. What are the disadvantages of Mcspadden technique in obturation:

- A. Increase time.
- B. Increase steps.
- C. Difficult in curved canals. ***
- D. All the above.

136. How do you know if there are 2 canals in the same root:

- A. Radiographically with 2 files inside the root. ***
- B. The orifices are close to each other.
- C.x

137. The best way to remove silver point:

- A. Steiglitz pliers. ***
- B. Ultrasonic tips.
- C. H files.
- D. Hatchet.

- A grasping tool such as the Stieglitz pliers (Henry Schein) can generally get a strong purchase on the coronal end of a silver point and then, utilizing the concept of fulcrum mechanics, elevate the silver point out of the canal.

- Ultrasonics is another important method to remove silver points. It is not wise to place any ultrasonic instrument directly on the silver point because it will rapidly erode away this soft material.

- Cement can be removed carefully from around the point using a Piezon ultrasonic unit and CT4 tip or sealer tip. Great care must be taken not to sever the point and damage the coronal end. The point is withdrawn using Stieglitz forceps or small-ended artery forceps.

138. 10 years pt come with necrotic pulp in upper central with root apex not close yet best treatment :

- A. Calcium hydroxide. ***
- B. Calcific barrier.
- C. Apexification with gutta percha filling.
- D. Gutta percha filling.

A premixed syringe of calcium hydroxide-methylcellulose paste is injected into the canal until it is filled to cervical level. The paste must reach the apical portion of the canal to stimulate the tissue to form a calcific barrier.

The action of calcium hydroxide in prompting formation of a hard substance at the apex is best explained by the fact that calcium hydroxide creates an alkaline environment that promotes hard tissue deposition.

139. Child 10 years came with trauma on the center incisor from year ago ,and have discoloring on it , in the examination ,no vitality in this tooth ,and in the x ray there is fracture from the edge of the incisal to the pulp ,and wide open apex the best treatment ?

- A. Calcification. ***
- B. RCT with gutta percha.
- C. Extraction.
- D. Capping

140. Patency Filling :

- A. Push the file apically to remove any block at the apex ***
- B. Rotate the file circumferentially at the walls to remove any block of lateral canals.
- C. Rotary files circumferentially at the walls to remove any block of lateral canals.
- D. File with bleaching agent.

141. The tip of size 20 endo file is:

- A. 0.02 m.m.
- B. 0.2 m.m. ***

142. Pt come with pain tooth #14. When drink hot tea . Pain continuous for 10 minutes diagnosis:

- A. Irreversible pulpitis. ***
- B. Necrotic.

143. Pulp with age:

- A. Reduce collagen fiber.
- B. Increase cellular in pulp.
- C. Decrease pulp chamber size.***

144. Over extended GP should remove using:

- A. Ultrasonic vibrating.
- B. Dissolving agent.
- C. Rotary or round bur.
- D. Surgery.

145. Ideal properties of RC filling material is the following EXCEPT:

- A. Radiolucent in radiograph. ***
- B. Not irritate the surrounding tissue.
- C. Easily removable when retreatment is necessary.
- D. Stable and less dimensional change after insertion.

146. The best method for core build up is:

- A. Amalgam. ***
- B. Compomer.
- C. Glass ionomer.

light-cure composite resin (President) and amalgam (Cavex avalloy) were statistically different than the other materials tested. They are stronger than compomer followed by resin modified glass ionomer and conventional glass ionomer core materials.

147. Best core material receiving a crown on molar:

- A. Amalgam. ***
- B. Reinforced glass ionomer.
- C. Composite.

Direct method Pre-formed posts are cemented into one or more canals. Amalgam may also be Packed into the coronal aspect of the root canals (Nayyar core technique) and an amalgam core Built up, which is the preferred technique. Resin modified GI or resin composite may also be used. These materials have the advantage that the preparation can be completed at the same visit. A Dentine adhesive system should be used with resin composite to enhance retention.

- Composite resin cores exhibit greater microleakage than do amalgam cores,²⁹ and they are not as dimensionally stable as amalgam in an vitro study. crowns made for teeth with composite resin cores failed to seat by 226 um more than crowns made for teeth with amalgam cores after immersion in body-temperature normal saline solution for 1 week. The surface of a composite resin core is affected adversely by exposure to zinc oxide-eugenol temporary cement,³¹ although that does not seem to have a negative effect on the tensile strength of the final crown.

148. Outline of lower 2nd molar access cavity:

A. Triangular with the base mesially***

149. The outline form of upper maxillary molar access opening is Triangular, The base of this triangle is directed toward :

A. Buccal. ***

B. Palatal.

C. Mesial.

D. Distal.

150. Irrigation solution for RCT ,when there is infection and draining from the canal is :

A. Sodium hypochlorite.

B. Iodine potassium.

C. Sodium hypochlorite and iodine potassium. ***

Therefore, like citric-acid rinsing, EDTA solution is recommended before the placement of calcium hydroxide. At a 15% concentration, citric acid has been shown to be very effective against anaerobic bacteria. Solvidont, a bisdequalium acetate, exhibits good antibacterial properties, but also an unfavorable relationship between cytotoxicity and antibacterial efficiency. Physiologic saline (NaCl) is the most tissue-friendly rinsing solution, but its antibacterial effect is quite low. Iodine and also potassium iodine are good antiseptics with equally good tissue biocompatibility. "Betadine" is the commercially available product. With paraformaldehyde or phenol-containing solutions, on the other hand, the tissue toxicity is higher than the antibacterial efficacy.

151. Irrigation solution for RCT , when there is infection and draining from the canal is ;

A. Sodium hypochlorite.

B. Iodine potassium.

C. Sodium hypochlorite and H₂O₂. ***

152. Best way to detect presence of 2 canals :

A. Putting 2 files & take x-ray ***

153. 6 years old patient received trauma in his maxillary primary incisor, the tooth is intruded. The permanent incisors are expected to have:

A. Yellowish or whitish discoloration with hypoplasia. ***

B. Displacement.

C. Malformation.

D. Cracks in enamel.

Enamel hypoplasia : Trauma or infections of developing teeth.

154. In the pulp :

A. Cell rich zone inner most pulp layer which contain fibroblast.

B. Cell free zone rich with capillaries and nerve networks.

C. Odontoblastic layer which contain odontoblast. ***

155. 3rd generation of apexo locator:

- A. Use with all pt.
- B. Need more research.
- C. Increase chair time.
- D. Decrease radiographic film need. ***

156. Saline coupling agent .. wetting wall of pulp :

- A. Decrease wall tension***
- B. Increase wall tension.

157. In Endo , one of sealer property is to be Flowable (or wettability) , to enhance this quality we can mix it with a material that have:

- A. Low surface tension. ***
- B. High surface tension.

Etch enamel and dentine (total etch concept). Wash and remove excess moisture, but do not dry. Silane acts as an adhesive between the inert filler and the organic matrix.

158. Female patient came to your clinic with continuous severe pain related to 1st Max molar. After examination dentist diagnose the tooth is carious and has irreversible pulpitis. He decides to do RCT. After enough time for anaesthisation, the patient won't allow the dentist to touch the tooth due to severe pain. Dentist should:

- A. Give another appointment to the patient with description of antibiotics.
- B. Extraction.
- C. Intra-pulpal anaesthesia.

159. Which of the following canals in # 14 is most difficult to locate :

- A. Palatal.
- B. Distobuccal.
- C. Mesibuccal. ***
- D. All of above.

160. Which condition is an apical lesion that develop acute exacerbation of chronic apical abscess:

- A. Granuloma.
- B. Phoenix abscess. ***
- C. Cyst.
- D. Non of above.

161. Acute exacerbation of chronic pulpitis:

- A. Reversible pulpitis.
- B. Irreversible pulpitis.
- C. Acute periodontitis. ***
- D. Acute exacerbation of chronic pulpitis.

162. Sealer is used in RCT to:

- A. Fill in voids. ***
- B. Increase strength of RC filling.
- C. Disinfect the canal.

163. Patient with pain on the upper right area, and the patient cannot tell the tooth causes the pain , what is the least reliable way to do test pulp:

- A. Cold test.
- B. Hot test.
- C. Electric test. ***
- D. Stimulation the dentine.

164. The best definition to odontoblastic:

- A. It 's subjacent to predentine, odontoblastic process..... ***
- B. Odontoblast cell is more in the cellular pulp than radicular.

Odontoblastic layer; outermost layer which contains odontoblasts and lies next to the predentin and mature dentin.

165. Non odontogenic Lesion similar to Endo Lesion:

- A. Hyperparathyroidism.
- B. Initial stage of cemental dysplasia. ***
- C. Ossifying Fibroma.
- D. Dentigeaus cyst.
- E. AmeLobLastoma.
- F. Lateral periodontal cyst.
- G. Myxoma & Hemangioma.

In the early radiolucent stage periapical cemental dysplasia PCD lesions,the most important differential diagnosis is the periapical rarefying osteitis.

166. The mineral Trioxide aggregate is best material for :

- A. Indirect pulp capping.
- B. Apexogenesis.
- C. Apexofication.
- D. Root canal Obturation.
- E. All except A.

MTA will be with direct pulp capping .

MTA used :

Direct Pulp Capping / Apexification / Perforation / Internal & External Resorption / Root End Filling.

167. The fundamental rule in the endodontic emergencies is :

- A. Control pain by inflammatory non steroid.
- B. Diagnosis is certain. ***

168. Female pt come with Endo treated upper central with MD caries & have Pt come with sinus u make GP tracing & take radiograph the GP appear in lateral surface of the root :

- A. Periodontal abscess.
- B. Periodontitis.
- C. Lateral accessory canal. ***

169. Tech of Endo fill where we use continuous condensation :

- A. Vertical condensation***

"Continuous wave of condensation" in the vertical condensation paragraph"

170. Post graduate student use MTA , the prognosis depend on prevent :

- A. Immediate suture.
- B. Disturbance during closure of wound. ***
- C. Using a flab.

171. What is the concept of Pro-taper system :

- A. Step down tech.
- B. Step back tech.
- C. Crown down tech.. ***

172. The main link between the pulp and the periodontium is:

- A. Apical foramen. ***
- B. Dentinal tubules.
- C. Accessory canals.
- D. PDL.

173. Patient came with severe pain related to right 1st mandibular molar, there's no swelling Related, pulp test is negative, no evidence in radiograph. Diagnosis:

- A. Irreversible pulpitis
- B. Acute periodontal abscess. ***
- C. Suppurative periodontal abscess

174. Pain in central incisors could from :

- A. Central & lateral incisors. *** (Collateral Innervations)
- B. Lateral & canine.
- C. Canine & premolar.
- D. Premolar & molar.

175. To treat non vital tooth with open apex when doing access opening with Gates Glidden bur take care to :

- A. Remove all dentin.
- B. Remove minimal dentine. ***
- C. Follow conservative method.

176. 20 years old pt have avulsed tooth for 60 min the management to return vascularity of the tooth:

- A. Scrap the surface of the root.
- B. Place the tooth in sodium sulfide of X %
- C. Place it in sodium chloride then sodium sulfide. ***

Avoid handling root surface. If tooth contaminated, hold crown and agitate gently in saline. extraoral time is longer 60 minutes, soak the tooth in citric acid and fluoride to make the root as resistant to resorption as possible. Consult a dentist.

177. Acute periapical abscess characterized by:

- A. Varying degree of pain.
- B. Varying degree of swelling.
- C. Some time not shown on the radiograph.
- D. All the above. ***

178. 4th canal in upper first molar is found:

- A. Lingual to MBC. ***
- B. Buccal to MBC.
- C. Distal to MBC.

179. To get file size 24 , the following length should be cut from file size 20:

- A. 1mm.
- B. 2mm. ***
- C. 3mm.
- D. 4mm.

180. Red color Endo file according ISO :

- A. 20
- B. 25 ***
- C. 30
- D. 35

181. The following canals may be found in an upper molar:

- 1. Mesio-buccal.
- 2. Disto-buccal.
- 3. Mesio-palatal.
- 4. Disto-lingual.
- 5. Palatal.
- A. 1+2+4.
- B. 1+2+4+5.
- C. 2+3+4+5.
- D. 1+2+3+5. ***

182. When resection the tip of root in Apicsactomy , the cut should Be :

- A. Perpendicular to the long axis of tooth
- B. Parallel to long axis
- C. Acute angle. ***
- D. Obtuse angle

183. When An intraosseous anesthesia is planned for treatment of an endodontic pathology , the surgeon should :

- A. Perforate mesial bone to do anesthesia. ***
- B. Inject 1/3 or 1/4 of the carpool.
- C. Use lignocaine with 1/50 000 epinephrine.
- D. Ask the pt if he has anesthesia.

184. The decision to retreat substandard endodontic should be based on :

- A. Radiographic evaluation of the endodontic treatment quality. ***
- B. ----- periapical pathology.
- C. Patient symptoms.
- D. Physical exploration of the root canal type and quality seal.
- E. Restorative treatment plan.

185. The best test for vitality of crowned tooth is :

- A. Cold with Rubber dam. ***

186. Intraosseous injection of local anesthesia to lower molar :

- A. Perforate the bone mesial to the tooth.
- B. Give one with 1:50000 epinephrine.
- C. Give 1/4 to 1/5 of the cartridge. ***
- D. Ask the pt if he has numbness in his lower lip after injection.

187. When take x ray in upper premolar to locate lingual root using mesial shift it will appear :

- A. Distal.
- B. Buccal.
- C. Lingual.
- D. Mesial.***

188. While taking X-ray for upper right first premolar with two equal roots Using mesial slob, its lingual root will move [Comparing to the Zygomatic Process]:

- A. Distal.
- B. Mesial. ***
- C. Palatal.
- D. Lingual.

189. Smear layer composed of:

- A. Dentine debris.
- B. Inorganic particles.
- C. Bacteria.
- D. All the above. ***

- The smear layer is a film of microcrystalline debris that remains on dentin after it is cut with rotary instruments.
- After removing the organic and inorganic debris of the smear layer by etching.
- The composition of the smear layer is basically hydroxyapatite and altered denatured collagen.
The smear layer consists of an amorphous layer of organic and inorganic debris, produced by cutting dentine.

The smear layer is composed of dentin debris, organic material and microorganisms that adhere to the root canal walls obstructing the openings of the dentin tubules, which can hinder the action of medicine in the dentin tubules and root canal system. Removal of this layer is important for the success of the endodontic treatment and is obtained with the use of chemical solutions during root preparation.

190. During making filing by Ni/Ti it gets fractured due the property of:

- A. Rigidity &
- B. Axial fatigue. ***
- C. Tustin.

191. Which of these canal irrigants is UNABLE to kill E.fecalis:

- A. NaOH.
- B. CHX.
- C. MTAD irrigants is able to kill E.fecalis.

192. While dentist making Biomechanical preparation by using NI TI file it broken this is because the property of ;

- A. Elasticity and memory.
- B. Rigidity and memory.
- C. Axial fatigue. ***
- D. Tarnish.

The most important reason for breaking NI TI files is cyclic fatigue and torsional stress.

193. Root end resection ... what is the conditioning:

- A. Cetric acid. ***
- B. Tetracyclin.
- C. EDTA.

194. Apicoectomy means :

- A. Surgical removal of the apical portion of the root. ***
- B. Removal of one or more roots.
- C. The root and the crown are cut lengthwise.
- D. None.

195. Patient have during recurrent normal check he had (different sense) on percussion on his tooth and x-ray widening lamina dura apical 3rd:

- A. Chronic apical periodontitis. ***
- B. Acute apical periodontitis.
- C. Chronic abscess.

196. EPOXY RESIN:

- A. Contain formaldehyde toxic.
- B. Contain corticoid steroids.
- C. Resrbable so it weakens the Endo fill.
- D. All of the above.

197. Extra canal in upper 6 present in which Root :

- A. MB Root. ***
- B. DB Root.
- C. Palatal Root.

198. In case of internal resorption your ttt is :

- A. Ca(OH)₂ application. ***
- B. Formocresol medicament.
- C. Zinoxide eugenol.

199. Using a larger file while reducing the length in Endodontic is called:

- A. Step back. ***

200. Aim to shape apical 3rd of the root:

- A. Widening apex.
- B. Permit irrigation to reach apical 3rd.
- C. Permit GP fill.
- D. For good sealer achieve.

207- For root canal treated tooth u choose to put post & amalgam this depend on:

- A. Remaining coronal structure ***.
- B. Root divergence-.
- C. Presence of wide root-
- D. Others.

208- Pt came with class IV he had tooth trauma & he brought the fracture segment & on examination u found that the pulp is not exposed & only u can see dentine, how u manage:

- A. To get rid of the fragment & fill with composite.
- B. To reattach the fragment with composite and latter cover with veneer. ***

209- Tooth had trauma resulted in hyperemia:

- A. Pain increased with cold .
- B. Reversible condition.
- C. Pain of short duration .
- D. B and C. ***
- E. All of the..

210- In maxillary 1st molar 4th canal is found in:

- A. MB canal. ***
- B. DB canal.
- C. Palatal root.

211- The normal response of a vital pulp to the thermal testing is:

- A. No response.
- B. Lingering painful response.
- C. Hypersensitive painful response.
- D. Painful response that disappears soon after stimulus is removed. ***

212- With weeping canal we use :

- A. GP.
- B. CaOH. ***

This situation is often referred to as a “weeping canal” and is annoying in that the apical part of the canal cannot be dried properly. The right therapy is a discontinuation of the use of the tissue-irritating antiseptics followed by 2–3 weeks of calcium hydroxide in the root canal. The chemically-induced exudation will then have stopped and the root canal can be dried and obturated.

213- Perforation during Endo space preparation what is the most surface of distal root of lower molar will have tendency of perforation:

- A. Mesial Surface. ***
- B. Distal surface.
- C. Buccal surface.
- D. Lingual surface.

214- Crown and root perforation:

- A. Respond to MTA.
- B. Use matrix with hydroxyapatite and seal with GI.
- C. Root canal filling.
- D. A & B. ***

215- Acceptable theory for dental pain:

- A. Hydrodynamic. ***
- B. Fluid movement.
- C. Direct transduction.

-The most accepted theory to explain the unusual sensitivity and response of exposed root surfaces to various stimuli is the hydrodynamic theory.

- Most authorities agree that the hydrodynamic theory "best explains dentin hypersensitivity. The equivalency of various hydrodynamic stimuli has been evaluated from measurements of the fluid movement induced in vitro and relating this to the hydraulic conductance of the same dentin specimen."

216- While u were preparing a canal u did a ledge, then u used EDTA with the file, this may lead to:

- A. Perforation of the strip.

217- Removing of dentine in dangerous zone to cementum is:

- A. Perforation. ***
- B. Ledge.
- C. Stripping.
- D. Zipping.

218- Follow up of RCT after 3 years , RCT failed best treatment is to:

- A. Extraction of the tooth.
- B. Redo the RCT. ***
- C. Apicectomy.

219- Acute abscess is:

- A. Cavity lined by epithelium.
- B. Cavity containing blood cells.
- C. Cavity containing pus cells. ***
- D. Cavity containing fluid.

An abscess is a pathological cavity filled with pus and lined by a pyogenic membrane.

220- The most close tooth to the maxillary sinus:

- A. Maxillary 1st molar. ***

221- Patient with radiopacity in the periapical area of a 1st mandibular molar with a wide carious lesion and a bad periodontal condition is:

- A. Condensing osteosis ***
- B. Hypercementosis

222- Perforation in the Furcation area:

- A. Mineral Trioxide Aggregate (MTA). ***
- B. CaOh.
- C. Formocresol.

223- Adding of surfactant to irrigation solution during RCT to increase wettability of canal walls by:

- A. Lowering surface tension***
- B. Increasing surface tension.
- C. Passing through dentinal tubules.

223- Thermal pulp test principle of:

- A. Blood supply of pulp.
- B. Nerve supply of pulp. ***
- C. AO fibers.

224- During endodontic surgery the irrigation solution used is:

- A. Saline. ***
- B. EDTA.
- C. Naocl.

225- The least effective irrigants against E.feacalis :

- A. Sodium hypochlorite.
- B. Tetracycline. ***
- C. Iodine.
- D. Chlorhexidine.

Causes of are:

- 1- Tensile
- 2- Fatigue
- 3- Creep
- 4- Steress corrosion cracking
- 5- controled crack propagation

Fatigue is: occurs when cyclic loading is applied, like fracture of a denture retentive clasp arm after several years of service

Deviation of the roots and trends that deviate. ((Study Only))

Maxillary central incisors:

Curve either towards the labial or palatal aspect at about the apical third level.

Maxillary lateral incisor:

The apical third tends to curve distally and the canal is often very fine with thin walls.

Maxillary canine:

The length of this tooth can be difficult to determine on radiographs as the apex tends to curve labially and the tooth will appear to be shorter than it actually is.

Maxillary first premolar:

The roots of these teeth are very delicate and at the apical third they may curve quite sharply buccally palatally, mesially or distally, so instrumentation needs to be carried out with great care

Maxillary second premolar:

As with the first maxillary premolar the apical third of the root may curve quite considerably , mainly to the distal sometimes buccally

Maxillary first molar:

The palatal root has a tendency to curve towards the buccal and the apparent length on a radiograph will be shorter than its actual length

Mandibular second premolar:

Unless the radiograph reveals a sharp distal curve at the apex as shown in the extracted tooth.

Community Dentistry 85 MCQs

1. In countries with higher annual population growth rates, the need for community based preventive programs would be greater for:

- A. Dental caries. ***
- B. Periodontal disease
- C. Dentofacial anomalies
- D. Dental floozies.

2. Dental carries is an endemic disease "means that the disease is:

- A. Occurs clearly in excess of normal expectancy.
- B. Is habitually present in human population. ***
- C. Affect large number of countries simultaneously.
- D. Exhibit a seasonal pattern.

3. Recent years, there has been an evidence that the prevalence and intensity of the caries attack has been diminishing in the more economically developed countries, mainly because of the wide spread use of:

- A. Artificial water fluoridation. ***
- B. Fluoride toothpaste
- C. Dental health education programs
- D. A & C.

أصبح من المعروف تماماً أن استخدام الفلورايد في مياه الشرب بالدول المتقدمة أدى لإنقاص نخر الأسنان بنسبة ٥٠-٦٠%

4. Cost effective method to prevent dental caries:

- A. Water fluoridation. ***
- B. Fluoridated tooth paste.

5. In terms of caries prevention, the most effective and most cost effective method is: Community based programs.

- A. Private based programs.
- B. Individually based programs. ***

One-to-one in the clinical environment. This is usually the most successful approach, because the message can be tailored to the individual and reinforcement is facilitated. However, it is expensive in terms of manpower.

6. The effects of natural fluoride versus added fluoride in reducing dental caries as it relates to the concentration are:

- A. Greater.
- B. Less. ***
- C. The same.

7. When does child should be first exposed for using tooth brush:

- A. As eruption of first tooth. ***
- B. One year old.
- C. Two years old.
- D. Primary school year.

8. When a child must first exposed to the use of the tooth brush:

- A. Of age of 2 years.
- B. Of age of 4 years.
- C. Immediately after eruption of first tooth. ***

Fluoridated toothpaste for 3 years child is recommended but under supervision in small pea-sized amount. Brushing using a fluoride toothpaste should start as soon as the first teeth erupt (about 6 months of age). Parents should supervise brushing up to at least 7 yrs of age to avoid over-ingestion of toothpaste and ensure adequate plaque removal.

9. Fluoride which we use in the clinic doesn't cause fluorosis because:

- A. It's not the same fluoride that cause fluorosis.
- B. Teeth already calcified. ***
- C. Calcium in the mouth counter.
- D. Saliva wasn't out.

10. Mentally ill Child The best way to apply fluoride:

- A. Acidulated phosphate fluoride.
- B. Natural Sodium Fluoride.
- C. Fluoride varnish. ***
- D. Stannous fluoride.

E.

11. Fluoride decrease dental caries by remineralization of enamel:

- A. True. ***
- B. False.

12. Person drinking fluoridated water, using toothbrush with fluoride, rinsing with fluoride mouthwash, then no need to put pit and fissure in his permanent teeth:

- A. True.
- B. False. ***

13. Dental fluorosis:

- A. Is indicative of systemic fluorosis. ***
- B. Can be contracted at any age.
- C. Becomes less noticeable with age.
- D. Is reversible.
- E. Is largely preventable.

14. Fluorides are most Anticaries effective when:

- A. Incorporated in the tooth enamel. ***
- B. Present in the blood stream.
- C. Present in the plaque and tissue fluids bathing the newly erupted tooth.
- D. Present in the ingested foods.
- E. Present on the intraoral mucous membranes.

15. **Fluoride is not taken up systemically from which of the following sources:**
 A. Water.
 B. Food.
 C. Dentifrices.
 D. Topical applications of fluoride. ***
16. **Fluoride reduces caries activity by:**
 A. Reduces bacterial adhesion and carbohydrate storage (antimicrobial activity).
 B. Enhances the precipitation of insoluble fluoroapatite into the tooth structure.
 C. Fluoride enhances remineralization of the non-cavitated carious lesions.
 D. All of the above.
 E. B & C. ***
17. **Communities with high annual population growth need education about:**
 A. Caries. ***
 B. Perio disease.
 C. Dentofacial anomalies.
 D. Dental fluorosis.
18. **Optima water fluoridation:**
 A. 1-1.5 mg\liter. ***
 B. 0.2-0.5 mg\liter.
 C. 2-3 mg\liter.
- وفي المناطق الحارة حيث يكثر شرب الماء يجب أن يكون تركيز الفلورايد أقل التركيز (١,٧) - (٢,٠) جزء بالمليون.
19. **Acidulated phosphate fluoride :**
 A. 1% fluoride ions.
 B. 1.23 %. ***
 C. 2 %.
 D. 2.23 %.
20. **One of these is less exposed to extensive dental caries:**
 A. Obes , malnourished.
 B. Pt has Xerostomia.
 C. Less plaque score. ***
21. **Most convenient and effective form of sterilization of dental instruments:**
 A. Boiling.
 B. Autoclave. ***
22. **The role of good sterilization:**
 A. Washing, inspection, autoclave, drying, storage.
 B. Inspection, autoclave, drying, storage.
 C. Autoclave, drying, storage.
 D. Autoclave is enough.
23. **Protocol of sterilization**
 A. Initial cleaning, inspection , cleaning, sterilization, storage. ***

24. **Autoclave relative to 100 F. dry oven:**
A. The same time.
B. Slightly higher time.
C. Considerable higher time.
D. Less time. ***
25. **What is the type of sterilization applied on ligation/fixation wires:**
A. Autoclave. ***
26. **Why the moisture heat sterilization is better than dry heat sterilization:**
A. Makes the instruments less rusty and blunt.
B. Needs more time and affects the proteins of the cell membrane.
C. Needs less time and affects the proteins of the cell membrane. ***
27. **Causes dullness:**
A. Breaks the protein cell membrane at moderately low temp. ***
B. Breaks the protein cell membrane at very high temp.
28. **Dentist must:**
A. Treat PT medically.
B. Prescribe medication to Pt with medical problem
C. do clinical examination, take medical history and evaluate the medical state. ***
29. **After patient came to your clinic and gave an extended history and complain, what's your next step in treatment :**
A. Clinical examination. ***
B. Start the treatment.
C. Radiographic examination.
30. **Radiotherapy increase caries by decreasing salivary secretion:**
A. True. ***
B. False.
31. **The most important microorganism in dental caries is:**
A. Streptococcus mutant. ***
B. Streptococcus salivarius.
C. Spirochaeta.
32. **Dental caries:**
A. Is a transmissible disease
B. Is world wide in distribution but uneven in intensity.
C. Can be prevented
D. All of the above. ***
E. None of the above.

Dental caries is a transmissible and multi-factorial disease. It suggests an impact on populations of entire countries, continents, or much of the world. The term therefore implies two elements: global distribution and severe consequence. Dental caries is a disease that usually can be successfully prevented or controlled.

33. **Which one of the following is least likely to contribute to oral bad breath:**
 A. Periodontal disease.
 B. Denture. ***
 C. Faulty restoration.
 D. Carious lesions.
34. **The most common activity associated with percutaneous injury of the dentist is:**
 A. Suturing.
 B. Anesthesia injection. ***
 C. Handpiece dig.
 D. Trimming impressions.
35. **The most common location of percutaneous injury among dentist is:**
 A. Hand. ***
 B. Face.
 C. Elbow.
 D. Arm.
36. **When take an x-ray to pregnant lady, we use all of this method EXCEPT:**
 A. Digital x-ray.
 B. High sensitive film.
 C. Paralleling tech (Long cone) 16 inch.
 D. Bisecting algle (short cone) 8 inch. ***
 E. Lead apron with thyroid collar.
- The 8 inch technique exposes more tissue by producing divergent beam. The intensity of the radiation is inversely proportional to the square of the distance.
37. **When take x-ray we should stand:**
 A. 6 feet away in 90-135 angle.
38. **In a study, it should ??**
 A. Protect you against role of the statistician
 B. Protect you against legal risks. ***
 C. Protect against physical risks.
39. **Examination of Pt health by the dentist:**
 A. To know the patients health.
 B. To know what medications to give.
 C. To know general health data.
 D. All of the above. ***
40. **Progression of initial caries to cavitations takes 18 month this based on:**
 A. Streptomutans initiate caries. ***
 B. Lactobacillia progress caries.

41. **To kill HIV use all of the following EXCEPT:**

- A. Naocl.
- B. Ultraviolet chamber. ***
- C. Autoclave.
- D. Chimoclave.

42. **Patient could suffer from Hyperventilation in the dental office mainly due to :**

- A. Anxiety ***
- B. Low level of CO₂.
- C. High level of CO₂.

43. **In clinical research:**

- A. Blind or double blind.
- B. Needs control.
- C. Includes intervention. ***
- D. Offers no benefits to subject at risk.

44. **Least effective to kill aids is:**

- A. Ultra violet. ***
- B. Naocl is very effective.

Also cetrимide and dry heat at 100 degree are infective in kill aids.

45. **Sharp pain is due to which type of fibers?**

- A. A fibers. ***
- B. B fibers.
- C. C fibers.

A-Delta fibers – small, myelinated fibers that transmit sharp pain. **C-Fibers** – small unmyelinated nerve fibers that transmit dull or aching pain.

46. **Flouride amount in water should be:**

- A. 0.2-0.5 mg/liter.
- B. 1-5 mg/liter.
- C. 1-2 mg/liter. ***
- D. 0.2 mg/liter.

47. **The powered toothbrush invented in:**

- A. 1929.
- B. 1939. ***
- C. 1959.
- D. 1969.

48. **10 yr's old child, who is an able to differentiate the colors, and cant tell his name, or address He is acting like:**

- A. 3 years old. ***
- B. 4 years old.
- C. 10 years old.

49. **Streptococcus activity detected by:**

- A. Fermentation.
- B. Catalase.***
- C.X.
- D.X.

Catalase test: This test is used to differentiate those bacteria that produce the enzyme catalase as **staphylococci** from non-catalase producing bacteria such as **streptococci**.

50. **Stococcusmutans cause caries & this disease is?**

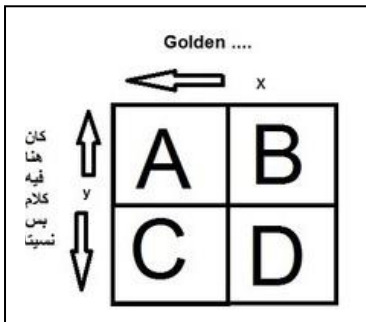
- A. Epidemic.
- B. Endemic. ***
- C. Isolated.

Endemic disease: An infectious disease that is present in the community at all times but normally at low frequency.

Endemic: a disease that exists permanently in a particular region or population. Malaria is a constant worry in parts of Africa .

Epidemic: An outbreak of disease that attacks many people's at about the same time and may spread through one or several communities .

Pandemic: When an epidemic spreads throughout the world.



51. **The rows show “truth”, the column show “test result” of:**

- A. Cell A has true positive sample. ***
- B. Cell A has true negative sample.
- C. Cell A has false positive sample.
- D. Cell A has false negative sample.

52. **Patient un-cooperation can result in fault of operation, Technical faults ONLY are related to patient factor:**

- A. TRUE.
- B. FALSE. ***

53. **Sterilization mean killing:**

- A. Bacteria and virus.
- B. Bacteria, virus, fungus and protozoa. ***
- C. Bacteria and fungus.

54. **Killing Bacteria is:**

- A. Bacteriostatic.
- B. Bactericidal. ***

55. **In prevention of dental caries, the promotion of a healthy diet is:**

- A. Low effective measure.
- B. Moderately effective measure. ***
- C. High effective measure.
- D. Mandatory measure.

56. Most used sugar substitute:

- A. Sorbitol.
- B. Mannitol.
- C. Insulin.
- D. Xylitol ***

Xylitol is a "tooth-friendly," nonfermentable sugar alcohol. A systematic review study on the efficacy of xylitol has indicated dental health benefits in caries prevention, showing superior performance to other polyols (polyalcohols). **Xylitol** is specific in its inhibition of the mutans streptococci group, bacteria that are significant contributors to tooth decay.

57. After usage of sharp scalpels, needles, what's the best management:

- A. Throw in a special container of sharp instrument. ***
- B. Sterilize and re use.
- C. Through in ordinary plastic waste basket.

58. What is the uses of microscope:

- A. To see metabolic.
- B. To see live cells. ***
- C. To see dead cells.

59. Twins came to your clinic during routine examination ,you found great change behavior between both of them this due to:

- A. Hereditary.
- B. Environment. ***
- C. Maturation.

Human twins are of two basic types: monozygotic (or identical) twins resulting from a single ovum fertilized by a single sperm, and dizygotic (or fraternal) twins resulting from fertilization of two ova by two sperm. It also follows that difference between monozygotic twins result from environmental differences whereas those between dizygotic twins result from differences in both heredity and environment.

60. For discharged sharp instrument (blades, needle tips, wedges ..etc) put in :

- A. Discharged paper basket.
- B. Designed sharp instrument special container. ***
- C. Disinfectant in auto glove then throw.
- D. Put it in multifoil.

61. What medical condition should prevent the dentist from practicing dentistry :

- A. Diabetes
- B. Hypertension
- C. Influenza. ***
- D. Headache.

62. At the begining of the Operation day in the clinic, you should start the water/air spray for Three minutes in order to get rid of which type of microorganisms :

- A. Streptococcus mutans.
- B. Streptococcus salivaris. ***

Dental high-speed turbines and handpieces can take up and expel microorganisms during operation and thus need regular sterilization. This study established a method for validating devices used to sterilize high-speed turbines and handpieces. The air and water channels and turbine chambers were contaminated with suspensions of Streptococcus salivarius or endospores of Bacillus stearothermophilus. The effect of flushing and/or autoclaving performed by a new device combining both procedures was evaluated by counting the number of viable bacteria recovered from these devices. Further, the effect on clinically used handpieces was evaluated. In an initial experiment, the device partially reduced S. salivarius, and the endospores survived. In a second experiment.

63. **The maximum dose of X-ray exposure dose for radiographic technique:**

- A. 100 milli roentgens per week. ***
- B. 10 roentgens per week.
- C. 100 roentgens per week.
- D. 300 roentgens per week.

Person who works near radiation can be exposed in one year to a maximum dose of 5 Rem (0.1 Rem per week)

64. **Food low cariogenic affect the following should be characteristic:**

- A. Low buffering capacity.
- B. Ph low than 3.
- C. Contain mineral. ***

65. **Salivary gland role in maintaining tooth and bacteria integrity on the oral cavity is done by:**

- A. Bacterial clearance.
- B. Remineralization.
- C. Buffering and direct anti-bacterial role.
- D. Bacterial clearance and remineralization.***

66. **Rideal-Walker test is the test for detecting activity of**

- A. Disinfection. ***
- B. Antibiotics.
- C. Sterilization by dry heat.
- D. Sterilization by wet heat.

67. **The use of fluoride toothpaste when less than child less than 3 years:**

- A. Recommended. ***
- B. Unlimited.
- C. There toxicity.

68. **When teeth begin in the form of uterine life**

- A. Between Weeks, fifth and sixth ***

69. **In a clinical research trial we primarily need to:**

- A. Get written subject in the patient's own native language. ***
- B. Verbally write subject briefly.
- C. Tell patients that they are part of study.

70. **Sterilization means killing of:**

- A. Virus.
- B. Fungi.
- C. Bacteria.
- D. Virus, fungi, bacteria, bacteria spores. ***
- E. Virus, fungi, bacteria.

71. **Tooth paste with fluoride is :**
A. Systemic application.
B. Topical application. ***
C. A + B.
D. None.
72. **Fluoride in water its concentrate:**
A. 2 PPM.
B. 1 PPM.
C. 3 PPM.
D. None.
73. **Too much ingestion of fluoride may lead to:**
A. Dental caries.
B. Dental fluorosis. ***
C. Gingivitis.
D. None.
74. **Medicine ethics aim to**
A. The dentist should be studied to know patient psycho.
B. Not to compromise or undermine ability to treat patient in community as professional.
C. ability to make decision.
D. All of above. ***
75. **Selection of steam heat over dry hot oven:**
A. Protein cell collagen under high pressure. ***
B. Save effect on shard instruments . no dull or corrosion.
76. **For the right handed dentist seated to the right of the patient the operator zone is between:**
A. 8 and 11 o'clock. ***
B. 2 and 4 o'clock.
C. 11 to 2 o'clock.
D. All of the above.
77. **For right handed dentist, the static zone is between :**
A. 8 - 11 o'clock.
B. 11 - 2 o'clock. ***
C. 2 - 4 o'clock.
D. all of the above.
78. **For right handed dentist, the assistant's zone is between:**
A. 8 - 11 o'clock.
B. 11 - 2 o'clock.
C. 2 - 4 o'clock. ***
D. all of the above.

79. **Sterilization in dry oven:**
A. One hour at 160 c.
B. 90 minutes at 160 c.
C. Two hours at 160 c. ***
D. None.
80. **Carbohydrate is digested in:**
A. Mouth. ***
B. Small intestine.
C. Large intestine.
D. None.
81. **Carbohydrate is essential for:**
A. Building the body.
B. Supplying the body with energy. ***
C. A + B.
D. None.
82. **The following factors effect the health:**
1. Hereditary.
2. Environement.
3. Social and economic factors.
4. Family welfare.
A. 1 + 2.
B. 1 + 2 + 4.
C. 1 + 2 + 3.
D. All of the above. ***
83. **How many mg of fluoride ions are obtained from 2.2 mg tablet of NaF:**
A. 0.5mg.
B. 1 mg. ***
C. 1.5mg.
D. 10mg.
84. **The first forming microbial elements of plaque are:**
A. Aerobic gram positive G+. ***
B. Aerobic gram negative GC.
C. Anaerobic gram negative GD.
D. Spirochetes.
E. Anaerobic gram positive G+.
85. **Extracellular polysaccharides in plaque are formed by:**
A. Bacteria from sucrose. ***
B. Precipitated from carbohydrate.
C. Precipitated from glycoprotein's.

Radiology 35 MCQs

1. The x-ray of choice to detect the proximal caries of the anterior teeth is:

- A. Periapical x-ray. ***
- B. Bitewing x-ray.
- C. Occlusal x-ray.
- D. None of the above.

2. Bitewing exam is used to diagnose EXCEPT:

- A. Proximal caries.
- B. Secondary caries.
- C. Gingival status.
- D. Periapical abscess. ***

3. Radiotherapy increase caries by decreasing salivary secretion:

- A. True. ***
- B. False.

4. To detect interproximal caries in primary teeth, the best film is:

- A. Periapical.
- B. Bitewing. ***
- C. Occlusal.

5. When using the buccal object rule in horizontal angulation, the lingual object in relation to the buccal object:

- A. Move away from the x-ray tube head.
- B. Move with the x-ray tube head. ***
- C. Move in an inferior direction from the x-ray tube head.
- D. Move in a superior direction from the x-ray tube head.
- E. None of the above.

If the object appears to move in the same direction as the x-ray tube, it is in the lingual aspect.

6. When take x ray in upper premolar to locate lingual root using mesial shift it will appear:

- A. Distal.
- B. Buccal.
- C. Lingual.
- D. Mesial. ***

7. While taking X-ray for upper right first premolar with two equal roots Using mesial slob, its lingual root will move [Comparing to the Zygomatic Process]:

- A. Distal.
- B. Mesial. ***
- C. Palatal.
- D. Lingual.

8. Radiographic examination in impacted teeth is useful to demonstrate:

- A. Proximity of the roots to the adjacent anatomical structures.
- B. Associated pathology.
- C. All of the above. ***

The criteria for imaging impacted teeth include identifying the impactions within the confines of the surrounding alveolar bone, then to determine their location relative to adjacent teeth and vital structures in the dento-alveolar complex and then finally to evaluate whether there is pathology.

9. A U- shaped radio-opaque structure in the upper 1st molar x-ray is:

- A. The Zygomatic process. ***
- B. Maxillary sinus wall.

10. When take an x-ray to pregnant lady, we use all of this method EXCEPT:

- A. Digital x-ray.
- B. High sensitive film.
- C. Paralleling tech (Long cone) 16 inch.
- D. Bisecting alge (short cone) 8 inch. ***
- E. Lead apron with thyroid collar.

The 8 inch=20 cm short cone technique exposes more tissue by producing divergent beam. The 16 inch=41 cm long cone technique reduce amount of exposed tissue by producing less divergent beam a sharper image. The intensity of the radiation is inversely proportional to the square of the distance.

11. When take x-ray we should stand:

- A. 6 feet away in 90-135 angle. ***

12. Disadvantage of digital x-ray EXCEPT:

- A. Large disk space Storage.
- B. Clarity and resolution. ***
- C. Expensive.

13. Radiographic evaluation in extraction EXCEPT:

- A. Relationship of associated vital structures.
- B. Root configuration and surrounding bone condition.
- C. Access to the tooth, crown condition and tooth mobility. ***
- D. All of the above.
- E. A & B.

14. Pt presented with vehicle accident u suspect presence of bilateral condylar fracture what is the best view to diagnose condylar Fracture:

- A. Occiptomenatal.
- B. Reverse town. ***
- C. Lat oblique 30 degree.

Reverse town for fracture of condylar neck & ramus areas. Reverse Townes position, beam 30° up to horizontal. Used for condyles.

15. The radiograph shows condylar head orientation and facial symmetry:

- A. Submentovertex.
- B. Reverse town. ***
- C. OPG.
- D. Transorbital.

16. To check TMJ range of movement:

- A. Cranial imagery.
- B. Arthrography. ***
- C. Traditional tomography.
- D. Computerized tomography.

17. To check a perforation in the disk of the TMJ we need:

- A. Cranial imagery..
- B. Arthrography. *** (CT after injection of a high contrast fluid)
- C. Traditional tomography.
- D. Computerized tomography.

18. The imaging showing disk position and morphology and TMJ bone:

- A. MRI. ***
- B. CT.
- C. Arthrography.
- D. Plain radiograph.
- E. Plain tomography.

MRI is better at imaging the soft tissue of the disk, but CT is better for almost all other investigations of the TMJ.

19. What kinds of radiographs which we do not use for TMJ movements?

- A. Transcranial. ***
- B. Computerized T.
- C. Conventional T.
- D. Arthrography.

20. Child with traumatized lip, no tooth mobility, what will you do first:

- A. Radiograph to check if there is foreign body. ***
- B. Refer to the physician for sensitivity test.

21. Patient came to your clinic complaining of pain, upon examination you can't find a clue. What's the next logical step to do in investigation:

- A. Panoramic x-ray. ***
- B. CT Scan.
- C. MRI.
- D. Regular tomography.

22. The maximum dose of X-ray exposure dose for radiographic technique:

- A. 100 Milli roentgens per week. ***
- B. 10 roentgens per week.
- C. 100 roentgens per week.
- D. 300 roentgens per week.

Person who works near radiation can be exposed in one year to a maximum dose of 5 Rem (0.1 Rem per week)

الجرعة المسموح بالتعرض لها سنوياً هي ٥ رونتجن ، أي الجرعة الأسبوعية = ٥ رونتجن ÷ ٥٢ أسبوع = حوالي ١٠٠ ميلي رونتجن بالأسبوع.

23. **The maximum dose of X-ray exposure dose for radiographic technique:**
A. 100 mini roentgens per week. ***
B. 10 roentgens per week.
C. 100 roentgens per week.
D. 300 roentgens per week.
24. **Patient complaining from pain in the floor of the mouth (beneath the lower jaw) your diagnosis is related to the salivary glands, what's the best x-ray to help you:**
A. Panoramic.
B. Occlusal.
C. Sialograph. *** (Specialized radiograph for the Salivary gland disorders)

Because the salivary glands consist of soft tissue, they cannot be seen on radiographs unless special steps are taken to make them visible. In a technique called Sialography.

25. **What is the first sign of fracture for face in x-ray ?**
A. Overlap of bone.
B. Fluid in Maxillary Since. ***
C. Suture.
D. All of the above.
26. **Digital radiography is a technique that shows transition from white to black. Its main advantage is the ability to manipulate the image by computer:**
A. 1st T, 2nd F. ***
B. 1st F, 2nd T.
C. Both T.
D. Both F.

Digital imaging: This technique has been used extensively in general radiology, where it has great advantages over conventional methods in that there is a marked dose reduction and less concentrated contrast media may be used. The normal X-ray source is used but the receptor is a charged coupled device linked to a computer or a photo-stimulable phosphor plate which is scanned by a laser. The image is practically instantaneous and eliminates.

27. **X-ray periapical for immature tooth is:**
A. Generally conclusive.
B. Simply inconclusive. ***
C. Should be compared with antermere.
28. **Gap between the apex of root and alveolar bone:**
A. Definite line of fracture. ***
B. No appear in x-ray.

Pt have trauma in upper central incisor the tooth and the alveolar bone is move as one PIC examination intraoral.

29. Which one of the conditions would delay a dentist's decision of taking full mouth X-ray examination ??
- A. Pregnancy. ***
 - B. Patient had full mouth examination by X-ray 6 months ago.
 - C. Patient will receive radiotherapy next week.
 - D. Patient had CT examination last week.
30. Pt have trauma in upper central incisor the tooth and the alveolar bone is move as one PIC examination intraoral.. ?
- A. Gap between the apex of root and alveolar bone.
 - B. Definite line of fracture. ***
 - C. No appear in x-ray.
31. Soft x-rays :
- A. Cause more damage than hard x-rays when they interact with tissues.
 - B. Are completely absorbed by the correct Aluminum filtration in the x-ray set.
 - C. Do not contribute to the radiographic image. ***
 - D. Will cause skin burns with dental exposures over 5 seconds.
32. Modern intra-oral x-ray sets can allow control over:
- A. Exposure time.
 - B. Kilovoltage.
 - C. Anode Current (mA)
 - D. All the above. ***
33. For a panoramic set, the dose can be reduced by:
- A. Speeding up the movement of the film cassette.
 - B. Slowing down the movement of the film cassette.
 - C. Reducing the kilovoltage of the set. ***
 - D. Reducing the slit width of the x-ray beam.
34. The photo-sensitive layer in film is made of:
- A. Silver Halides. ***
 - B. Potassium Permanganate.
 - C. Sodium Thiosulphate.
 - D. All the above.
35. Extra-oral films should be removed from cassettes immediately because:
- A. They may become fogged if left.
 - B. The surface emulsion may react with the intensifying screens. ***
 - C. There is a risk of putting another film in without removing the previous one.
 - D. The intensifying screen may be developed by mistake.

Surgery 240 MCQs

1. The following medical conditions may precipitate a syncope:

- A. Hypoglycemia. ***
- B. Mild hyperglycemia.
- C. Anti hypertensive drugs with ganglionic blocking agent.
- D. Anti depressant therapy.
- E. All of the above.

A faint may mimic far more serious conditions, most of which can be excluded by a familiarity with the patient's PMH. These include strokes, corticosteroid insufficiency, drug reactions and interactions, epileptic fit, heart block, hypoglycaemia, and MI.

2. What's the first sign of Syncope:

- A. Paleness. ***
- B. Nose bleeding (Epistaxis)
- C. Miosis.

3. Most frequent cause of fainting in dental office:

- A. Vaso-Vagal shock. ***
- B. Diabetes.
- C. Fear.

4. Loss of consciousness most frequent cause:

- A. Syncope. ***
- B. CO2 ...

The most common cause of loss of consciousness in the dental office is "SYNCOPE"

5. Pt on treatment with steroids are placed on antibiotic after oral surgical procedure because:

- A. The Pt is more susceptible to infection. ***
- B. Antibiotics are synergistic to steroids.
- C. Antibiotic inhibits kerkheimer reaction.
- D. Antibiotic protect the Pt from steroid depletion.

6. The post operative complication after the removal of impacted third molar is:

- A. Secondary hemorrhage.
- B. Swelling.
- C. Pain.
- D. Alveolar osteitis.
- E. All of the above. ***

7. Step deformity of the Mandibular body fracture may due to:

- A. Forward pull of lateral pterygoid muscle.
- B. Upward pull of masseter and temporalis. ***
- C. Toward pull of medial pterygoid muscle.
- D. Downward pull of geniohyoid and mylohyoid.

8. Inorganic material in bone compromise:

- A. 65%. ***
- B. 25%.
- C. 10%.
- D. 95%.

9. Which is most common:

- A. Cleft lip.
- B. Cleft palate.
- C. Bifid tongue.
- D. Cleft lip and palate. ***

(Most Common & Most Complicated)

Clefts of the upper lip and palate are the most common major congenital craniofacial abnormality. Cleft lip and palate are more common together than is cleft lip alone.

10. Which cranial nerve that petrous part of temporal bone houses:

- A. Trigeminal n V.
- B. Facial n VII. ***
- C. Vagus n IX.
- D. Vestibulocochlear n VIII.

11. Hypercementosis:

- A. Occur in Paget disease.
- B. Difficult to extract.
- C. Bulbous root.
- D. Easy to extract by elevator.
- E. A and b.
- F. A and d.
- G. A + B + C ***
- H. All the above.

Hypercementosis increases the difficulty of tooth removal.

If **hypercementosis** is present, the periodontal ligament space is visible around the added cementum; that is, the cementum is contained within and is surrounded by the periodontal ligament space. Condensing osteitis, by contrast, is situated outside the periodontal ligament space.

12. Lateral pterygoid muscle has how many origin:

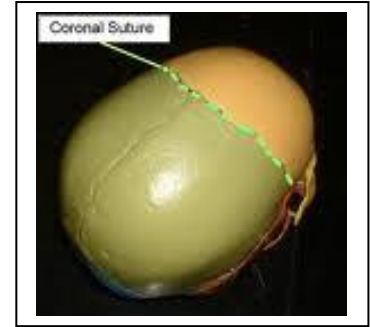
- A. 1.
- B. 2. ***
- C. 5.
- D. 7.

13. Embryo become fetus in:

- A. 1st week
- B. 1st month.
- C. 2nd month.
- D. 3rd month. ***

14. All are single bone in the skull EXCEPT:

- A. Lacrimal. ***
- B. Occipital.
- C. Sphenoid.
- D. Parietal.



15. Coronal suture is between:

- A. Occipital and temporal bone.
- B. Frontal and parietal bone. ***
- C. Occipital and tympanic bone.

16. What is the number of pharyngeal "Branchial" arches:

- A. 4.
- B. 5.
- C. 6. ***

17. What is the name of first pharyngeal "branchial" arches:

- A. Maxillary.
- B. Mandibular. ***

18. Stomodeum and fagi separated by:

- A. Frangeal arch. ***
- B. Ectodermal cleft.

The stomodeum is lined by **ectoderm**, and is separated from the anterior end of the **fore-gut** by the buccopharyngeal membrane.

19. The antibiotic of choice in pregnant:

- A. Metronidazole.
- B. Penicillin. ***
- C. Tetracycline.

20. Suture commonly used in oral cavity:

- A. Black silk. ***
- B. Catgut.
- C. Chromic.

21. Tooth fracture during extraction may be occur due to:

- A. None vital tooth.
- B. Diabetic Pt.
- C. Improper holding by forceps.
- D. A and C. ***

22. Many parts of bones are originally cartilaginous that replaced by bone:

- A. True. ***
- B. False.

23. Pt came with fracture because of blow in the right side of his face. he has ecchymosis around the orbit in the right side only .and subjunctional bleeding in the maxillary buccal vestibule .with limited mouth open what is ur diagnosis?

- A. Le fort 1.
- B. Lofort 2.
- C. Lefort 3.
- D. Zygomatic fracture. ***

Zygoma fracture:

Clinical flattening of the cheekbone prominence — paraesthesia in distribution area of infraorbital nerve — diplopia, restricted eye movements - subconjunctival haemorrhage - limited lateral excursions of mandibular movements - palpable step in infraorbital bony margin.

24. Moon face appearance is not present in:

- A. Le fort I.
- B. Le fort II.
- C. Le fort III.
- D. Zygomatic complex. ***
- E. Le fort II and Le fort III.

25. Open bite is seen in:

- A. Le fort II.
- B. Unilateral Condylar fracture.
- C. Bilateral Condylar fracture. ***

26. What is the first sign if there is fracture in the face in x-ray?

- A. Fluid paranasal. ***
- B. Suture.
- C. Overlap of bone.
- D. All the above.

The eyes are examined for double vision (Diplopia), any restriction of movement and subconjunctival haemorrhage. The condyles of the mandible are palpated and movements of the mandible checked. Swelling, bruising and lacerations are noted together with any areas of altered sensation that may have resulted because of damage to branches of the trigeminal nerve. Any evidence of cerebrospinal fluid leaking from the nose or ears is noted, as this is an important feature of a fracture of the base of the skull. An intra-oral examination is then carried out, looking particularly for alterations to the occlusion, a step in the occlusion, fractured or displaced teeth, lacerations and bruises. The stability of the maxilla is checked by bimanual palpation, one hand attempting to mobilise the maxilla by grasping it from an intra-oral approach, and the other noting any movement at extra-oral sites such as nasal, zygomatic-frontal and infraorbital.

27. Complete blood count "CBC" is a laboratory test important in dentistry:

- A. True. ***
- B. False.

28. Bleeding of the socket following tooth extraction:

- 1. Is always a capillary bleeding in nature.
- 2. Takes not less than half – day in normal individual.
- 3. Is always favorable if it is primary type.
- 4. Can be due to the presence of a nutrient vessel.
 - A. 1 and 2 are correct.
 - B. 1, 2 and 3 are correct.
 - C. 1, 3 and 4 are correct. ***
 - D. All are correct.

29. In sickle cell anemia, O₂ is decreased in oral mucosa:

- A. True. ***
- B. False.

30. Destruction of RBC may cause anemia and it is due to defect in cell membrane:

A. True. ***

B. False.

31. Immunofluorescent test and biopsy are used to diagnosis pemphigus:

A. True. ***

B. False.

32. Management of tuberosity fracture during extraction of maxillary molar is:

A. Replace and suture. ***

B. Remove and suture with primary heal.

C. Replace and suture intra alveolar by wire.

D. Remove and leave to heal.

If the tuberosity is fractured but intact , it should be manually repositioned and stabilized by sutures.

33. During maxillary 3rd molar extraction the tuberosity fractured. It was firmly attached to the tooth and cannot be separated. What is the management:

A. Remove it with the tooth. ***

B. Splint the tooth to the 2nd molar then re-extracted after 6 weeks.

C. Suturex

34. After extraction a molar you found a hard tissue at the furcation like pearl .it is:

A. Enamel pearl. ***

B. Enostosis.

C. Hypercementosis.

35. Tooth # 36 planned to extraction on x-ray no PDL after extraction u found lesion like pearl on furcation wt the lesion:

A. Enamel pearl. ***

B. Enostosis.

C. Hypercementosis.

36. Microbial virulent produced by root bacteria is collagens from spirochete:

A. True. ***

B. False.

37. Oral diaphragm consist mainly of:

A. Tongue.

B. Geniohyoid muscle.

C. Digastric muscle.

D. Mylohyoid muscle. ***

38. Masseter muscle extends from lower of border Zygomatic arch to lateral border of ramus and angel mandible:

A. True. ***

B. False.

- 39. Extend of temporalis behind infratemporal fossa of temporal bone insert in coronoid process:**
A. True. ***
B. False.
- 40. Main arterial supply in face is facial artery and superficial temporal artery:**
A. True. ***
B. False.
- 41. Mandible is the 1st bone calcified in skull but clavicle start first but in same embryological time:**
A. True. ***
B. False.
- 42. Mandible formed before frontal bone:**
A. True.
B. False. ***
- 43. Maxilla is formed**
A. Before mandible.
B. Same with mandible.
C. Slightly after mandible. ***
D. None of the above.
- 44. Development of maxillary process and medial frontal process in medial elongation of central portion:**
A. True.
B. False. ***
- 45. Some bone are formed by endochondral ossification like long bone, flat bone by intramembranous ossification and some bone by endochondral and intramembranous ossification:**
A. True. ***
B. False.
- 46. Facial nerve supply:**
A. Masseter muscle.
B. Temporal muscle.
C. Buccinator muscle. ***
D. Mylohyoid muscle.
- 47. Upon giving a lower mandible anesthesia , you notice the patient's eye, cheek corner of the lip are uncontrolled , what's the reason :**
A. Paresthesia of the Facial Nerve. ***

48. Muscle of facial expression are all innervated by facial nerve:

- A. True. ***
- B. False.

49. While performing cranial nerve examination you notice that the patient is unable to raise his eyebrows , hold eyelids closed , symmetrically smile or evert his lower lip .. this may indicate:

- A. Trigeminal nerve problem.
- B. Facial nerve problem. ***
- C. Oculomotor nerve problem.
- D. Trochlear nerve problem.
- E. All of the above.

50. The primary direction for spread of infection in the mandible is to Submental lymph node:

- A. True.
- B. False. ***

51. Paraesthesia of lower lip after surgical removal of lower 8 is due to the irritation of inferior alveolar nerve:

- A. True. ***
- B. False.

52. Mastoid process is a part of:

- A. Temporal bone. ***
- B. Parietal bone.
- C. Occipital bone.

53. Parotid duct opens opposite in 2nd Mandibular molars:

- A. True.
- B. False. ***

54. Palate consists of:

- A. Palatine and sphenoid bone.
- B. Palatine and maxillary bone. ***
- C. Palatine and zygomatic bone.

55. Hard palate consists of the following:

- A. Palatal maxillary process & Ethmoid bone.
- B. Palatal maxillary process & Sphenoid bone.
- C. Palatal maxillary process & Palatine bone. ***
- D. Palatal maxillary process & Temporal bone.

56. Nerve impulse stops when injection local anesthesia:

- A. True. ***
- B. False.

57. The 1st cervical vertebrae is:

- A. Atlas. ***
- B. Axis.

Atlas. C1.
Axis or Epistropheus. C2.
Cervical vertebra. C3 – C7.

58. Cartilaginous joints in the body affect bone growth:

- A. True. ***
- B. False.

59. The nerve which supply the tongue and may be anesthetized during nerve block injection:

- A. V. ***
- B. VII
- C. IX.
- D. XII.

60. The amount of L.A in 2% lidocaine with 1/100000 adrenaline is:

- A. 0.01
- B. 0.02
- C. 36 mg. ***

61. How many mg of adrenalin in cartridge 1.8 cc of 2 % Xylocine:

- A. 1.8 mg.
- B. 0.18 mg.
- C. .036 mg.
- D. 3.6 mg.
- E. 0.018 mg. ***

62. What is the amount in mg in 1.8 ml of Xylocain:

- A. 20 mg/ml.
- B. 1.8 mg/ml.
- C. 36 mg. ***

إذا كان تركيز الليدوكائين ٢%. تكون كميته ٣٦ ملغ لأن حجم الأمبولة ١,٨ سم. مكعب
إذا كان تركيز الأدرينالين جزء من ١٠٠٠٠٠ تكون كميته ٠,٠١٨ مل.

63. The most common complication after extraction for diabetic Pt is:

- A. Infection. ***
- B. Severe bleeding.
- C. Oedema.
- D. All of the above.

64. Transverse fracture of developing teeth in the mixed dentition can be managed by:

- a. Forced eruption. ***
- b. Extraction and placement of a removable partial denture.
- c. Placement of single tooth.
- d. All of the above.

Root Fractures:

The non communicating fracture occurs in the apical or middle third of the root. Perform a vitality test , check for color change in the crown , and record the degree of mobility of each traumatized tooth. If the pulp is vital , then immobilize the tooth by splinting it to the adjacent teeth. If the fracture of any part of the root is coronal to the periodontal attachment. The fractured part should be removed during the emergency visit , and endodontic treatment should be done in one visit. Once the emergency has been taken care of, plans must be made for restoring the tooth.

65. Adult 20 years male with soft tissue & dental trauma reveals severe pain in soft tissues with loss of epithelial layers and anterior upper centrals are intruded the diagnosis is:

- A. Abrasion with luxation.
- B. Erosion with sub luxation.
- C. Traumatic ulceration with luxation. *****
- D. Ulceration with subluxation.

66. Adult 20 years male with soft tissue & dental trauma reveals severe pain in soft tissues with loss of epithelial layers and anterior upper centrals are intruded the diagnosis is:

- A. Abrasion with luxation.
- B. Erosion with sub luxation.
- C. Laceration with luxation. *****
- D. Laceration with subluxation.

67. The most common cause of the angina is:

- A. Stress.
- B. Renal disease.
- C. Arteriosclerotic plaques of the coronary vessels. *****
- D. Hypoglycemia.
- E. Hypertension.

68. Which of the following drugs is completely effective in eliminating angina episode:

- A. Propranolol.
- B. Nifedipine.
- C. Diltiazem.
- D. Transdermal nitroglycerin. *****
- E. None of the above.

69. CPR :

- A. Is best performed in the dental chair.
- B. Should be performed on all patients experiencing chest pain.
- C. Is more efficient when using a full mask, delivering 100% oxygen, than with the mouth to mouth technique. *****
- D. Is beyond the medico legal responsibility of the practicing dentist.

70. Reduction of mandibular fracture is defined as:

- A. Nonalignment and separation of the fracture segment.
- B. Realignment of fracture segments.
- C. Holding of the fracture segments in place. ***
- D. Screw and bone plates.
- E. Internal fixation.

71. Wiring the upper and lower teeth together is called:

- A. Internal fixation.
- B. An open reduction.
- C. Intermaxillary fixation. ***
- D. Displacement.
- E. External fixation.

72. The incidence of nerve damage after third molar surgery is estimated to be:

- A. 5% or less. ***
- B. 10% to 15%.
- C. 15% to 20%
- D. 20% to 25%.

73. The least likely mechanism for the nerve damage is:

- A. Direct needle trauma.
- B. Intranural haematoma formation.
- C. Local anesthetic toxicity. ***
- D. Stretching and binding of the nerve.

74. The best transport medium for evulsed tooth is:

- A. Tap water.
- B. HBSS (Hank's balanced salt solution). ***
- C. Saliva.
- D. Milk.

75. High rate of fractures at canine area in the mandible due to:

- A. Change direction of forces accruing here.
- B. Long canine root ***
- C. Lower border is thin in this area.
- D. Alveolus is thin in this area.

The mental foramen, and the long roots of the canine teeth as well as impacted 3rd molars create points of weakness that are particularly prone to fracture.

76. Radiographic examination in impacted teeth is useful to demonstrate:

- A. Proximity of the roots to the adjacent anatomical structures.
- B. Associated pathology.
- C. All of the above. ***

The criteria for imaging impacted teeth include identifying the impactions within the confines of the surrounding alveolar bone, then to determine their location relative to adjacent teeth and vital structures in the dento-alveolar complex and then finally to evaluate whether there is pathology.

77. Epidemiology can be defined as:

- A. A study of special areas of the skin.
- B. The study of the distribution and determinant of disease in man. ***
- C. Study of biological animals.
- D. Study of disease in research laboratory.

78. Odontogenic infection can cause least complication:

- A. Pulmonary abscess.
- B. Peritonitis. *** (التهاب الصفاق)
- C. Prosthetic valve infection.
- D. Cavernous sinus thrombosis.

What are the significant complications of untreated Odontogenic infection? • Tooth loss. • Spread to the cavernous sinus and brain. • Spread to the neck with large vein complications. • Spread to potential fascial spaces with compromise of the airway. • Septic shock.

79. Cavernous sinus thrombosis not manifested as:

- A. Infra orbital syndrome.
- B. Syncope due to atrial obliteration. ***
- C. Eye exophthalmos.

Cavernous sinus thrombosis: may follow infection from the **pterygoid venous plexus**. Cavernous sinus thrombosis: Patients present with proptosis (**eye exophthalmos**), **orbital swelling**, neurologic signs, and fever.

80. After u inject L.A for 2nd max molar pt become colorless with external swelling its due to :

- A. Facial artery.
- B. Plexus vein. ***
- C. Posterior alveolar Nerve.

Hematoma: This is commonly produced by inserting the needle too far posteriorly into the pterygoid plexus of veins. Additionally, the maxillary artery may be perforated.

81. Pass throw parotid gland

- A. Facial nerve. ***
- B. Facial arteries.
- C. External carotid veins.
- D. The Zygomatic process.
- E. Maxillary sinus wall.

Structures that pass through the Parotid Gland. (Lateral to Medial): # Facial nerve. # Retromandibular vein. # External carotid artery. # Superficial temporal artery. # Branches of the great auricular nerve. # Maxillary Artery.

82. Loss of sensation in the anterior 2/3 of the tongue is related to paralysis of:

- A. Lingual nerve. ***
- B. Hypoglossal nerve.
- C. Chorda tympani nerve.

Anterior 2/3: Lingual N. for Sensation & Chorda tympani N. for the Taste.
Posterior 1/3: Both Taste & Sensation by Glossopharyngeal N.

83. The choice of local anesthesia depend on:

- A. Diameter of the nerve
- B. Structure of the bone
- C. Number of branches
- D. Type of L.A agent chemistry. ***

84. Choice of local anesthesia technique influenced by:

- A. Chemical composition of anesthesia.
- B. The location of the nerve.
- C. Bone structure. ***

The bone of the maxilla is more porous than that of the mandible, therefore it can be infiltrated anywhere.

85. Mandibular branch of trigeminal nerve leaves the skull through:

- A. Foramen rotundum.
- B. Foramen ovale. ***
- C. Superior orbital fissure.
- D. Inferior orbital fissure.
- E. Jugular foramen.

86. Foramen oval is in the following bone:

- A. Temporal.
- B. Occipital.
- C. Sphenoid. ***

87. The inferior alveolar nerve is branch of:

- A. Mandibular nerve – not divided. ***
- B. Posterior mandibular alveolar nerve.
- C. Anterior mandibular alveolar nerve.

88. The following structures open into the middle meatus:

- A. Nasolacrimal duct.
- B. Posterior ethmoidal sinus.
- C. Maxillary sinus.
- D. Sphenoid sinus.
- E. Anterior ethmoidal sinus.
- F. A, B & D.
- G. A & B.
- H. C & E. ***
- I. All of the above.

89. Ligaments associated with TMJ:

- A. Temporomandibular.
- B. Sphenomandibular.
- C. Stylomandibular.
- D. All of the above. ***

The **Lateral Temporomandibular** ligament: limits the movement of the mandible in a posterior direction. The **Sphenomandibular** ligament lies on the medial side of the joint. The **Stylomandibular** ligament lies behind and medial to the joint.

90. Location to give inferior alveolar nerve block the landmarks are:

- A. Pterygomandibular raphe.
- B. Coronoid notch.
- C. All of the above. ***

91. The optic foramen canal is a part of:

- A. Frontal bone.
- B. Sphenoid bone. ***
- C. Esthmoid bone.

92. Optic nerve coming from which bone:

- A. Sphenoid bone. ***
- B. Zygomatic.
- C. Palatal.

93. Factors delay healing of wound:

- A. Infection.
- B. Torn wound edges. (الحواف المتشققة)
- C. Strain. (الإجهاد)
- D. All of the above. ***

94. Factor interfere with healing:

- A. Poor suturing.
- B. Infection. ***

Healing occur more rapidly with a low risk of infection.

95. Dry socket happen after:

- A. 24 h.
- B. 3-5 days. ***
- C. 1 week.
- D. 2 weeks.

Treatment Choose: (Zinc Oxide and Eugenol impregnated cotton pellets, Alvogyl (Eugenol, Iodoform and Butamen), Dentalone, Bismuth Subnitrate and Iodoform paste (BIPP) on ribbon gauze and Metronidazole and Lidocaine Ointment.

96. Avulsion more important factor that affect Reimplantation:

- A. Contaminated roots.
- B. Time since the avulsion. ***

97. Most sign of fracture of mandible:

- A. Nose bleeding.
- B. Malocclusion. ***
- C. Parasthesia.

98. What supply the gingival buccal tissue of premolars, canines and incisors:

- A. Long buccal.
- B. Inferior alveolar nerve. ***
- C. Superior alveolar nerve.

99. Drainage of tip of the tongue:

- A. Submandibular lymph nodes.
- B. Submental. ***

Metastases from the tongue cancer.....the 1st nodes to become involved are the submandibular or jugulodigastric.

100. Most difficult of extract:

- A. Mand. 3rd molar with mesioangular fused roots
- B. Mand 3rd molar with distoangular angulation with divergent curve roots ***

101. Pt have hyperventilation in clinic. Most cause:

- A. Reduced of CO₂
- B. Increase CO₂
- C. Anxiety. ***

102. Contraindication to extraction:

- A. Cardiac pt.
- B. Previous recent radio therapy. ***

103. Base of the flap should be wide for:

- A. Healing
- B. Better blood supply to the wound. ***

"Flap design should ensure adequate blood supply; the base of the flap should be larger than the apex"

104. Principle of elevator use of all the following EXCEPT:

- A. Wheel and axle.
- B. Wedging the socket wall. ***
- C. Wedging.
- D. Lever.

Dental elevators work either on the principle of 'block and wedge' or 'wheel and axle', and should never be used as crow-bars. Hence, a dental luxator with its sharp edge is pushed between the root of a tooth and its alveolar bone via the periodontal space. This wedging effect should cause the root to be moved from its socket

Mechanical principles involved in extraction: (Lever & Wedge & Wheel and Axle)

1- Lever- Elevators are used primarily as levers. Transmit modest force- w/ mechanical adv. of long lever arm and short effectors arm- into same movement against greatest resistance. Use a purchase point and crane pick to elevate tooth from socket.

2- Wedge: Force tips of forceps into PDL space to expand bone and force the tooth out of the socket. Useful when a str8 elevator is used to luxate a tooth from its socket, some elevator forced into space, displaces the root toward the occlusal and out of the socket.

3- Wheel and Axle: Triangular or pennant shaped elevator. When one root is left, pennant elevator put into socket and turned. Handle is an axle, tip of triangular elevator is well and engages & elevates the root from the socket.

105. When do we do incision and drainage?

- A. Indurated diffuse swelling.
- B. Sinus tract.
- C. Chronic apical periodontitis. ***

106. Pregnant lady needs oral surgery:

- A. Needs prophylactic antibiotic.
- B. Needs under GA.
- C. Needs steroid cover.
- D. None of the above. ***

107. When do we give antibiotic:

- A. Widespread, rapid infection.
- B. Compromised host defence.
- C. A & B. ***

108. Muscle that form floor of the mouth:

- A. Mylohyoid. ***
- B. X

109. Root most commonly pushed in max sinus:

- A. Buccal of 7.
- B. Palatal of 6. ***
- C. Palatal of 7.
- D. Buccal of 6.
- E. Distal of 6 & 7.

The palatal root of the maxillary first molar is most often dislodged into the maxillary sinus during an extraction procedure.

110. If tooth or root is pushed during surgical extraction into maxillary sinus:

- A. Leave it and inform the patient.
- B. Remove it as soon as possible. ***
- C. Follow the patient for 3 months.
- D. None of the above.

111. Factors that make impaction surgery more difficult:

- A. Mesioangular position, large follicle, wide periodontal ligament and fused conical roots.
- B. Mesioangular position, large follicle, wide periodontal ligament and curved roots.
- C. Distoangular position, large follicle, wide periodontal ligament and fused conical root.
- D. Distoangular position, thin follicle, narrow periodontal ligament and divergent curved roots. ***
- E. Soft tissue impaction, separated from second molar and inferior alveolar nerve.

112. Which scalpel below is universally used for oral surgical procedures?

- A. Number 2 blade.
- B. Number 6 blade.
- C. Number 10 blade.
- D. Number 12 blade.
- E. Number 15 blade. ***

113. The radiograph shows Condylar head orientation and facial symmetry:

- A. Submentovertex.
- B. Reverse town. ***
- C. OPG.
- D. Transorbital.

114. The best way of radiograph shows displacement of mandibular conyle:

- A. Reverse town. ***
- B. Oplage horizontal 30.

115. What kinds of radiographs which we do not use for TMJ movements?

A. Transcranial. ***

B. Computerized Tx.

C. Conventional Tx.

D. Arthrography.

116. To check TMJ range of movement:

A. Cranial imagery.

B. Arthrography. ***

C. Traditional tomography.

D. Computerized tomography.

117. To check a perforation in the disk of the TMJ we need:

A. Cranial imagery.

B. Arthrography. *** (CT after injection of a high contrast fluid)

C. Traditional tomography.

D. Computerized tomography.

118. Buccal branch of trigeminal is:

A. Sensory. ***

B. Motor.

C. Psychomotor.

D. Sensory and motor.

119. Buccal branch of facial is:

A. Sensory.

B. Motor. ***

C. Mixed.

120. Lower anterior teeth labial mucosa supplied by:

A. Mental nerve. ***

B. Inferior dental nerve.

C. Buccal nerve.

121. Most difficult of extract:

A. Mand. 3rd molar with mesioangular fused roots.

B. Mand 3rd molar with distoangular angulation with divergent curve roots. ***

For impacted mandibular molars:

Order from the least difficult to most difficult to remove:

Mesioangular > Horizontal > Vertical > Distoangular (The opposite in MAXILLA)

Typically distoangular impactions are the easiest to extract in the maxilla and most difficult to extract in the mandible, while mesioangular impactions are the most difficult to extract in the maxilla and easiest to extract in the mandible.

122. Energy absorbed by the point of fracture called:

- A. Ultimate strength.
- B. Elastic limit.
- C. Toughness. ***
- D. Brittleness.

Toughness: It is defined as the amount of energy per volume that a material can absorb before rupturing. The ability of a metal to deform plastically and to absorb energy in the process before fracture is termed toughness.

123. Local contraindication of extraction:

- A. Pt recent receive radiotherapy.
- B. Tooth in the malignant Tumor.
- C. Both A and B ***

124. Most impacted tooth is:

- A. Mand. 8. ***
- B. Max. 2.

125. Most common tooth which needs surgical extraction:

- A. Mandibular third molar. ***

126. Pt have unilateral fracture of left the Condyle , the mandible will:

- A. Deviate to the left side. ***
- B. Deviate to the right side.
- C. No deviate.

The mandible will always deviate to the side of injury. A patient who sustained a subcondyle fracture on the left side would be unable to deviate the mandible to the right.

127. When removing lower second molar:

- A. Occlusal plane perpendicular To the floor.
- B. Buccolingual direction to dilate socket. ***
- C. Mesial then lingual.

128. All of these are ways to give L.A with less pain EXCEPT:

- A. Give it slowly.
- B. Stretch the muscle. ***
- C. Topical anesthesia.
- D. The needle size over than 25 gauge.

إذا زاد رقم الإبرة تكون أرفع وبالتالي أقل ألماً بالحقن.

129. One of the primary considerations in the treatment of fractures of the jaw is

- A. To obtain and maintain proper occlusion. ***
- B. Test teeth mobility.
- C. Vitality.
- D. Embedded foreign bodies.

130. A patient complaining from a severe edema in the lower jaw that increases in size upon eating, Diagnosis is:

- A. Salivary Gland. *** (Submandibular Salivary. Gl.)

131. A patient that wasn't anaesthetized well in his 1st visit, next day he returns with a limited mouth opening (trismus). He must be anaesthetized, what's the technique to be used:

- A. William's technique.
- B. Bercher's technique.***

132. A patient that wasn't anaesthetized well in his 1st visit, next day he returns with a limited mouth opening (truisms). He must be anaesthetized , what's the technique to be used:

- A. William's technique.
- B. Gow gates technique.
- C. Vazirani-akinosi technique. ***

Vazirani-Akinosi technique - a closed-mouth injection technique, the syringe is "advanced parallel to the maxillary occlusal plane at the level of the maxillary mucogingival junction.

133. Pt came to dental clinic having a hematological problem after lab test they found that factor VIII is less 10% what's the diagnosis:

- A. Heamophilia A. ***
- B. Hemophilia B.

(Defect factor 9 : Hemophilia B)

134. Child 3 years old came to clinic after falling on his chin, you found that the primary incisor entered the follicle of the permanent incisor what you will do:

- A. Surgical removal of the follicle
- B. Leave it
- C. Surgical removal of the primary incisor. ***

If the intruded incisor is contenting the permanent tooth bud, the primary tooth should be extracted.

135. Tongue developed from:

- A. Mandibular arch & tuberculin impar. ***
- B. 1st branchial arch.

- The mandibular arch lies between the first branchial groove and the stomodeum ; from it are developed the lower lip, the mandible, the muscles of mastication, and the anterior part of the tongue.
- The ventral ends of the second and third arches unite with those of the opposite side, and form a transverse band, from which the body of the hyoid bone and the posterior part of the tongue are developed.

During the third week there appears, immediately behind the ventral ends of the two halves of the mandibular arch, a rounded swelling named the tuberculum impar, which was described by His as undergoing enlargement to form the buccal part of the tongue. More recent researches, however, show that this part of the tongue is mainly, if not entirely, developed from a pair of lateral swellings which rise from the inner surface of the mandibular arch and meet in the middle line.

136. An adult had an accident, maxillary central incisors intruded, lip is painful with superficial wound what is the trauma's classification:

- A. Luxation. ***
- B. Subluxation.
- C. Laceration.
- D. Abrasion.
- E. Contusion.

Intrusive luxations, or intrusions, result from an axial force applied to the incisal edge of the tooth that results in the tooth being driven into the socket.

137. Cleft lip is resulted from incomplete union of:

- A. Tow maxillary arches.
- B. Maxillary arches and nasal arch.***

138. Arrange the steps of cleft palate management:

- A. Measures to adjust speech.
- B. Establish way for nursing and feeding.
- C. Cosmetic closure.
- D. Prevent collapse of two halves.
- E. B – D – A – C. ***
- F. A – D – B – C.

139. Time of PT, PTT:

- A. 11-15 seconds , 25-40 seconds. ***

PT= 12-14 sec. (زمن تخثر الدم)
PTT= 30-40sec. (زمن توقف الدم)
Bleeding time within < 8 min.

140. When extracting all max teeth the correct order is:

- A. 87654321.
- B. 87542163. ***
- C. 12345678.

141. For a patient that is on a corticosteroid therapy, upon oral surgery, the patient is given:

- A. 100 - 200 mg Hydrocortisone. ***
- B. 400 - 600 mg Prednisolone.

142. Patient under corticosteroid therapy , he will undergo surgical extraction of third molar . what will you give to avoid adrenal crisis :

- A. Dexamethasone (4 mg / I.V.).
- B. Methyl prednisolone (40 mg / I.V).
- C. Hydro cortisone sodium sulfide (40 – 50 mg.)
- D. Hydro cortisone sodium succinate (100 – 200 mg). ***

143. Patient with lupus erythematosus and under cortisone, he needs to surgical extraction of a tooth. What should the surgeon instruct the patient:

- A. Take half of the cortisone dose at the day of operation.
- B. Double the cortisone dose at the day of operation.***
- C. Take half of the cortisone dose day before and at the day of operation and day after.
- D. Double the cortisone dose day before and at the day of operation and day after.

Instruct patient to double dose of steroids the morning of surgery up to 200mg. If taking greater than 100mg, then give only an additional 100mg.

- If on alternate day steroids, do surgery on day steroids are taken.
- If patient has had 20 mg of steroid for more than two weeks in the past 2 weeks, but is not currently taking steroids, then give 40mg hydrocortisone prior to surgery. For multiple extractions or extensive mucogingival surgery, the dose of corticosteroids should be doubled on the day of surgery. If the patient is treated in the operating room under general anesthesia, stress level doses of cortisone, 100 mg intravenously or intramuscularly, should be given preoperatively.

144. The right corticosteroid daily dose for pemphigus vulgaris is:

- A. 1-2 g/kg/daily.
- B. 1-2 mg.
- C. 10 mg.
- D. 50- 100 mg hydrocortisone. ***

Very high dosages are used initially to suppress bulla formation (of the order of 1 mg/kg prednisolone daily), but this may often be slowly reduced to a maintenance dose of 15 mg daily or thereabouts.

145. The right corticosteroid daily dose for pemphigus vulgaris is:

- A. 1-2 g/kg/daily.
- B. 1-2 mg/kg/daily. ***
- C. 10 mg/kg/daily.
- D. 50- 100 mg/kg/daily hydrocortisone.

146. The following are indication of outpatient general anesthesia EXCEPT:

- A. ASA categories 1 & 2.
- B. The very young child.
- C. Cost increase. ***
- D. Patient admitted and discharge the same day.

147. A removable partial denture patient, Class II Kennedy classification. The last tooth on the left side is the 2nd premolar which has a distal caries. What's the type of the clasp you will use for this premolar:

- A. Gingivally approaching clasp. ***
- B. Ring clasp.

148. A 55 year old patient with multi-extraction teeth , after extraction what will you do first:

- A. Suturing.
- B. Primary closure should be obtained if there is no luntant tissue.
- C. Alveoplasty should be done in all cases. ***

149. Child with traumatized lip, no tooth mobility, what will you do first:

- A. Radiograph to check if there is foreign body. ***
- B. Refer to the physician for sensitivity test.

150. Patient complains from pain in TMJ. During examination you noticed that during opening of the mouth mandible is deviate the right side with left extruded. Diagnosis is:

- A. Condylar displacement with reduction.
- B. Condylar displacement without reduction. ***

151. Pt. Presented to u complain of click during open and close. There is no facial asymmetry EXCEPT when opening What is the diagnosis:

- A. Internal derangement with reduction. ***
- B. Internal derangement without reduction.
- C. Rheumatoid arthritis.

152. Unilateral fracture of left Condyle of the mandible will:

- A. Deviate to the left side. ***
- B. Deviate to the right side.

153. To drain submandibular abscess:

- A. Intraorally through the mylohyoid muscles.
- B. Extraorally under the chin.
- C. Extraorally at the most purulent site.
- D. Extraorally at the lower border of the mandible. ***

In case of abscess you incise in healthy tissue to be sure good blood flow to the incision line so good healing of incision line with no scar. If you incise in most purulent area which is not healthy tissue, the result is a scar in incision line.

154. Most used Scalpel in oral surgery:

- A. Bard Parker blade # 15.

155. Antibiotics are most used in cases of:

- A. Acute Localized lesion.
- B. Diffuse , Highly progressing lesion. ***

156. Bone graft material from site to another site in the same person:

- A. Allograft.
- B. Auto graft. ***
- C. Alloplast.
- D. Xenograft.

157. Ester type of local anesthesia secreted by:

- A. Liver only.
- B. Kidney.
- C. Lung.
- D. Plasma. *** (Therefore preferably used in pregnant women)

158. Where does the breakdown of Lidocaine occurs :

- A. kidneys
- B. Liver. ***

159. Avulsed tooth:

- A. Splint (7-14) day. ***
- B. Splint (3- 14) weeks

160. An 8 years old child, suffered a trauma at the TMJ region as enfant. Complaining now from limitation in movement of the mandible. Diagnosis is:

- A. Sub luxation.
- B. Ankylosis. ***

161. Generalized lymphadenopathy seen in:

- A. Infection.
- B. Lymphocytic leukemia.
- C. HIV.
- D. Pernicious anemia.
- E. A + B.
- F. A + B + C. ***
- G. Only D.
- H. B + D.

Causes of Generalized Lymphadenopathy:

Infection :

Viral : Infectious mononucleosis, Infective hepatitis, AIDS.

Bacterial : Tuberculosis, Brucellosis, 2ry syphilis.

Protozoal : Toxoplasmosis.

Fungal : Histoplasmosis.

Malignant : Leukaemia – Lymphoma - Metastatic carcinoma.

Immunological : Systemic lupus erythematosus - Felty's syndrome - Still's disease.

Drug hypersensitivity as Hydantoin, Hydralazine, Allopurinol.

Misc. : Sarcoidosis – Amyloidosis - Lipid storage disease – Hyperthyroidism.

162. Surgical interference with edentulous ridge for:

- A. Good retention, stability and continuous uniform alveolar ridge. ***

163. Non absorbable suture:

- A. Catgut.
- B. Vicryl.
- C. Silk. ***

164. The following is a non- absorbable suture:

- A. Plain catgut.
- B. Chromic catgut.
- C. Silk.***
- D. All the above.

165. Chronic pericoronitis:

- A. Difficult mouth opening.
- B. Halitosis.
- C. All of the above. ***

166. Safe months to treat pregnant ladies:

- A. 1 - 3.
- B. 4 - 6. ***
- C. 7 - 9.

167. Most common site which drain pus is:

- A. Mandibular central incisors.
- B. Mandibular canines.
- C. Mandibular first molar. ***

168. Mandibular fracture other complications:

- A. Nasal bleeding.
- B. Exophthalmos.
- C. Numbness in the infraorbital nerve distribution. ***

169. Hypercementosis and Ankylosis is seen in:

- A. Paget disease. ***
- B. Monocytic fibrous dysplasia.
- C. Hyperparathyroidism.

170. The infection will spread cervically in infection from:

- A. Lower incisors.
- B. Lower premolars.
- C. Lower 2nd and 3rd molars. ***
- D. Upper incisors.

171. In hypertension patient the history is important to detect severity:

- A. True. ***
- B. False.

172. Forceps to hold flap when suturing:

- A. Adson's. ***

Surgical forceps are used for suturing the wound, firmly grasping the tissues while the needle is passed. There are two types of forceps: the long standard surgical forceps, used in posterior areas, and the small, narrow Adson forceps, used in anterior areas.

173. Pulp edema:

- A. Has no effect on vascular system.
- B. Fluid is compressed in the vessels limiting the intercellular pressure.
- C. Interstitial pressure increased due to increased vascularity ***
- D. Cause necrosis of the pulp tissues.

174. Master cone doesn't reach the apex:

- A. Ledge.
- B. Residual remnants. (debris)
- C. X.
- D. 1 & 2. ***

175. Pterygomandibular raphe:

- A. Insertion & Origin.
- B. Muscles.
- C. Should be medial to the injection.
- D. All of the above. ***

176. (10 years) child with congenital heart disease came for extraction of his lower 1st molar, the antibiotic for choice for prevention of infective endocarditis is:

- A. Ampicillin 30 mg /kg orally 1hour before procedure.
- B. Cephalixine 50mg/kg orally 1hour before procedure.
- C. Clindamicine 20mg/kg orally 1hour before procedure.
- D. Amoxicillin 50mg/kg orally 1hour before procedure. ***

Amoxicillin , 2.0 gm orally 1 hr before procedure"

177. Patient complaining of Xerostomia & frequent going to the toilet at night:

- A. Diabetes Mellitus. ***

178. Patient had anaphylactic shock due to penicillin injection , what's the most important in the emergency treatment to do:

- A. 200 mg hydrocortisone intravenous.
- B. 0.5 mg epinephrine of 1/10000 intra venous.
- C. Adrenaline of 1/1000 intra muscular. ***

Anaphylaxis is always an emergency. It requires an immediate injection of 0.1 to 0.5 ml of epinephrine 1: 1,000 aqueous solution, repeated every 5 to 20 minutes as necessary. • If the patient is in the early stages of anaphylaxis and hasn't yet lost consciousness and is still normotensive, give epinephrine I.M. or subcutaneously (S.C.), helping it move into the circulation faster by massaging the injection site. For severe reactions, when the patient has lost consciousness and is hypotensive, give epinephrine I.V.

Management

- Place patient supine with legs raised, if possible.
- 0.5 ml of 1:1000 adrenaline IM or SC. Repeat after 15 min, then every 15 min until improved. Do not give IV in this concentration as it will induce ventricular fibrillation.
- Up to 500 mg of hydrocortisone IV.
- Up to 20 mg of chlorpheniramine slowly IV (if available).
- O2 by mask,

179. Bronchial asthma epinephrine concentration subcutaneously:

- A. 1/1000. ***
- B. 1/10000.
- C. 1/100000.

If the reaction is immediate (less than 1 hour) and limited to the skin, 50 mg of diphenhydramine should be given immediately either intravenously or intramuscularly. The patient should be monitored and emergency services contacted to transport the patient to the emergency department. If other symptoms of allergic reaction occur, such as conjunctivitis, rhinitis, bronchial constriction, or angioedema, 0.3 cc of aqueous 1/1000 epinephrine should be given by subcutaneous or intramuscular injection. The patient should be monitored until emergency services arrive. If the patient becomes hypotensive, an intravenous line should be started with either Ringer's lactate or 5% dextrose/water.

180. Which is contraindicated to the general anaesthesia:

- A. Patient with an advanced medical condition like cardiac. ***
- B. Down's syndrome patient.
- C. Child with multiple carious lesion in most of his dentition.
- D. Child who needs dental care, but who's uncooperative, fearful. etc.

181. Continuous condensation technique in GP filling is:

- A. Obtura I.
- B. Obtura II.
- C. Ultrafill.
- D. System B. ***

All of the first three options injection techniques & Softened by heat.

182. What's the test used for HIV:

- A. Elisa. ***

183. Pt with renal dialysis the best time of dental Tx is:

- A. 1 day before dialysis.
- B. 1 day after dialysis. ***
- C. 1 week after dialysis.

Patients typically receive dialysis 3 times/week. Dental treatment for a patient on dialysis should be done on the day between dialysis appointments to avoid bleeding difficulties.

في الحالات المعتدلة يتم تغيير الدم للمريض (كل أسبوع) وبعدها (بيوم واحد) يكون ب أوج نشاطه عكس اليوم السابق لتبديل الدم ، أما بنفس اليوم لا يمكن إجراء الجراحة بسبب وجود (الهيبارين) بالدم.

184. Pt presented with vehicle accident u suspect presence of bilateral condylar fracture what is the best view to diagnose condylar Fracture:

- A. Occiptomenatal.
- B. Reverse Towne. ***
- C. Lat oblique 30 degree.

Reverse town for fracture of condylar neck & ramus areas.
Reverse Townes position, beam 30° up to horizontal. Used for condyles.

185. The nerve which supplies the tongue and may be anesthetized during nerve block injection:

- A. V.
- B. VII. ***
- C. IX.
- D. XII.

(Note .. An injection into parotid capsule during nerve block injection MAY CAUSE Bell's palsy facial expretion) AND The sensory portion of facial N supplies the taste to the anterior two-thirds of the tongue)

186. Pt came to the clinic after he has an accident. X-ray revealed bilateral fracture of the condyle. Mandible movements are normal in all direction.... What is your treatment?

- A. Inter maxillary mandibular fixation.
- B. Fixed IMF for 6 weeks.
- C. Inter mandibular fixation. ***
- D. No treatment is performed only anti inflammatory drugs and observation.

187. 9 year old Pt came to the clinic after he has an accident. X-ray revealed bilateral fracture of the condyle. Mandible movements are normal in all direction. What is your treatment?

- A. Inter maxillary mandibular fixation.
- B. Fixed IMF for 6 weeks.
- C. Inter mandibular fixation.
- D. No treatment is performed only anti inflammatory drugs and observation. ***

بالنسبة للسؤالين السابقين يجب عدم التثبيت إذا كان المريض صغيراً كالحالة الثانية منعا لحدوث (أنكيلوسز) أما إذا كان المريض كبيراً فإننا نستخدم جبيرة لتحديد حركة الفك السفلي أي الخيار الثالث حسب كلام استشاري جراحة وجهه وفكين ..

188. Pt taken heparins he should do surgery after :

- A. 1 Hr.
- B. 2 Hr.
- C. 4 Hr.
- D. 6 Hr. ***

189. Avulsed teeth with replantation, dentist evaluate prognosis with :

Flexible wire. ***

Ridge wire.

In follow-up pd wire.

Splinting the tooth in position:

The ideal splint for avulsed teeth is a flexible splint. These are typically made using Gortex or other synthetic cloth or metallic mesh strips made for this purpose. Other types of flexible splint may be made using thin orthodontic wire. Ideally, the splint should encompass several teeth on either side of the avulsed tooth. There are quite a few options depending on the comfort level of the practitioner. The recommendation for flexibility involves theoretical considerations in the formation of the new periodontal ligament. However, since the splint is kept in place for no more than 7 to 10 days, the flexibility factor may be of little practical significance. This is my personal opinion. I'm sure others would argue the point.

190. Pt need complete denture, when u did the examination u notice the max tuberosity will be interfere with denture:

A. Need 12 no blade to be extention. ***

B. partial thickness flap extend buccal & palatal suture under tension.

Tuberosity Reduction:

Excesses in the maxillary tuberosity may consist of soft tissue, bone, or both. Sounding, which is performed with a needle, can differentiate between the causes with a local anesthetic needle or by panoramic radiograph. Bony irregularities may be identified, and variations in anatomy as well as the level of the maxillary sinuses can be ascertained. Excesses in the area of the maxillary tuberosity may encroach on the interarch space and decrease the overall freeway space needed for proper prosthetic function. Access to the tuberosity area can be obtained easily using a crestal incision beginning in the area of the posterior tuberosity and progressing forward to the edge of the defect using a no. 12 scalpel blade. Periosteal dissection then ensues exposing the underlying bony anatomy. Excesses in bony anatomy are removed using a side-cutting rongeur.

191. Skeletal Bone of skull develop from :

A. Neurocranium ossification.

B. Intramembranous ossification.

C. Endochondral ossification. ***

Endochondral ossification : Short bone and long bone. Ethmoid, sphenoid and temporal bone. Intramembranous ossification: Flat bone.

192. Skeletal face is from:

A. Neural crest***

B. Paraxial mesoderm.

C. lateral plate (somatic layer) mesoderm.

Neural crest give rise to : frontal b. – sphen nasal - lacrimal zygomatic maxilla incisive mandible _SqTemporal.paraxial mesoderm (somitesomitomeres) gives rise to occipitals - pet temporal- -parietal bon.

193. Glenoid fossa is found in:

A. Orbital cavity.

B. Nasal cavity.

C. Middle cranial fossa.

D. Temporal bone. ***

The Glenoid fossa = the mandibular fossa.

The mandibular fossa: a depression in the temporal Bone that articulates with the condyle of the Mandible and is divided into two parts by a slit.

194. The spread of Odontogenic infection is based on:

- A. Host defense.
- B. Virulent of microorganism.
- C. No. Of bacteria.
- D. All. ***

195. Surgery for ridges aim to:

- A. Vertical dimension.
- B. Speech.
- C. Modify ridge for stability. ***

196. Patient with warfarin treatment and you want to do surgery, when you can do:

- A. When PTT is 1 – 1.5 INR on the same day.
- B. When PTT is 2 – 2.5 INR on the same day.
- C. When PT is 1 – 1.5 INR on the same day. ***
- D. When PT is 2 – 2.5 INR on the same day.

Warfarin affects clotting factors II, VII, IX, and X by impairing the conversion of vitamin K to its active form. The normal PT for a healthy patient is 10.0—13.5 seconds with a control of 12 seconds. Oral procedures with a risk of bleeding should not be attempted if the PT is greater than 1½ times the control or above 18 seconds with a control of 12 seconds.

197. The last sensation which disappear after local anesthesia:

- A. Pain.
- B. Deep pressure. ***
- C. Temperature.

Both sensory & motor nerves are equally sensitive. Order of pain blockade is pain, temperature, touch, deep pressure sense. Applied to tongue bitter taste is lost first, followed by sweet & sour, and salty taste is lost last of all.

198. Pt take 40 cortisone in day of procedure:

- A. Double the dose just day of procedure. ***
- B. Double the dose day of procedure & day after.
- C. Stop the medication.

199. Which of the following materials is NOT a haemostatic agent :

- A. Oxidized cellulose.
- B. Galvan.
- C. Zinc Oxide. ***

200. Patient suffering from a submandibular gland abscess, dentist made a stab incision and is fixing a rubber drain to evacuate the pus, the drain is sutured to :

- A. Intra-oral
- B. From angle of the mandible.
- C. Between myeloid muscle and.....

201. Upon opening an incision in a periapical abscess in a lower 1st molar, you open :

- A. The most bottom of the abscess. ***
- B. The most necrotic part of the abscess.
- C. Extra oral.

202. Neonate 2 years old, has a lesion on the centrum of the tongue. With the eruption of the 1st tooth:

A. Riga-Fede disease. * <sublingual traumatic ulceration>**

Riga-Fede disease: a tumor of the tongue (Lingual Frenum) in some infants. It is caused by early teeth rubbing on it. Also called (Fede's Disease).

203. The type of maxillofacial defects:

- A. Congenital defects.
- B. Acquired defects.
- C. Developmental defects.
- D. All. *****

204. Cleft palate, cleft lip, missing ear, prognathism are:

- A. Acquired defects.
- B. Congenital defects. *****
- C. Developments defects.
- D. None.

205. Accidents, surgery, pathology are:

- A. Acquired defects. *****
- B. Developments defects.
- C. Congenital defects.
- D. None.

206. Extra-oral restorations are:

- A. Radium shield.
- B. Ear plugs for hearing.
- C. Missing eye, missing nose or ear. *****
- D. All.

207. Lost part of maxilla or mandible with the facial structures is classified by:

- A. Intra-oral restorations.
- B. Extra-oral restorations.
- C. Combined intra-oral and extra-oral restorations. *****
- D. All.

208. The lack of continuity of the roof of the mouth through the whole or part of its length in the form of fissure extending anteroposteriorly is:

- A. Obturator.
- B. Splint.
- C. Stent.
- D. Congenital cleft palate. *****

209. **The factors that influence the induction of cleft palate:**
A. Hereditary.
B. Environmental.
C. A and B. ***
D. None.
210. **A prosthesis used to close a congenital or acquired opening in the palate is:**
A. Stent.
B. Splint.
C. Obturator. ***
D. None.
211. **-..... Are appliances used for immobilization of fragments of broken parts of jaw bones in their original position until repair takes bleeding?**
A. Splints. ***
B. Stents.
C. Obturators.
D. Speech aids.
212. **Outline of Pericoronitis treatment may include:**
A. Mouth wash and irrigation.
B. Extraction of the opposing tooth.
C. Surgical removal of the causative tooth.
D. All the above. ***
213. **Physiological activity of local anesthesia**
A. Lipid solubility. *** (Lipid solubility of unionized form)
B. Diffusibility.
C. Affinity for rotenone.
D. Percent ionizing at physiologic pH.
E. Vasodilation properties.
214. **Re-implant of avulsed tooth , what to do:**
A. Optimal reposition and fixed splint.
B. Optimal reposition and flexible splint. ***
C. Observe.
D. Watch with splint periodontally.

AVULSED TOOTH

Splint tooth in position with (Preferably) a flexible splint.

Have patient bite into occlusion to be certain that the position is correct before applying the splint.

The splint will be kept in place for about one week.

215. **The following medicines are given to a patient angina pectoris EXCEPT:**
A. Broberanol.
B. Verelan.
C. Metoprolol Tartrate.
D. Nasids ***
216. **When u want to make immediate complete denture after extraction all teeth what the type of suture u will use:**
A. Horizontal mattress suture.
B. Vertical mattress suture.
C. Interrupted suture.
D. Continuous locked suture. ***
217. **The patient has an appointment for minor surgery on his right lower first molar after anesthesia I.A.N.B there is pain found in lower molar, we should complete to give anesthesia:**
A. The lingual nerve.
B. Mental nerve.
C. Nerve mylohyoideus. ***
D. Auriculotemporalis nerve.
218. **Child has a blue color on the gums. Symptoms only profuse saliva, what is the diagnosis?**
A. Eruption hematoma. ***
219. **After remove impacted 3rd lower molar , there is parasthesia why?**
A. Irritating the nerve during extraction. ***
B. Broke mandible.
220. **Mobility in mid-face with step deformity in front Zygomatic suture. Diagnosis:**
A. Lefort II.
B. Lefort III.***
C. Bilateral zygomatic complex fracture.
221. **In case of infiltration anesthesia we give**
A. Sub-mucosal. ***
B. Intraosseous.
C. Sub-periosteal.
D. None.
222. **The patient who have not breakfast , we never give him anesthesia because:**
A. Hyperglycemia.
B. Hypoglycemia. ***
C. Increased heart rate.
D. Hypertension.

223. For injection local anesthesia in the lower jaw we use :

- A. Short needle.
- B. Long. ***
- C. None.

224. Adrenaline is added to local anesthesia for :

- A. Increasing the respiratory rate.
- B. Prolonging the effect of local anesthesia. ***
- C. Increasing the bleeding.
- D. None.

225. During surgery firmly handle forceps of flap tissue:

- A. Stillis forceps.
- B. Adison forceps. ***

Adson forceps (tissue forceps)

These forceps are non-toothed, and so are ideal for **holding** delicate tissues.

226. Lemphadenopathy due to:

- A. Infection.
- B. Lymphocytic leukemia.
- C. HIV.
- D. Pernicious aneamia.
- E. A , B and C. ***

227. The aim from prosthetic surgery:

- A. Increase stability , retention , ridge dimension. ***
- B. Increase vertical dimension.
- C. Esthetic anterior.

228. During mentoplasty doctor should take care for injury of what nerve..

- A. lower branch of the facial nerve. ***

229. The roots of the following teeth are closely related to the maxillary sinus:

- A. Canine and upper premolar.
- B. Lower molar.
- C. Upper molar and premolar. ***
- D. None.

230. Patient positions are:

- A. Upright position.
- B. Supine position.
- C. Sub supine.
- D. All of the above. ***

- 231. On radiograph (onion skin) appearance , and under microscope there is glycogen:**
A. Osteosarcoma
B. Pindborg tumor.
C. Ewing sarcoma. ***
- 232. Healing by secondary intention cause:**
A. X
B. There is space between the edges filled by fibrous tissue.
C. Leading to scar formation.
D. B and C. ***
- 233. A 65 year old woman arrived for dental therapy. The answered questionnaire shows that she is suffering from severe cirrhosis. The problem that can be anticipated in the routine dental therapy is:**
A. Extreme susceptibility to pain.
B. Tendency towards prolonged hemorrhage. ***
C. Recurring oral infection.
D. Increased tendency to syncope.
E. Difficulty in achieving adequate local anaesthesia.
- 234. Loss of sensation in the lower lip may be produced by:**
A. Bell's palsy
B. Traumatic bone cyst
C. Trigeminal neuralgia
D. Fracture in the mandible first molar region. ***
E. Ludwig's angina.
- 235. Patient received heavy blow to the right body of the mandible sustaining a fracture there. You should suspect a second fracture is most likely to be present in:**
A. Symphysis region.
B. Left body of the mandible.
C. Left sub-condylar region. ***
D. Right sub-condylar region.
E. sub-condylar region.
- 236. Signs and symptoms that commonly suggest cardiac failure in a patient being assessed for oral surgery are :**
A. Elevated temperature and nausea.
B. Palpitations and malaise.
C. Ankle oedema and dyspnoea. ***
D. Erythema and pain.
E. Pallor and tremor.

- 237. A cyst at the apex of an upper central incisor measuring 1 cm in diameter is visualized in radiograph and confirmed by aspiration biopsy; which method of treatment would you consider:**
- A. Extraction of the central incisor and retrieving the cyst through the socket.
 - B. Exteriorizing the cyst through the buccal bone and mucosa.
 - C. Making a mucoperiosteal flap and removing the cyst through an opening made in the alveolar bone, followed by tooth removal.
 - D. Making a mucoperiosteal flap and removing the cyst through an opening made in the alveolar bone, followed by endodontic treatment. *****
 - E. Routine orthograde endodontic treatment followed by observation.
- 238. A persistent oroantral fistula for a 12 weeks period following the extraction of a maxillary first permanent molar is best treated by:**
- A. Further review and reassurance since it will most probably heal spontaneously.
 - B. Antibiotic therapy and nasal decongestants.
 - C. Curettage and dressing of the defect.
 - D. Excision of the fistula and surgical closure. *****
 - E. Maxillary antral wash out and nasal antrostomy.
- 239. The most significant finding in clinical evaluation of parotid mass may be accompanying:**
- A. Lymph adenopathy.
 - B. Nodular consistency.
 - C. Facial paralysis. *****
 - D. Slow progressive enlargement .
 - E. Xerostomia.
- 240. As far as surgical removal of wisdom teeth is concerned which of the following is true:**
- A. Prophylactic prescription of antibiotic reduces dramatically the chances of infection. *****
 - B. Raising a lingual flap will increase the incidence of neurapraxia but will reduce the incidence of neurotmesis with respect to the lingual nerve
 - C. Prophylactic prescription of dexamethasone will dramatically reduce post operative swelling
 - D. Inferior dental nerve injury is unlikely since the nerve passes medial to the wisdom tooth root
 - E. The use of vasoconstrictors in local anaesthetics will increase the chances of infection.

Oral medicine 175 MCQs

1- Aphthous ulcer, compared with herpes ulcer is:

- A. More characteristic in histology.
- B. Leaves scar.
- C. Less response to stress.
- D. Occur in lining mucosa. ***

2- Syphilis first appearance:

- A. Multiple vesicle.
- B. Erythematous reaction.
- C. Ulcer. ***
- D. Bullae.

3- Child with vesicle on the hard palate with history of malaise for 3 days what is the possible diagnosis:

- A. Herpes simplex. ***
- B. Erythema multiform.

4- Which virus is present in the patient's mouth all his Life?

- A. Herpes Simplex
- B. Herpes zoster
- C. Varicella Virus
- D. None of the above ***

Herpes Simplex - Symptoms, Treatment and Prevention:

Cold sores are caused by the Herpes Simplex Virus. Once infected, they plague the patient for life.

Herpes can be treated but not cured. Symptoms appear briefly and then disappear; the disease lies dormant in nerve cells, but it may be reactivated by stress or illness.

Shingles:

Shingles is caused by the varicella zoster virus, which also causes chickenpox. If you have had chickenpox, the varicella virus remains in a group of nerves in your central nervous system, but doesn't cause any symptoms. This is called a dormant virus. The central nervous system consists of the brain and spinal cord, which are connected to the nerves in the body. When the virus becomes active again, it causes the symptoms of shingles.

Varicella-zoster virus (VZV) is the cause of chickenpox and herpes zoster (also called shingles).

الفيرس الذي يسكن الجسم مدى الحياة (لا يسكن الفم) : (HSV1) Herpes Simplex :

4- Calcium channel blockers cause increase saliva secretion :

- A. True.
- B. False. ***

5- The most common type of biopsy used in oral cavity is:

- A. Excisional biopsy. ***
- B. Incisional biopsy.
- C. Aspiration through needle.
- D. Punch biopsy.

6- 10 years old child present with bilateral swelling of submandibular area, what could be the disease:

- A. Fibrous dysplasia.
- B. Cherubism ***
- C. Polymorphic adenoma.

Cherubism , the most common presenting sign is a painless , firm , bilateral enlargement of the lower face. It develops nearly child hood.

7- The scientific evidence in dictating that oral Lichen planus is a "pre-malignant Lesion" is:

- A. Very strong
- B. Non-existent
- C. Moderately strong
- D. Weak. ***

- The pre-malignant potential of oral lichen planus and the malignant transformation rate is cited as 0.4-3.3 per cent. Whether or not patients with atrophic or erosive forms of oral lichen planus are more susceptible to malignant change has yet to be proved by long-term prospective studies. Good prognosis; rare malignant transformation (0.5–3%).

8- Oral lesions of lichen planus usually appear as:

- A. White striae. ***
- B. Red plaque.
- C. Shallow ulcers.
- D. Papillary projections.
- E. Bullae.

9- The oral lesions of the lichen planus:

- A. Are usually painful.
- B. Rarely appear before lesion elsewhere on the body.
- C. May be part of a syndrome in which lesions also appear on the skin, conjunctiva and genitalia. ***
- D. Often appear in nervous, high-strung individuals.
- E. Heals with scarring.

Skin Sites: Forearm, Shin, Scalp, Genitalia.

Etiology: • Unknown • Autoimmune T cell-mediated disease targeting basal keratinocytes.
Lichen Planus Variants: reticular (most common oral form) - erosive (painful) – atrophic ,
papular , plaque types; bullous (rare).

10- All of the following are oral features of acquired immunodeficiency syndrome (AIDS) EXCEPT:

- A. Candidiasis.
- B. Erythema multiform. ***
- C. Hairy leukoplakia.
- D. Rapidly progressing periodontitis.
- E. Kaposi's sarcoma.

11- Hairy trichoglossia may be caused by:

- A. Broad spectrum antibiotic.
- B. H₂O₂ mouth wash.
- C. Systemic steroid.
- D. Heavy smokers.
- E. All of the above. ***

12- In hairy tongue, which taste buds increase in Length:

- A. Fili form. ***
- B. Fungi form.
- C. Foliate.
- D. Circumvallates.

13- Verrucous carcinoma:

- A. Malignant. ***
- B. Benign.

14- Patient comes to your clinic complaining that the denture become tight, during examination you notice nothing, but when the patient stand you notice that his legs bowing (curved). What you suspect :

- A. Paget's disease.. ***

15- Pt come for check up, no complaining , after radiograph u see well circumscribe radiolucent area in related to mandibular molar & the periphery was radiopaque which not well defined border the diagnosis is:

- A. Simple bone cyst. ***

16- Scalloped border above inferior alveolar canal between roots of mandibular molars, this lesion is:

- A. Solitary cyst.
- B. Aneurysmal bone cyst.
- C. Traumatic bone cyst (Simple Bone Cyst). ***

- This is the radiographic finding for the the trumatic bone cyst Radiographically, these lesions tend to appear as smoothly outlined radiolucencies that scallop around the roots of the teeth.

They do not displace teeth or resorb roots, and the lamina dura is left intact.

They may range from very small (<1 cm) to very large (involving most of the mandible).

- They tend to occur above the inferior alveolar canal.
- A traumatic bone cyst is not a true cyst since there is no epithelial lining.
- Found mostly in yong people, asymptomic.
- Radiolucency which appears to scallop around the roots of teeth.
- Teeth are usually vital.

17- Cyst between roots of mandibular molars , above the mandibular canal has scalloped border above inferior alveolar canal, on inspiration straw like exudate, the teeth were vital, no periodontal involvement this lesion is:

- A. Static bone cyst.
- B. Stafne bone cyst.
- C. Aneurismal bone cyst.
- D. **Unicameral bone cyst. *****

18- Radiographic radiolucency in the interradicular area:

- A. Invasion of furcation.
- B. Periodontal abscess.
- C. **Periodontal cyst. *****

19- Mental foramen appear in radiograph as radiolucent round area to the area of:

- A. **Mandibular premolars. *****
- B. Mandibular incisors.
- C. Maxillary canine.

20- Radiographic diagnosis of a well-defined, unilocular radiolucent, area between vital mandibular bicuspias is more likely to be:

- A. Residual cyst.
- B. **The mental foramen. *****
- C. A radicular cyst.
- D. Osteoporosis.
- E. None of the above.

21- Which cyst is not radiolucent?

- A. Globulomaxillary cyst.
- B. Follicular cyst.
- C. **Dentigerous cyst. *****
- D. Nasopalatine cyst.

22- Female . Swelling in left of mandible, slowly increasing , radio opaque surrounded by radiolucent band:

- A. Osteoma.
- B. Ossifying fibroma.
- C. **Cementoblastoma. *****
- D. Osteosarcoma.

23- Radiolucent are cover the pericornal part of the 3rd molar is:

- A. **Dentigerous cyst. *****
- B. Central.

24- Cyst in x- ray:

- A. Radiolucent with bone expansion.
- B. **Radiolucent with bone resorption. *****

Cyst growth: Several mechanisms are described for cyst growth.

Including:

- ✓ Epithelial proliferation.
- ✓ Internal hydraulic pressure.
- ✓ Bone resorption.

25- Which of the following lesions has more tendency to show well defined multilocular radiolucency:

- A. Lateral periodontal cyst
- B. Squamous cell carcinoma of jaw bones
- C. Primordial cyst.
- D. Ameloblastoma. *****
- E. Osteomyelitis of the mandible.

26- Pt come for check up, no complaining, after radiograph u see well circumscribe radiolucent area in related to mandibular molar & the periphery was radiopaque which not well defined border the diagnosis is:

- A. Simple bone cyst. *****

27- Radiographic diagnosis of bone destructive in the mandible without evidence of bone formation is:

- A. Osteomyelitis.
- B. Malignancy. *****
- C. Fibro-osseous lesion.
- D. Fracture.
- E. Osteoradionecrosis.

Malignant lesions destroy bone uniformly. In osteomyelitis, areas of radiographically normal-appearing bone are frequently seen between the areas of destruction. Sequestra are not present in malignant lesions.

28- A 60-year-old man has been treated for a (t2nomo) squamous cell carcinoma by radical radiotherapy. He has a history of chronic alcoholism and was a heavy smoker. Six years after treatment, he develops a painful ulcer in the alveolar mucosa in the treated area following minor trauma. His pain worsens and the bone became progressively exposed. He is treated by a partial mandibular resection with graft. The diagnosis is :

- A. Acute osteomyelitis.
- B. Gerre,s osteomyelitis.
- C. Osteoradionecrosis. *****
- D. Chronic osteomyelitis.

29- Osteoradionecrosis is more in :

- A. Maxilla.
- B. Mandible. *****
- C. No difference.

30- Radiographic diagnosis of bilateral expansible radio opaque areas in the canine premolar region of the mandible is:

- A. Hematoma.
- B. Remaining roots.
- C. Tours mandibularis. *****
- D. Internal oplique ridge.
- E. Genial tubercle.

31- In radiographs, which disease cause multiple radiolucencies:

- A. Hypothyroidism.
- B. Hyperparathyroidism. ***
- C. Ricket disease.

32- The following are multilocular radiolucencies in x-ray EXCEPT:

- A. Ameloblastoma.
- B. Odontogenic keratocyst.
- C. Adenomatoid Odontogenic cyst. ***
- D. Myxoma.

Central giant cell reparative granuloma - aneurismal bone cyst - brown tumor of hyperparathyroidism - Odontogenic Myxoma/Myxofibroma – Cherubism - Hypopharynx Abscess -

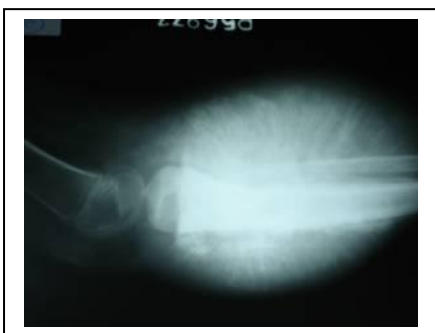Simple Bone Cyst: Solitary bone cyst, traumatic bone cyst, hemorrhagic bone cyst, hemorrhagic cyst, idiopathic bone cavity, unicameral bone cyst
Fibrous Dysplasia - Mucoepidermoid Carcinoma –

33- (33 years old) female PT come with slow growing swelling in the angle of the mandible. Radiograph show radio-opaque with radio-lucent border diagnosis:

- A. Osteoma.
- B. Osteosarcoma.
- C. Cementoblastoma. ***

34- Patient came to your clinic with severe pain, on x-ray the right side of the mandible has a radiolucency with a radiopaque border that resembles the sunshine rays. Your diagnosis is :

- A. Ossifying fibroma.
- B. Osteosarcoma. ***
- C. Acute Osteomyelitis.



Cortical integrity, periosteal reaction and soft tissue Slow-growing lesions often cause expansion with cortical bowing, while cortical destruction denotes aggressive inflammatory or neoplastic lesions. Presence of periosteal reaction and soft tissue is also suggestive of an inflammatory or malignant aetiology. Some types of periosteal reactions are quite specific, like the sunburst type in osteosarcoma.

Periapical and occlusal radiography and orthopantomography revealed diffuse bone destruction on the left side of the mandible due to the presence of a lesion of variable appearance, presenting dense radiopaque, mixed and completely radiolucent areas. The lesion was extensive and poorly delimited, with the periosteum showing the classical "sunray" reaction on occlusal and periapical radiographs.

35- Osteomyelitis most in:

- A. Maxilla
- B. Mandible. ***

36- Child 12 years old with swelling in the mandibular premolars area, first premolar clinically missing, in X ray examination we found Radiolucent is cover the percoronal part of the 3rd molar is:

- A. Dentigerous cyst. ***

37- Osteomyelitis more common :

- A. Maxilla.
- B. **Mandible *****
- C. Zygoma.
- D. Nasal septum.
- E. Condyle.

38- Diabetic patient came to clinic with pain & swelling & enlarged mandible, on radiograph it showed moth eaten appearance, your diagnosis is :

- A. **Acute osteomyelitis. *****
- B. focal sclerosing osteomyelitis.
- C. diffuse sclerosing.

OSTEOMYELITIS : Radiographically the "moth-eaten" appearance is quite characteristic.

39- Patient suffering from pain in the area of the mandibular molars with paresthesia in the lower lip. By clinical and radiographic examination your diagnosis:

- A. **Acute osteomyelitis. *****

Oral paresthesia may be caused by manipulation or inflammation of a nerve or tissues around a nerve, direct damage to a nerve or tissues around a nerve, tum or impinging on or invading a nerve, pnmary neural tumor, and central nervous system tumor.

40- The x ray show scattered radiopaque line in the mandible jaw, the diagnosis will be:

- A. **Paget disease. *****
- B. Garres syndrome.
- C. Fibrous dysplasia.
- D. Osteosarcoma.

41- The most common type of malignant bone tumor of the jaws is:

- A. Osteochondrosarcoma.
- B. **Osteosarcoma. *****
- C. Leiomyosarcoma.
- D. Chondrosarcoma.

42- HBV can be transmitted by transplacental:

- A. **True. *****
- B. False.

43- Bleeding of the socket following tooth extraction:

1. Is always a capillary bleeding in nature.
2. Takes not less than half – day in normal individual.
3. Is always favorable if it is primary type.
4. Can be due to the presence of a nutrient vessel.
 - A. 1 and 2 are correct.
 - B. 1, 2 and 3 are correct.
 - C. **1, 3 and 4 are correct. *****
 - D. All are correct.

44- In sickle cell anemia, O₂ is decreased in oral mucosa:

- A. True. ***
- B. False.

45- Destruction of RBC may cause anemia and it is due to defect in cell membrane:

- A. True. ***
- B. False.

46- Immunofluorescent test and biopsy are used to diagnosis pemphigus:

- A. True. ***
- B. False.

47- Measuring blood pressure is one of vital signs important in medical compromised:

- A. True. ***
- B. False.

48- Cell of chronic inflammation:

- A. Lymphocytes. ***
- B. PMN.
- C. Neutrophils.

49- Amalgam tattoo is an oral pigmentation lesion:

- A. True. ***
- B. False.

50- Oral and perioral cyst formed from epithelial rest of serres:

- A. True.
- B. False. ***

51- DNA only infect human but RNA doesn't infect human:

- A. True.
- B. False. ***

52- Parotid DUCT is opposite to :

- A. Maxillary premolar.
- B. Maxillary 1st molar.
- C. Maxillary 2nd molar ***
- D. Mandibular 1st molar.

The parotid duct, also known as Stensen's duct, is the route that saliva takes from the parotid gland into the mouth. It passes through the buccal fat, buccopharyngeal fascia, and buccinator muscle then opens into the vestibule of the mouth next to the maxillary second molar tooth. The buccinator acts as a valve that prevents inflation of the duct during blowing. Running along with the duct superiorly is the transverse facial artery and upper buccal nerve; running along with the duct inferiorly is the lower buccal nerve.

53- The most common benign tumor in oral cavity is:

- A. **Fibroma.** ***
- B. Papilloma.
- C. Lipoma.

Dental Decks - page 1030-1039

- **Fibroma:** Reactive , the most common tumor seen in oral cavity.

54- The most prominent cell in acute inflammation is:

- A. Lymphocyst.
- B. Plasma cell.
- C. **PMN.** ***

55- Flat bone grow by endochondral ossification:

- A. True.
- B. **False.** ***

56- Radiopacity attached to root of mandibular molar:

- A. Ossifying fibroma.
- B. **Hypercementosis.** ***
- C. Periapical cemental dysplasia.

57- Geographic tongue is seen in Pt with:

- A. **Diabetes.** ***
- B. Iron deficiency anemia.
- C. Pemphigus.

Benign migratory glossitis is seen with a fourfold increase in frequency in patients with juvenile diabetes, possibly due to an increased frequency of elevated amounts of the HLA-B15 tissue type.

52- Geographic tongue is always accompanied in patient with:

- A. Diabetes.
- B. Erythema multiform.
- C. Iron deficiency.
- D. **Psoriasis.** ***

Geographical tongue:

There may be an association between certain types of psoriasis (especially pustular psoriasis) and geographic tongue.

53- (A 21 years old) patient who has iron deficiency anemia, difficulty in swallowing, with examination of barium sulphate , you found:

- A. Geographical tongue.
- B. **Burning mouth syndrome.** ***
- C. Syndrome.
- D. Diabetic patient.

Iron deficiency result in:

Candida – Leukoplakia - Aphthous Stomatitis - Sore tongue (Glossodynia – Glossitis – Burning mouth syndrome) - Patterson-Brown-Kelly syndrome (GASTROINTESTINAL DISEASE)

54- Pt came to the clinic complaining from soreness in the tongue sore throat the diagnosis is:

- A. Burning mouth syndrome. ***
- B. Geographical tongue.
- C. Fissure tongue.

Acute atrophic candidiasis presents as a red patch of atrophic or erythematous raw and painful mucosa, with minimal evidence of the white pseudomembranous lesions observed in thrush. Antibiotic sore mouth, a common form of atrophic candidiasis, should be suspected in a patient who develops symptoms of oral burning, bad taste, or sore throat during or after therapy with broad-spectrum antibiotics. Patients with chronic iron deficiency anemia may also develop atrophic candidiasis.

55- Handicapped Pt with lesion in central nervous system appears to have different type of disorder in movement and procedure:

- A. Seizure.
- B. Cerebral palsy. ***
- C. Learning disability.

Cerebral palsy: The disability might involve and uncoordinated or involuntary movements.

56- Intercellular movement of PMN leukocytes is called migration:

- A. True. ***
- B. False.

57- Gingival hyperplasia related to phenytoin therapy is:

- A. Most common on lingual surface.
- B. Most common in older Pt.
- C. Strongly related to phenytoin dosage.
- D. Strongly related to poor oral hygiene. ***

58- Burning mouth syndrome is a chronic disorder typically characterized by each of the following EXCEPT:

- A. Mucosal lesion. ***
- B. Burning pain in multiple oral sites.
- C. Pain similar in intensity to toothache pain.
- D. Persistent altered taste perception.

59- Which of the following is the most likely potential cause of BMS (Burning mouth syndrome):

- A. Denture allergy.
- B. Salivary dysfunction. ***
- C. Neural dysfunction.
- D. Menopausal changes. انقطاع الطمث

60- Which of the following represents the best pharmacologic therapy for BMS:

- A. Antidepressant agents.
- B. Corticosteroids.
- C. Anxiolytic agents.
- D. There is no therapy of proven general efficacy. ***

If an underlying cause of BMS can be identified (Table 2), then treatment should be directed toward the source.^{41,6} Unfortunately, treatment based on any of these possible etiologic factors is frequently ineffective,⁴ and no therapy for BMS has proven generally effective.

61- Type I diabetes mellitus can be characterized as:

- A. Non-insulin-dependent.
- B. Adult- onset.
- C. Ketosis-prone. ***
- D. Accompanied by normal cell activity.

62- The most common form of oral ulcerative disease is:

- A. HSV.
- B. Major aphthous ulcer.
- C. Bahjet disease.
- D. Minor aphthous ulcer. ***

63- The majority of primary herpetic infections are:

- A. Symptomatic.
- B. Asymptomatic. ***
- C. Proceeded by fever.
- D. Accompanied by gingival erythema.
- E. A, c and d.

64- Tobacco should be considered a risk factor when planning treatment for Pt who require:

- A. Implants.
- B. Periodontal surgery.
- C. Oral surgery.
- D. Esthetic treatment.
- E. All of the above. ***

65- Child came to u with gray discolouration of the deciduous incisor also on radio exam. There is dilation of follicle of the permanent successor what will u do:

- A. Extract the deciduous tooth. ***
- B. Start endo.
- C. Observe over time.

66- Droplet nuclei containing mycobacterium tuberculosis:

- A. Do not cause infection.
- B. Settle out of room air quickly.
- C. Do not spread widely in the building.
- D. Remain air-born for prolonged period. ***

67- Which of the following is the cause of immediate type allergic reaction to latex products:

- A. Accelerator.
- B. Antioxidants.
- C. Latex protein. ***
- D. Nickel.

68- Which of the following is a benign epithelial neoplasm:

- A. Rhabdomyoma.
- B. Fibroma.
- C. Lipoma.
- D. Granular cell tumor.
- E. Keratoacanthoma. ***

A **rhabdomyoma** is a benign neoplasm of striated muscle. Almost all lesions in the oral cavity that are called **fibromas** are not true neoplasms. A **lipoma** is a benign neoplasm composed of fat cells.

A **granular cell tumor**, also called granular cell myoblastoma or Abrikosov's tumor in the past, is a benign lesion of the soft tissues whose origin and nature are not fully understood. For a long time the lesion was considered a benign neoplasm related to muscles. Currently a neurogenic origin seems to be more likely.

A **keratoacanthoma**, also called molluscum sebaceum, is a benign cutaneous lesion that is believed to arise from hair follicles. Histologic examination of a keratoacanthoma shows hyperplastic epithelium with carcinoma-like features.

The keratoacanthoma: It is defined as a benign epithelial neoplasm, originated from the superior portion of the sebaceous gland of the hair follicle.

69- The function of the periodontal ligament include

- A. Mechanical function
- B. Formative function
- C. Nutritive function
- D. Sensory function
- E. All of the above. ***

70- Ankylosis:

- A. No PDL.
- B. Caused by trauma.
- C. Extracted surgically.
- D. All of the above. ***

71- The following are types of hematoma EXCEPT:

- A. Cementoblastoma ***.
- B. Compound odontoma.
- C. Complex odontoma.

72- A child came to the clinic with continuous involuntary movement of his head and extremities and difficulty in vocal communication; The condition is described as:

- A. Epilepsy.
- B. Cerebral palsy. ***

73- The movement of water across a selectively permeable membrane is called:

- A. Osmosis. ***
- B. Active transport.
- C. Filtration.
- D. Diffusion.

Osmosis is the net movement of water across a selectively permeable membrane driven by a difference in solute concentrations on the two sides of the membrane.

74- Cell that can give more than one type:

- A. Fibroblast.
- B. Odontoblast
- C. Mesenchymal cell. ***

Mesenchymal cell: An undifferentiated cell found in mesenchyme and capable of differentiating into various specialized connective tissues.

75- The Common disease affecting the submandibular salivary gland is:

- A. Salivary calculi ***
- B. Pleomorphic adenomas.
- C. Viral sialoadenitis.
- D. Infected sialoadenitis.

76- Which most common salivary gland neoplasm:

- A. Pleomorphic adenoma. ***

Pleomorphic adenoma is the most common tumor of the major and minor salivary glands.
وهو يصيب الغدة النكفية ويمثل ٨٠% من مجمل الأمراض التي تصيب الغدد اللعابية عموماً.

77- Ranula is associated with which salivary gland:

- A. Submandibular gland.
- B. Sublingual gland. ***

A **Ranula** is a similar cyst arising in the floor of mouth from the sublingual gland

78- Ranula Can be treated by:

- A. Excision.
- B. Cauterization.
- C. Incision.
- D. Marsupialization. ***

Marsupialization can be performed before a definitive excision. Contemporary oral and maxillofacial surgery. The usual treatment of ranula is marsupialization. The preferred tx for recurrent or persistent ranula is excision of the ranula and sublingual gland.

79- Solitary bone cyst management:

- A. Anti inflammatory and follow up.
- B. Curettage and close.
- C. Marsupialization. ***
- D. No active management.

80- Most common Benign Tumor in oral cavity is:

- A. Fibroma (Ameloblastic fibroma). ***

81- Which of the following spaces are bilaterally involved in Ludwig's angina?

- A. Submandibular + masticatory spaces
- B. Sublingual + Lat.Pha.space
- C. Submandibular + Sublingual + Submental. ***

82- The roof of mandibular fossa consist of:

- A. Thin compact bone. ***
- B. Spongy bone.
- C. Cancellous bone.

83- Neoplasm that spread by Lymphatic from the angle of the mouth reach the:

- A. Preauricular Lymph nodes.
- B. Mental Lymph nodes.
- C. Submandibular Lymph nodes. ***
- D. Pterygoid plexus.
- E. Jugulo-digastric nodes.

A standard rule of thumb is that the lymphatic drainage for any particular region is predicted by the arterial supply of that region. The lip, cheek, and anterior gingiva drain to submandibular and submental lymph node groups. In addition, the cheek and upper lip also drain to inferior parotid nodes.

84- A plastic anemia is caused by:

- A. Tetracycline.
- B. Penicillin.
- C. Erythromycin.
- D. Sulfonamide. ***

Aplastic Anemia : Roughly half of all aplastic anemias occur as a result of drugs (such antibiotics as chloramphenicol, sulfonamides, phenylbutazone [Butazolidin], and such anticonvulsant agents as mephenytoin)
Also: chloramphenicol, phenylbutazone [Butazolidin], and such anticonvulsant agents as mephenytoin.

85- The cell primary site of ATP production is:

- A. Mitochondria. ***
- B. Lysosomes.
- C. Nucleus.
- D. Nucleolus.
- E. Vacuoles.

86- The organelle most closely associated with the manufacture of proteins within the cell:

- A. Ribosome. ***
- B. Lysosome.
- C. Nucleolus.
- D. Cell wall.
- E. Cell membrane.

87- The packing and sorting of protein is the function of:

- A. Endoplasmic reticulum.
- B. Golgi apparatus. ***
- C. Mitochondria.
- D. Nucleus.

88- The process of attraction of neutrophils to a site of Local tissue injury is called:

- A. Phagocytosis.
- B. Diapedesis.
- C. Chemotaxis. ***
- D. Epistaxis.

89- Action of Histamine:

- A. Vasodilatation.
- B. Permeability.
- C. Chemokinesis.
- D. Broncho.
- E. All of the Above.

90- Cholesterol crystals are found in:

- A. Keratocyst. ***
- B. Periodontal cyst.

Radicular cysts : Contain brown shimmering fluid because of the presence of the cholesterol crystals, whereas odontogenic keratocysts contain pale greasy fluid, which may include keratotic squames. Cholesterol crystals are found in many odontogenic cysts including (Radicular cysts, Dentigerous cysts , and Odontogenic keratocysts.). The cyst wall shows nicks produced by **cholesterol crystals**, inflammatory cells, calcifications and satellite microcysts.

91- The process of cell engulfing particle is called:

- A. Endocytosis.
- B. Exocytosis.
- C. Phagocytosis. ***
- D. Pinocytosis.

92- The Most common odontogenic cysts in the jaws are:

- A. Radicular cyst. ***
- B. Keratocyst.

93- Most commonly dentigerous cysts are associated with:

- A. Unerupted permanent maxillary canines.
- B. Unerupted mandibular third molars. ***

Spontaneous regression of bilateral dentigerous cysts associated with impacted mandibular third molars : Article : British Dental Journal It is most prevalent in the third molar region and is therefore a common cause of a radiolucency associated with the crown of an impacted third molar.

Bilateral Dentigerous Cysts - Report of an Unusual Case and Review of the Literature although it may involve any tooth, the mandibular third molars are the most commonly affected.

94- Histopathologically , dentigerous cyst Lining epithelium may be:

- A. Cuboidal in type.
- B. Stratified squamous in type. ***
- C. Reduced enamel epithelium.
- D. All of the above.

95. Thyroglossal duct cysts:

- A. Are only found in the posterior tongue.
- B. Clinically present in the Lateral neck tissue.
- C. May be found anywhere along the pathway of the embryonic thyroglossal duct. **
- D. Are sometimes called Lympho-epithelial cysts.

Most cyst occur in the midline ,with 60% over the thyroid membrane and only 2% within the tongue it self. Residual epithelial elements that do not completely atrophy may give rise to cysts in later life.

96- Unilateral swelling + slowly progressing Lesion on the Left side of the mandible.

This could be:

- A. Osteoma.
- B. Cementoblastoma.
- C. Ossifying Fibroma. ***
- D. Osteo-sarcom.

The ossifying fibroma is a slow growing ,expansile lesion that is usually a symptomatic.

97- The body secret antibody against antigen using which cells:

- A. T lymphocyte.
- B. B lymphocyte. ***

98- In diabetic patient, periodontium affected by which cells:

- A. Neutrophil. ***
- B. Macrophages.

99- Cause of angular cheilitis:

- A. Loss vertical dimension Pt have complete denture. ***
- B. Autoimmune factors.

100- Compared to herpetic ulcers...aphthous ulcers are:

- A. Small size.
- B. In mucosa lining. ***
- C. Leave scars.

101- Nicotine stomatitis:

- A. Palate hyper ..?
- B. Hyperplasia.
- C. Prickle cell like shape prominent ... base ... ***

102- Treatment of fungal infections:

- A. Penicillin.
- B. Tetracyclin.
- C. Nystatin. ***

103- Radiographic diagnosis of bilateral expansible radio-opaque areas in the canine premolar area region of the mandible is :

- A. Hematoma.
- B. Remaining roots.
- C. Torus mandibularis. ***
- D. Internal oblique ridge.
- E. Genial tubercle.

104- Syphilis first appear as:

- A. Multiple vesicles.
- B. Erythematous reaction.
- C. Ulcer. ***
- D. Bulla.

105- Body defends itself by antibodies from:

- A. B lymphocytes. ***
- B. T lymphocyte.
- C. Plasma cell.

106- Cell that produce antibodies:

- A. B lymphocytes. ***
- B. T lymphocytes.
- C. Plasma cell .

107- Squamous Cell Carcinoma is derived from:

- A. Epithelial tissue. ***
- B. Connective tissue.

108- Most common site of oral squamous cell carcinoma:

- A. Postero-lateral border of tongue. ***
- B. Floor of the mouth.
- C. Buccal mucosa.
- D. Lip.
- E. Skin.

The posterior lateral and ventral surfaces of the tongue are the most common sites of intraoral cancer.

109- The majority of intraoral squamous cell carcinomas are histologically:

- A. Poorly differentiated.
- B. Well moderately differentiated. ***
- C. Spindle cell in type.
- D. Carcinoma in situation.

110- Squamous cell carcinoma is multifactorial:

- A. True. ***
- B. False.

111- Early squamous cell carcinoma of oral cavity present as:

- A. Vesicle.
- B. Sessile mass.
- C. An ulcer.
- D. Red plaque. ***
- E. A white cauliflower like lesion.

SCC:

Clinical appearance Most often seen as a painless ulcer, although may present as a swelling, an area of leukoplakia, erythroleukoplakia or erythroplakia (A reddened patch), or as malignant change of long-standing benign tumours or rarely in cyst linings. Pain is usually a late feature when the lesion becomes superinfected or during eating of spicy foods. Referred otalgia is a common manifestation of pain from oral cancer. The ulcer is described as firm with raised edges, with an indurated, inflamed, granular base and is fixed to surrounding tissues.

SCP "A white cauliflower like lesion: "

Squamous cell papillomas may present as exophytic pedunculated papules with a cauliflower-like appearance.

112- Firm, fixed neck nodes are most to be detected in association with:

- A. An Ameloblastoma
- B. A Basal cell carcinoma
- C. An Odontogenic fibroma
- D. A Squamous cell carcinoma. ***

113- Stage IB disease of squamous cell carcinoma:

- A. T1 NO MO.
- B. T3 NO MO.
- C. T2 NO MO. ***
- D. T4 NO MO.

114- Atropine :

- A. Dries secretion such saliva. ***
- B. Depresses the pulse rate.
- C. Cause central nervous system depression.

115- Drug used to increase saliva is:

- A. Anticholinergic.
- B. Cholinergic. ***
- C. Antidiabetic.
- D. Anticorticosteroid.

116- In order to decrease the gastric secretion:

- A. Histamine A antigen equivalent.
- B. Histamine B antigen equivalent.
- C. Anticholenergic. ***
- D. Adrenal steroids.

117- Drug used to decrease saliva during impression taking is:

- A. Cholinergic.
- B. **AntiCholinergic. *****
- C. Antidiabetic.
- D. Anticorticosteroid.

Atropine: It is classified as an anticholinergic drug. Injections of atropine are used in the treatment of bradycardia (an extremely low heart rate), asystole and pulseless electrical activity (PEA) in cardiac arrest. This works because the main action of the vagus nerve of the parasympathetic system on the heart is to decrease heart rate. Atropine blocks this action and, therefore, may speed up the heart rate. Atropine's actions on the parasympathetic nervous system inhibits salivary, sweat, and mucus glands. Atropine induces mydriasis by blocking contraction of the circular pupillary sphincter muscle, which is normally stimulated by acetylcholine release.

- Scopolamine, atropine and benztropine are anticholinergic drugs. They decrease - the flow of saliva. Cholinesterase inhibition is associated with a variety of acute symptoms such as nausea, vomiting, blurred vision, stomach cramps, and rapid heart rate.

118- Pt on long term antibiotic came with systemic Candida:

- A. Amphotrecin.
- B. **Fluconazol. *****
- C. Nystatin.

Fluconazole 50 mg od is the systemic drug of choice. C. Glabrata, C. Tropicalis, and C. Knusel are fluconazole resistant, therefore, candida subtyping should be performed for resistant cases.

119- Candida infection is a frequent cause of:

- A. **Burning mouth**

120- Lesion at junction between hard and soft palate and surrounded with pseudoepithelium A) hyperplasia in salivary gland.

- A. **Necrotizing Sialometaplasia. *****

121- Treacher collins syndrome characterized by:

- A. Prognathia of mandible.
- B. No ear loss.
- C. Upward slanting of eye.
- D. **Malar bone not well formed or absence. *****

122- Patient present with deficiency at the Malar Bone, Open Bite, Normal Mental Abilities;

- A. **Treacher collins. *****
- B. Cleidocranial dysplasia.
- C. Eagle syndrome.

123- Pt. Wears complete denture for 10 years & now he has cancer in the floor of the mouth. What is the first question that the dentist should ask:

- A. Does your denture is ill fitted.
- B. **Smoking. ***+ (80% of the cancer of the floor of the mouth is caused by smoking)**
- C. Alcohol.
- D. Does your denture impinge the o.mucosa. (traumatic cause)

124- Lesion at junction between hard and soft palate and surrounded with psudoepithelium hyperplasia in salivary gland :

A. Necrotizing sialometaplasia***

125- A female patient came to your clinic with dry lips and mouth and bilateral submandibular oedema and ocular dryness. Diagnosis is:

A. Polymorphecadenoma.

B. Sialotitis. *** OR Sjögren's syndrome if present.

126- The compression / relaxation cycle of external cardiac compression should be repeated:

A. 2 times / second.

B. 60 times / minute.

C. 76 times / second.

D. 100 times / minute. ***

Circulation Feel for a carotid pulse. If it is present, provide 10 breaths per minute, checking the pulse for 10 sec every 10 breaths. If no pulse commence chest compression, at the middle of the lower half of the sternum, depressing 4-5 cm 100 times per minute.

127- All these shows honey combed bone radiographically EXCEPT:

A. Ameloblastoma.

B. Odontogenic myxoma cyst.

C. Odontogenic keratocyst.

D. Adenomatous tumor. ***

Mucocoele

Infrequently, a mucocoele goes away without treatment. But if some mucocoeles remain untreated, they can scar over. Your dentist should examine any swelling in your mouth.

A mucocoele usually is removed by surgery. The dentist may use a scalpel or a laser to remove the mucocoele. Afterward, the tissue will be sent to a laboratory for evaluation. There is a chance that after the mucocoele is removed another one may develop.

Some doctors use corticosteroid injections before trying surgery. These sometimes bring down the swelling. If these work, you may not need surgery.

128- The way to remove mucocoele is:

A. Radiation.

B. Excision. ***

C. Chemotherapy.

D. Caterization.

129- Schick test an intradermal test for determination of susceptibility to:

A. Diphtheria hypersensitivity. ***

B. Tuberculosis hypersensitivity.

C. Lepson.

The Schick test, invented between 1910 and 1911[1] is a test used to determine whether or not a person is susceptible to diphtheria.[2] It was named after its inventor, Béla Schick (1877–1967), a Hungarian-born American pediatrician.

The test is a simple procedure. A small amount (0.1 ml) of diluted (1/50 MLD) diphtheria toxin is injected intradermally into the arm of the person. If a person does not have enough antibodies to fight it off, the skin around the injection will become red and swollen, indicating a positive result.

130- Parotitis with purulent exudate ,what you will do:

A. Immediate coverage with antibiotic 7 days.

B. Delay selection antibiotics until know culture result.

C. anti viral drug.

D. Give patient wide spectrum antibiotic until result of lab. Culture. ***

131- Young pt came without any complain. During routine X ray appear between the two lower molar lesion diameter about 2mm & extend laterally with irregular Shape. What's the type of cyst :

- A. Dentigerous cyst. ***
- B. Apical cyst.
- C. Radicular cyst.

132- Patient come to your clinic complaining that the denture become tight, during examination you notice nothing, but when the patient stand you notice that his legs bowing (curved). What you suspect:

- A. Paget's disease. ***
- B.x.
- C.x.

133- Cleidocranial dysostosis characteristic:

- A. Supernumerary of teeth.
- B. Clelival problems.
- C. Both of them. ***
- D. None of them.

134- Isolation period of chickenbox should be:

- A. After appear of rach by week.
- B. Untill vesicle become crusted. ***
- C. Until carter stage is last.

Its most contagious one day before the onset of rash and until all vesicle have crusted.

135- After u did upper & lower complete denture for old pt. He came back to the clinic next day complaining of un comfort with the denture. After u re check ,no pain, good occlusion, good pronunciations , but u notice beginning of inflammation in the gum and outer margins of the lips , u will think this is due to:

- A. Xerostomia. ***
- B. Vit-B deficiency.
- C. Sclero edema.

Xerostomia can cause difficulty in speech and eating. It also leads to halitosis and a dramatic rise in the number of cavities, as the protective effect of saliva's remineralizing the enamel is no longer present, and can make the mucosa and periodontal tissue of the mouth more vulnerable to infection.

136- Patient comes to your clinic with complete denture for Routine visit no complenining .During speech or swallowing or opening the mouth just glossitis Angular Cheilitis and discomfort increasing while day :

- A. Vitamin B deficiency. ***
- B. Xerostomia.
- C. sclero edema.

137- Patient with leukemia absolute neutrophilic count is 1700 what oral surgeon should do go on the manager:

- A. Postpone another day. ***
- B. Work with prophylactic antibiotic.
- C. Platelets transfusion.

138- Child came to your clinic have leukaemia number of neutrophils are (1400) want to extract his primary central incisor will you treat him:

- A. As usual pt-.
- B. Give prophylactic. (antibody).
- C. Give platelets before extraction-.

بالنسبة للسؤالين السابقين فإن المريض لديه لوكيميا شديدة طالما أن العدد أقل من ٢٠٠٠ حسب كلام اختصاصي تحاليل طبية فلا يجوز أن نقدم له أي عمل في العيادة.

D. Do not extract. * (Less than 2000 no dental Tx)**

139- Pt came to the clinic complaining from pain related to swelling on maxillary central incisor area with vital to under percussion ?

- A. Periapical cyst.
- B. Incisive cyst(nasopalatin cyst). *****
- C. Globulomaxillary cyst.
- D. Aneurysmal bone cyst.

140- Pt came to the clinic with a lesion confined to the middle of the hard palate, on the clinical examination the lesion is fluctuant & tender. On the X-ray radiolucent area btw the two central incisors roots. The diagnosis will be:

- A. Globulomaxillary cyst.
- B. Incisive canal cyst. *****
- C. Bohn's nodule.
- D. Aneurysmal bone cyst.

141- Trigeminal neuralgia treated by Carbamazepine, the max dose per day divided in doses is:

- A. 200 mg.
- B. 500 mg.
- C. 1000 mg.
- D. 1200 mg. *** (Daily dose from 600-1200 m)**

Usual Adult Dose for Trigeminal Neuralgia:

Initial dose: 100 mg orally twice a day (immediate or extended release) or 50 mg orally 4 times a day (suspension).

May increase by up to 200 mg/day using increments of 100 mg every 12 hours (immediate or extended release), or 50 mg four times a day. (suspension), only as needed to achieve freedom from pain. Do not exceed 1200 mg/ day.

Maintenance dose: 400 to 800 mg/day.

Some patients may be maintained on as little as 200 mg/day while others may require as much as 1200 mg/day.

At least once every 3 months throughout the treatment period, attempts should be made to reduce the dose to the minimum effective level or to discontinue the drug.

142- White lesion bilaterally on cheek,& other member in the family has it:

- A. Leukoplakia.
- B. White sponge nevus. *****
- C. Others.

White sponge nevus, presents as bilateral symmetric white, soft , “Spongy,” or velvety thick plaques of the buccal mucosa.

White sponge nevus, also known as Cannon's disease , Hereditary leukokeratosis of mucosa , and White sponge nevus of Cannon.

[1] Appears to follow a hereditary pattern as an autosomal dominant trait.

[2] Although it is congenital in most cases, it can occur in childhood or adolescence. It presents in the mouth, most frequently as a thick bilateral white plaque with a spongy texture, usually on the buccal mucosa, but sometimes on the labial mucosa, alveolar ridge or floor of the mouth.

143- Head and neck nevi with multi lesion is:

- A. Eagle syndrome.
- B. **Albright syndrome. *** (Albright syndrome)**

144- Dylantin (Phenytoin) don't give with :

- A. Aspirin.
- B. Azoles.
- C. **Metronidazole. *****
- D. All of the above.

145- Pregnant 25 years, bleeding on probing, location on papilla of anterior area of the maxilla, Isolated:

- A. Giant cell granuloma.
- B. **Pyogenic granuloma. (pregnancy epulis). *****
- C. Giant cell granuloma.

146- Endocrine and exocrine gland is :

- A. **Pancreas. *****
- B. Pituitary Gland.
- C. Thyroid G.
- D. Salivary G.
- E. Sweat G.

The pancreas is a gland organ in the digestive and endocrine system of vertebrates. It is both an endocrine gland producing several important hormones, including insulin, glucagon, and somatostatin, as well as an exocrine gland, secreting pancreatic juice containing digestive enzymes that pass to the small intestine. These enzymes help to further break down the carbohydrates, protein.

147 - Patient complaining from pain in the floor of the mouth (beneath the lower jaw) your diagnosis is related to the salivary glands, what's the best x-ray to help you:

- A. Panoramic.
- B. Occlusal.
- C. **Sialograph. *** (Specialized radiograph for the Salivary gland disorders)**

Because the salivary glands consist of soft tissue, they cannot be seen on radiographs unless special steps are taken to make them visible. In a technique called sialography.

148- The movement of polymorphic cells in the gaps of intracellular to the blood capillary Outside it called:

- A. Porosity.
- B. Slinking.
- C. **Diapedesis. *****

149- Child with cleft palate and cleft lip with anodontia due to:

- A. Van der woude syndrome. ***
- B. Treacher Collins syndrome.
- C. Paget disease.

Van Der Woude Syndrome (VDWS) is a genetic disorder. People with VDWS have cleft lip with or without cleft palate, isolated cleft palate, pits or mucous cysts on the lower lip, and hyperdontia. Affected individuals have normal intelligence.

150- Pt came 2 u with coloration bluish (or green??) and black in the gingival margins .he said that hi has gasteriointensinal problem. this is caused because of :

- A. Mercury.
- B. Lead.
- C. Bismuth. *** (Bismuth salts are used in the installation of anti-gastric ulcers and acidity.)
- D. Arsen.

151- Child patient presented with swelling in the buccal and palatal maxillary anterior area two days ago, the pathology of the lesion there is a giant cell, what is the diagnosis:

- A. Giant granuloma. ***
- B. Hemangioma.

Central Giant Cell Granuloma (CGCG) is a benign intraosseous lesion of the jaws that is found predominantly in children and young adults. Although benign, it may be locally aggressive, causing extensive bone destruction, tooth displacement and root resorption.

152- Child with anodontia and loss of body hair, the diagnosis is:

- A. Down's syndrome.
- B. Ectodermal dysplasia. ***
- C. Fructose
- D. Diabetic

153- Which of the following conditions is highly indicated for the short therapy of DOTS and is directly observed once in the clinic:

- A. Tuberculosis. ***
- B. HIV.
- C. H1N1.
- D. Mental Illness.

154- A question about Cleidocranial dysostosis characteristic:

#Partly or completely missing collarbones. If the collarbones are completely missing or reduced to small vestiges, this allows hyper-mobility of the shoulders including ability to touch the shoulders together in front of the chest.

A soft spot or larger soft area in the top of the head where the fontanelle failed to close.

Bones and joints are underdeveloped. People are shorter and their frames are smaller than their siblings who do not have the condition.

The permanent teeth include supernumerary teeth. Unless these supernumeraries are reabsorbed before adolescence, they will crowd the adult teeth in what already may be an underdeveloped jaw. In that case, the supernumeraries will probably need to be removed to provide space for the adult teeth.

Permanent teeth not erupting.

Bossing (bulging) of the forehead.

Hypertelorism.

155- Pt have lesion in tongue which suffering from scar fever > the lesion when remove leave the bleeding area under it ...diagnosis is:

- A. Leukoplaqua.
- B. **Candida. *****
- C. Ulcer.

156- Child patient with painful herpes simplex the treatment is acyclovir with :

- A. Vitamin C.
- B. **Local anesthesia with multi-Vitamin. *****
- C. Local anesthesia with protein.

157- Child 10 years old came to the clinic with periodontitis associated with the 1ry & 2ry dentition with sever generalized bone destruction and calcification on the general examination hyperkeratosis of hands & feet is noticed the diagnosis is:

- A. Hypophosphotasia.
- B. Pre_puberty periodontitis.
- C. **Papillon lefevre syndrome. *****
- D. Juvenile periodontitis.

158- Pt. with palm oplanter keratosis and periodontitis in permanent dentition is likely to has:

- A. **Papillon –lefevere syndrome. *****
- B. "Down" syndrome.
- C. Leukemia.
- D. Hypophosphatesia.

159- Diabetic pt with multiple naevi on the neck and the scalp , and multiple jaw cyst , your diagnosis will be:

- A. Eagle syndrome.
- B. **Gorlin – Goltz syndrome*****
- C. Pierre Robin syndrome.
- D. None of the above.

160- Maternal immunity that passed from mother to the fetus through the placenta, IgG, IgA is considered:

- A. **Natural passive immunity.*****
- B. Natural active immunity.
- C. Acquired passive immunity.
- D. Acquired active immunity.

161- Pt came 2 your clinic complain from his gingiva which bleeds allot with any little pressure, on clinical examination u found pin point purple dots and general rash like of eccymosis on his body laboratory finding : highly decrease in platelets (slightly more than 25000) have a history of eccymosis and brushing all over his body:

- A. **Thrombocytopenic purpura. *****

حسب كلام دكتور تحاليل طبية ، إذا كان عدد الصفيحات أكثر من ٢٥٠٠٠ يكون النزف شديد لأقل رضى أو خدش ، أما إذا كان العدد أقل من ذلك فيكون النزف بشكل تلقائي ..

162- Radiolucent structure occupied by a radio-opaque structure that forms a mass of disorganized arrangement of odontogenic tissue:

- A. **Complex odontoma. *****
- B. Calcifying Epithelial Odontogenic Cyst.
- C. Compound odontoma.

163- Is a white lesion :

- A. **Lichen planus. *****
- B. Cancer.
- C. Hematoma.
- D. None.

162- Fordyce's spots is on :

- A. Tongue.
- B. Oral mucosa.
- C. **Upper lip. *****
- D. Throat.

163- Is an anticoagulant agent:

- A. Aspirin.
- B. **Heparin. *****
- C. Paracetamol.
- D. Evex.

Heparin given every six hours and working on PTT.

164- Duct of submandibular gland is :

- A. **Warton. *****
- B. Bartholin.
- C. Barvenous.
- D. Stenson.

165- leukoplakia is present on :

- A. **The mouth. *****
- B. Eye.
- C. Heart.
- D. Lungs.

166- Cranial nerves are

- A. **12 nerves. *****
- B. 14 nerves.
- C. 10 nerves.
- D. 16 nerves.

167- Deficiency of vitamin C , leads to :

- A. **Scurvy. *****
- B. Anemia.
- C. Ricket.
- D. Defect in blood clotting.

168- Deficiency of vitamin K , leads to :

- A. Scurvy.
- B. Anemia.
- C. Ricket.
- D. Defect in blood clotting. ***

169- Deficiency of vitamin D , leads to :

- A. Scurvy.
- B. Anemia.
- C. Ricket. ***
- D. Defect in blood clotting

170- Child 8 years old hearing loss , flush around his mouth and notches in incisors and bulbous molars .what is your diagnosis ??

- A. Gardner syndrome.
- B. Congenital syphilis. ***

171- Nicotinic stomatitis:

- A. A canthosis with keratin. ***
- B. Brickle cell like shape bases.

172- pt came with prominence in the forehead and the potassium sulfate level increased with curved legs enlarged mandible and maxilla:

- A. Paget disease. ***

173- Patient came to dentist after previous stressful procedure complaining of burning & discomfort of his lip on examination u found lesions on the palate, diagnosis is:

- A. Contact dermatitis.
- B. Allergy.
- C. Aphthous ulcer.
- D. Herpes simplex. (Herpetic Gingivostomatitis) ***

174- Mandible with lucent areas in sclerotic masses. Which is the diagnosis?

- A. Acute osteomyelitis.
- B. Diffuse sclerosing osteomyelitis. ***
- C. Garre osteomyelitis.
- D. Focal sclerosing osteomyelitis.
- E. Cherubis.

175- Which is a cause of lip and neck swelling following ingestion of drugs, shellfish, or nuts?

- A. Anaphylaxis
- B. Urticaria
- C. Fixed drug reaction
- D. Acquired angioedema. ***
- E. Contact allergy

Pharmacology 25 MCQs

1. Which of the following may cause gingival enlargement:

- A. Phenyntoin (Dilantin). *** (50-60%)
- B. Cyclosporine. (20-30%).
- C. Nifedipine (A Calcium Channel Blocker) 6-20%
- D. Aspirin.
- E. All of the above. ***
- F. None of the above.

The highest incidence of drug induced hyperplasia is reported to phenytoin (Dilantin)

2. Dylantin (phynotoin) don't give with :

- A. Azoles.
- B. Metronidazole. ***
- C. All of the above.

3. Which of the following drugs is completely effective in eliminating angina episode:

- A. Propranolol.
- B. Nifedipine.
- C. Diltiazem.
- D. Transdermal nitroglycerin. ***
- E. None of the above.

4. The antibiotic of choice in pregnant:

- A. Metronidazole.
- B. Penicillin. ***
- C. Tetracycline.

5. Chlorhexidine is used as mouth wash in the concentration of:

- A. 0.1-0.2%. ***
- B. 1-2%.
- C. 5-10%.
- D. 20%.

6. A plastic anemia is caused by:

- A. Tetracycline.
- B. Penicillin.
- C. Erythromycin.
- D. Sulfonamide. ***

A Plastic Anemia:

Roughly half of all aplastic anemias occur as a result of drugs (such antibiotics as chloramphenicol, **sulfonamides**, phenylbutazone [Butazolidin] , and such anticonvulsant agents as mephenytoin)

Also: chloramphenicol, phenylbutazone [Butazolidin], and such anticonvulsant agents as mephenytoin.

7. (30 years) old pt came to the clinic with brownish discoloration of all his teeth (intrinsic discoloration) & yellowish in U/V light the most likely cause is:

- A. Fluorosis.
- B. Tetracycline. ***
- C. Amelogenesis imperfect.
- D. Dentogenesis imperfecta .

8. Treatment of fungal infections:

- A. Penicillin
- B. Tetracyclin
- C. Nystatin. ***

9. When do we give antibiotic:

- A. Widespread , rapid infection.
- B. Compromised host defense.
- C. X.
- D. A & B.

10. Antibiotics are most used in cases of:

- A. Acute Localized lesion.
- B. Diffuse , Highly progressing lesion. ***

11. Prophylactic antibiotic needed in:

- A. Anesthesia not interaligamentary.
- B. Suture removal.
- C. Routine tooth brushing.
- D. Orthodontic band. ***

12. Calcium channel blockers cause increase saliva secretion:

- A. True.
- B. False. ***

13. Atropine :

- A. Dries secretion such saliva. ***
- B. Depresses the pulse rate.
- C. Cause central nervous system depression.

14. Drug used to decrease saliva during impression taking is:

- A. Cholinergic.
- B. AntiCholinergic. ***
- C. Antidiabetic.
- D. Anticorticosteroid.

15. In order to decrease the gastric secretion:

- A. Histamine A antigen equivalent.
- B. Histamine B antigen equivalent.
- C. Anticholenergic. ***
- D. Adrenal steroids.

16. Drug used to increase saliva is:

- A. Anticholinergic.
- B. Cholinergic. ***
- C. Antidiabetic.
- D. Anticorticosteroid.

17. Pt with complete denture come to your clinic, complaint from his dry mouth, the proper medicine is:

- A. Anti diabetic medicine.
- B. Anticordial. ***
- C. Steroid.

Atropine: It is classified as an ant-cholinergic drug. Injections of atropine are used in the treatment of Bradycardia (an extremely low heart rate), asystole and pulseless electrical activity (PEA) in cardiac arrest. This works because the main action of the vagus nerve of the parasympathetic system on the heart is to decrease heart rate. **Atropine** blocks this action and, therefore, may speed up the heart rate. **Atropine's** actions on the parasympathetic nervous system **inhibits salivary**, sweat, and mucus glands. **Atropine** induces mydriasis by blocking contraction of the circular papillary sphincter muscle, which is normally stimulated by acetylcholine release. **Scopolamine, atropine and benztropine** are anticholinergic drugs. They decrease the flow of and salivary. Cholinesterase inhibition is associated with a variety of acute symptoms such as nausea, vomiting, blurred vision, stomach cramps, and rapid heart rate.

Note: Cholinergic > Increases saliva and gastric secretion and decreases the pulse.

Ant-cholinergic > Decrease saliva flow and mydriasis, increase pulse and decrease gastric secretion.

18. Pt on long term antibiotic came with systemic Candida:

- A. Amphotrecin.
- B. Fluconazol. ***
- C. Nystatin.

Fluconazole 50 mg od is the systemic drug of choice. C. Glabrata, C. Tropicalis, and C. Knusel are fluconazole resistant, therefore, candida subtyping should be performed for resistant cases.

19. Trigeminal neuralgia treated by carbamazepine, the max dose per day divided in doses is:

- 200 mg.
- 500 mg.
- 1000 mg.
- 1200 mg. *** (Daily dose 600 – 1200 mg)

Usual Adult Dose for Trigeminal Neuralgia :

Initial dose: 100 mg orally twice a day (immediate or extended release) or 50 mg orally 4 times a day (suspension). May increase by up to 200 mg/day using increments of 100 mg every 12 hours (immediate or extended release), or 50 mg four times a day. (suspension), only as needed to achieve freedom from pain. **Do not exceed 1200 mg/ day.**
Maintenance dose: 400 to 800 mg/day. Some patients may be maintained on as little as 200 mg/day while others may require as much as 1200 mg/day. At least once every 3 months throughout the treatment period, attempts should be made to reduce the dose to the minimum effective level or to discontinue the drug.

20.(10 years) child with congenital heart disease came for extraction of his lower 1st molar, the antibiotic for choice for prevention of infective endocarditis is:

- A. Ampicelline 30 mg /kg orally 1hour before procedure.
- B. Cephalixine 50mg/kg orally 1hour before procedure.
- C. Clindamicine 20mg/kg orally 1hour before procedure .
- D. Amoxicillin 50mg/kg orally 1hour before procedure. ***

Amoxicillin, 2.0 gm orally 1 hr before procedure"

21. Candida infection is a frequent cause of:

- A. Burning mouth. ***

22. Patient had anaphylactic shock due to penicillin injection , what's the most important in the emergency treatment to do:

- A. 200 mg hydrocortisone intravenous.
- B. 0.5 mg epinephrine of 1/10000 intra venous. *** <The only IV in the choices>

Management

- Place patient supine with legs raised, if possible.
- 0.5 ml of 1:1000 adrenaline IM or SC. Repeat after 15 min, then every 15 min until improved. Do not give IV in this concentration as it will induce ventricular fibrillation.
- Up to 500 mg of hydrocortisone IV.
- Up to 20 mg of chlorpheniramine slowly IV (if available).
- O2 by mask.

23. Inhalation anesthesia:

- A. Nitrous oxide.
- B. Ethanol.
- C. Halothane.
- D. All of the above. ***

24. Pre-anesthetic medication are all except:

- A. Benzodiazepine.
- B. Opioids (Fentanyl)
- C. Thiopental. ***
- D. Antcholinergic.

25. Benzodiazepines:

- A. The most widely used anxiolytic drugs.
- B. They have largely replaced barbiturates in the treatment of anxiety.
- C. Are safe and more effective.
- D. All of the above. ***

Prosthodontics – Fixed 120 MCQs

1. The most frequent cause of failure of a cast crown restoration is:

- A. Failure to extend the crown preparation adequately into the gingival sulcus.
- B. Lack of attention in carving occlusal anatomy of the tooth.
- C. Lack of attention to tooth shape, position, and contacts ***.
- D. Lack of prominent cusps, deep sulcus, and marginal ridges.

2. Saline coupling agent:

- A. Used with porcelain to enhance wettability of bonding. ***
- B. Used with tooth and porcelain.
- C. Remove inlay and clean with alcohol. For porcelain only, place layer of silane coupling agent on fitting surface.

3. Polyether impression materials:

- A. Are less stable dimensionally than poly sulfide rubber.
- B. Are less stiff than poly sulfide rubber.
- C. Can absorb water and swell if stored in water. ***

4. An anterior fixed partial denture is contraindicated when:

- A. Abutment teeth are not carious.
- B. An abutment tooth is inclined 15 degrees but otherwise sound.
- C. There is considerable resorption of the residual ridges. ***
- D. Crown of the abutment teeth are extremely long owing to gingival recession.

5. During 3/4 crown preparation on premolar, bur used to add retentive grooves is:

- A. Radial fissure.
- B. Tapered fissure. ***

6. During post insertion examination of a 3 unit ceramometal fixed partial denture. One of the retainers showed chipping of porcelain at the ceramometal junction. In order to avoid the problem the dentist must:

- A. Reduce the metal to 0.3 mm.
- B. Have uniform porcelain thickness.
- C. Have occlusion on metal.
- D. Keep porcelain metal junction away from centric contacts. ***

7. What is a Pier abutment?

- A. Single tooth holding one pontic.
- B. A tooth that supports a removable partial denture.
- C. All of the above.
- D. None of the above. ***

8. Which are the ways in which the proximal contacts can be checked?

- A. Use a pencil.
- B. Use a shim stock.
- C. Use a silicone checker.
- D. Use a dental floss.
- E. Only b & d. ***

A total of 969 proximal contacts in forty volunteer subjects was examined for proximal contact integrity with shim stock. It passed uninhibited through 88% of the contacts. Neither sex nor age affected the evaluation; however, shim stock was more likely to pass through contacts with enamel surfaces than those which were restored.

9. The incisal reduction for a metal ceramic restoration should be:

- A. 1.5 mm.
- B. 2 mm. ***
- C. 3 mm.
- D. 4 mm.

10. The occlusal reduction for an all metal veneer crown should:

- A. Be as flat as possible to enable an easy fabrication of occlusion anatomy.
- B. Follow the occlusal morphology with a clearance rating from 1 to 1.5 mm with the opposing dentition. ***
- C. Follow the occlusal morphology with a clearance of no more than 0.5 mm with the opposing dentition.
- D. Be the last step in the tooth preparation.

11. Gingival retraction is done:

- A. To temporarily expose the finish margin of a preparation.
- B. To accurately record the finish margin of a portion of uncut tooth surface apical to the margin in the final impression.
- C. Even in the presence of a gingival inflammation.
- D. By various methods but the most common one is the use of retraction cord.
- E. A and B.
- F. A , B and C.
- G. A , B and D. ***

12. Regarding tissue retraction around tooth:

- A. Short duration of retraction of gingival margin during preparation of finishing line.
- B. Retraction of gingival margin during taking final impression to take all details of unprepared finish line.
- C. Usually retracted severely inflamed gingival margin.
- D. Retraction of gingival margin can be done by many ways one of them is retraction cord.
- E. A, b and C.
- F. B, c and D.
- G. A and D. ***

13. The most accurate impression material for making the impression of an onlays cavity:

- A. Impression compound.
- B. Condensation type silicone.
- C. Polyvinyl Siloxane ***
- D. Polysulfide.

14. Missing lower Six and tilted Seven :

- A. Uprighting of molar by orthodontics.
- B. Proximal half crown.
- C. Telescope crown.
- D. Non rigid connector. ***

None rigid connector: it is indicated when retainers cannot be prepared without excessive tooth reduction.

15. Post fracture decrease with:

- A. Prefabricated post.
- B. Ready made post.
- C. Casted post. ***
- D. Metal post.

16. Teeth with RCT and you want to use post, which post is the least cause to fracture:

- A. Ready made post.
- B. Casted post.
- C. Fiber post. ***
- D. Prefabricated post.

17. During post removal the first thing to do is:

- A. Remove the G.P.
- B. Remove all the old restoration & undermined enamel & caries. ***
- C. Insertion of post immediately

18. Post length increasing will :

- A. Increase retention. ***
- B. Increase resistant.
- C. Increase strength of restoration.

19. For post preparation we should leavemm of GP:

- A. ????
- B. 10mm
- C. 5mm. ***

20. In post and core preparation must:

- A. Extend to contra bevel.
- B. Extend to full length tooth preparation.
- C. Take same shape of natural tooth.
- D. Take shape of preparation abutment.
- E. A & D. ***
- F. A & B.

21. After RCT, for insertion of post dowel:

- A. Post applied pressure.
- B. Post should be loose.
- C. Insert it without pressure but with retention. ***

22. The best restoration for max central incisor that has received RCT through conservatively prepared access opening would be:

- A. Post-retained metal-ceramic crown.
- B. Post-retained porcelain jacket crown.
- C. Composite resin. ***
- D. None of the above.

23. One of anatomical land mark is:

- A. Ala tragus line. ***
- B. Ala orbital.
- C. Frank fort plane.

24. For onlays preparation, reduction of functioning cusp should be:

- A. 1.5 mm. ***
- B. 2 mm.
- C. 1 mm.

25. Thickness of porcelain should be:

- A. 0.3-0.5 mm.
- B. 0.05-0.15 mm.
- C. 0.5-1.5 mm. ***

The necessary thickness of the metal substructure is 0.5 mm the minimal porcelain thickness is 1.0 - 1.5 mm.

26. Occlusal plane is:

- A. Above the level of the tongue.
- B. Below the level of the tongue. ***
- C. The tongue rests on the occlusal surface.

27. Amount of reduction in PFM crown:

- A. 1.5 - 2. ***
- B. 1.7 - 2.
- C. 2 - 5.

28. To enhance strength properties of ceramo metal restoration, it is important to:

- A. Avoid sharp or acute angles in the metal structure.
- B. Build up thick layer of porcelain.
- C. Porcelain should be of uniform thickness and any defect of the preparation should be compensated by the metal substructure.
- D. Compensate any defect in the preparation equally by porcelain and metal substructure.
- E. A and B are correct.
- F. A and C are correct. ***
- G. B and D are correct.

Sharp angles and under cuts should be avoided. Thin porcelain with uniform thickness supported by rigid thickness is the strongest. Porcelain should be kept at a minimum thickness that is still compatible with good esthetic deficiencies of the tooth preparation. Should be compensated by with extra thickness of the coping in those areas.

29. Endodontically treated 2nd maxillary premolar with moderate M & D caries is best restored by:

- A. Amalgam.
- B. 3/4 crown.
- C. Full crown. ***
- D. Onlay.

30. Artificial teeth best to be selected by:

- A. Preextraction cord. ***
- B. Postextraction cord.

31. In full gold crown, to prevent future gingival recession:

- A. Make the tooth form good at gingival one third. ***
- B. Make the tooth form good at gingival one fifth.
- C. Make the tooth form good at gingival one half.

32. Fixed partial prosthesis is more successful in:

- A. Single tooth missing. ***
- B. Multiple missing teeth.

33. Best pontic is:

- A. Ridge lap.
- B. Hygiene. ***
- C. Saddle.

34. White polycarbonate are temporary crowns used for anterior teeth:

- A. True. ***
- B. False.

35. Bridge return to dentist from lab with different degree of color although the shade is the same, the cause:

- A. Thin metal framework.
- B. Different thickness of porcelain. ***
- C. Thick opaque.

36. Pt with missing lower right 1st molar for long time you'll find:

- A. Mesial drifting of lower right 2nd molar. ***
- B. Intrusion of upper right 1st molar.
- C. Over eruption of lower right 2nd molar.

37. Over erupted upper right 1st molar will be managed by: EXCEPT:

- A. Intruded easily Orthodontically. ***
- B. Crowing.
- C. Adjustment of occlusion.

38. Over erupted upper right 1st molar will be managed by:

- A. Intruded easily Orthodontically.
- B. Crowning.
- C. Adjustment of occlusion.
- D. In severe cases may be extracted.
- E. A , B , C.
- F. **B , C , D. *****
- G. A , B , D.
- H. A , C , D.

39. Over erupting tooth can be treated by:

- A. Crowning after Endo.
- B. Ortho intrusion.
- C. Extraction.
- D. **A and B. *****
- E. All the above.

40. The amount of facial redaction in PFM crown:

- A. **1.3. *****
- B. 1.7.
- C. 0.8.
- D. 2.2.

41. A tooth with 25 degree inclination could be used as abutment:

- A. **True. *****
- B. False.

42. In onlays , stopping of cusp is 1.5 - 2 mm:

- A. **True. *****
- B. False.

43. The first step in diagnostic work, up is obtaining the:

- A. Medical history.
- B. **Present complaint. *****
- C. Biographical data.
- D. Restorative history.
- E. Traumatic history.

44. For the ceramometal restorations, the type of finish line is:

- A. Chamfer.
- B. **Beveled shoulder *****

Beveled shoulder: According to the results of this study as the shoulder bevel had better fit than shoulder and deep chamfer designs and also there was significant difference between shoulder bevel and shoulder, so it is recommended to use shoulder bevel finish line in the metal ceramic restoration.

45. Benefits of opaque porcelain layer:

- A. Bonding the metal structure.
- B. Initiating the color.
- C. A & B. ***

46. Porcelain shrinkage after firing:

- A. 1-5%
- B. 5-10%
- C. 10-20% ***

At a firing temperature of 1400° C, they shrink by 16 percent.

47. Is this statement true or false:

- A. RCT abutment of FPD has higher risk for fracture.
- B. Abutment which has RCT in cantilever FPD have higher susceptibility to fracture.
- C. 1st is true , 2nd is false.
- D. 1st is false , 2nd is true.
- E. Both are false.
- F. Both are true. ***

Cements for luting have desired film thickness of 15: 25 microns. Cavity Liners (either solution or suspension liners) have a desired film thickness of 5 microns. Bases have a final application thickness of 1-2 mm (they may be thicker depending on the amount of dentin that may be destroyed). The maximum allowable thickness is 25 µm (ADA specification No. 96)

48. Thickness of luting cement:

- A. 100 micrometer.
- B. 40 micro meter.
- C. 1mm.

49. Pontic design of an FPD:

- A. Same size buccolingual of the missing tooth.
- B. Smaller than missing buccolingual. ***
- C. Wider buccolingual.
- D. None of the above .

Dental Cements: The low 12-micron film thickness is ideally suited for luting applications.

50. Which material has best biocompatibility Intraorally:

- A. Cobalt chromium.
- B. Titanium. ***
- C. Nickel chromium.
- D. Gold Palladium.

51. Which of following Resto more likely to cause wear to opposing:

- A. Composite.
- B. Gold.
- C. Porcelain. ***
- D. Amalgam.

52. Minimum thickness of noble metal crown:

- A. 1 mm.
- B. 0.5 mm ***
- C. 1 mm.
- D. 2 mm.

The necessary thickness of the metal substructure is 0.5 mm the minimal porcelain thickness is 1.0 - 1.5 mm.

53. Patient is diagnosed for ceramometal full veneer. You plan to use Epoxy resin > missing text > what's the best impression material to be used :

- A. Poly ether.
- B. Poly sulfide.**
- C. Agar gar.
- D. Irreversible hydrocolloid.

54. The impression material of choice when we want to take impression for epoxy resin pin is:

- A. Polysulfide. *****
- B. Polyether.
- C. Agar agar.
- D. Irreversible hydrocolloid.

55. Impression material cause bad taste to patient :

- A. Poly sulfide. *****
- B. Polyether.
- C. Additional silicon.
- D. Alginate.

56. What is the most unfavorable imp, material by the patient due to bad taste :

- A. Agar
- B. Silicone
- C. Polyether
- D. Polysulfide. *****

57. The impression used for preliminary impressions or study casts is:

- A. Agar agar.
- B. Silicon.
- C. Alginate. *****
- D. None.

58. What is the least accurate imp material:

- A. Alginate. *****
- B. Polysulfide.
- C. Polyether.

59. Minimal facial reduction when preparing for veneers:

- A. 0.3 mm.
- B. 0.3 - 0.5 mm. *****
- C. 1 - 1.5 mm.

The facial enamel is usually reduced by 0.3 – 0.5mm, but where the underlying tooth is severely discolored, reduction should be 0.7mm.

60. The best material for taking impression for full veneer crowns:

A. Poly vinyl Sialoxane (Additional Silicone). ***

61. Stock trays compared to Custom trays for a removable partial denture impression :

A. Custom trays less effective than stock trays.

B. Custom trays can record an alginate impression as well as elastomeric impression.

C. Custom trays provide even thickness of impression material. ***

D. All of the above.

62. Provisional restoration for metal ceramic abutment is :

A. Aluminum sheet.

B. Stainless steel crown.

C. ZNO.

D. Tooth colored polycarbonate crown. ***

63. In fixed P.D u use GIC for cementation what best to do :

A. Remove smear layer by acid to increase adhesion.

B. Do not varnish because it affect adhesion. ***

C. Mixed slowly on small area until become creamy.

D. Remove excess when it in dough stage.

For glass ionomer cement, the measured powder is divided into two equal parts and mixed with a plastic spatula. The first increment is rapidly incorporated in 10 seconds, and the second increment is incorporated and mixed for an additional 10 seconds.

Avoid using cavity cleaners to aid in drying the preparation because they may adversely affect pulpal health.

Remove excess cement with an explorer. Early cement removal may lead to early moisture exposure at the margins with increased solubility.

64. Instrument which we use to make groove in the wax is :

A. Curver. ***

65. Instrument used for wax grooving for a die in FPD:

A. NKT no ...

B. NKT no

C. Spoon excavator. ***

D. Burnisher.

66. Cast with (+ve) bubble b/c of:

A. Mixing stone.

B. Voids in impression when taken by the dentist. ***

C. Pouring.

D. Using warm water when mixing stone.

67. On a central incisor receiving a full ceramic restoration, during finishing of the :

- A. Shoulder finish line subgingivally.
- B. Diamond end cutting. ***

68. After final inlay cementation and before complete setting of cement we should:

- A. Remove occlusal interferences.
- B. Burnishing of peripheries of restoration for more adaptation. ***
- C. Lowering occlusal surface.

It is easier to remove excess cement before it finally sets. Once the cement is hard the rubber dam is removed and the occlusion checked with articulating paper and adjusted with fine diamond burs.

69. Female come need to endodontic for central insical ,and have media composite restorations in the mesial and distal walls ,and have attrition in the insicial, edge the best restoration?

- A. Jacket crown.
- B. Full crown. ***
- C. Metal crown.

70. Child have dental caries in 3 or 4 surfaces of his first primary molar we will replace them with:

- A. Preformed metal crown. ***
- B. Porcaline crown.
- C. Amulgam crown.
- D. Composite restoration.

71. What name of bur used in proximal surface of laminate veneer ??

- A. Radial .
- B. Dimound. ***
- C. Fissure.

The facial depth cuts are removed with the 850-014 diamond bur, and the long axis of the diamond bur is “rolled” into the proximal chamfer area to eliminate any sharp line angles.

72. What name of bur use in facial surface of veneer ??

- A. Dimond. ***
- B. FFissure.

Round-end diamonds create chamfer margin and facial reduction for direct and indirect veneer restorations.

73. What type pontic design would you in a patient with a high esthetic demand when preparing teeth number 9 – 11 for a F P D :

- A. Ridge lap or saddle pontic.
- B. An ovate pontic.
- C. Modified ridge lap pontic. ***

74. Design of anterior pontic :

- A. Modified ridge lab. ***
- B. Saddle.
- C. Hygienic.

75. Porcelain, highly esthetic, anterior maxilla area, we choose:

- A. Dicor.
- B. In ceram. ***
- C. Impress.

In-Ceram has been used to fabricate fixed partial dentures, but the manufacturer recommends only short-span (three-unit) anterior restorations. Alumina-reinforced ceramic systems (In-Ceram) significantly improve the light reflection characteristics of crowns when compared to conventional metal-ceramic restorations. However, opaque aluminum oxide diminishes translucency when compared to leucite-reinforced systems (Optec, IPS-Empress). To improve light transmission and reflection in single anterior crowns where maximum strength is not required, a magnesium aluminous spinel may be utilized. The transilluminating qualities seem to be similar to those of natural teeth.

76. The highest strength in porcelain:

- A. ZR (zircon) reinforced in ceram. ***

77. (32 years old) patient came to your dental office, suffering from a bad odour and taste from His mouth. By examination patient has an anterior mandibular 3 unit bridge that bubbles upon Applying water spray and slight pressure. Cause:

Broken abutment.

Food impaction underneath the pontic.

Separation between the abutment and the retainer. *** (Dissolving of cement/Microleakage)

78. Which tooth require special attention when preparing the occlusal aspect for restoration:

- A. Lower 2ed molar.
- B. Lower 1st premolar. ***
- C. Lower 2ed premolar.
- D. Upper 1st molar.

79. The kind of onlays wax used in cast :

- A. Paraffin wax. ***
- B. Baseplate wax.
- C. Carving wax.

80. Wax inlay which type contain in much gradient:

- A. Paraffin wax. ***
- B. Bee wax.

81. Incisal abrasion. Porcelain veneer is planned with modification to cover incisal edge veneer should end:

- A. Fourth lingually 0.5 mm before centric occlusal. ***
- B. Fourth 1.5 before centric occlusion.
- C. Fifth 1.5 before centric occlusion.

82. The cause of black cast which prevent pickling due to :

- A. Over heat. ***
- B. Contaminate with gas.
- C. Incomplete casting.

Dark discolored casting due to :

Over heating of the investment lead to decomposition of calcium sulphate hemihydrates binder and release of sulphur which will combine with copper and silver of gold alloy lead to compounds **which resist pickling of casting.**

83. What is the main function of impression tray holes:

- A. Fixing the Impression material. ***

84. The best material for taking full crown veneers impression is :

- A. Poly-sulphide.
- B. Poly-ether.
- C. Irreversible hydrocolloid.
- D. Poly vinyl siloxane (Additional silicone). ***

85. Preparation of tooth for metal ceramic restoration should be done in:

- A. Two planes. ***
- B. Parallel to long axis.

86. Labial reduction for porcelain metal restoration must be:

- A. (1 Plane) for aesthetic.
- B. (2 Plane) by follow the morphology. ***

87. Preparation for labial surface in one plane in the preparation for metal crown is:

- A. More retentive.
- B. Less retentive. ***

88. Patient need fixed bridge after you check in mouth of the patient see change color of bridge to cloudy to milky what causes?

- A. Excessive fired. ***
- B. Reduced fired.
- C. Excessive moisture.
- D. Increased porosity.

When porcelain is fired too many times it may devitrify this appears as a milky state and make glazing very difficult.

89. The Ideal crown-to- root ratio of a tooth be utilized as a bridge abutment is:

- A. 3:1.
- B. 2:1.
- C. 1:2. ***
- D. 1:1.

90. Provide retention for a crown :

- A. Enhance the strength of the tooth.
- B. Provide retention for a core. ***
- C. Provide the root canal sealing.

91. Patient come with sever stained anterior central left maxillary incisor with small distal caries & lost incisal edge treated by :

A. Full ceramic restoration. ***

92. The ideal post drill for most posterior teeth is :

A. Gates Glidden size 3.

B. Pesso-remar drill size 3-6.

C. Profile size 60-70.

D. Pesso-remar drill size 2-3. ***

93. The function of post :

A. Provide retention for a crown.

B. Enhance the strength of the tooth.

C. Provide retention for a core. ***

D. Provide the root canal sealing.

94. Die ditching means :

A. Carving apical to finish line. ***

B. Carving coronal to finish line.

C. Mark finish line with pen.

95. Most common cause of chipped porcelain in PEM:

A. Thin layer of metal.

B. Thin layer of porcelain.

C. Centric occlusal contact at the junction of porcelain and metal. ***

96. The forces action through a FPD on to the abutment tooth should be directed :

1. As far as possible at right angles to the long axes of the teeth.

2. Parallel to the long axes of the teeth.

3. By decreasing the facio-lingual dimension of the pontic

4. By decreasing the Mesio-lingual dimension of the pontic.

5. In a mesial direction , teeth nearer the midline will offer additional support.

A. 1+3+4.

B. 1+2+5.

C. 1+4+5.

D. 2+3. ***

E. 2+4.

F. 2+5.

97. Which not compatible to the pulp :

A. GIC.

B. Zinc phosphate cement. ***

C. Zinc polycarboxylate cement.

98. The working time of zinc phosphate cement is shortened By:

- A. Concentrating the acid.
- B. Warming of glass slab. ***
- C. Incremental mixing of powder.
- D. All of the above.

99. You sent shade of PFM , technician give you different color with same shade :

- A. Non uniform porcelain. ***
- B. Thick opaque.
- C. Thin opaque.

100. Most abrasive contact :

- A. Tooth to tooth.
- B. Porcelain to tooth. ***
- C. Gold to tooth.

101. Length of post :

- A. (1/2) root.
- B. (2/3) root.
- C. (1/2) root containing in bone.
- D. As much longer and leave (4 mm) apical seal. ***

102. Concentrating of acid used in etching porcelain veneer :

- A. 9.6 % hydrofluoric acid. ***
- B. 35%phosphoric acid.
- C. 37%phosphoric acid.
- D. 37%hydrflouric acid.

103. Placement of maxillary anterior teeth in complete dentures too far superiorly and anteriorly might result in difficulty in pronouncing :

- A. F and V sounds.***
- B. D and T sounds.
- C. S and TH sounds.
- D. Most vowels.

104. An advantage of rubber-base impression material over reversible hydrocolloid material is that rubber base impression material:

- A. Will displace soft tissue.
- B. Requires less armamentarium.
- C. Is significantly more accurate. ***
- D. Is more accurate if saliva, mucous or blood is present.

105. Best provisional coverage for anterior teeth is:

- A. Tooth colored polycarbonate crown. ***
- B. Stainless steel crown
- C. Zinc oxide eugenol.

106. Diagnostic cast wax up help in:

- A. Predict the result of treatment.
- B. Explain the treatment plan to patient.
- C. All of the above. ***

107. A low sag factor in a metal-ceramic FPD and cause :

- 1. Flow of metal under functional load.
 - 2. High abrasion resistance.
 - 3. Less deformation of bridge spans when fired.
 - 4. Poor metal-ceramic bond strength.
 - 5. Contamination of porcelain.
- A. 1 only.
 - B. 1 and 4.
 - C. 2 and 3.
 - D. 3 only. ***
 - E. 4 and 5.
 - F. All of the above.

108. In mean of compressive strength ,tensile strength which is strongest:

- A. Resin cement. ***
- B. Zinc phosphate.
- C. G.I.

109. Shoulder is the finish line of choice for:

- A. Full veneer.
- B. PFM. **
- C. (¾) Crown.

110. Which of the following characteristics of inlay wax is its major disadvantage:

- A. Flow.
- B. Rigidity.
- C. Hardness.
- D. High thermal expansion. ***

111. As the gold content of a dental solder decreases ,the :

- A. Hardness decreases.
- B. Utility increases
- C. Corrosion resistance decreases.
- D. Ultimate tensile strength decreases***

112. The most ductile and malleable metal is:

- A. Silver.
- B. Gold.***
- C. Copper.
- D. Platinum.

113. What the name of the depressions present on molars in the middle and between the cusps:

A. Developmental grooves. ***

114. Patient had enamel and dentin hypoplasia your ttt:

A. Porcelain crowns. ***

B. Splinting with composite.

C. Composite bridge.

115. Indication of shoulder :

A. Facial margin of metal ceramic crown.

B. Complete ceramic crown. ***

116. Minimal facial reduction when preparing for veneers:

A. (0.1) mm.

B. (0.3-0.5) mm. ***

C. (1-1.5) mm.

117. Which of the following components of balanced occlusion are frequently altered by dentist ?

A. Cuspal inclination, Condylar guidance.

B. Incisal guidance, cuspal inclination. ***

C. Plane of orientation , curve of spee.

D. Compensatory curve, cuspal inclination.

118. Which of the following is the typical interocclusal distance between opposing denture teeth at the physiological rest position?

A. (0.0-0.15) mm.

B. (2.0-4.0) mm. ***

C. (4.5-5.5) mm.

D. (6.0-8.0) mm.

119. What best describe porcelain?

A. Low compressive.

B. High tensile.

C. Biocompatible. ***

D. High impact strength.

120. Fixed For onlay preparation, reduction of Non functioning cusp should be:

A. (1.5) mm.

B. (2) mm.

C. (1) mm. ***

Prosthodontics Removable. 150 MCQs

1. **Orthographic ridge relationship (class II) presents several problems which should be taken into consideration when constructing complete denture prosthesis. These include all EXCEPT:**

- A. Require minimum interocclusal distance. ***
- B. Have a great range of jaw movement.
- C. Require careful occlusion, usually cuspless teeth are indicated.

RESIDUAL RIDGE RELATIONSHIP:

- Class II or retrognathic is usually difficult as the patient looks toothy, often holds the mandible forward to improve appearance with subsequent TMJ problems, usually have a great range of jaw movements in function, require careful occlusion, and usually needs a large interocclusal distance.
- Class III or prognathic is usually easier if not extreme. The patient usually functions on a hinge (little or no protrusive component) and requires a minimum of interocclusal distance. In any case, do not set the teeth for a retrognathic or Prognathic patient in a normal relationship, unless there is only a moderate deviation from Class I.

2. **Planning centric occlusion for complete denture, it is advisable to have:**

- A. 1-2 mm of vertical and horizontal overlap of upper and lower anterior teeth with no contact. ***
- B. Definite tooth contact of upper and lower anterior teeth in order to facilitate the use of anterior teeth for incision.

3. **The posterior extension of Max complete denture can be detected by the followings EXCEPT:**

- A. Hamular notch.
- B. Fovea palatine. ***
- C. Vibrating line.

4. **The distal palatal termination of the maxillary complete denture base is dictated by the:**

- A. Tuberosity.
- B. Fovea palatine.
- C. Maxillary tori.
- D. Vibrating line. ***
- E. Posterior palatal seal.

Vibrating line is determined the posterior extension of the posterior palatal seal.

5. **Vibrating line:**

- A. Between hard & soft palate.
- B. Between mobile and non mobile soft tissue. ***

6. **Oral surgeon put his finger on the nose of the patient and the patient asked to blow. This done to check:**

- A. Anterior extension of posterior palatal seal. ***
- B. Lateral extension of posterior palatal seal.
- C. Posterior extension of posterior palatal seal.
- D. Glandular opening.

Land marks for posterior palatal seal: The posterior outline: is formed by the "Ah" line or vibrating line and passes through the two pterygomaxillary (hamular) notches and is close to the fovea palatine. The anterior outline: is formed by the "blow" line and is located at the distal extent of the hard palate.

7. Pt. Presented after insertion of complete denture complaining of dysphagia and ulcers what is the cause of Dysphagia?

- A. Over extended. ***
- B. Over post dammed.
- C. Under extended.
- D. Under post dammed.

8. Pt with denture has swallowing problem and sore throat. The problem is:

- A. Posterior over extension at distal palatal end. ***
- B. Over extension of lingual.
- C. Over extension of hamular notch.

9. Nausea is a complaint that a new denture wearer might encounter. It may result from:

- A. Thick posterior border.
- B. Denture under extended.
- C. Denture slightly over extended.
- D. A & B are correct. ***

Gagging (Nausea): Loose denture – thick distal termination of upper denture – lingual placement of upper denture – occlusal plane low.

Types Of Gagging:

- A. Psychogenic - Starts in mind , very difficult to treat.
- B. Stomatogenic - Starts in body (usually dentures), treatable.
- C. Dental causes:
 - 1. Lack of retention.
 - 2. Poor occlusion.
 - 3. Insufficient or excessive palatal seal.
 - 4. Crowded tongue due to a thick palate or poor tooth placement.
 - 5. Excessive salivation.
 - 6. Excessive vertical dimension (often seen in new dentures).

Denture over-extension onto the soft palate may stimulate a gag reflex directly by continuous contact or indirectly by intermittent contact brought about by the activity of the soft palate or posterior third of the tongue. An under-extended denture (or an unstable denture from occlusal interferences) will lack a posterior seal, will dislodge intermittently, irritate the posterior third of the tongue and thus cause nausea. A palpable and thickened posterior border will also irritate the tongue. Interference with tongue space, as in an excessively large vertical dimension which causes compensatory protrusion of the tongue, or in a narrow arch which forces the tongue to occupy an unnatural position, may also manifest as nausea.

- 10. After insertion of complete denture, Pt came complaining from pain in TMJ and tenderness of muscle with difficulty in swallowing, this could be due to:**
- A. High vertical dimension. ***
 - B. Low vertical dimension.
 - C. Thick denture base.
 - D. Over extended denture base.
- 11. Most common complete denture post insertion complaint after 24 hrs:**
- A. Rough.
 - B. Overextension causing laceration. ***
 - C. Pt not used to new vertical dimension.
- 12. Which palatal form is more retentive and offers better stability to complete denture:**
- A. V shaped.
 - B. Wide palate.
 - C. U Shaped. ***
 - D. Flat palate.
- 13. All relate to retention of maxillary complete denture EXCEPT:**
- A. Tongue movement. ***
 - B. Type of saliva.
- 14. Best instrument to locate vibrating line with it is:**
- A. T burnisher. ***
- 15. We can use to palatal posterior seal:**
- A. Le jao carver.
 - B. Kingsley scraper. ***
- 16. An examination of the edentulous mouth of an aged Pt who has wore maxillary complete dentures for many years against six mandibular teeth would probably show:**
- A. Cystic degeneration of the foramina of the anterior palatine nerve.
 - B. Loss of osseous structure in the anterior maxillary arch. ***
 - C. Flabby ridge tissue in the posterior maxillary arch.
 - D. Insufficient inter occlusal distance.

When a patient wears complete maxillary denture against the six mandibular anterior teeth its very common to have to do a reline so often de to loss of bone strucutre in anterior maxillary arch.

17. If the oral tissues are inflamed and traumatized, impression for making a new denture:

- A. Should be started immediately in order to prevent further deterioration.
- B. The occlusion of the existing denture is adjusted, and tissue condition material is applied, and periodically replaced until the tissue are recovered, then making impression take place. ***
- C. The Pt is cautioned to remove the denture out at night.
- D. A & B are correct.
- E. All of the above are correct.

18. Balanced occlusion refers to:

- A. The type of occlusion which allows simultaneous contact of the teeth in centric occlusion only.
- B. The type of occlusion which allows simultaneous contact of the teeth in centric and eccentric jaw positions.***
- C. A type of occlusion which is similar to the occlusion of the natural teeth.

19. The indication for the use of lingual plate major connector include:

- A. For the purpose of retention.
- B. When the lingual frenum is high or when there is a shallow lingual sulcus.
- C. To prevent the movement of mandibular anterior teeth.
- D. All of the above. ***

20. Lingual plate:

- A. Shallow sulcus.
- B. Mobile anterior teeth.
- C. Deep sulcus.
- D. A+ B. ***
- E. All of above.

21. In class I partially edentulous lower arch, selection of major connector depend on:

- A. Height of lingual attachment.
- B. Mandibular tori.
- C. Periodontal condition of remaining teeth.
- D. All of the above. ***

22. In registering the vertical dimension of occlusion for the edentulous patient. The physiological rest dimension:

- A. Equals the vertical dimension of occlusion.
- B. May be exceeded if the appearance of the patient is enhanced.
- C. Is of little importance as it is subject to variations.
- D. Must always be greater than vertical dimension of occlusion. ***

23. Examination of residual ridge for edentulous PT before construction of denture determine stability, support and retention related to the ridge:

- A. True. ***
- B. False.

- 24. Three weeks after delivery of a unilateral distal extension mandibular removable partial denture, a Pt complained of a sensitive abutment tooth, clinical examination reveals sensitivity to percussion of the tooth, the most likely cause is:**
- A. Defective occlusion. ***
 - B. Exposed dentine at the bottom of the occlusal rest seats.
 - C. Galvanic action between the framework and an amalgam restoration in the abutment tooth.
- 25. PT with lower complete denture, intraoral examination show with slightly elevated lesion with confirmed border, PT history of ill fitting denture. It is by:**
- A. Immediate surgical removal.
 - B. Instruct PT not to use denture for 3 weeks then follow up. ***
 - C. Reassure PT and no need for treatment.
- 26. Upon examination of alveolar ridge of elderly PT for construction of lower denture easily displaceable tissue is seen in the crest of ridge. Management:**
- A. Minor surgery is needed.
 - B. Inform the PT that retention of denture will decrease.
 - C. Special impression technique is required. ***
- 27. In recording Man-Max relation , the best material used without producing pressure is:**
- A. Wax.
 - B. Compound.
 - C. Bite registration paste (Zinc oxide & Eugenol paste). ***
- 28. The posterior seal in the upper complete denture serves the following functions:**
- A. It reduces Pt discomfort when contact occurs between the dorsum of the tongue and the posterior end of the denture base.
 - B. Retention of the maxillary denture.***
 - C. It compensate for dimensional changes which occur in the acrylic denture base during processing.
 - D. B & C are correct.
- 29. Function of post dam:**
- A. Prevent tongue from palate touch increase comfort.
 - B. Increase retention. ***
 - C. To compensate acrylic dimension.
 - D. All.
- 30. In recording jaw relation, best to use:**
- A. Occlusal rim with record base. ***
 - B. Occlusal rim with base wax.
 - C. Occlusal rim with nacial frame.

Occlusal rims: make maxilla-mandibular jaw records.

31. The goal of construction of occlusion rims is:

- A. To obtain the occlusal plane, vertical dimension, tentative centric relation, face bow transfer, placement of the teeth. ***
- B. To obtain the protrusive condylar guidance.
- C. To obtain the lateral condylar posts and incisal guide.
- D. None.

32. A temporary form representing the base of a denture which is used for making Maxillo-Mandibular (jaw) relative record for arranging teeth or for trial insertion in the mouth is:

- A. Bite rims.
- B. Custom tray.
- C. Set up.
- D. Base plate. ***

33. To recheck centric relation in complete denture:

- A. Ask Pt to swallow and close.
- B. Ask Pt to place tip of tongue in posterior area and close. ***
- C. To wet his lip and tongue.
- D. All of the above.

34. Management knife-edge ridge in complete denture:

- A. Reline with resilient material.
- B. Maximum coverage. ***
- C. Wide occlusal label.
- D. All of the above.

35. In distal extension P.D during relining occlusal Rest was not seated:

- A. Remove impression and repeat it. ***
- B. Continue and seat in after relining.
- C. Use impression compound.

36. After taking alginate impression:

- A. Wash with water and spray with sodium hydrochloride for 10 sec.
- B. Same but wait 5-10 min and then put in sealed plastic bag. ***

37. Occlusal plane should be:

- A. Parallel to Interpupillary line.
- B. Parallel to ala-tragus line.
- C. At least tongue is just above occlusal plane.
- D. All of the above. ***

38. Occlusal rest function:

- A. To resist lateral chewing movement.
- B. To resist vertical forces. ***
- C. Stability.
- D. Retention.

39. Check bite of retainer by:

- A. Paste. ***
- B. Impression.

40. Selection of type of major connector in partial denture is determined:

- A. During examination.
- B. During diagnosis and planning. ***
- C. During bite registration.

41. Cause of fracture of occlusal rest:

- A. Shallow preparation in marginal ridge. ***
- B. Extension of rest to central fossa.
- C. Improper centric relation.

42. Child came to the clinic with amalgam restoration fracture at isthmus portion, this fracture due to:

- A. Wide preparation at isthmus.
- B. High occlusal.
- C. Shallow preparation. ***
- D. Constricted isthmus.

Isthmus joins the occlusal key with the interproximal box. It is the part of the filling most prone to fracture.

43. Complete denture poorly fit and inadequate inter-occlusal relation:

- A. Relining.
- B. Rebasing.
- C. New denture. ***
- D. None of the above.

44. Diabetic Pt with ill fit denture, examination of residential ridge help to:

- A. Determine the need for tissue conditioning and surgery. ***
- B. Determine occlusal height.
- C. Determine vertical dimension of occlusion.

45. Which of the following statement about the mechanism of action for denture adhesive is not correct:

- A. It depends in part on physical force and viscosity. ***
- B. Carboxyl group provide bio adhesion.
- C. Greater water solubility increase duration of adhesion.
- D. Zinc salts have been associated with stronger longer adhesion.

46. Rigid palatal strap major connector. The material of construction is:

- A. CO-CR. ***
- B. Gold TI.
- C. GoldX
- D. Wrought wire.

47. Porcelain teeth in complete denture opposing natural teeth are not preferred due to:

- A. Increase Occ load on natural teeth.
- B. Wear of natural teeth. ***
- C. Clicking during mastication.

48. Soft palate falls abruptly facilitate recording post dam, falls gradually make recording post dam difficult :

- A. Two statement true.
- B. Two false. ***
- C. First true, second false.
- D. First false, second true.

49. (60 YEARS) old patient need to make complete denture with thick labial frenum with wide base. The operation:

- A. Vestibuloplasty. ***
- B. Z-Plasty.
- C. Subperiosteum incision.
- D. Deepmucoperiosteum incision.

Z-plasty are effective for narrow frenum attachments. Vestibuloplasty is often indicated for frenum attachments with a wide base.

50. In (6 week) intra uterine life the development start. The oral epithelium is stratified squamous epithelium will thicken and give dental lamina:

- A. True. ***
- B. False.

51. Pt with complete denture come to your clinic, complaint from his dry mouth, the proper medicine is:

- A. Anti-diabetic medicine.
- B. Anti-cordial. ***
- C. Steroid.

52. Pt have a complete denture came to the clinic, tell you no complaint in the talking, or in the chewing, but when you exam him, you see the upper lip like too long , deficient in the margins of the lip, reason is?

- A. Deficiency in the vertical dimensional.
- B. Anterior upper teeth are short. ***
- C. Deficient in Vitamin B.

53. (65 years) old black man wants to have very white teeth in his new denture what should the dentist do:

- A. Put the white teeth.
- B. Show the patient the suitable color first then show him the white one. ***
- C. Convince him by showing him other patients photos.
- D. Tell him firmly that his teeth color are good.

OR - Another answer in another test form: (Do not show white teeth).

Often a short informative talk using some of the tooth manufacturer's (or preferably your own) "before and after" photos can be very effective in motivating patients to accept a more natural tooth selection.

SHADE SELECTION:

The shade is selected with the Portrait shade guide. There are **24** shades; enough to fulfill the color requirement of any denture patient. The large selection seems confusing but you will soon note that certain shades will be used the most. Shades A,B,C, & D (16) are the most useful and are called characterized shades as they are a subtle mix of many shades. The last 8 are the Bioform shades, B59-882, and are not characterized and do not look as natural. They are included as Bioform teeth and shades have been sold for many years and it's often necessary to match them.

1. For youthful patients, use lighter shades with a bluish incisal.
2. For older patients, use a darker shade with mostly body color.
3. If the patient has dark hair, brown eyes, and dark skin, darker shades with more yellow and brown will look more natural. "This rule does not apply for Black patients as they often have very white teeth".
4. If the patient has blue eyes and fair skin, use lighter shades with more gray.
5. Consider the patient's desires: Many patients have very definite ideas on tooth color and will often not accept the above guidelines. Don't let the patient get a hold of the shade guide; many will select the pearly white A1 !! Select a shade that you think is suitable and let them make the final choice.
6. Consider the patient's old denture. Do they like the color of the teeth? If they think the color of the old dentures teeth were satisfactory, match them closely. Keep in mind that teeth discolor and other manufacture's shades may be somewhat different.

54. Patient with complete denture pronouncing F as a V :

A. Anterior teeth are upward from lip line. ***

B. Placement of maxillary anterior teeth in complete dentures too far from superiorly and anteriorly might result in difficulty in pronouncing F and V sounds.

55. Patient with complete denture pronouncing F as a V : (Q, Another Exam)

C. Maxillary anterior teeth had placed too far from superiorly and anteriorly. ***

56. Knife ridge should be Tx with:

A. Relining soft material.

B. Maximum coverage of flange. ***

C. Wide occ. Table.

D. All.

If you are fibrating mandibular complete denture for with a patient with knife-edge ridge, you need maximal extension of the denture to help distribute the forces of occlusion over a large area.

57. Pt come to u needs upper partial denture CII Kennedy classification, he has palatal defect (I don't know what it was but i think torus palatines) preferable partial denture with:

A. Horseshoe. ***

B. Palatal bar.

C. Palatal..... X

D. Palatal..... X

58. Patient come to the clinic with ill-fitting denture, during examination you notice white small elevation on the crest of the lower ridge, what will you tell the patient:

A. This lesion needs no concern and he should not worry.

B. The patient should not wear the denture for 2 weeks then follow up. ***

C. X

59. Advantage of Wrought Wire in RPD over Cast Wire:

A. Less irritation to the abutment. ***

60. Why we use acrylic more than complete metal palate in complete denture:

A. Can't do relining for the metal. ***

61. Relining of denture:

A. Remove all or part of fitting surface of the denture and add acrylic.

B. Add acrylic to the base of the denture to increase vertical dimension. ***

62. Rebasing of Complete Denture mean:

A. Addition or change in the fitting surface.

B. Increasing the vertical dimension.

C. Change all the fitting surface. ***

Rebasing is replacement of most or all of the denture base.

63. When all the teeth are missing EXCEPT the 2 canines , according to Kennedy classification it is:

A. Class I modification 1. ***

64. Most important criteria for full ceramic FPD:

A. High compressive strength. ***

B. High tensile strength.

Because ceramics are stronger in compression than in tension, this property is used to advantage to provide increased resistance to shattering.

65. Pt need complete denture u take impression with irreversible hydrocolloid & poured it after late more than 15 min the cast appear sort & chalky the reason is:

A. Dehydration of the impression. ***

B. Expansion of the impression.

C. Immerse the impression in a chemical solution

66. After insertion of immediate complete denture, pt remove denture at night next day he couldn't wearing it .and came to why this is happened:

A. Relief.

B. Swelling And inflammation after extraction.

C. Lack of skills for the patient to put the denture. ***

67. Material which used for flasking complete denture:

A. Plaster. ***

B. Stone.

C. Refractory.

A + B. (If it include these choice is to be correct)

68. Flasking were done in four groups:

A. Group 1: Plaster- Mixed.

B. Group 2: Plaster-Stone- Mixed.

C. Group 3: Plaster- Mixed- Stone.

D. Group 4: Plaster- Stone- Plaster. ***

69. In inflamed mucosa due to wearing denture to when do new denture:

- A. Immediately.
- B. After week.
- C. Put tissue conditioning material and wait until the tissue heal and take impression after 2 weeks. ***

70. Best material for major connector:

- A. Gold wrought wire.
- B. Chrome cobalt. ***
- C. Gold palladium.
- D. Titanium.

71. Patient has a palatal torus b/w hard & soft palate, the major connector of choice:

- A. Anteroposterior palatal strap.
- B. U Shaped. ***
- C. Posterior palatal strap.

72. Pt construct for him a complete denture after few days he came to u complaining from pain & white spots on the residual ridge do relief in that area & give him ointment & after few days he came again complaining the same but in another area the main cause is :

- A. Uneven pressure on the crest of alveolar ridge. ***
- B. Increase vertical dimension.

73. For recording of vertical dimension we use:

- A. Willis Gauge. ***
- B. Caliper.
- C. Face bow.

Resting face height is assessed using:

- A Willis gauge, to measure the distance between the base of nose and the underside of the chin. Is only accurate to ± 1 mm.
- Spring dividers, to measure the distance between a dot placed on both the chin and the tip of the patient's nose. This method is less popular with patients and is C/I for bearded gentlemen (or ladies!).
- The patient's appearance and speech.

Willis gauge is used to record the occlusal face height of the the patient.

A face-bow is a caliper-like device used to record the patient's maxilla/hinge axis relationship (opening and closing axis). It is also used to transfer this relationship to the articulator during the mounting of the maxillary cast.

74. How can u repair fractured rest (In the place where it passes over the marginal ridge of the tooth) in removable partial denture?

- A. Spot welding.
- B. Electric soldering. ***
- C. Industrial brazing.

- 75. Pt have denture, after 5 year he complain of ulcer and inflammation in lower buccal vestibule. wt is the Dx:**
- A. Hypertrophic Frenum. ***
 - B. Epulis fissurment.
- 76. Patient presented to you after fitting the immediate denture 5 – 10 months, complaining pain and over tissue in the mandibular, what is the diagnosis:**
- A. Epulis fissurment. ***
 - B. Hypertrophic Frenum.
- 77. Pt with complete denture complain from tightness of denture in morning then become good this due to:**
- A. Relif of denture. *** (because there may be pressure points or areas that the tissues will try to Adjust to it throughout the day)
 - B. Lack of cheek elastisty (pressure on the flanges <> displacement of denture)
 - C. Poor post dam (no posterior seal <> displacement of denture)
- 78. Old. Pt come with set of complete denture with tight denture in morning and become loose later in a day what is the cause:**
- A. Lack of posterior palatal seal.
 - B. Deflecting of occlusion.
 - C. Excessive relining of denture. ***
 - D. Inelasticity of cheek.
- 79. A border line diabetic pt came with denture stomatitis you find abundant debris in the tissue surface area of the denture > the proper management is:**
- A. Systemic antibiotic.
 - B. Topical antifungal. *** (topical + relining with a tissue conditioner + rest of tissues at night +Good oral hygiene)
 - C. Systemic antifungal.
 - D. Topical antibiotic.
- 80. The peripheries of the custom tray should be under extended to all border and clearance from the frenum areas:**
- A. 2mm. ***
 - B. 4mm.
 - C. 6mm.
 - D. 8mm.
- 81. The goal of making the peripheries of the custom tray under extended to all bordered clearance from the frenum areas:**
- A. To give enough space for the used impression materials to allow border molding the tray. ***
 - B. To give enough space for the die spacer.
 - C. To give enough space for the cementation materials.
 - D. None.

82. The base plate could be made by:

- A. Acrylic plate.
- B. Ceramic plate.
- C. Wax plate.
- D. A and C. ***

83. The vertical height of the maxillary occlusion rim from the reflection of the cast is:

- A. 12mm.
- B. 22mm. ***
- C. 32mm.
- D. 42mm.

84. The anterior width of the maxillary occlusion rim is:

- A. 5mm. ***
- B. 10mm.
- C. 15mm.
- D. 20mm.

85. The posterior width of the maxillary occlusion:

- A. 8-10mm. ***
- B. 8-15mm.
- C. 10-15mm.
- D. 15-20mm.

86. The anterior height of the mandibular occlusion rim is:

- A. 6mm.
- B. 16mm. ***
- C. 26mm.
- D. 36mm.

87. The posterior height of mandibular occlusion rim is:

- A. Equal to the point representing 1/2 of the height of retro molar pad. ***
- B. Equal to the point representing 1/2 of the height of the frenum areas.
- C. Equal to the point representing 1/2 of the height of the alveolar ridge.
- D. None.

88. To record the occlusal plane in order to:

- A. To determine the amount of space between the mandible and the maxilla which will be occupied by an artificial teeth
- B. To determine vertical and horizontal level of the teeth.
- C. A and B. ***
- D. None.

89. The protrusive condylar guidance should be set on the articulator at:

- A. 30-35 degree*.
- B. 50 degree.
- C. 60 degree.
- D. 70 degree.

90. The lateral condylar posts should be set on the articulator at:

- A. Zero degree.
- B. 20 degree.***
- C. 40 degree.
- D. None.

91. The incisal guide should be set on the articulator at:

- A. Zero degree. ***
- B. 20 degree.
- C. 40 degree.
- D. None.

92. The primary goal of anterior tooth selection is:

- A. To provide good functional requirements.
- B. To satisfy aesthetic requirements. ***
- C. To let the patient feel comfortable.
- D. None.

93. The primary goal of posterior tooth selection is:

- A. To provide good functional requirements. ***
- B. To satisfy aesthetic requirements.
- C. To satisfy psychological requirements.
- D. None.

94. You need to get the teeth shade:

- A. Shade guide. ***
- B. Incisal guide.
- C. Acrylic teeth.
- D. Porcelain teeth.

95. The teeth materials are:

- A. Acrylic teeth.
- B. Porcelain teeth.
- C. A and B. ***
- D. None.

96. The width of the lower teeth is:

- A. 1/2 of the maxillary anterior teeth in normal jaw relationship.
- B. 1/3 of the maxillary anterior teeth in normal jaw relationship.
- C. 3/4 of the maxillary anterior teeth in normal jaw relationship. ***
- D. None.

97. Generally posterior teeth are classified into:

- A. Anatomy (Cusp) teeth.
- B. Non-anatomy (Cuspless) teeth or flat.
- C. A and B. ***
- D. None.

98. The process of positioning or arranging teeth on the denture base is termed:

- A. Casting.
- B. Investing.
- C. Setting up. ***
- D. Flasking.

99. Important functions must be considered when arranging anterior teeth:

- A. Aesthetics.
- B. Incision.
- C. Phonetics.
- D. All of the above *.

100. The incisal edge of the maxillary lateral incisor is 1/2 mm above and parallel to the occlusal plane:

- A. 1/2 mm. ***
- B. 1 mm.
- C. 2 mm.
- D. 3 mm.

101. The long axis of the maxillary cusped is inclined slightly to the:

- A. Mesial.
- B. Distal. ***
- C. Buccal.
- D. Lingual.

102. It is called When the occlusal surfaces of the right and left posterior teeth are on the same level:

- A. Vertical plane.
- B. Horizontal plane. ***
- C. Compensating curve.
- D. All.

- 103. The Of the maxillary first bicuspid is raised approximately 1/2mm of the occlusal plane:**
- A. Buccal cusp.
 - B. Lingual cusp. *****
 - C. Mesial surface.
 - D. All.
- 104. The long axis of the maxillary first molar is inclined to :**
- A. Buccal.
 - B. Mesial.
 - C. Distal.
 - D. Lingual. *****
- 105. All maxillary posterior teeth touch the occlusal plane EXCEPT:**
- A. First bicuspid.
 - B. Second bicuspid.
 - C. First molar.
 - D. Second molar. *****
- 106. The distance between the lingual surfaces of the maxillary anterior teeth and the labial surfaces of the mandibular anterior teeth is:**
- A. Vertical overlap (Overbite).
 - B. Horizontal overlap (Overjet). *****
 - C. Occlusal plane.
 - D. All.
- 107. The distance between the incisal edges of the maxillary and mandibular anterior teeth is:**
- A. Horizontal overlap (Overjet).
 - B. Vertical overlap (Overbite). *****
 - C. Occlusal plane.
 - D. All.
- 108. The average distance between the lingual surface of the maxillary anterior teeth and the buccal surface of the mandibular anterior teeth (Overjet) is:**
- A. 1/2mm.
 - B. 1mm.
 - C. 2mm.
 - D. 3mm.*****

Overjet: Distance between upper and lower incisors in the horizontal plane. (Normal is 2 - 4 mm).

- 109. Which tooth of the mandibular anterior teeth that touch the lingual surface of the maxillary anterior teeth in normal centric relation?**
- A. Central incisor.
 - B. Lateral incisor.
 - C. Cusped (Canine). ***
 - D. None.
- 110. The mesial surface of the mandibular lateral incisor contacts:**
- A. The mesial surface of the central incisor.
 - B. The distal surface of the central incisor. ***
 - C. The mesial surface of the cuspid.
 - D. The distal surface of the cuspid.
- 111. The tip of cusp of the mandibular cuspid is one above the occlusal plane to establish Of the maxillary anterior:**
- A. Horizontal overlap.
 - B. Occlusal plane. ***
 - C. Vertical overlap.
 - D. All.
- 112. The relation involves the movement of the mandibular to the side either right or left in which the act of mastication is to be accomplished. Therefore the side to which the mandible moves is called:**
- A. Balancing side.
 - B. Working side. ***
 - C. Compensating side.
 - D. All.
- 113. When the mandible moves to the working side, the opposite side cusp to cusp contacts in order to balance stresses of mastication. This relation is called:**
- A. Working relation.
 - B. Balancing relation. ***
 - C. Occlusal relation.
 - D. None.
- 114. In order to distribute the primary forces of mastication, to fall within the base of the denture, the mandibular teeth are set:**
- A. On the bucal edge of the ridge.
 - B. On the lingual edge of the ridge.
 - C. On the crest of the ridge. ***
 - D. All.

- 115. The mandibular posterior tooth that has no contact with any maxillary teeth during the balancing occlusion is:**
- A. First bicuspid. ***
 - B. Second bicuspid.
 - C. First molar.
 - D. Second molar.
- 116. The used device in flasking procedure is called:**
- A. Articulator.
 - B. Separating medium.
 - C. Flask. ***
 - D. None.
- 117. We Vaseline the inner surface of the flasks all rounds:**
- A. To help in the packing procedure.
 - B. To separate the models (Casts) safety. ***
 - C. A and B.
 - D. None.
- 118. The procedure that follows the flasking procedure is called:**
- A. Polishing.
 - B. Deflasking.
 - C. Packing. ***
 - D. Curing the acrylic.
- 119. Teeth selection in setting up teeth GSF is based on these factors:**
- A. Shade of the teeth.
 - B. Size and shape of the teeth.
 - C. Angle of the teeth.
 - D. A and B. ***
 - E. All the above.
- 120. It is preferable to be the length of the handle of the custom tray:**
- A. 10mm.
 - B. 20mm.
 - C. 15mm. ***
 - D. 25mm.

121. is the art and science of functional, anatomic and cosmetic reconstruction of missing or defective parts in the maxilla, mandible or face by the use of non living substances:
- A. Complete denture.
 - B. Maxillofacial prostheses. ***
 - C. Orthodontics.
 - D. Partial denture.
122. Is the one that provides application and device to restore aesthetic and functional requirements to patients with maxillofacial defects:
- A. Endodontist.
 - B. Pedodontist.
 - C. Maxillofacial Prosthodontics. ***
 - D. Periodontics.
123. The objectives of maxillofacial prosthetics:
- A. Aesthetic.
 - B. Functions.
 - C. Protect the tissues.
 - D. All. ***
124. The prepared surface of an abutment to receive the rest is called:
- A. Minor connector.
 - B. Major connector.
 - C. Rest seat. ***
 - D. None.
125. The part of a removable partial denture that contacts a tooth it affords primarily vertical support is called:
- A. Minor connector.
 - B. Major connector.
 - C. Rest. ***
 - D. None.
126. The part of a removable partial denture is:
- A. Rests.
 - B. Major connectors.
 - C. Retainers.
 - D. All. ***
127. First step in Tx of abused tissue in patient with existing denture is to:
- A. Educate the patient. ***

128. **A rigid part of the partial denture casting that unites the rests and another part of the prosthesis to the opposite side of the arch is called:**
A. Minor connector.
B. Major connector. ***
C. Retainer.
D. Rest.
129. **The part of a removable denture that forms a structure of metal struts that engages & unites the metal casting with the resin forming the denture base is called:**
A. Minor connector.
B. Major connector.
C. Denture base connector. ***
D. Retainer.
130. **The rests are classified into:**
A. Anterior rests.
B. Posterior rests.
C. A and B. ***
D. None.
131. **The surveyor instrument consists of:**
A. Vertical arm.
B. Cast platform or table.
C. Small analysis rod.
D. All. ***
132. **The primary guiding surface that determines the insertion for the partial denture is:**
A. The tooth surface opposite to the edentulous areas.
B. The tooth surface adjacent to the edentulous areas. ***
C. None.
133. **The one who is supposed to give the correct design of the removable partial denture:**
A. Prosthodontist. ***
B. Technician.
C. Assistant.
D. None.
134. **When selecting posterior artificial teeth for complete denture, a fully balanced occlusion is best obtained with the 33 degree ones.**
A. True. ***
B. False

135. **To fabricate a removable partial casting requires making a second cast of high-heat investment material this cast is called:**
A. Study cast.
B. Master cast.
C. Refractory cast. ***
D. All.
136. **Kennedy divided all partial edentulous arches:**
A. Two main types.
B. Three main types.
C. Four main types. ***
D. Five main types.
137. **According to the Kennedy's classification, the bilateral edentulous areas located posterior to the remaining natural teeth is:**
A. Class one. ***
B. Class tow.
C. Class three.
D. Class four.
138. **According to the Kennedy's classification, unilateral edentulous area with natural teeth remaining both anterior and posterior is:**
A. Class one.
B. Class tow.
C. Class three. ***
D. Class four.
139. **The primary role of the anterior teeth on a denture is:**
A. Esthetics. ***
140. **Edentulous pt CIII Kennedy classification 2nd premolar used as abutment when we surving we found mesial under cut what is the proper clasp used:**
A. Wrought wire with round cross section. ***
B. Wrought wire with half round cross section.
C. Cast clasp with round cross section.
D. Cast clasp with half cross section.
141. **Balance occlusion in complete denture help in:**
A. Retention.
B. Stability . ***
142. **In case of advanced upper jaw to the lower this is called :**
A. Angle class I.
B. Angle class II. ****
C. Angle class III.
D. All of the above.

143. **Alginate contains calcium sulphate in concentration of :**
A. 40%
B. 50%
C. 12%***
D. none.
144. **Elastic impression material is:**
A. Rubber. ****
B. Plaster.
C. Zinc oxide.
D. Compound.
145. **In processing an acrylic denture in a water bath, a proper heating cycle is desired because of the possibility of:**
A. Warpage.
B. Shrinkage of the denture.***
C. Porosity due to boiling of the monomer.
D. Crazeing of the denture base around necks of the teeth.
146. **In an alginate impression material, tri sodium phosphate is the:**
A. Filler.
B. Reactor.
C. Retarder .***
D. Accelerator
147. **The principal function of an indirect retainer is to:**
A. Stabilize against lateral movement. ***
B. Prevent settling of the major connector.
C. Minimize movement of the base away from supporting tissue.
D. Restrict tissue ward movement of the distal extension base of the partial denture.
148. **Steep palatal vault provides more stability than flat palatal vault.**
A. True. ***
B. False.
149. **The posterior lingual flange slopes medially away from the mandible to allow for the action of mylohyoid muscle.**
A. True. ***
B. False
150. **In determining the vertical relation of occlusion by mechanical method includes**
A. Ridge rotation
B. Measurements of former (old) dentures
C. Pre-extraction records
D. All of the above

في الختام

**اختبار هيئة التخصصات الطبية يعتمد على الفهم أولاً وأخيراً
بعد توفيق الله ..**

**أي أسئلة أو أي مصدر مهم فيه الفهم للأسئلة قبل الحفظ لأن
احتمالية تغير صيغة السؤال أو الجواب وارد وبنسبة كبيرة ،
لذلك أتمنى التركيز على فهم السؤال وكذلك الإجابات لأي
أسئلة ..**

**أي تجميع أسئلة وارد تكراره بالاختبار ، وممكن ما يتكرر منه
أي سؤال ، لذلك التنوع في الدراسة والمصادر شيء جميل ..**

**تجميع هذا الجزء من الأسئلة جهد شخصي ، أتمنى إنني وفقت في
صياغته بالشكل اللائق والسهل ..**

**(هذا ما عندي فإن أحسنت فمن الله ، وإن أسأت أو أخطأت فمن
نفسي والشيطان)**

**أتمنى التوفيق لجميع زملائي الأفاضل ، وفقنا ربي وإياكم
جميعاً لمستقبل علمي وعملي أجمل ب إذن الله ..**

محبكم

أحمد العوني